

Idiopathic left innominate vein stenosis during pacemaker implantation with venoplasty in a retrograde approach



Danny HF Chow, MBBS, FHKCP, Chi Chung Choy, MBBS, FHKCP, Ngai Yin Chan, MBBS, FHKCP

From the Department of Medicine and Geriatrics, Princess Margaret Hospital, Kwai Chung, Hong Kong.

Introduction

Left innominate stricture or stenosis after hemocatheter insertion or pacemaker lead insertion is not an uncommon vascular complication.¹⁻³ However, spontaneous left innominate venous stricture has not been reported. We present a case with spontaneous left innominate vein stenosis in a patient with history of open heart surgery during pacemaker implantation. Retrograde channel from the right femoral vein was delineated with a coronary guiding catheter followed by repeated venoplasty in the left innominate vein to allow pacemaker lead access.

Case report

A 75-year-old man with a history of severe aortic regurgitation with aortic valve replacement in 2006 was diagnosed to have tachy-brady syndrome with significant pause up to 7.99 seconds. He was admitted for pacemaker implantation.

After a left pectoral pocket was opened through blunt dissection under aseptic technique, a left axillary venous approach through the Seldinger technique was adopted. Initially, a micropuncture set was used. However, the 0.018 in guidewire passed down the left subclavian vein with resistance. A 7 French 13 cm introducer SafeSheath system with 0.035 in guidewire was used to gain better support. However, both a regular 0.035 in guidewire and another 0.035 in Terumo hydrophilic coated guidewire failed to pass down the left innominate vein, evidenced by repeated deflection of the guidewires upward toward the external jugular vein under fluoroscopy ([video available online](#)). A second puncture, aimed more distally at the left subclavian vein, was done to bypass any venous valve, but the guidewires failed to pass again. To ensure that the guidewire was in the true venous lumen, the Terumo hydrophilic guidewire was first passed up the left external jugular vein for support.

KEYWORDS Innominate vein stenosis; Pacemaker implantation; Retrograde venoplasty; Retrograde venogram
(Heart Rhythm Case Reports 2016;2:310-312)

Address reprints and correspondence: Dr Danny HF Chow, Princess Margaret Hospital, 2-10 Princess Margaret Rd, Kwai Chung, Hong Kong. E-mail address: danny.chow.hf@gmail.com.

Then the 7 French SafeSheath was inserted halfway into the subclavian vein until resistance was felt and the dilator was withdrawn. A few milliliters of venous blood were withdrawn from the sheath's side hole to confirm true lumen. Then, 7–8 mL of contrast was injected through the sheath to delineate left subclavian venous anatomy under fluoroscopy, but contrast failed to pass down the left innominate vein.

Right femoral venous access was achieved with 6 French sheath through the Seldinger technique. A 0.035 in guidewire was inserted to support a Judkins Right 4 (JR4) 6 French guiding catheter up to the superior vena cava to help delineate the venous anatomy from the retrograde approach. Multiple injections of contrast through the JR4 catheter confirmed a site of stenosis at the left innominate vein ([Figure 1](#)). After multiple attempts, a 0.035 in Terumo hydrophilic guidewire bypassed the site of stenosis and passed up the left subclavian vein down to the left brachial vein for support. Another 0.014 in Grandslam coronary guidewire was inserted through the JR4 guiding catheter. Using the Terumo guidewire as a guide, the Grandslam guidewire passed through the left innominate vein stenosis to the left brachial vein. The Terumo guidewire was then withdrawn. A 6.0 mm noncompliant balloon was passed down the Grandslam guidewire and multiple dilatations at low pressure (8 ATM) were done along the stenotic segment of the left innominate vein ([Figure 2](#)). After predilatation, venogram through the JR4 catheter revealed evidence of multiple well-formed collaterals proximal to the stenosis ([Figure 3](#)). The Grandslam guidewire was then left at the left subclavian vein as a guide for subclavian venous puncture through the antegrade left axillary vein approach.

After another successful left subclavian venous puncture, a 0.035 in guidewire was advanced through the stenotic segment in the left subclavian vein, and a 7 French 25 cm SafeSheath long sheath was inserted to facilitate endocardial lead insertion. Prior to endocardial lead insertion, a second 7 French 13 cm SafeSheath was inserted to bypass the stenotic segment along with the extra-long sheath to ensure passage of the second endocardial lead. A Medtronic bipolar endocardial lead (model CapSureFix Novux 5076 58 cm) was inserted through the 7 French 25-cm-long sheath under

KEY TEACHING POINTS

- Idiopathic left innominate vein stenosis can occur during pacemaker implantation.
- A traditional stepwise approach is necessary to bypass typical venous anatomy.
- Angiogram from the femoral approach allows delineation of left innominate and subclavian venous anatomy.
- The femoral approach allows strong support for venoplasty.

fluoroscopic guidance and was actively screwed to the right ventricular septum. The stimulation thresholds were obtained for the ventricular lead. The R wave entry was 9.2 mV, impedance was 649 Ω , and minimum stimulation threshold was 0.7 V at 0.5 ms. The 25 cm sheath was split and the ventricular lead position was secured with the triple anchoring sleeve with 3-0 Dermalon.

Another Medtronic endocardial lead (model CapSureFix Novus 5076 52 cm) was inserted through the 7 French 13 cm sheath and the lead was actively screwed to the right atrial appendage. The stimulation thresholds were obtained for the atrial lead. The P wave entry was 2.0 mV, impedance was 623 Ω , and minimum stimulation threshold was 0.9 V at 0.5 ms. The 13 cm sheath was split and the atrial lead was secured with 3-0 Dermalon accordingly.

The subcutaneous pocket was irrigated with gentamicin 80 mg. Both the atrial and ventricular leads were connected to a Medtronic pulse generator (model Medtronic Ensura MRI DDDR). The pulse generator was placed within the

subcutaneous tissue. The pacemaker pocket was sutured with 3-0 Vicryl followed with Steri-Strips application. A pressure dressing was applied.

Discussion

Venous stenosis after transvenous lead implantation is not uncommon. A study by Abu-El-Haija et al⁴ showed that 26% of 212 patients with existing pacing or implantable cardioverter-defibrillator systems presenting for generator replacement, lead revision, or device upgrade, with a mean time since implantation of 6.2 years, had total occlusion of the subclavian or innominate vein. However, idiopathic stenosis of the left innominate vein is rare.

This case describes a patient with a history of open heart surgery presenting with idiopathic stenosis of the left innominate vein. Extreme opening of the median sternotomy retractor, causing fracture of the clavicle or first rib, can lead to thoracic outlet syndrome (TOS).⁵ Three types of TOS are described: neurogenic, venous, and arterial. Neurogenic TOS comprises over 90% of all TOS.⁶ Isolated venous TOS is not common. Patients often present with swelling or cyanosis of the arm. Since there was evidence of well-developed collaterals during venogram in the case, the stenosis may be chronic. The collaterals may alleviate the symptoms of obstruction. Therefore, a final computed tomography scan of the chest was done after pacemaker implantation to delineate the anatomic relationship in the thoracic outlet and assess whether there was evidence of concomitant arterial compression. The computed tomography scan did not reveal any arterial collaterals or evidence of thoracic outlet obstruction.

The 0.035 in hydrophilic guidewire and 0.018 in guidewire from the micropuncture set failed to pass antegradely from left subclavian and axillary venous access. Contrast injection through the 7 French SafeSheath confirmed that the puncture site was within the true lumen. The site of

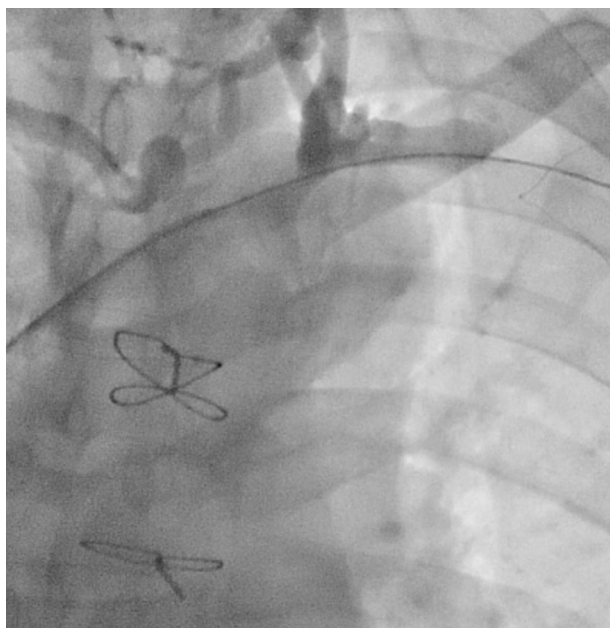

Figure 1 After successful wiring with a 0.35 in Terumo guidewire, venogram confirmed the site of stenosis at the junction of the left subclavian vein and left innominate vein.

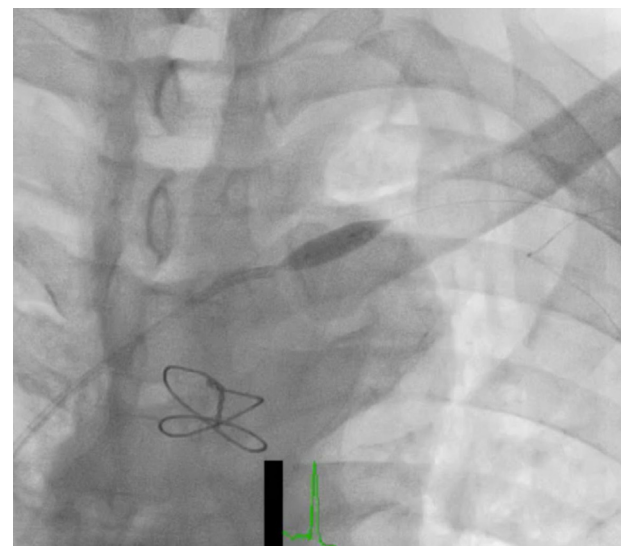


Figure 2 Venoplasty was performed with strong support by placement of the Judkins Right 4 guiding catheter proximal to the stenotic site and passing the Grandslam guidewire down the left brachial vein.

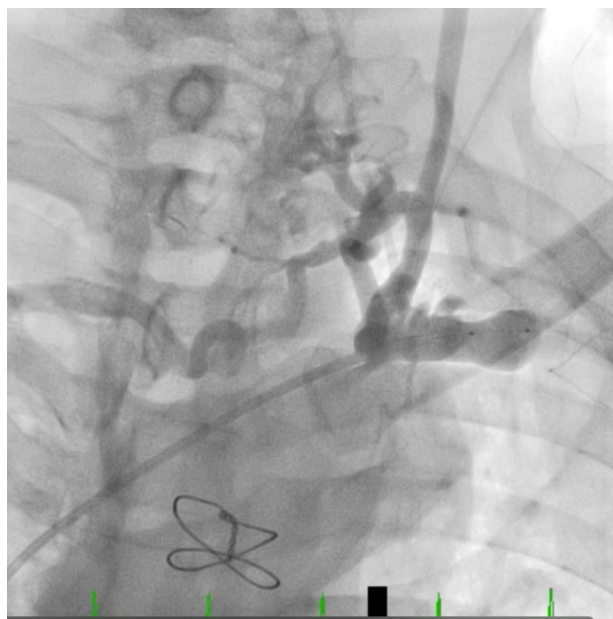

Figure 3 Venogram after venoplasty reviewed well-developed collaterals at the junction between the left subclavian vein and left innominate vein, suggesting the stenosis was chronic.

innominate stenosis was finally identified retrogradely from the femoral venous approach with a coronary guiding catheter. Although an extravascular was necessary, retrograde guidance not only allowed us to delineate the left innominate venous anatomy, it also allowed strong support for venoplasty. By placing the coronary guiding catheter just proximal to the stenotic site and placing the Grandslam guidewire down the left brachial vein, a very strong backup support was gained to pass the peripheral balloon through the stenotic site.

Another approach to delineate the site of innominate venous stenosis antegradely from the left subclavian vein would be inserting a less traumatic 4 French coronary guiding catheter (eg, Tiger II or JR4) under the guidance

of an 0.018 in guidewire from the micropuncture set. This approach would prevent another vascular access, but would only be advantageous if the site of stenosis is short and not severe. If venoplasty is required, an exchange of 0.23 inch guidewire after passing the 4 French guiding catheter through the stenotic site antegradely followed by exchange of 5 French or 6 French guiding catheter is needed.

Conclusion

Idiopathic left innominate vein stenosis or occlusion is rare. Using a coronary guiding catheter with guidewire from the retrograde approach from the right femoral vein allowed identification of the site of stenosis, facilitated venoplasty by providing strong backup support, and acted as an anatomic guide for the final puncture after venoplasty.

Appendix

Supplementary material

Supplementary data associated with this article can be found in the online version at <http://dx.doi.org/10.1016/j.hrcr.2016.03.006>.

References

1. Fourestie V, Godeau B, Lejonc J, Schaeffer A. Left innominate vein stenosis as a late complication of central vein catheterization. *Chest* 1985;88(4):636–638.
2. Bolad I, Karanam S, Mathew D, John R, Piemonte T, Martin D. Percutaneous treatment of superior vena cava obstruction following transvenous device implantation. *Catheter Cardiovasc Interv* 2005;65:54.
3. Lickfett L, Bitzen A, Arepally A, Nasir K, Wolpert C, Jeong KM, Krause U, Schimpf R, Lewalter T, Calkins H, Jung W, Luderitz B. Incidence of venous obstruction following insertion of an implantable cardioverter defibrillator. A study of systematic contrast venography on patients presenting for their first elective icd generator replacement. *Europace* 2004;6:25.
4. Abu-El-Hajja B, Bhawe P, Cambell D, Mazur A, Hodgson-Zingman D, Cotarlan V, Giudici M. Venous stenosis after transvenous lead placement: a study of outcomes and risk factors in 212 consecutive patients. *J Am Heart Assoc* 2015;4(8):e001878.
5. Brooke B, Freischlag J. Contemporary Management of Thoracic Outlet Syndrome. *Curr Opin Cardiol* 2010;25(6):535–540.
6. Sanders R, Hammond S, Rao N. Diagnosis of thoracic outlet syndrome. *J Vasc Surg* 2007;46(3):601–604.