

Received:
16 December 2015

Revised:
08 July 2016

Accepted:
11 October 2016

Cite this article as:

Frankel J, Sukov R. Diagnosing urethral duplication including a novel radiological diagnostic algorithm. *BJR Case Rep* 2017; 2: 20150506.

CASE REPORT

Diagnosing urethral duplication including a novel radiological diagnostic algorithm

JONATHAN FRANKEL, MD and RICHARD SUKOV, MD FRCR

Department of Radiology, Cedars Sinai Medical Center, Los Angeles, CA, USA

Address correspondence to: Jonathan Frankel

E-mail: Jonathan.Frankel@cshs.org

ABSTRACT

Until this 24-year-old male was sexually active, the small dimple on his penile glans had never required any consideration. However, persistent focal irritation during sexual intercourse compelled him to pursue medical attention. Following urological consultation he was referred for imaging evaluation that demonstrated urethral duplication. After determining the subtype classification, urologic repair was successfully completed without complication. Urethral duplication is an exceedingly rare genitourinary anatomic anomaly with a variety of presentations and symptomatology. The vast majority of urethral duplications are diagnosed within the paediatric and adolescent populations. Although urethral duplication is managed by urologists, imaging identification of the particular subtype is critical for proper management planning. A thorough review of existing literature on the classification strategies and diagnostic criteria is discussed. Owing to the scarcity of clinical experience, a wide variety of diagnostic approaches are described. These often include unnecessary radiation, invasiveness and cost. A strategic and efficient diagnostic algorithm is included to guide future imaging evaluation of suspected urethral duplication. This provides the essential clinical information, while minimising radiation, invasiveness and cost.

CASE REPORT

A 24-year-old previously asymptomatic male presented to his primary care physician with a complaint of focal penile irritation related to sexual intercourse. The irritation originates from a lesion along the midline on the dorsum of his penile glans. He was referred to a urologist for further evaluation.

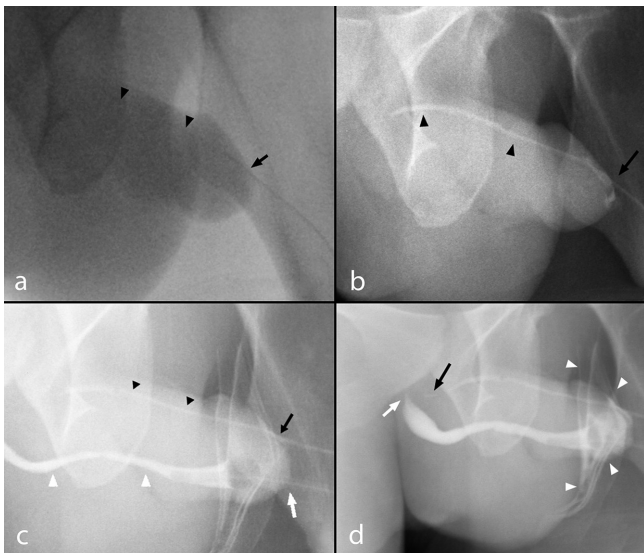
The patient reported noticing a small dimple along the midline on the dorsum of his glans for as long as he could remember. The lesion had not previously caused him any discomfort, nor did he report a history of discharge, including urine, semen, blood or pus from the orifice. In recent months, the patient has become more sexually active and he has become aware that during and after intercourse the site is painful and inflamed for a short period of time. The patient wants to make sure there is not something wrong with his anatomy and seeks a solution.

The patient had no significant past medical history. There is no family medical history of relevance, specifically no one has reported any genital malformation. Physical examination by a urologist demonstrated a well-developed adult male. A small midline opening was present on the dorsum of the penile glans. There was no focal erythema or discharge present at the time of examination. Manipulation of the opening demonstrated a thin lumen that appeared to

continue proximally along the dorsum of the penile shaft. The most likely aetiology was determined to be urethral duplication. Imaging was necessary for confirmation and to delineate the particular anatomic presentation in order to plan treatment. Demonstration of communication with the urethra or bladder would require more extensive surgical intervention to eliminate the sequelae of discharge accumulation in the lumen causing infection, cyst formation or recanalisation of the accessory orifice. The patient was referred to radiology for urethrography.

Since no urine, semen or other discharge had ever been noted to exude from the accessory urethra, a retrograde urethrogram (RUG) was performed (Figure 1). A 5F paediatric catheter was advanced 3 cm through the dorsal accessory meatus. Simultaneously, a 6F Foley catheter was inserted into the orthotopic urethral meatus and the retention balloon inflated in the fossa navicularis. Cystografin contrast was manually instilled into both catheters. Opacification of the accessory meatus demonstrated a hypoplastic urethra traversing the dorsum of the penis and terminating blindly at the level of the levator musculature. No contrast was visualized refluxing into either the orthotopic urethra or the bladder. Contrast injected into the orthotopic urethra demonstrated a normal appearing urethra terminating at the sphincteric musculature. There was

Figure 1. (a-d) A 23-year-old male with urethral duplication. Findings: RUG fluoroscopic coned-down spot images demonstrating (a) cannulation of the dorsal urethra meatus (black arrow) with minimal opacification of the dorsal urethra owing to resistance to Cystografin contrast flow (black arrow heads). (b) Continued gradual pressure resulted in dilatation of the atretic dorsal urethra terminating in a blind end without demonstration of communication with the ventral urethra or bladder (black arrow heads). A small volume of contrast spillage around the urethral meatus resulted owing to the significant resistance offered by the blind end (black arrow). (c) Cannulation of the ventral urethra with inflation of the Foley catheter balloon within the fossa navicularis (white arrow) and demonstration of a normal diameter ventral urethra (white arrows) relative to the atretic accessory urethra (black arrowheads). (d) Contrast is demonstrated tapering proximally at the level of the sphincteric mechanism within the ventral urethra (white arrow) despite increased injection pressure resulting in contrast spillage (white arrowheads). Persistent pressure resulted in further filling of the dorsal urethra demonstrating a tapered blind end without communication to the ventral urethra or bladder (black arrow). RUG, retrograde urethrogram.



2 mm of distance separating the terminal blind end of the accessory urethra and the orthotopic urethra. Based on the radiographic evidence a Type 1-A urethral duplication was diagnosed.

After confirming a Type 1-A urethral duplication the patient was offered and consented to operative reconstruction. A short rigid ureteroscope was used to inspect the main urethra and bladder demonstrating the appearance of normal verumontanum and sphincteric mechanisms confirming the ventral urethra as the functional urethra. The ureteroscope was then used to evaluate the accessory urethra and passed through to the blind-end. The accessory urethra was cauterized as the ureteroscope was withdrawn.

The patient tolerated the procedure well without any reported postoperative complications. At follow-up the patient did not report recurrent irritation during sexual intercourse and was pleased with the cosmetic result.

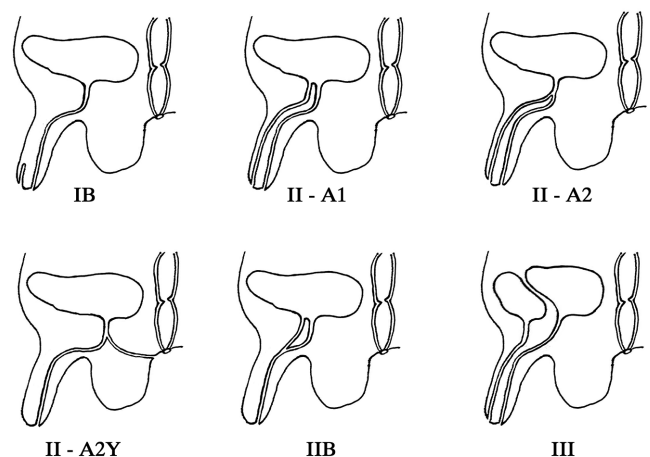
DISCUSSION

Although rare, urethral duplication is known to occur along a spectrum of severity distinguished by discrete anatomic features. The precise incidence is difficult to gauge as there is no consensus from the literature. There are approximately 300 known cases.^{1,2} The most common classification systems are the Effmann³ or Woodhouse and Williams⁴ systems. The former is considered more therapeutically practical and is more commonly used to describe anomalies. The Woodhouse and William system is not as functional but allows for subtype differentiation of the less common coronally oriented anomalies. These are not incorporated within the Effmann system and tend not to alter surgical planning.

The Effmann system classifies a blind incomplete accessory urethra as Type 1. The Type 1-A subtype is an accessory urethra that lacks communication with the functional urethra or bladder. The Type 1-B subtype is a proximal accessory urethra that derives from the functional urethra and terminates blindly within the periurethral soft tissues, similar to a urethral diverticulum. Type 2 duplications represent a complete functional duplication of the urethra with subtypes differentiating the origin of the duplication at either the bladder or along the orthotopic urethra. Further subtype differentiation of Type 2 duplications are determined by their site of termination; either terminating at the penile dorsum, perineum or reconnecting with the orthotopic urethra more distally in its course. Type 3 duplications are complete duplications of the bladder and functional urethra (Figure 2).

The aetiology of the anomalous development is uncertain and likely results from several embryologic errors.⁵ Urethral duplications occur most commonly in males; however, rare instances of

Figure 2. The Effmann classification system divides duplications by their therapeutic interventions and is therefore more useful for surgical planning. A blind incomplete accessory urethra is Type 1. Type 2 represents a complete functional duplication of the urethra with subtypes differentiating the origin of the duplication at either the bladder or along the orthotopic urethra. Further subtype differentiation of Type 2 duplications are determined by their site of termination; either terminating at the penile dorsum, perineum or reconnecting with the orthotopic urethra more distally in its course. Type 3 duplications are complete duplications of the bladder and functional urethra.²⁰



At least 60% of urethral duplications have a second associated abnormality such as: vesicoureteral reflux, bladder exstrophy, epispadias, hypospadias, cryptorchidism, anal stenosis and renal dysplasia.^{7,12–14} Concurrent anatomic abnormalities are found more frequently in cases of bladder duplication.^{4,15} Further evaluation with cross sectional imaging of additional anomalies in the genitourinary, gastrointestinal or central nervous system may be pursued as indicated for surgical planning or clinical management. The decision to proceed with surgical intervention depends on symptom presentation and cosmetic considerations. Surgical approach depends on the anomaly type and can vary in complexity from simple meatoplasty to island flap urethroplasty, accessory urethral excision and, in the most severe cases, ureteral reimplantation.

MR urethrography is an alternative modality available for the evaluation of the lower genitourinary system. This modality, although not new, is only recently developing into a common tool for the evaluation of genitourinary pathology.¹⁶ Extant literature espouses the use of MR urethrography for evaluation of urethral duplication, however, in the opinion of the authors, there is insufficient evidence to support exclusive use as the primary imaging modality. A complete discussion of the benefits and limitations of MR for the evaluation of genitourinary anatomy and pathology is beyond the scope of this article, however, an appreciation of the specific features supporting or excluding its inclusion in the diagnostic algorithm is appropriate.

The diagnostic reliability of MR urethrography for evaluation of urethral anatomy is likely adequate for employing its use delineating the Effmann subtype of urethral duplication.¹⁷ For patients requiring sophisticated surgical planning, or if a high degree of clinical suspicion exists for associated genitourinary or gastrointestinal anomalies, MR urethrography's additional soft tissue information would provide clinically beneficial information and an efficient means to diagnose and provide broader management information.^{17,18} In fact, MR is the best available modality for detailing the presence of anomalies, fistulas or other comorbidities that will affect surgical planning.¹⁶ Additionally, MR provides all of these benefits without the use of ionizing radiation.

Nonetheless, according to the opinion of the authors, the limitations of modern MR urethrography preclude its use as a practical tool in the urethral duplication diagnostic algorithm. Since most patients with urethral duplication are young children, sedation with some type of anesthesia will be necessary, increasing the invasiveness and cost of making the diagnosis. Of all potential risks associated with pediatric MR evaluation the greatest source of complication derives from anesthetic use resulting, at worst, in as many as 1:4000 deaths.¹⁹ Avoiding the use of anesthesia in the pediatric population receiving MR evaluation often requires the use of distraction tools such as child life consultants and sophisticated interventions that further increase the cost and duration of the study.¹⁹ Furthermore, the practicality of MR urethrography itself is challenging requiring the injection of gel or saline into the urethra to ensure adequate urethral distention to optimize signal strength and anatomic delineation;¹⁶ this increases the invasiveness of the diagnostic process as well as compromising the reliability of the results owing to under-distension or inadequate distension.

Ultimately, although exposing the patient to ionizing radiation, fluoroscopic evaluation with voiding cystourethrogram or IVP are equally if not more reliable than MR for diagnosing duplication subtype,¹⁶ less invasive and significantly less expensive and time consuming.

LEARNING POINTS

1. Urethral duplication is a rare congenital anomaly with a variety of presentations each necessitating reliable determination of the anatomic subtype and identification of the functional urethra to ensure proper surgical management.
2. Following the simple radiologic algorithm provided, efficacious diagnosis of urethral duplication subtype can be determined utilizing the least possible radiation, cost and invasive risk.

CONSENT

Informed consent to publish this case was obtained and is held on record.

REFERENCES

1. Sencan A, Yıldız M, Ergin M, Hoşgör M, Yıldız M. A new variation of urethral duplication. *Urology* 2013; **82**: 451–3. doi: <https://doi.org/10.1016/j.urology.2013.02.010>
2. Baid M, Dutta A. Urethral duplication in a 15-year-old: case report with review of the literature. *Rev Urol* 2014; **16**: 149–51.
3. Effmann EL, Lebowitz RL, Colodny AH. Duplication of the urethra. *Radiology* 1976; **119**: 179–85. doi: <https://doi.org/10.1148/119.1.179>
4. Woodhouse CR, Williams DI. Duplications of the lower urinary tract in children. *Br J Urol* 1979; **51**: 481–7. doi: <https://doi.org/10.1111/j.1464-410X.1979.tb03583.x>
5. Casselman J, Williams DI. Duplication of the urethra. *Acta Urol Belg* 1996; **34**: 535e41.
6. Coleman RA, Winkle DC, Borzi PA. Urethral duplication: cases of ventral and dorsal complete duplication and review of the literature. *J Pediatr Urol* 2010; **6**: 188–91. doi: <https://doi.org/10.1016/j.jpuro.2009.07.006>
7. Salle JL, Sibai H, Rosenstein D, Brzezinski AE, Corcos J. Urethral duplication in the male: review of 16 cases. *J Urol* 2000; **163**: 1936–40.
8. Onofre LS, Gomes AL, Leão JQ, Leão FG, Cruz TM, Carnevale J, et al. Urethral duplication – a wide spectrum of anomalies. *J Pediatr Urol* 2013; **9**: 1064–71. doi: <https://doi.org/10.1016/j.jpuro.2013.03.006>
9. Abraham MK, Garge S, Sudarshan B, Vishwanath N, Puzhankara R, Paliwal A, et al. An unusual variant of urethral duplication: an addition to the Effman classification. *Int Urol Nephrol* 2013; **45**: 601–6. doi: <https://doi.org/10.1007/s11255-013-0424-0>
9. Brian D, Coley MD. *Caffey's pediatric diagnostic imaging*. 12th edn. Amsterdam: Elsevier; 2013.
11. Dunnick R, Sandler CM, Newhouse JH. Congenital anomalies: bladder duplication. In: *Textbook of uroradiology*. 5th edn.

- Philadelphia: Lippincott Williams & Wilkins; 2012.
12. Belman AB. Hypospadias and other urethral abnormalities. In: Kelalis P, King L, Belman AB eds. *Clinical pediatric urology*. 3rd edn Philadelphia: WB Saunders; 1992. pp 619–63.
 13. Haleblan G, Kraklau D, Wilcox D, Duffy P, Ransley P, Mushtaq I. Y-type urethral duplication in the male. *BJU Int* 2006; **97**: 597–602. doi: <https://doi.org/10.1111/j.1464-410X.2006.06025.x>
 14. Merrot T, Weber D, Steyeart H, Alessandrini P. Duplication sagittales de l'ure'thre chez l'enfant. A propos de 7 observations. *Prog Urol* 2002; **12**: 77–83.
 15. Vijayaraghavan SB, Nirmala AB. Complete duplication of urinary bladder and urethra: prenatal sonographic features. *Ultrasound Obstet Gynecol* 2004; **24**: 464–6. doi: <https://doi.org/10.1002/uog.1093>
 16. El-Ghar MA, Osman Y, Elbaz E, Refiae H, El-Diasty T. MR urethrogram versus combined retrograde urethrogram and sonourethrography in diagnosis of urethral stricture. *Eur J Radiol* 2010; **74**: e193–e198. doi: <https://doi.org/10.1016/j.ejrad.2009.06.008>
 17. Bhadury S, Parashari UC, Singh R, Kohli N. MRI in congenital duplication of urethra. *Indian J Radiol Imaging* 2009; **19**: 232–4. doi: <https://doi.org/10.4103/0971-3026.54884>
 18. Ryu J, Kim B. MR imaging of the male and female urethra. *Radiographics* 2001; **21**: 1169–85. doi: <https://doi.org/10.1148/radiographics.21.5.g01se121169>
 19. Durand DJ, Young M, Nagy P, Tekes A, Huisman TA. Mandatory child life consultation and its impact on pediatric MRI workflow in an academic medical center. *J Am Coll Radiol* 2015; **12**: 594–8. doi: <https://doi.org/10.1016/j.jacr.2014.12.015>
 20. Dayanc M, Irkilata HC, Kibar Y, Bozkurt Y, Basal S, Xhafa A. Y-type urethral duplication presented with perineal fistula in a boy. *Ger Med Sci* 2010; **8** Doc 33. doi: <https://doi.org/10.3205/000122>