



Contents lists available at ScienceDirect

International Journal of Surgery Case Reports

journal homepage: www.casereports.com

Application of homograft for intraoperative severe atherosclerotic iliac vessel finding in renal transplantation: A case report

Vu Nguyen Le^a, Lu Huu Pham^b, Dang Hai Do^{c,*}, Huong Lan Nguyen^d, Dung Thi Kim Dao^e, Nghia Quang Nguyen^a^a Organ Transplantation Center, Vietnam Germany Hospital, Hanoi, Viet Nam^b Cardiovascular and Thoracic Center, Vietnam Germany Hospital, Hanoi, Viet Nam^c Department of General Surgery, Hanoi Medical University, Hanoi, Viet Nam^d Medical Imaging and Nuclear Medicine Center, Vietnam Germany Hospital, Hanoi, Viet Nam^e Center of Anesthesia and Surgical Intensive Care, Vietnam Germany Hospital, Hanoi, Viet Nam

ARTICLE INFO

Article history:

Received 13 October 2020

Received in revised form 2 November 2020

Accepted 3 November 2020

Available online 7 November 2020

Keywords:

Arterial homograft

Atherosclerotic iliac vessel

Vascular complications

Kidney transplantation

Case report

ABSTRACT

INTRODUCTION: Severe atherosclerosis is a complicated condition in chronic kidney disease (CKD) and could lead to the operation's failure, when it was not detectable by pre-operative diagnostic imaging. Several methods including two-stage approach, synthetic graft, stent... have been reported, but complications (i.e. infection, graft rejection) are a matter of concern. The aim of this case is to provide the one-stage approach, in which renal transplantation and vascular reconstruction using fresh homografts from one brain-dead donor were used.

PRESENTATION OF CASE: We reported a case of a 33-year-old male, who was diagnosed with CKD caused by chronic glomerulonephritis since the age of 28 and had been on hemodialysis. Not until did the transplantation take place that the operation team spotted the atherosclerotic external iliac artery, and vessel graft from the same donor was used and the renal was transplanted. The patient was discharged 14 days after the surgery without any complications.

DISCUSSION: Kidney transplantation has revolutionized the life of patients with end-stage renal disease (ESRD). Around 6% of patients have severe atherosclerosis and the figure is increasing. Vascular degradation in ESRD might lead to unsuccessful operation. One-stage approach (including renal transplantation and external iliac artery replacement) using homograft from one donor is feasible to handle the situation.

CONCLUSION: Severe atherosclerosis often accompanies with CKD. The difficulties of doing arterial anastomosis increases, which requires advanced techniques to deal with. Surgeons should be prepared about this circumstance. One-stage approach using one donor's homografts, is a possible and safe procedure.

© 2020 The Authors. Published by Elsevier Ltd on behalf of IJS Publishing Group Ltd. This is an open access article under the CC BY-NC-ND license (<http://creativecommons.org/licenses/by-nc-nd/4.0/>).

1. Introduction

Kidney transplant is considered as the most effective treatment for patients with end-stage renal disease (ESRD). The standard technique is to make the vascular anastomoses with external iliac vessels. But roughly 6% of transplant recipients have severe atherosclerosis and the number is predicted to rise [1]. Previously, atherosclerosis was the relative contradiction for renal transplantation due to high risk of ischemia, dysfunctional renal graft [2]. The evolution of synthetic grafts have made the operation feasible, but the risk of rejection was increased [3]. Fresh arterial homo-

graft, a safer and more advantageous one, however, has rarely been published. The aim of this case report is to highlight the role of one-stage approach (i.e. renal transplantation and vessel replacement from one brain-dead organ donor in one operation). We followed the SCARE criteria to conduct this article [4].

2. Presentation of case

A 33-year-old male was diagnosed with chronic kidney disease (CKD) due to chronic glomerulonephritis since the age of 28. He had been on hemodialysis three times a week for two months before the operation. Before the kidney transplant, his performance status was good, BMI was 18.9; he had facial edema due to fluid retention and high blood pressure (180/120 mmHg), the ankle-brachial index was 1. Urine volume was roughly 1000 mL/d. His medication included Neo Recormon 4000 UI b.i.d, amlodipine 5 mg q.d. Laboratory results showed an increase in blood urea nitrogen and creatinine (30 mmol/l and 1050 umol/l respectively), other values

* Corresponding author.

E-mail addresses: nguyenvu.urologue@gmail.com (V.N. Le), phamhuulu76@gmail.com (L.H. Pham), dangsp94@gmail.com (D.H. Do), huongus08@yahoo.com (H.L. Nguyen), kimdung.vietduc@gmail.com (D.T. Kim Dao), nghianguyenvduc@gmail.com (N.Q. Nguyen).

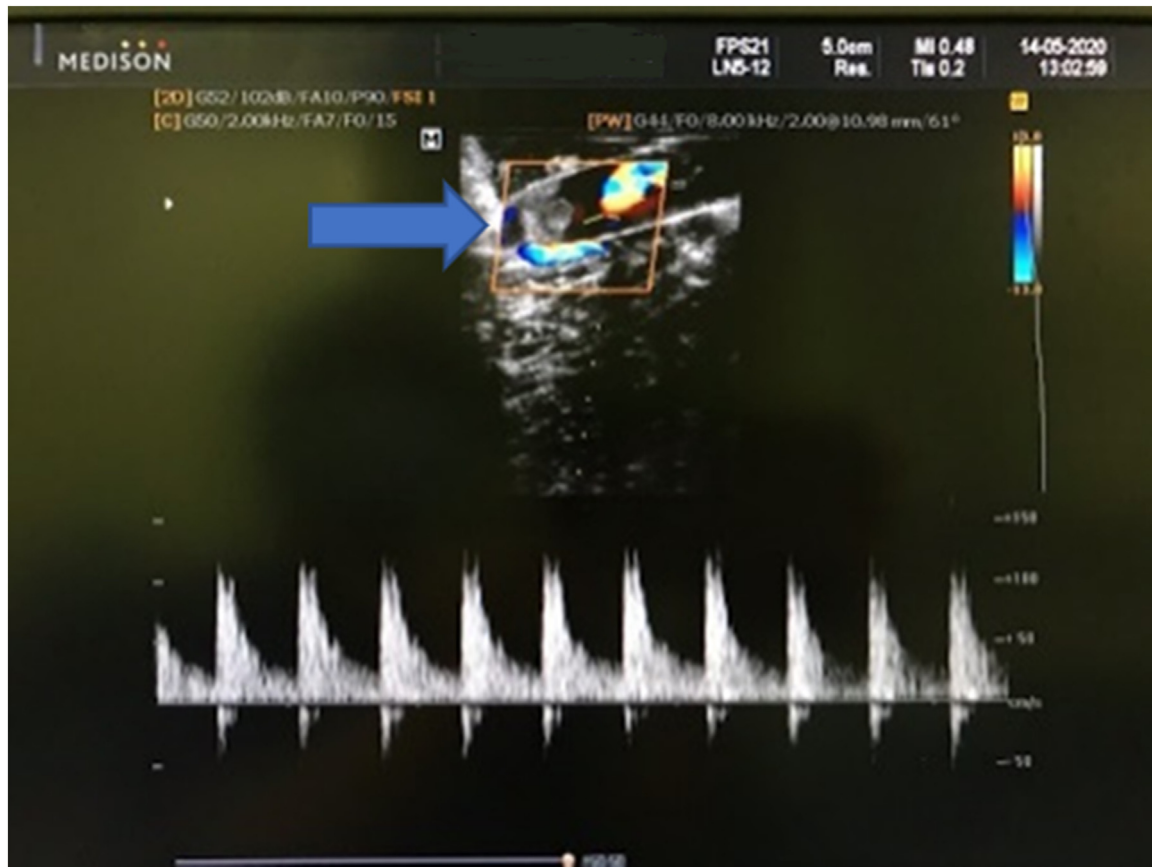

Fig. 1. Thrombus (arrow) in the transplanted renal artery.

were normal, including glucose and blood lipids (serum glucose 5.23 mmol/l, triglyceride 2.8 mmol/l, and cholesterol 5485 mmol/l). Pre-operative Doppler ultrasound (US) and computed tomography (CT) scan did not show any sign of atherosclerosis. He was made to put in the transplant waiting list after passing a thorough evaluation based on the Vietnam Ministry of Health's conditions. The donor was a 47-year-old brain-dead female donor after a traffic collision. The operation plan was to be replaced the recipient's right kidney by the donor's one.

The operation was performed by Vu Le Nguyen, Organ Transplantation Center and Lu Huu Pham, Cardiovascular and Thoracic Center, Vietnam Germany hospital, Hanoi, Viet Nam. The recipient's artery was then sutured to the external iliac artery in an end-to-side fashion. Nonetheless, after clamps removal, the graft was soft, blue with darkened spots on the surface and anuria. Several maneuvers were then applied, including nerve blocking, kidney reposition, raising blood pressure. . . but the situation was unimproved. Intra-operative Doppler ultrasound was conducted, which showed the sign of arterial thrombosis (Fig. 1), the renal hilum resistive index (RI) was 0.86 with Vmax at 107 cm/s. Then, while dissecting the arterial anastomosis, we spotted a 6 cm dissection in the right external iliac vessel (Fig. 2). We transected the proximal at 2 cm below the iliac artery bifurcation, the distal end is close to the inguinal ligament, and placed soft clamps. A donor's external iliac homograft was harvested (Fig. 3). End-to-end anastomoses were performed and then, the renal was re-transplanted by end-to-side fashion (Fig. 4). Five minutes after releasing the clamp, urine flow was observed.

Six hours after the surgery, urine output was 1.6 L. Hematocrit was at 40%, serum sodium concentration was 128 mmol/L, potassium was 4.4 mmol/L. Tacrolimus (FK), mycophenolic acid (MMF) and steroids were used to prevent graft rejection. Doppler ultra-

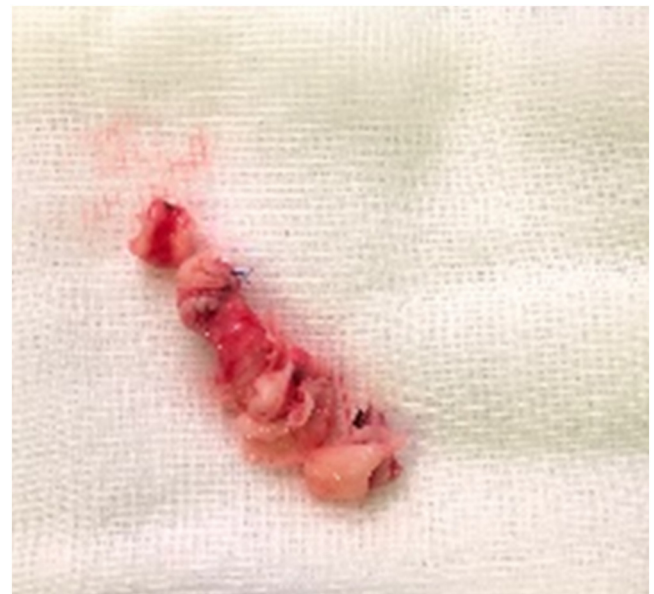

Fig. 2. The luminal dissection of the iliac artery.

sound of the renal arteries revealed that intrarenal RI was 0.64, Vmax20 cm/s, renal artery's RI 0.72 without a sign of thrombus. Heparin at a dose of 50 IU/kg/day daily was given for ten days before switching to aspirin 100 mg/day orally. Seven days after the surgery, the patient was stable, diuretic was not needed. Serum FK was maintained at the level of 9 ng/mL. The patient was discharged 14 days after the operation. The pathological report showed fibromuscular dysplasia along with vascular wall dissection. Follow-up

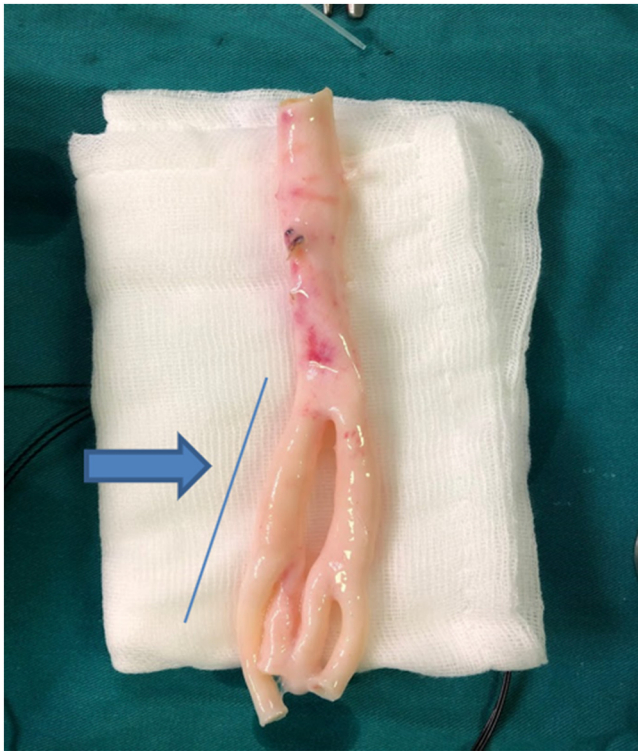


Fig. 3. The iliac artery taken from the brain-dead donor.

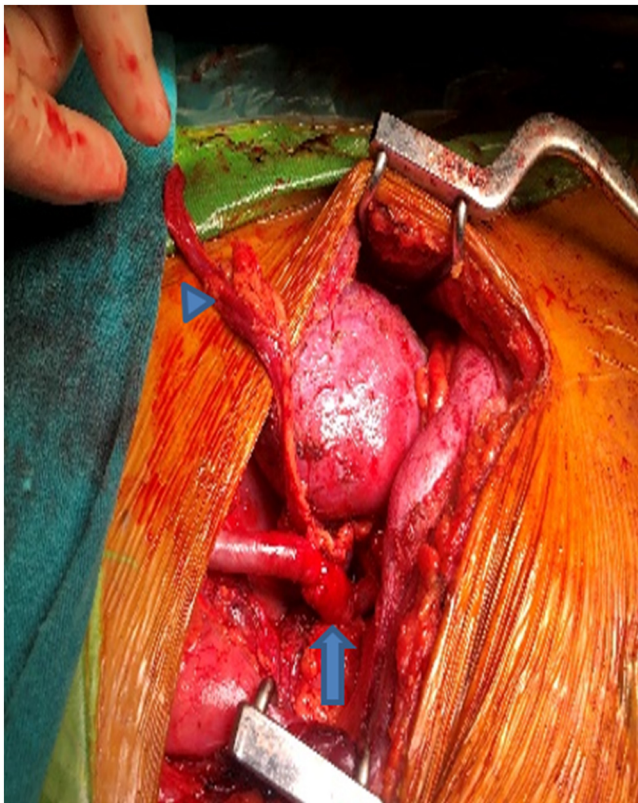


Fig. 4. The transplanted kidney was re-perfused (arrow: ureter, arrowhead: arterial homograft).

examination after 4 months, the patient adhered to the regimen of immunosuppressive drug and is in a good condition with no noticeable complications. Serum FK at 7,8 ng/mL, serum urea nitrogen and creatinine were stable at 10 mmol/l and 125 umol/l, respectively.

3. Discussion

Kidney transplantation has revolutionized the life of ESRD patients, in both physically and psychologically manners. The overall survival (OS) had risen considerably, with 1-year and 5-year OS of 95 and 90% respectively and the quality of life (QOL) is better than hemodialysis group [5,6]. The number of patients awaiting continued to rise, but it is also accompanied by more comorbidities (e.g. atherosclerosis). Around 6% of patients have severe atherosclerosis and the figure is increasing. Several authors pointed out classical and emerging risk factors including age, male, diabetes mellitus, dyslipidemia, mineral bone metabolism, vascular calcification, uremic toxin, inflammation, oxidative stress and endothelial dysfunction. . . [7–9]. And more importantly, the progression of atherosclerosis and CKD was strongly related to each other [7].

Vascular degradation in ESRD might lead to unsuccessful operation [1]. The most common location was on the anastomotic site. The main causes of arterial thrombosis during transplantation are intra-operative renal artery injury which leads to vessel torsion; twisting and kinking [10–12]. Thus, developing surgical techniques and procedures for these patients becomes a prerequisite in the new era of transplantation.

Several approaches have been proposed, including two-stage approach, autologous long saphenous vein graft, synthetic graft, intravascular stent [3,13–15]. However, the increased risk of infection, adhesions are the main disadvantages for a two-stage approach. Furthermore, synthetic graft and stent could lead to higher rate of organ rejection and infection [16]. One-stage approach in which vessel reconstruction by homograft and kidney transplantation could solve the problem. The superiority of this approach is the safety, a lower cost and with fewer complications as only grafts from the same donor are used. The duration and the type of solution are the most important factors on which we should focus as leukocytes, plasmocytes. . . are virtually absent if handled properly by cryopreservation.

Matia (2007) reported 14 cases with CKD in which vascular reconstruction and renal transplantation were conducted in one-stage approach [15]. In the follow-up time, 3 patients died due to gastrointestinal or intracerebral hemorrhage, 2 patients had chronic rejection and 1 patient had acute rejection. The appeal in our case was that we did not spot any risk factors for atherosclerosis as well as pre-operative ultrasound and CT scan did not show the sign of this complication. Not until did the operation run that we identified the atherosclerotic external iliac artery, which made the operation more difficult. The iliac root segment of the donor had just been put into 5 °C storage and was immediately used. Our suggestion is that the evaluation should be carefully carried out, atherosclerosis should not be excluded even if pre-operative imaging was reported normally. And we highlighted the role of the surgeon's skills and experiences, homografts as well as tissue bank in difficult renal transplantation surgery.

4. Conclusion

Severe atherosclerosis is a complicated condition in patients with CKD and the rate is increasing. Surgeons should be cautious, even in patients with low risk, to promptly detect and manage the vascular complications. One-stage approach in which renal transplantation and vascular reconstruction using homograft is a safe and feasible method and could be widely applied.

Declaration of Competing Interest

None.

Funding

None.

Ethical approval

The study was approved by our research committee, Viet Duc University Hospital, Hanoi, Vietnam.

Consent

Written informed consent was obtained from the patient for publication of this case report and accompanying images. A copy of the written consent is available for review by the Editor-in-Chief of this journal on request.

Author contribution

Nghia NQ, Vu LN, Lu PH: Main surgeon.
Dang DH: Wrote manuscript.
Huong NL: Performed the Doppler ultrasound scan.
Dung DTK: Did the anesthesia.

Registration of research studies

1. Name of the registry: researchregistry
2. Unique identifying number or registration ID: researchregistry6189
3. Hyperlink to your specific registration (must be publicly accessible and will be checked): <https://www.researchregistry.com/browse-the-registry#home/registrationdetails/5f9d3cf250c7970015e7458d/>

Guarantor

Vu N. Le, M.D, Ph.D.
Nghia N. Quang, M.D, Ph.D.

Provenance and peer review

Not commissioned, externally peer-reviewed.

References

- [1] K. Nanmoku, Y. Watarai, S. Narumi, et al., Surgical techniques and procedures for kidney transplant recipients with severe atherosclerosis, *Exp. Clin. Transplant.* 15 (6) (2017) 594–601.
- [2] Z. Galazka, T. Grochowicki, T. Jakimowicz, M. Kowalczewski, J. Szmidi, Is severe atherosclerosis in the aortoiliac region a contraindication for kidney transplantation? *Transplant. Proc.* 43 (8) (2011) 2908–2910.
- [3] A. Ozgecik, J. Treckmann, A. Paul, et al., Results of kidney transplantation with simultaneous implantation of vascular graft, *Transplant. Proc.* 39 (2) (2007) 509–510.
- [4] R.A. Agha, M.R. Borrelli, R. Farwana, et al., The SCARE 2018 statement: updating consensus Surgical Case Report (SCARE) guidelines, *Int. J. Surg.* (60) (2018) 132–136.
- [5] J.D. Briggs, Causes of death after renal transplantation, *Nephrol. Dial. Transplant.* 16 (8) (2001) 1545–1549.
- [6] Y. Tamura, A. Urawa, S. Watanabe, et al., Mood status and quality of life in kidney recipients after transplantation, *Transplant. Proc.* 50 (8) (2018) 2521–2525.
- [7] J.M. Valdivielso, D. Rodríguez-Puyol, J. Pascual, et al., Atherosclerosis in chronic kidney disease, *Arterioscler. Thromb. Vasc. Biol.* 39 (10) (2019) 1938–1966.
- [8] P. Stenvinkel, O. Heimbürger, F. Paulter, et al., Strong association between malnutrition, inflammation, and atherosclerosis in chronic renal failure, *Kidney Int.* 55 (5) (1999) 1899–1911.
- [9] K. Nitta, T. Ogawa, Vascular calcification in end-stage renal disease patients, *Contrib. Nephrol.* 185 (2015) 156–167.
- [10] M. Tavakkoli, R.M. Zafarhandi, R. Taghavi, A. Ghoreifi, R.M. Zafarhandi, Immediate vascular complications after kidney transplant: experience from 2100 recipients, *Exp. Clin. Transplant.* 15 (5) (2017) 504–508.
- [11] D. Dimitroulis, J. Bokos, G. Zavos, et al., Vascular complications in renal transplantation: a single-center experience in 1367 renal transplantations and review of the literature, *Transplant. Proc.* 41 (5) (2009) 1609–1614.
- [12] S. Aktas, F. Boyvat, S. Sevmis, G. Moray, H. Karakayali, M. Haberal, Analysis of vascular complications after renal transplantation, *Transplant. Proc.* 43 (2) (2011) 557–561.
- [13] J.I. Moon, G. Ciancio, G.W. Burke, Arterial reconstruction with donor iliac vessels during pancreas transplantation: an intraoperative approach to arterial injury or inadequate flow, *Clin. Transplant.* 19 (2) (2005) 286–290.
- [14] J.G. Wright, R.J. Tesi, D.W. Massop, et al., Safety of simultaneous aortic reconstruction and renal transplantation, *Am. J. Surg.* 162 (2) (1991) 126–130.
- [15] I. Matia, M. Adamec, M. Varga, L. Janousek, K. Lipar, O. Viklicky, Aortoiliac reconstruction with allograft and kidney transplantation as a one-stage procedure: long term results, *Eur. J. Vasc. Endovasc. Surg.* 35 (3) (2008) 353–357.
- [16] S. Sterioff Jr., J.B. Zachary, G.M. Williams, Dacron vascular grafts in renal transplant patients, *Am. J. Surg.* 127 (5) (1974) 525–528.

Open Access

This article is published Open Access at [sciencedirect.com](https://www.sciencedirect.com). It is distributed under the [IJSCR Supplemental terms and conditions](#), which permits unrestricted non commercial use, distribution, and reproduction in any medium, provided the original authors and source are credited.