



Three-Dimensional Printed Model of Partial Anomalous Pulmonary Venous Return with Biatrial Connection

양측 심방 연결을 형성하는 부분 폐정맥 환류 이상의 3D 프린팅 모델

Myoung Kyoung Kim, MD¹ , Sung Mok Kim, MD^{1,2*} ,
Eun Kyoung Kim, MD^{2,3} , Sung-A Chang, MD^{2,3} ,
Tae-Gook Jun, MD⁴ , Yeon Hyeon Choe, MD^{1,2}

Departments of ¹Radiology, ³Medicine, ⁴Thoracic and Cardiovascular Surgery, Samsung Medical Center, Sungkyunkwan University School of Medicine, Seoul, Korea
²Imaging Center, Heart Vascular Stroke Institute, Samsung Medical Center, Seoul, Korea

Partial anomalous pulmonary venous return (PAPVR) is a rare congenital cardiac anomaly that can be difficult to detect and often remains undiagnosed. PAPVR is diagnosed using non-invasive imaging techniques such as echocardiography, CT, and MRI. Image data are reviewed on a 2-dimensional (D) monitor, which may not facilitate a good understanding of the complex 3D heart structure. In recent years, 3D printing technology, which allows the creation of physical cardiac models using source image datasets obtained from cardiac CT or MRI, has been increasingly used in the medical field. We report a case involving a 3D-printed model of PAPVR with a biatrial connection. This model demonstrated separate drainages of the right upper and middle pulmonary veins into the lower superior vena cava (SVC) and the junction between the SVC and the right atrium, respectively, with biatrial communication through the right middle pulmonary vein.

Index terms Pulmonary Veins; Heart Defects, Congenital; Printing, Three-Dimensional; Tomography, X-Ray Computed

INTRODUCTION

Partial anomalous pulmonary venous return (PAPVR) is a rare congenital heart disease with an overall incidence of 0.4–0.7% (1). PAPVR is usually diagnosed using non-invasive imaging techniques, such as echocardiogram, CT, and MRI. The image data is reviewed on a 2-dimensional (D) monitor, which may cause some confusion in under-

Received February 6, 2020
Revised May 20, 2020
Accepted June 16, 2020

*Corresponding author

Sung Mok Kim, MD
Department of Radiology and Imaging Center,
Heart Vascular Stroke Institute,
Samsung Medical Center,
Sungkyunkwan University
School of Medicine,
81 Irwon-ro, Gangnam-gu,
Seoul 06351, Korea.

Tel 82-2-3410-2548

Fax 82-2-3410-2559

E-mail sungmok_kim@hanmail.net

This is an Open Access article distributed under the terms of the Creative Commons Attribution Non-Commercial License (<https://creativecommons.org/licenses/by-nc/4.0>) which permits unrestricted non-commercial use, distribution, and reproduction in any medium, provided the original work is properly cited.

ORCID iDs

Myoung Kyoung Kim
<https://orcid.org/0000-0001-9228-022X>
Sung Mok Kim
<https://orcid.org/0000-0001-5190-2328>
Eun Kyoung Kim
<https://orcid.org/0000-0002-7653-3503>
Sung-A Chang
<https://orcid.org/0000-0001-5124-605X>
Tae-Gook Jun
<https://orcid.org/0000-0002-5161-4665>
Yeon Hyeon Choe
<https://orcid.org/0000-0002-9983-048X>

standing the 3D complex heart structure. In recent years, 3D printing technology has been increasingly used in the medical field, allowing production of actual 3D models using source image datasets obtained from cardiac CT or MRI. The 3D printing has shown great promise in medicine, and reports in congenital heart disease continue to increase (2-4). Moreover, only a few cases have been reported in the imaging case of PAPVR with biatrial connection (5, 6). Here, we report CT findings and a 3D-printed model based on CT datasets of PAPVR with a biatrial connection.

CASE REPORT

A 48-year-old man who had no cardiovascular symptoms was referred to our hospital for further evaluation of cardiomegaly discovered on chest radiography. An electrocardiogram showed right axis deviation with sinus rhythm. A transthoracic echocardiogram revealed PAPVR of the right pulmonary vein to the right atrium (RA) with a dilated right ventricle (RV) cavity and RA enlargement. Furthermore, a combined sinus venosus type atrial septal defect (ASD) and left-to-right shunt was observed. Further studies with electrocardiogram-gated cardiac CT demonstrated the right upper pulmonary vein (RUPV) drained into the superior vena cava (SVC) (Fig. 1A, apical segment; 1B, anterior segment; 1C, posterior segment). The right middle pulmonary vein (RMPV) connected to the SVC at the level of the caval atrial junction and drained into the left atrium (LA) (Fig. 1D). On the coronal image, RMPV was connected just below the posterior segmental orifice of the RUPV (Fig. 1E). For better visualization of the pulmonary vein's anatomy, the 3D printing of the heart was performed by using the cardiac CT data. Anonymized CT data was transferred to a 3D printing company (Anymedi Inc, Seoul, Korea). The production process of the 3D model is as follows: At first, a segmentation of both atria, the SVC, and the pulmonary veins was performed and a stereolithography (STL) file was generated by dedicated software (Mimics, Materialise NV, Leuven, Belgium). Then, the surface of the voxel-based mesh was smoothly expressed and a 2 mm offset was formed in the vessel wall using a commercial program (3-Matic, Materialise NV). The prepared STL file was transferred to a 3D printer system (Objet 500 Connex3; Stratasys, Minnesota, MN, USA). The left- and right-sided cardiac structures were generated with different colors by using rubberlike, transparent, and flexible materials (FLX935, Agilus30/FLX935-L, Agilus30-L, Stratasys Ltd., Eden Prairie, MN, USA). The 3D-printed heart model demonstrated that the RUPV drained into the SVC. The RMPV passed through the caval atrial junction of the RA and drained into the LA (Fig. 1F). Therefore, we assumed that the interatrial shunt was formed through abnormal connection of the RMPV rather than the ASD. The patient had volume-overload right chambers, mild to moderate tricuspid regurgitation and left-to-right shunt. Enlargement of the RA and RV is an American Heart Association/American College of Cardiology Class I indication for surgical correction of sinus venosus ASD, regardless of symptom burden (7). Therefore, the patient was scheduled for surgery because of progression to right heart failure.

DISCUSSION

PAPVR is a congenital pulmonary venous anomaly that involves drainage of one to three

Fig. 1. 3D printing model of partial anomalous pulmonary venous return with a biatrial connection.

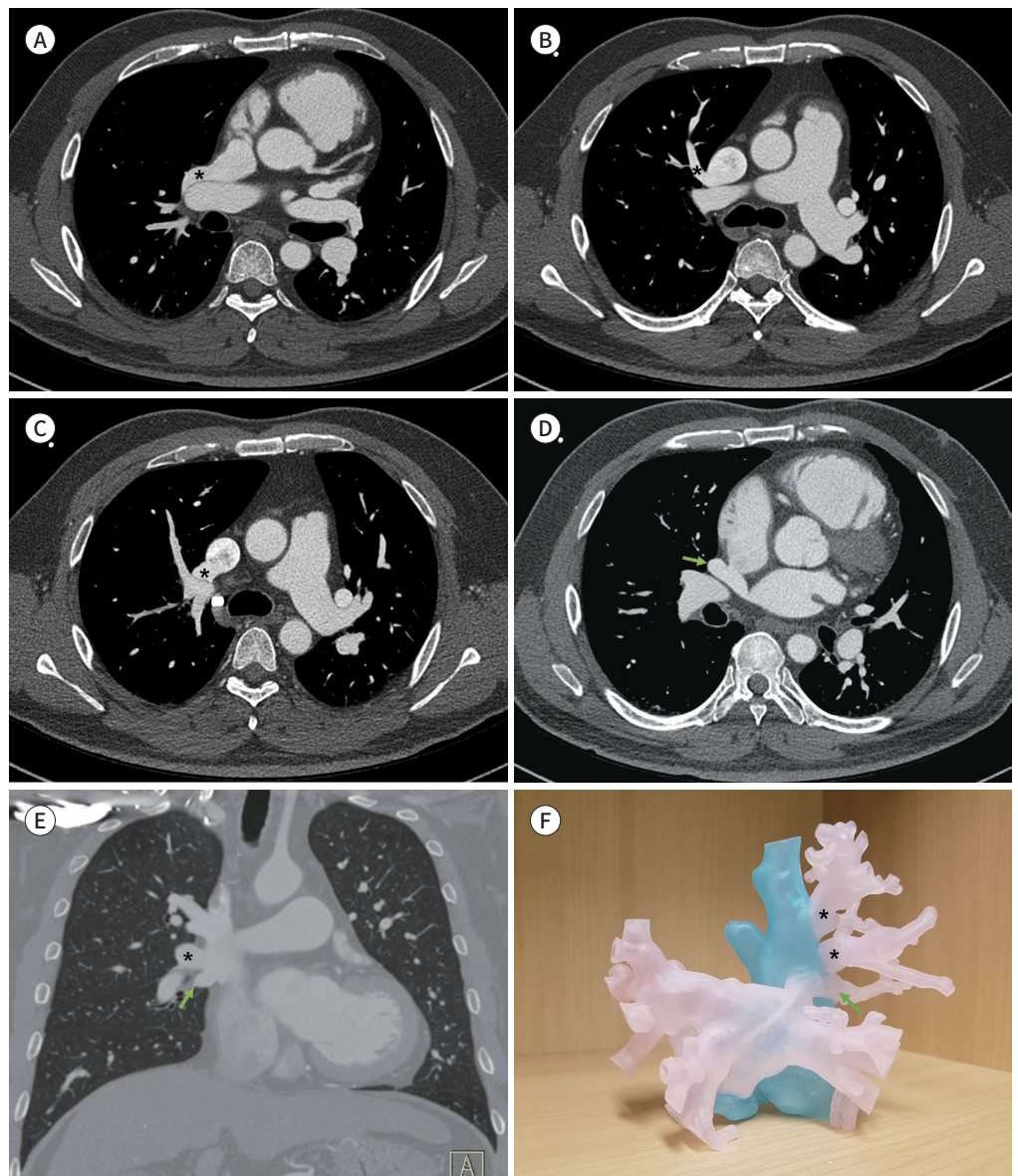
A-C. The right upper pulmonary veins (asterisks) drain into the superior vena cava (**A**, apical segment; **B**, anterior segment; **C**, posterior segment).

D. The right middle pulmonary vein (arrow) drains into the superior vena cava at the level of the caval atrial junction and the left atrium. The right middle pulmonary vein crosses the intact atrial septum and has a bi-atrial connection.

E. The right middle pulmonary vein (arrow) is connected just below the orifice of the posterior segment of the right upper pulmonary vein (asterisk).

F. The 3D-printed model demonstrates that the right upper pulmonary veins (asterisks) drain into the superior vena cava. The right middle pulmonary vein (arrow) passes through the caval atrial junction of the right atrium and drains into the left atrium.

3D = three-dimensional



pulmonary veins into the right-sided circulation, with or without a partial left-to-right shunt. The most common type of PAPVR is an anomalous right upper lobe pulmonary vein draining to the SVC or the RA (8). Right upper lobe PAPVR is accompanied by a high prevalence (80-90%) of sinus venous ASD located high in the septum near the SVC orifice (1). At other point, a previous report found that a posterior inter-atrial communication closely related to the orifice of the SVC or inferior vena cava suggested that sinus venosus atrial defect should be considered as an anomalous venous connection with an inter-atrial communication outside the boundaries of the atrial septum (9). Watanabe et al. (5) reported a case of a 3-year-old boy who had PAPVR with a biatrial connection. They observed that anomalous connection between the RUPV and the RMPV was very close to the orifice of the right pulmonary vein in the RA. Wang et al. also reported a case of a 75-year-old female who had the symptoms of dyspnea and palpitation (6). They demonstrated that the SVC overrode across the intact atrial septum and had bi-atrial connection with one opening connecting to the RA and another opening to the LA using CT angiography. In the present case, right upper lobe pulmonary veins drained to the SVC with separate ostia, and the right middle lobe pulmonary vein connected to the SVC at the level of the caval atrial junction and continuously drained to the LA. Biatrial communication appeared to be formed through the right middle lobe pulmonary vein rather than ASD.

In PAPVR, the patient's clinical severity is determined by degree of left-to-right shunt. Patients with a small amount of shunt are usually asymptomatic. These anomalous veins tend to not be found during the patient's lifetime but are sometimes incidentally detected during investigation of another disease. However, patients with large shunts present with symptoms. The flow ratio of pulmonary-to-systemic blood flow is used to determine the significance of the shunt. A ratio (Q_p/Q_s) of 1.5:1 generally requires surgical repair. In patients without symptoms, enlargement of the RA and RV is also considered a surgical indication (7).

Diagnosis of PAPVR has been a clinical challenge. Symptoms or signs such as dyspnea, atrial arrhythmias, right heart failure, and pulmonary hypertension may occur but are not specific to PAPVR. Many PAPVR cases are misdiagnosed as primary pulmonary hypertension (10) or are diagnosed incidentally (1). MRI and CT are increasingly being used in diagnosis and follow-up of congenital pulmonary vein anomalies. With development of a 3D reconstruction method, 3D volume-rendered images have been used in the diagnostic process of congenital heart disease. Although such technique allows observers to visualize the heart from various angles, these methods are insufficient to provide complete understanding of the intra-cardiac structures because it relies on interpretation from a 2D screen. To overcome this drawback, studies have attempted to create personalized 3D heart models using 3D printing techniques (2-4). The 3D-printed models derived from patient imaging data not only improve spatial visualization, but also assist in preoperative planning, serve as useful tools in medical education, and improve doctor-patient communication.

Here, we reported a case involving CT images and a 3D-printed model of PAPVR with a biatrial connection. These images and a 3D model demonstrated a biatrial connection through the RMPV. Biatrial connection of PAPVR is exceptionally rare. When PAPVR with inter-atrial shunt is suspected, in addition to routine echocardiography, CT images with a 3D printing can help understand anatomic structure.

Author Contributions

Conceptualization, C.Y.H.; funding acquisition, C.Y.H.; investigation, K.M.K., K.S.M.; visualization, K.M.K., K.S.M.; writing—original draft, K.M.K., K.S.M.; and writing—review & editing, all authors.

Conflicts of Interest

The authors have no potential conflicts of interest to disclose.

Acknowledgments

This study was supported by the DongKook Life Science. Co., Ltd., Republic of Korea. Grant was used to pay for the creation of 3D printed model.

REFERENCES

1. Ho ML, Bhalla S, Bierhals A, Gutierrez F. MDCT of partial anomalous pulmonary venous return (PAPVR) in adults. *J Thorac Imaging* 2009;24:89-95
2. Yoo SJ, Van Arsdell GS. 3D printing in surgical management of double outlet right ventricle. *Front Pediatr* 2018;5:289
3. Kim GB, Lee S, Kim H, Yang DH, Kim YH, Kyung YS, et al. Three-dimensional printing: basic principles and applications in medicine and radiology. *Korean J Radiol* 2016;17:182-197
4. Yang DH, Park SH, Lee K, Kim T, Kim JB, Yun TJ, et al. Applications of three-dimensional printing in cardiovascular surgery: a case-based review. *Cardiovasc Imaging Asia* 2018;2:166-175
5. Watanabe N, Fallah H, Pugh C, Nasirov T. Biatrial connection of partial anomalous pulmonary venous return. *Asian Cardiovasc Thorac Ann* 2017;25:381-382
6. Wang H, Guan H, Wang DW. Partial anomalous pulmonary venous connection to superior vena cava that overrides across the intact atrial septum and has bi-atrial connection in a 75-year-old female presenting with pulmonary hypertension. *BMC Cardiovasc Disord* 2014;14:149
7. Dudzinski DM, Bhatt DL, Aragam JR, Maron BA. Explaining unexplained dyspnea: the ever "holesome" heart. *Circulation* 2014;130:2057-2066
8. Alsoufi B, Cai S, Van Arsdell GS, Williams WG, Caldarone CA, Coles JG. Outcomes after surgical treatment of children with partial anomalous pulmonary venous connection. *Ann Thorac Surg* 2007;84:2020-2026; discussion 2020-2026
9. Oliver JM, Gallego P, Gonzalez A, Dominguez FJ, Aroca A, Mesa JM. Sinus venosus syndrome: atrial septal defect or anomalous venous connection? A multiplane transoesophageal approach. *Heart* 2002;88:634-638
10. Gatzoulis MA, Giannakoulas G. Sinus venosus atrial septal defect in a 31-year-old female patient: a case for surgical repair. *Eur Respir Rev* 2010;19:340-344

양측 심방 연결을 형성하는 부분 폐정맥 환류 이상의 3D 프린팅 모델

김명경¹ · 김성목^{1,2*} · 김은경^{2,3} · 장성아^{2,3} · 전태국⁴ · 최연현^{1,2}

부분 폐정맥 환류 이상은 드문 선천성 폐정맥 기형의 한 종류로 진단 시 종종 간과될 수 있다. 대부분의 경우 비 침습적인 영상검사인 심장 초음파, CT 또는 MRI로 진단을 하게 되는데, 2D 모니터를 이용한 영상진단은 삼차원적으로 복잡한 심장의 구조를 이해하는데 제한이 있다. 최근에는 CT와 MRI에서 얻은 의료 영상 데이터를 기반으로 3D 프린팅 기술을 이용하여 심장의 모형을 만드는 기술이 소개되어 점차 이용이 증가되고 있다. 본 증례 보고에서 저자들은 우측 상 폐정맥과 우측 중 폐정맥이 상대정맥으로의 각각 배출되며 우측 중 폐정맥을 통해 양측 심방 간의 연결이 이루어진 환자의 CT 영상 및 3D 프린팅 모델에 대해 보고하고자 한다.

성균관대학교 의과대학 삼성서울병원 ¹영상의학과, ³내과, ⁴흉부외과,
²삼성서울병원 심뇌혈관병원 이미징센터