



Contents lists available at ScienceDirect

International Journal of Surgery Case Reports

journal homepage: www.casereports.com

Phalangectomy combination double-pedicled digital artery flap for second-toe macrodactyly reconstruction: A case report

Fonny Josh^{a,b}, Tomie Hermawan Soekamto^c, Muhammad Faruk^{d,*}, August Jacob Rieuwpassa^{a,b}^a Division of Plastic and Reconstructive Surgery, Department of Surgery, Faculty of Medicine, Hasanuddin University, Makassar, Indonesia^b Division of Plastic and Reconstructive Surgery, Department of Surgery, Dr. Wahidin Sudirohusodo Hospital, Makassar, Indonesia^c Department of Plastic and Reconstructive Surgery, Koja Hospital, Jakarta, Indonesia^d Department of Surgery, Faculty of Medicine, Hasanuddin University, Makassar, Indonesia

ARTICLE INFO

Article history:

Received 8 March 2021

Accepted 10 March 2021

Available online 13 March 2021

Keywords:

Macrodactyly

Phalangectomy

Double-pedicle digital artery flap

Case report

ABSTRACT

INTRODUCTION: Pedal macrodactyly is a rare form of congenital deformity in which the toes and underlying structures are enlarged. The goal of most macrodactyly reconstruction surgeries is to reconstruct the affected toes to resemble the normal size such that the patient is able to wear shoes of the same size. **CASE PRESENTATION:** We report a three-year-old female patient presenting with an enlargement of the right foot index and middle toes. The anomaly was noticed at two months of age and grew progressively. X-ray imaging revealed enlarged bones and soft-tissue hypertrophy proximal to the distal phalanx of the second and third digits. There was no history of other systemic or syndromic diseases. The patient underwent phalangectomy surgery involving reduction of the fibrofatty tissue, double-pedicle medial and lateral digital artery flap. Satisfactory results were noted at evaluation two months after surgery. **CONCLUSION:** Macrodactyly reduction surgeries are generally composed of several kinds of surgical techniques to provide the best results. The management of macrodactyly depends on the surgeon's experience while considering the most suitable surgical technique to be performed in each case. Therefore, it was deemed necessary to report this case and its surgical technique. We hope that this case report will enrich the existing literature and be useful for the management of macrodactyly cases.

© 2021 The Authors. Published by Elsevier Ltd on behalf of IJS Publishing Group Ltd. This is an open access article under the CC BY-NC-ND license (<http://creativecommons.org/licenses/by-nc-nd/4.0/>).

1. Introduction

Macrodactyly is a rare form of congenital deformity in which the fingers or toes are enlarged [1]. All the underlying structures, including bones, tendons, nerves, blood vessels, fat tissue, nails and skin, are enlarged [1,2]. Primary macrodactyly is defined as an enlargement of the fingers or toes, excluding limb hypertrophy, vascular abnormalities, and other syndromic disorders. In contrast, secondary macrodactyly presents with underlying diseases such as neurofibromatosis, hemangiomatosis, arterial-venous malformations, congenital lymphedema, and Klippel-Trenaunay-Weber syndrome [3,4].

Barsky described two types of macrodactyly: static and progressive. Static macrodactyly occurs at birth, whereby the digits appear larger and grow proportionately with the rest of the body. Progressive macrodactyly is characterized by disproportionate growth, and

the digits increase in size more rapidly than the normal growth patterns [2,5].

Although the exact etiology of macrodactyly is unknown, a study conducted by Wu et al. discovered that macrodactyly may be related to mutation of the PIK3CA gene. Macrodactyly accounts for 1% of all congenital abnormalities of the extremities, and the incidence is estimated at 1 case per 100,000 live births. It has also been reported that macrodactyly predominantly occurs in males at a ratio of 1.2:1. Macrodactyly has a higher probability of affecting the second digits, with the progressive type having a higher proportion among all cases [6].

The goals of surgical intervention are to reduce deformity, improve functionality, and reduce the symptoms that arise from the condition. Surgical interventions for macrodactyly include the following: fat mass reduction by debulking-dissecting of bone and soft tissue; osteotomy or ostectomy; epiphysiodesis; nerve decompression; and amputation. Combinations of surgical techniques that can be performed include phalangectomy followed by tendon shortening and fixation of the adjacent joint capsules [4,6,7]. We herein report a case of pedal macrodactyly of the right foot, and this case is reported in line with the Surgical Case Report Guidelines (SCARE Guidelines) 2020 [8].

* Corresponding author at: Department of Surgery, Faculty of Medicine, Hasanuddin University, Jalan Perintis Kemerdekaan KM 11, Makassar, 90245, Indonesia.

E-mail addresses: fonnyjosh2003@yahoo.com (F. Josh), tomherma@yahoo.com (T.H. Soekamto), farosex8283@gmail.com (M. Faruk), bedahplastikfkuh@gmail.com (A.J. Rieuwpassa).

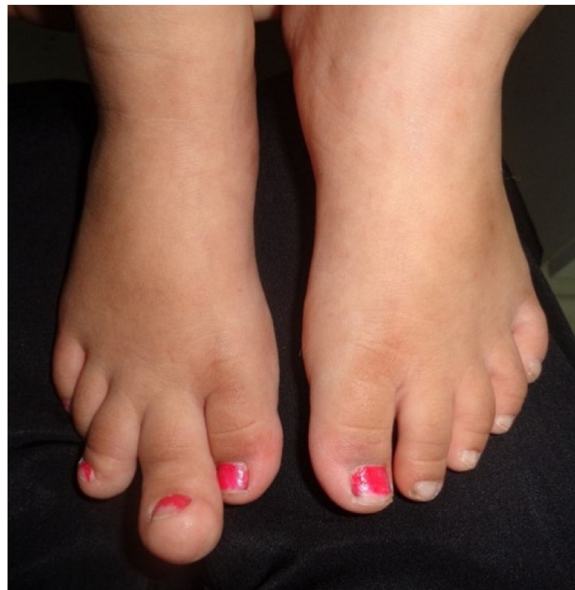

Fig. 1. Picture of the patient's foot before the surgery.

2. Case report

A three-year-old female presented with a main complaint of an enlargement of the index toe of her right foot. This was noticed by the parents when she was 2 months old (Fig. 1). When she was one year old, the growth became more significant and grew progressively until it curved upwards. We found no evidence of syndromic or systemic abnormalities. The patient was born at full-term gestation, with a normal delivery by a doctor in the hospital. Two antenatal care sessions were performed, and there was no illness or medicine consumption during pregnancy. There was no family history of similar congenital abnormalities.

Physical examination revealed that the second and third digits of the right foot were larger than those of the normal side. The second digit was also curved upwards. The length of the second digit was 3.5 cm, with a diameter of 6.5 cm. X-ray imaging showed that the bones proximal to the distal phalanx were enlarged, accompanied by soft-tissue hypertrophy (Fig. 2). We conducted a multistep procedure as follows: medial phalangectomy (Fig. 3B) from the dorsal approach (Fig. 3A); joint capsule fixation with 4.0 nylon thread, insertion of intramedullary pinning and reduction of skin and soft tissue on the medial-distal phalanx dorsal area with preservation of the medial and lateral digital arteries (Fig. 3C); and ellipse excision (Fig. 3D) to remove the excess skin and fibrofatty tissue on the plantar side (Fig. 3E). Fig. 3F shows the end result.

We (plastic surgeons and residents) briefly describe the surgical procedure to the second digit as follows. The patient was placed in a supine position under general anesthesia. A longitudinal line design (Fig. 4A) was made on the dorsal side of the medial phalanx, and an ellipse-shaped design was made on the plantar side with the proximal opening facing toward the proximal side (Fig. 4B). A longitudinal incision was made on the dorsal side of the second

digit, and the entire medial phalanx was removed (Fig. 4C). The joint capsule was brought closer and sutured with 4.0 nylon thread. The proximal and distal phalanx were stabilized by intramedullary pinning using Kirschner wire (Fig. 4D). The digitalis extensor tendon was shortened and sutured with a mattress suture using 5.0 nylon thread. On the plantar side of the second digit, the skin and fibrofatty tissue were excised according to the design (Fig. 4E and F). Skin closure was conducted by advancing two flaps with digitalis artery pedicles from the medial and lateral sides (Fig. 4G). Excess skin and soft tissue on the dorsal side of the medial phalanx were excised while preserving the medial and lateral digital arteries. The wounds were sutured with 4.0 absorbable thread and 5.0 nylon thread (Fig. 4H and I). We performed a histopathological examination on the excised tissue, which displayed fibrolipoma and osteochondroma features.

There were no complications during or after the surgery. The intramedullary pinning was maintained for 4 weeks. Six months later, we decided to perform a secondary surgery to reduce the excess fibrofatty tissue. Two months after the surgery, we found that the patient's index toe was similar to the healthy side (contralateral) (Fig. 5). The patient was able to wear a shoe of the same size as that of her normal foot, and there were no significant complaints during the healing process. The patient's parents were satisfied with the results of the surgery.

3. Discussion

Primary macrodactyly presents as an overgrowth involving all toe structures. In this case, the patient's toes had characteristics that were consistent with Barsky's description of macrodactyly. The patient's affected toes showed fast growth and continued to grow disproportionately, which is also known as the progressive type

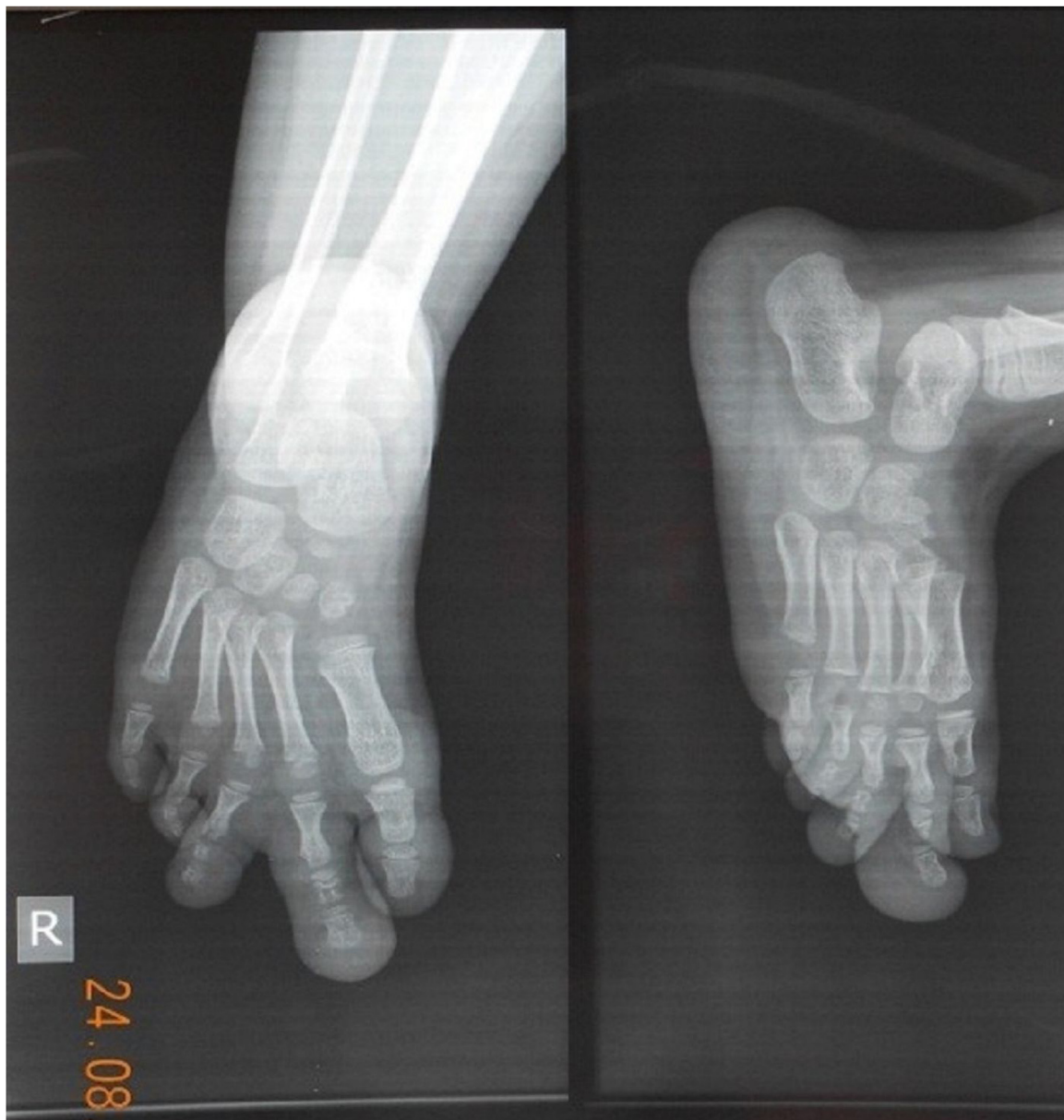

Fig. 2. X-ray imaging before the surgery.

[1,2,5]. This case of macrodactyly was considered nonhereditary, consistent with the patient's family history, as no family member had the same condition [6].

The goals of surgical intervention in pedal macrodactyly are to restore size, reshape the toes, and reduce morbidity while preserving esthetic aspects. To achieve this goal, comprehensive preoperative planning is required. X-ray examination was conducted before the surgery to assess the level of deformity. Based on physical examination and X-ray images, we planned to perform a phalangectomy at the medial phalanx and a reduction in the skin and fibrofatty tissue of the second toe [5,9].

We decided to only perform reconstruction surgery on the second toe because of the following considerations. First, the second toe grew more progressively, which greatly affected the patient's feet and shoe size asymmetry. Second, having a simultaneous reconstruction surgery on two digits that are close together will risk injuring the digital artery, which can cause flap necrosis or even loss of the entire digit. If the second or third toe was found to

be enlarged in the future, another reconstruction surgery would be conducted.

Ray amputation or ray resection is one of the most common surgical techniques for progressive macrodactyly [4,10]. The dorsal longitudinal incision is designed to facilitate the opening of the medial phalanx. In this case, phalangectomy to the medial phalanx was performed to reduce the length. The advantage of this technique is the ability to reduce the length quite effectively. The drawback of this technique is regarding esthetics, as this technique removes one segment of the patient's toe. This shortcoming will be obvious if the segment removed is the distal phalanx with the nail. Toenails in women affect the esthetics of the feet, especially when wearing open-toed shoes.

The joint capsule was sutured and fixated using Kirschner wire to prevent twisting at the proximal and distal digits and to let arthrodesis occur. The extensor tendon was shortened, but the flexor tendon was not shortened because the length of the flexor tendon will adjust over time. An elliptical excision design at the

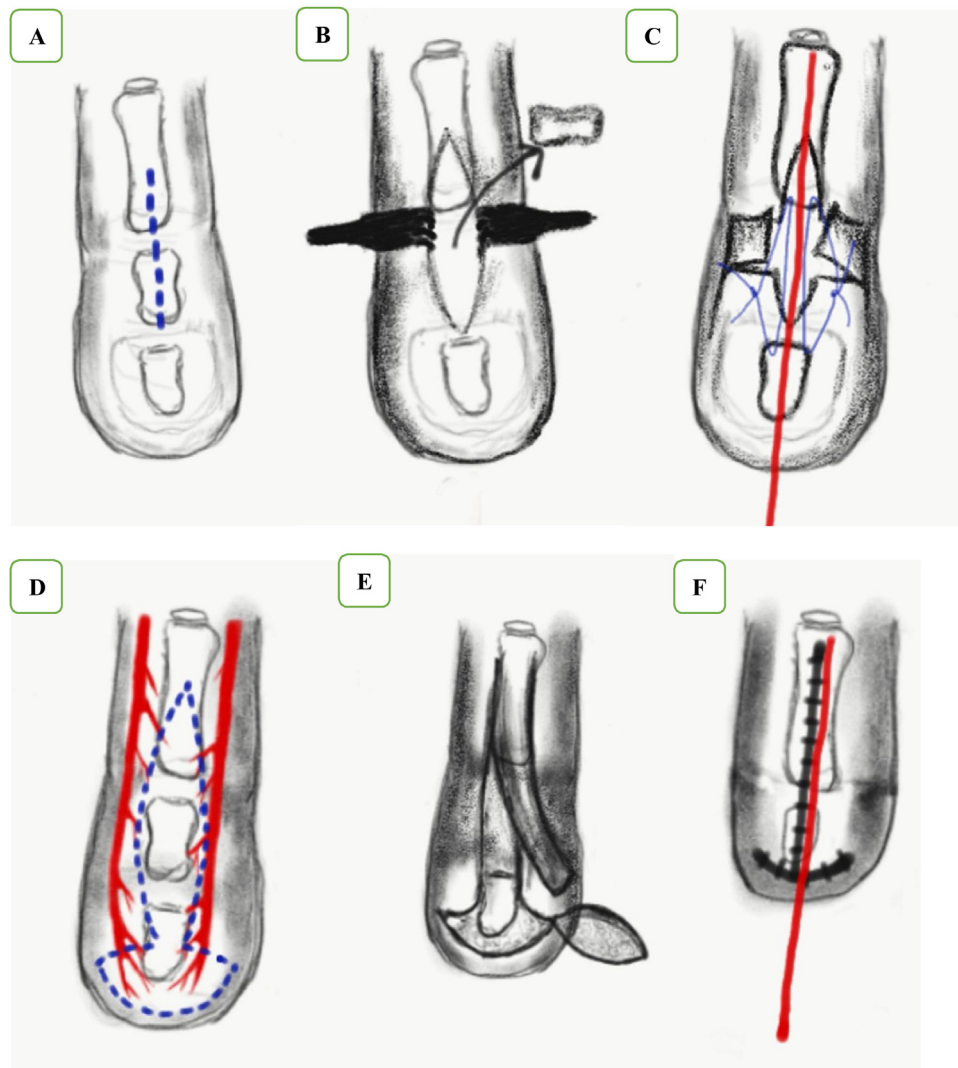


Fig. 3. Illustration of the surgical technique. A. Longitudinal incision for the medial phalanx approach. B. Medial phalangectomy. C. Joint capsule fixation, insertion of intramedullary pinning, reduction of the skin and soft tissue of the medial-distal phalanx dorsal area. D. An ellipse excision design with the proximal opening facing the proximal site. E. Removal of the excess skin and fibrofatty tissue on the plantar side. F. End result.

distal end of the second digits, with one side opening toward the proximal end, was carried out to reduce the plantar skin and fibrofatty tissue. Fibrofatty tissue reduction was performed to reduce the volume and diameter of the digits such that the appearance of the toes was more natural. In this case, preservation of the medial and lateral digital arteries was performed prior to excision of the skin and soft tissue, which will prevent flap tissue or postoperative necrosis of the toes.

The results of the histopathological examination revealed fibrolipoma and osteochondroma features, which is consistent with Syed et al.'s finding that the pathological tissue in pedal macrodactyly is dominated by the proliferation and accumulation of excess fat tissue [11]. The outcomes of macrodactyly surgery are based on several indicators, such as sensitivity, functionality, cessation of pathological growth, and esthetics. However, an easy way to evaluate the success of therapy is to assess shoe size. In this case,

after the operation, the patient was able to wear the same shoe size as the unaffected foot [12].

The surgery in this case was carried out when the patient was quite young, in consideration of functional and psychological aspects. Research conducted by Ghavami described that the psychological impact caused by macrodactyly is quite severe, especially for school-age children [12]. Future follow-up is necessary and should be on going, especially in patients with the progressive type because this type continues to grow disproportionately over time.

Until now, there has been no standard surgical techniques for treating this condition. The choice usually combines several surgical techniques that are personalized to the condition of each case. The experience, skills, and availability of the hospital's equipment are also important for successful treatment of macrodactyly. Thus, treating macrodactyly is a challenge for surgeons [13].

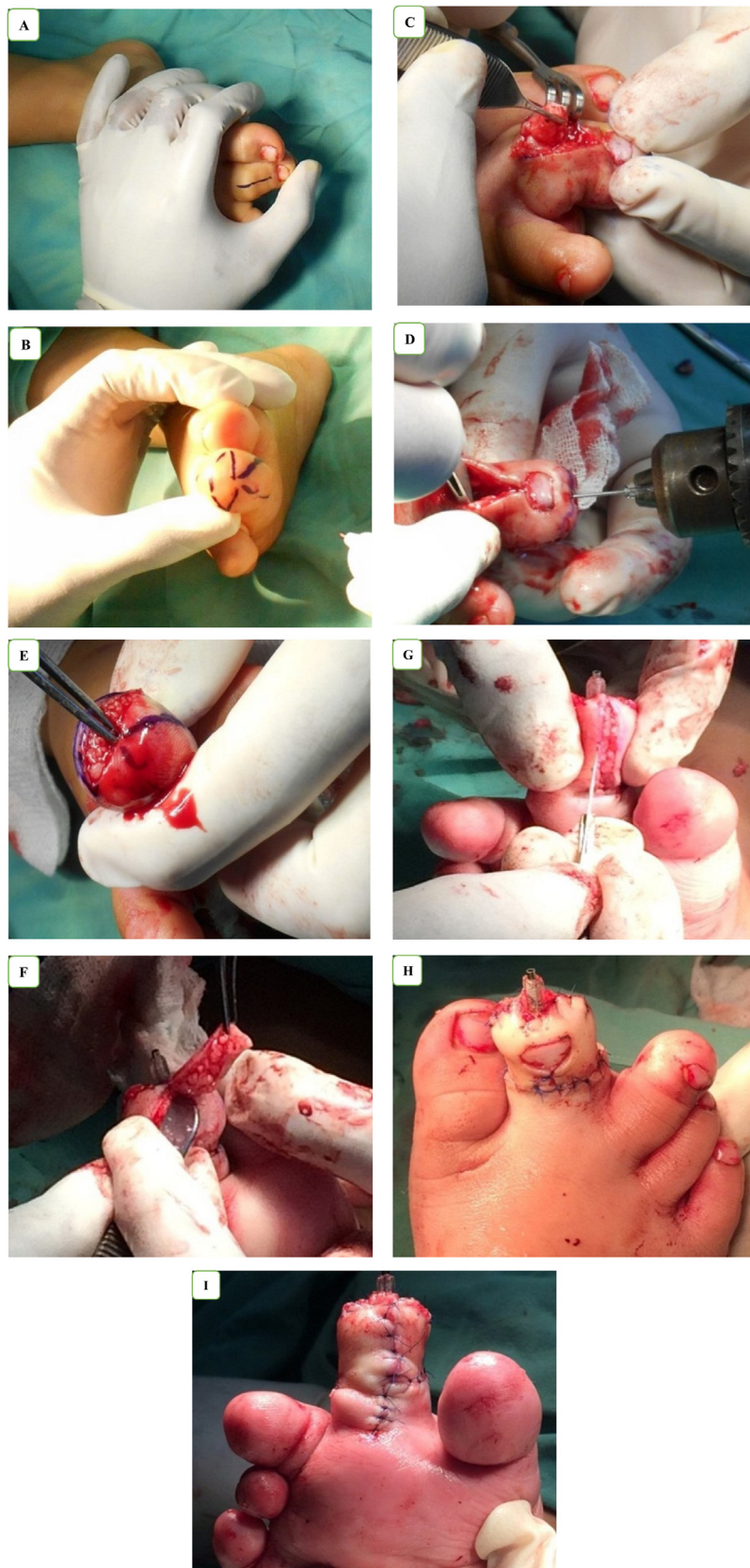


Fig. 4. Intraoperative photo. A. Dorsal longitudinal incision design. B. An elliptical incision design at the distal end of the second digit, with one side opening toward the proximal. C. Incision to the dorsal side, followed by phalangectomy. D. Joint capsule fixation and Kirschner wiring to the second digit. E. Excision on the plantar side of the second digit according to the design. F. Reductive excision of the skin and the fibrofatty tissue on the plantar side. G. Double-pedicle flap from the lateral and medial sides with preservation of the digital arteries. H. Dorsal view immediate after the surgery. I. Plantar view immediate after the surgery.

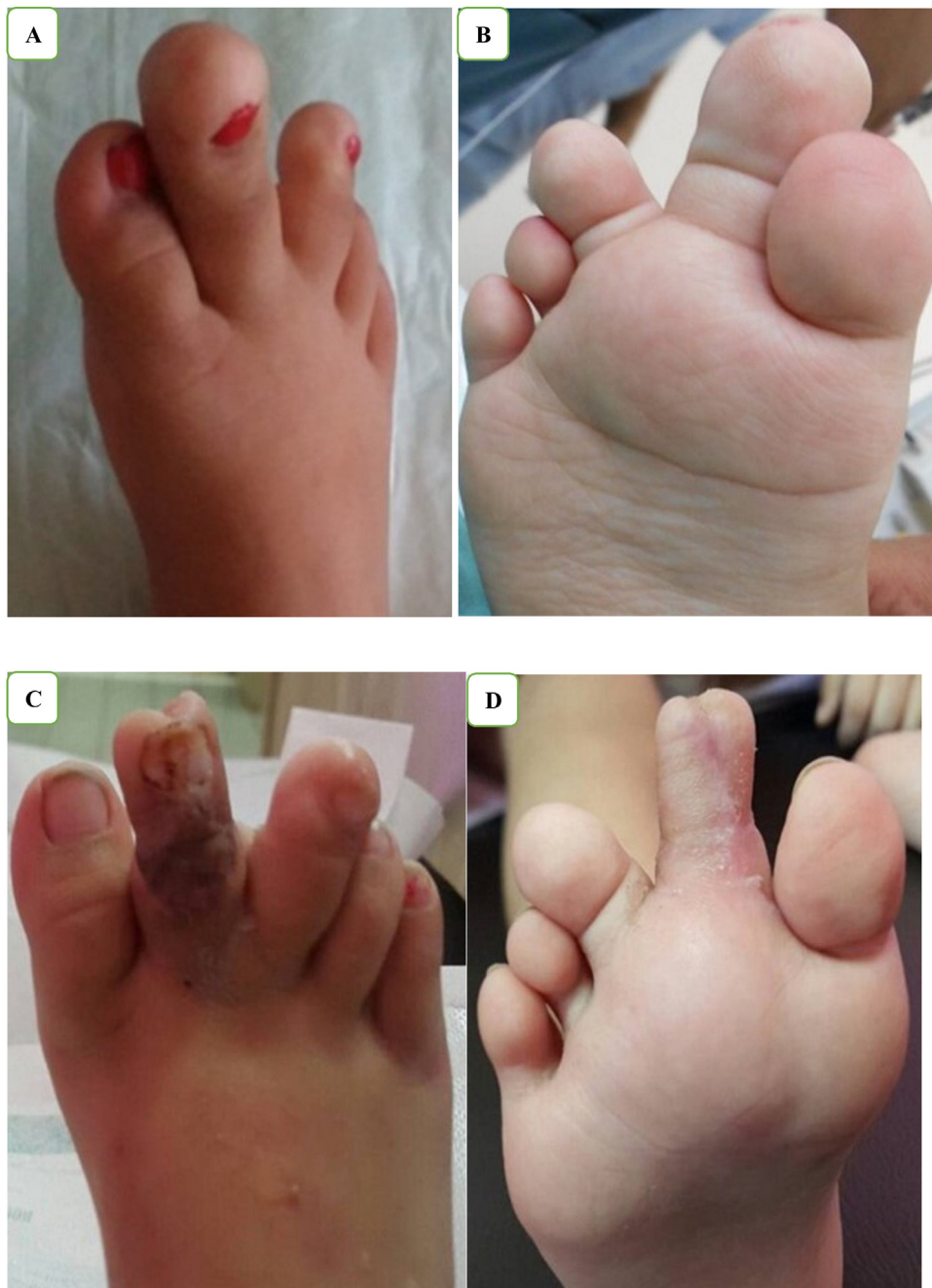

Fig. 5. A. Dorsal view of the patient's foot before the surgery. B. Plantar view of the patient's foot before the surgery. C. Dorsal view of the patient's foot two months after the second surgery. D. Plantar view of the patient's foot two months after the second surgery.

4. Conclusion

Macroductyly is a rare congenital disorder, and until now, there has been no consensus regarding its management. There are various choices of surgical techniques that can be performed. However, the best surgical option should be personalized for each patient's individual condition. In this case report, we report surgical removal of the medial phalanx of the second toe, followed by a reduction in fat tissue and preservation of the medial and lateral digital arteries. This technique yielded satisfactory results in both functionality and esthetics.

Conflicts of interest

Nothing to declare.

Funding

No funding or sponsorship was received for this study or publication of this article.

Ethical approval

The study is exempt from ethical approval in our institution.

Consent

Written informed consent was obtained from the child's parents or guardians for publication of this case report and accompanying

images. A copy of the written consent is available for review by the Editor-in-Chief of this journal on request.

Author contribution

Fonny Josh and Tomie Hermawan Soekamto: study concept, surgical therapy for this patient. **Fonny Josh, Tomie Hermawan Soekamto, and August Jacob Rieuwpassa:** Data collection, Writing-Original draft preparation. **Muhammad Faruk and Fonny Josh:** Editing, Writing. All authors read and approved the final manuscript.

Registration of research studies

Not applicable.

Guarantor

Fonny Josh.

Provenance and peer review

Not commissioned, externally peer-reviewed.

References

- [1] D. Casanova, J.-F. Chabas, B. Salazard, Macroductylies of the hand and foot, *Chir. Main* 27 (Suppl. 1) (2008) S178–S184, <http://dx.doi.org/10.1016/j.main.2008.07.021>.
- [2] A.J. Barsky, Macroductyly, *J. Bone Jt. Surg. Am.* 49 (1967) 1255–1266.
- [3] F. Cerrato, K.R. Eberlin, P. Waters, J. Upton, A. Taghinia, B.I. Labow, Presentation and treatment of macroductyly in children, *J. Hand Surg.* 38 (2013) 2112–2123, <http://dx.doi.org/10.1016/j.jhsa.2013.08.095>.
- [4] J. Kim, J.W. Park, S.W. Hong, J.Y. Jeong, H.S. Gong, G.H. Baek, Ray amputation for the treatment of foot macroductyly in children, *Bone Jt. J.* 97-B (2015) 1364–1369, <http://dx.doi.org/10.1302/0301-620X.97B10.35660>.
- [5] M.J. Hop, J.J. van der Biezen, Ray reduction of the foot in the treatment of macroductyly and review of the literature, *J. Foot Ankle Surg. Off. Publ. Am. Coll. Foot Ankle Surg.* 50 (2011) 434–438, <http://dx.doi.org/10.1053/j.jfas.2011.04.011>.
- [6] J. Wu, G. Tian, Y. Ji, J.P. Higgins, W.P.A. Lee, Clinical characteristics of 90 macroductyly cases, *J. Hand Surg.* 45 (2020) 982.e1–982.e5, <http://dx.doi.org/10.1016/j.jhsa.2020.03.002>.
- [7] M. Bulut, L. Karakurt, O. Belhan, S. Serbest, Ray amputation for the treatment of macroductyly in the foot: report of three cases, *Acta Orthop. Traumatol. Turc.* 45 (2011) 458–462, <http://dx.doi.org/10.3944/AOTT.2011.2353>.
- [8] R.A. Agha, T. Franchi, C. Sohrabi, G. Mathew, A. Kerwan, A. Thoma, A.J. Beamish, A. Noureldin, A. Rao, B. Vasudevan, B. Challacombe, B. Perakath, B. Kirshtein, B. Ekser, C.S. Pramesh, D.M. Laskin, D. Machado-Aranda, D. Miguel, D. Pagano, F.H. Millham, G. Roy, H. Kadioglu, I.J. Nixon, I. Mukhejee, J.A. McCaul, J. Chi-Yong Ngu, J. Albrecht, J.G. Rivas, K. Raveendran, L. Derbyshire, M.H. Ather, M.A. Thorat, M. Valmasoni, M. Bashashati, M. Chalkoo, N.Z. Teo, N. Raison, O.J. Muensterer, P.J. Bradley, P. Goel, P.S. Pai, R.Y. Afifi, R.D. Rosin, R. Coppola, R. Klappenbach, R. Wynn, R.L. De Wilde, S. Surani, S. Giordano, S. Massarut, S.G. Raja, S. Basu, S.A. Enam, T.G. Manning, T. Cross, V.K. Karanth, V. Kasivisvanathan, Z. Mei, The SCARE 2020 guideline: updating consensus Surgical CAse REport (SCARE) guidelines, *Int. J. Surg.* 84 (2020) 226–230, <http://dx.doi.org/10.1016/j.ijsu.2020.10.034>.
- [9] C. Sever, C. Sahin, Y. Bayram, S. Ekinci, B. Aysal, U. Berber, M. Incedayi, F. Uygur, Y. Kulahci, Adult foot macroductyly: a case report and review of the literature, *Arch. Clin. Exp. Surg.* 3 (2014) 123, <http://dx.doi.org/10.5455/aces.20120721124714>.
- [10] P.C. Cavadas, A. Thione, Treatment of hand macroductyly with resection and toe transfers, *J. Hand Surg.* 43 (2018) 388.e1–388.e6, <http://dx.doi.org/10.1016/j.jhsa.2017.08.012>.
- [11] A. Syed, R. Sherwani, Q. Azam, F. Haque, K. Akhter, Congenital macroductyly: a clinical study, *Acta Orthop. Belg.* 71 (2005) 399–404.
- [12] J. Hardwicke, M.A.A. Khan, H. Richards, R.M. Warner, R. Lester, Macroductyly – options and outcomes, *J. Hand Surg. Eur.* 38 (2012) 297–303, <http://dx.doi.org/10.1177/1753193412451232>.
- [13] M. Ezaki, T. Beckwith, S.N. Oishi, Macroductyly: decision-making and surgery timing, *J. Hand Surg. Eur.* 44 (2018) 32–42, <http://dx.doi.org/10.1177/1753193418796441>.

Open Access

This article is published Open Access at [sciencedirect.com](https://www.sciencedirect.com). It is distributed under the [IJSCR Supplemental terms and conditions](#), which permits unrestricted non commercial use, distribution, and reproduction in any medium, provided the original authors and source are credited.