

Case Report



Long-limb Roux-en-Y Reconstruction after Subtotal Gastrectomy to Treat Severe Diabetic Gastroparesis

Joong-Min Park , Jong Won Kim , Kyong-Choun Chi

Department of Surgery, Chung-Ang University College of Medicine, Seoul, Korea

OPEN ACCESS

Received: Mar 25, 2019

Revised: May 16, 2019

Accepted: Jun 22, 2019

Correspondence to

Joong-Min Park

Department of Surgery, Chung-Ang University
College of Medicine, 102 Heukseok-ro,
Dongjak-gu, Seoul 06973, Korea.
E-mail: jmpark@cau.ac.kr

Copyright © 2019. Korean Gastric Cancer
Association

This is an Open Access article distributed
under the terms of the Creative Commons
Attribution Non-Commercial License ([https://
creativecommons.org/licenses/by-nc/4.0](https://creativecommons.org/licenses/by-nc/4.0))
which permits unrestricted noncommercial
use, distribution, and reproduction in any
medium, provided the original work is properly
cited.

ORCID iDs

Joong-Min Park

<https://orcid.org/0000-0002-8582-6391>

Jong Won Kim

<https://orcid.org/0000-0002-9556-7143>

Kyong-Choun Chi

<https://orcid.org/0000-0001-8703-5377>

Author Contributions

Conceptualization: P.J.M.; Data curation:
P.J.M.; Supervision: K.J.W., C.K.C.; Validation:
K.J.W., C.K.C.; Writing - original draft: P.J.M.;
Writing - review & editing: P.J.M.

Conflict of Interest

No potential conflict of interest relevant to this
article was reported.

ABSTRACT

The role of surgical intervention in patients with diabetic gastroparesis is unclear. We report a case of a 37-year-old man with a history of recurrent episodes of vomiting and long-standing type 2 diabetes mellitus. Esophagogastroduodenoscopy did not reveal any findings of reflux esophagitis or obstructive lesions. A gastric emptying time scan showed prolonged gastric emptying half-time (344 minutes) indicating delayed gastric emptying. Laboratory tests revealed elevated fasting serum glucose and glycosylated hemoglobin (HbA1c, 12.9%) and normal fasting C-peptide and insulin levels. We performed Roux-en-Y reconstruction after subtotal gastrectomy to treat gastroparesis and improve glycemic control, and the patient showed complete resolution of gastrointestinal symptoms postoperatively. Barium swallow test and gastric emptying time scan performed at follow-up revealed regular progression of barium and normal gastric emptying. Three months postoperatively, his fasting serum glucose level was within normal limits without the administration of insulin or oral antidiabetic drugs with a reduced HbA1c level (6.9%). Long-limb Roux-en-Y reconstruction after subtotal gastrectomy may be useful to treat severe diabetic gastroparesis by improving gastric emptying and glycemic control.

Keywords: Diabetes mellitus; Gastroparesis; Gastrectomy; Vomiting

INTRODUCTION

Gastroparesis is defined as delayed or impaired gastric emptying in the absence of mechanical gastric outlet obstruction. Gastroparesis is associated with a variety of underlying diseases, and diabetes is the most common cause of this condition [1].

The role of surgical intervention in patients with diabetic gastroparesis is unclear. Resectional treatment is considered the last resort for the treatment of diabetic gastroparesis. Notably, metabolic surgery is being incorporated into the diabetes treatment algorithm.

We describe a case of a young man with a history of long-standing type 2 diabetes and severe gastroparesis that was refractory to medical therapy but was successfully treated with Roux-en-Y reconstruction after subtotal gastrectomy.

CASE REPORT

A 37-year-old man was admitted via the emergency room for evaluation of a 6-month history of recurrent episodes of vomiting and a 10-year history of type 2 diabetes mellitus. His antidiabetic regimen consisted of daily with 18 units of long-acting insulin and thrice daily with 6 units of rapid-acting insulin without an oral hypoglycemic agent.

He complained of severe nausea and recurrent episodes of vomiting and had been admitted to the Department of Gastroenterology with these symptoms, on 3 previous occasions. He underwent several tests for the evaluation of recurrent episodes of vomiting during the previous hospitalization. Esophagogastroduodenoscopy did not reveal any findings of reflux esophagitis but revealed diffuse hyperemia and edematous mucosa of the gastric body and antrum, which were compatible with chronic superficial gastritis. Endoscopy showed no obstructive lesion.

He also underwent a gastric emptying time scan, which indicated delayed gastric emptying (gastric emptying half-time of 344 minutes) (**Fig. 1A**).

At the time of his current admission, he weighed 56 kg, and body mass index (BMI) was 20.1 kg/m². Physical examination revealed no abnormalities. Laboratory investigations revealed an elevated fasting serum glucose level of 170 mg/dL and glycosylated hemoglobin (HbA1c) of 12.9%. The fasting C-peptide (1.17 ng/mL) and insulin (9.41 mU/L) levels were within normal ranges.

Additionally, we performed autonomic nerve function testing and a nerve conduction study. The results of this testing were compatible with autonomic nerve dysfunction and electrophysiological abnormalities, suggesting sensorimotor polyneuropathy involving the bilateral upper and lower extremities. Other causes of gastroparesis were excluded.

Following multidisciplinary collaboration, we scheduled Roux-en-Y reconstruction after subtotal gastrectomy to treat gastroparesis and improve glycemic control.

The patient was placed in the reverse Trendelenburg position. Transumbilical insertion of the first trocar (for the camera) was performed using an open technique. A 12-mm trocar (to provide access for the surgeon's right hand) and a 5-mm trocar (to provide access for the surgeon's left hand) were inserted on the right side. An additional 5-mm trocar was inserted under direct vision on the left side for the assistant surgeon.

The gastrocolic ligament and short gastric vessels were divided using ultrasonic shears to mobilize the greater curvature of the stomach. The infrapyloric and right gastric arteries were divided, and the duodenum was transected 1 cm distal to the pylorus using a laparoscopic linear stapler. The right gastroepiploic and left gastric arteries and the vagus nerve were preserved. Following the insertion of a 36-french bougie, we performed longitudinal subtotal gastrectomy, and the gastric antrum and greater curvature of the gastric body and the fundus were removed. The staple line was reinforced using continuous suture. We divided the jejunum 50 cm distal to the ligament of Treitz and performed Roux-en-Y antecolic gastrojejunostomy using a linear stapler. Jejunojejunostomy was created 100 cm distal to the gastrojejunostomy (**Fig. 2**). A small bowel mesenteric defect and Peterson's defect were repaired using continuous sutures.

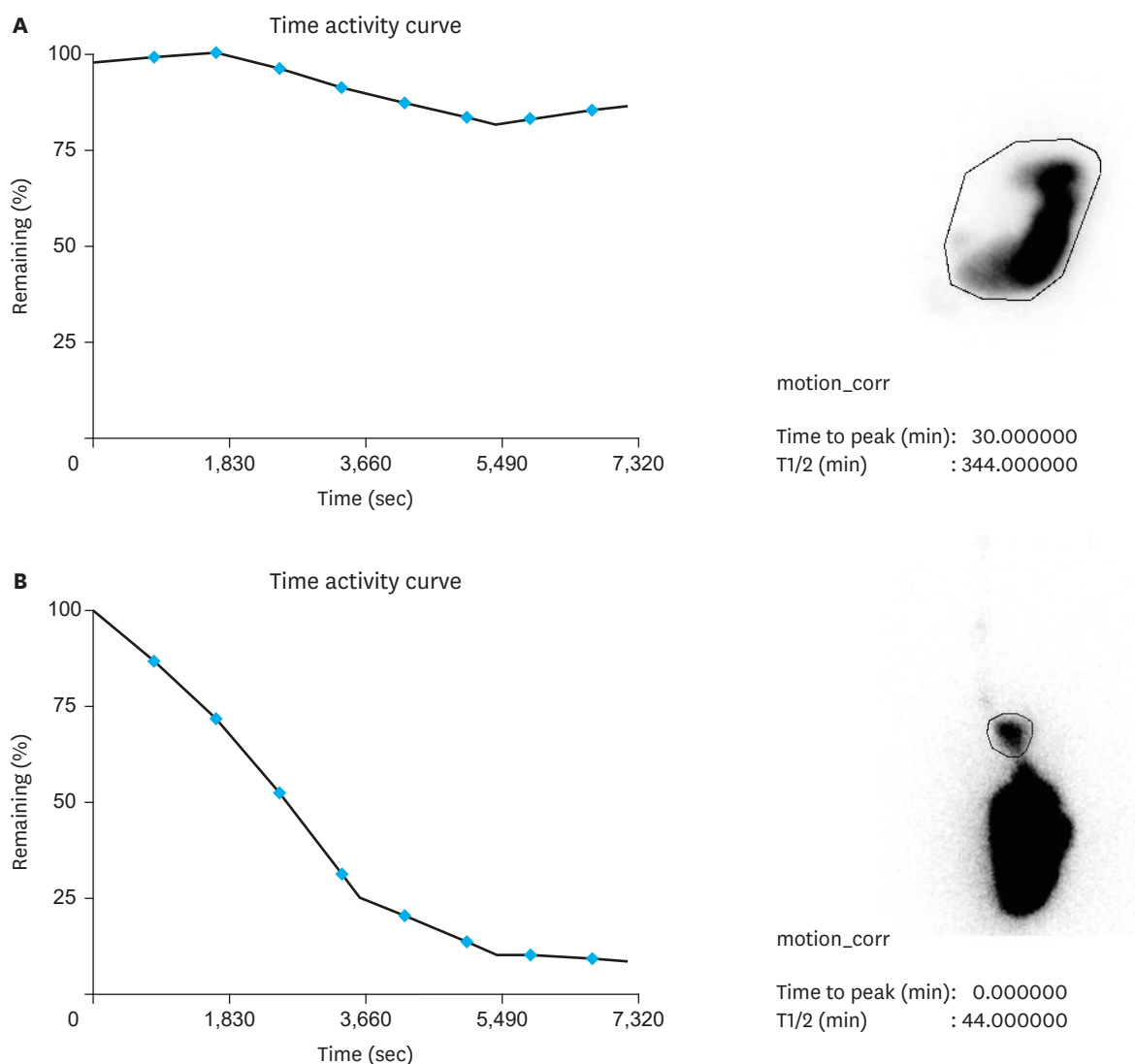


Fig. 1. Gastric emptying study in a patient with diabetic gastroparesis. (A) Preoperative gastric emptying time is significantly delayed. (B) Postoperative gastric emptying time is normal.

The patient was allowed to drink a small amount of water immediately postoperatively, and a soft diet was introduced from the 2nd postoperative day. The patient showed complete resolution of gastrointestinal symptoms, and he was discharged on the 6th postoperative day after an uneventful postoperative course. A barium swallow esophagogastrography and a gastric emptying time scan performed for follow-up evaluation of the gastrointestinal tract showed regular barium progression and normal gastric emptying (**Fig. 1B**). Insulin dosage required for glycemic control was markedly reduced to a single dose of long-acting insulin. Three months later, all antidiabetic drugs were completely discontinued, and his serum HbA1c level decreased to 6.9%, with normal serum glucose levels. Slight weight loss was observed, and his postoperative BMI was 18.6 kg/m²; however, other nutritional biochemical parameters were normal (hemoglobin 13.5 g/dL, serum albumin 4.5 g/dL, ferritin 268.5 ng/mL, and vitamin B12 963 pg/mL).




Fig. 2. Diagrammatic representation of long-limb Roux-en-Y subtotal gastrectomy with longitudinal resection of the stomach.

DISCUSSION

Gastroparesis refers to gastrointestinal motility dysfunction associated with a variety of symptoms. Patients most commonly present with nausea and vomiting, and less common symptoms include upper abdominal pain and abdominal distention. Gastroparesis associated with weight loss, necessitating nutritional support is considered a more severe form of this disorder.

The most common causes of gastroparesis, excluding idiopathic etiology, include diabetes and surgery [2]. Although the true prevalence of gastroparesis is unknown, reduced gastric motility is not rare in patients with a history of long-standing diabetes. Reportedly, gastroparesis occurs in 20%–40% of patients with type 1 diabetes mellitus and in approximately 20% of patients with type 2 diabetes [1]. Notably, foregut surgery predisposes to gastroparesis. Most cases occur in patients undergoing vagotomy; however, it may also occur in the absence of vagotomy. With regard to incidence rates of post-surgical gastroparesis, gastroparesis most commonly occurs after gastrectomy. However, it is observed even after pylorus-preserving pancreaticoduodenectomy or cholecystectomy. In Western countries, gastroparesis after laparoscopic repair of hiatal hernia and Nissen fundoplication is common [3].

Gastroparesis is defined as delayed gastric emptying in the absence of mechanical obstruction of the gastric outlet. Therefore, the diagnostic procedure in patients with symptoms suggestive of gastroparesis should necessarily include gastroscopy to exclude obstructive lesions, and a gastric emptying study must be performed to confirm abnormal gastric emptying.

The general principles for the treatment of gastroparesis include nutritional support, symptomatic management, and identification and correction of the underlying cause of gastroparesis. Conventionally, invasive surgery is avoided in patients with gastroparesis,

and patients are primarily treated with conservative therapy including dietary modification, medications to stimulate gastric motor activity, and antiemetic drugs.

The role of surgical intervention in patients with gastroparesis remains unclear. There is limited evidence to support the effect of surgery in gastroparesis treatment. Surgical procedures may be performed as supportive or definitive therapy. Although supportive surgical intervention includes intravenous or enteral access for nutritional support, surgical modalities for definitive therapy include gastric electrical stimulation, drainage procedures such as pyloroplasty, pyloromyotomy, and gastrojejunostomy, and resectional therapy.

Surgical resectional therapy is effective for gastroparesis because it involves definitive removal of the dysfunctional organ. However, this modality is primarily used in patients with post-surgical gastroparesis [4]. Resectional treatment for diabetic gastroparesis has been reported only in case reports or small retrospective reviews involving a small number of patients [5-7].

Watkins et al. [7] reported the largest study describing subtotal gastrectomy in patients with diabetic gastroparesis. The authors reported that 6 of 7 patients showed immediate resolution of vomiting with improved quality of life that persisted until 6 years postoperatively.

Notably, metabolic surgery (gastric bypass) is being increasingly incorporated into the diabetes treatment algorithm [8]. Randomized controlled trials comparing metabolic surgery and medical intervention have reported that metabolic surgery was more effective in achieving glycemic control or diabetes remission [9,10].

Therefore, surgery for patients with diabetic gastroparesis should be considered as a surgical method to improve delayed gastric emptying and to achieve remission of diabetes.

To date, the optimal procedure for resectional therapy to treat diabetic gastroparesis remains unknown. There is lack of consensus regarding the extent of stomach resection and the length of small intestinal segments that should be bypassed. We selected subtotal gastrectomy with longitudinal resection of the stomach and long-limb Roux-en-Y reconstruction based on the following factors.

- 1) The patient's weight and BMI were within the normal limits. Thus, subtotal gastrectomy was preferred over near-total gastrectomy because preservation of an adequate volume of the remnant stomach was important to maintain normal body weight.
- 2) Rapid gastric emptying was observed in patients undergoing bariatric surgery with a longitudinal sleeve gastrectomy [11]. This is the mechanism underlying the metabolic effects of sleeve gastrectomy. Unfortunately, a previously reported retrospective study that described the use of longitudinal sleeve gastrectomy for the treatment of patients with gastroparesis included a small number of patients [12]. Unlike the procedure performed in sleeve gastrectomy, the gastric antrum was resected and gastrojejunostomy was performed in our patient. Therefore, there was no effect of high intraluminal pressure provided by preserving pyloric function. However, the fundus (which constitutes the most distensible part of the stomach) was removed, resulting in stimulation of gastric emptying, as expected.
- 3) With regard to glycemic control and diabetes remission, the lengths of the biliopancreatic and alimentary limbs were the same as those used in conventional gastric bypass for bariatric and metabolic surgery.

Although significant improvement in diabetes and gastroparesis symptoms occurred postoperatively, we could not predict the long-term durability of these improvements and/or the development of any nutritional complications secondary to gastric resection. Evaluation of long-term outcomes is warranted because this technique is not a common surgical procedure.

Surgical treatment for gastroparesis includes diverse options. To date, no approach has been shown to be definitively superior over others in terms of therapeutic efficacy. A retrospective large-scale study reported similar symptomatic outcomes across various types of surgical treatment options and suggested that a tailored approach might improve gastroparesis symptoms [12].

Based on our findings of improved gastric emptying and glycemic control postoperatively, long-limb Roux-en-Y reconstruction after subtotal gastrectomy may be considered a useful treatment option that can be tailored to suit the needs of selected patients with severe gastroparesis secondary to type 2 diabetes mellitus.

This study was presented at the KINGCA week 2019 in Incheon, Korea as an oral presentation.

REFERENCES

1. Horowitz M, Wishart JM, Jones KL, Hebbard GS. Gastric emptying in diabetes: an overview. *Diabet Med* 1996;13:S16-S22.
[PUBMED](#)
2. Rabine JC, Barnett JL. Management of the patient with gastroparesis. *J Clin Gastroenterol* 2001;32:11-18.
[PUBMED](#) | [CROSSREF](#)
3. Tog C, Liu DS, Lim HK, Stiven P, Thompson SK, Watson DI, et al. Risk factors for delayed gastric emptying following laparoscopic repair of very large hiatus hernias. *BJS Open* 2017;1:75-83.
[PUBMED](#) | [CROSSREF](#)
4. McCallum RW, Polepalle SC, Schirmer B. Completion gastrectomy for refractory gastroparesis following surgery for peptic ulcer disease. Long-term follow-up with subjective and objective parameters. *Dig Dis Sci* 1991;36:1556-1561.
[PUBMED](#) | [CROSSREF](#)
5. Ejskjaer NT, Bradley JL, Buxton-Thomas MS, Edmonds ME, Howard ER, Purewal T, et al. Novel surgical treatment and gastric pathology in diabetic gastroparesis. *Diabet Med* 1999;16:488-495.
[PUBMED](#) | [CROSSREF](#)
6. Bell DS, Ovalle F. Gastroparesis cured by gastrectomy. *Diabetes Care* 1999;22:1000-1001.
[PUBMED](#) | [CROSSREF](#)
7. Watkins PJ, Buxton-Thomas MS, Howard ER. Long-term outcome after gastrectomy for intractable diabetic gastroparesis. *Diabet Med* 2003;20:58-63.
[PUBMED](#) | [CROSSREF](#)
8. Rubino F, Nathan DM, Eckel RH, Schauer PR, Alberti KG, Zimmet PZ, et al. Metabolic surgery in the treatment algorithm for type 2 diabetes: a joint statement by International Diabetes Organizations. *Diabetes Care* 2016;39:861-877.
[PUBMED](#) | [CROSSREF](#)
9. Mingrone G, Panunzi S, De Gaetano A, Guidone C, Iaiconelli A, Nanni G, et al. Bariatric-metabolic surgery versus conventional medical treatment in obese patients with type 2 diabetes: 5 year follow-up of an open-label, single-centre, randomised controlled trial. *Lancet* 2015;386:964-973.
[PUBMED](#) | [CROSSREF](#)
10. Schauer PR, Bhatt DL, Kirwan JP, Wolski K, Aminian A, Brethauer SA, et al. Bariatric surgery versus intensive medical therapy for diabetes - 5-year outcomes. *N Engl J Med* 2017;376:641-651.
[PUBMED](#) | [CROSSREF](#)

11. Pilone V, Tramontano S, Di Micco R, Monda A, Hasani A, Izzo G, et al. Gastric emptying after sleeve gastrectomy: statistical evidence of a controlled prospective study with gastric scintigraphy. *Minerva Chir* 2013;68:385-392.
[PUBMED](#)
12. Arthur LE, Slattery L, Richardson W. Tailored approach to gastroparesis significantly improves symptoms. *Surg Endosc* 2018;32:977-982.
[PUBMED](#) | [CROSSREF](#)