

Received: 2015.09.23
Accepted: 2015.11.16
Published: 2016.02.15

ISSN 1941-5923
© Am J Case Rep, 2016; 17: 89-92
DOI: 10.12659/AJCR.896070

Burkitt's Lymphoma of the Rectosigmoid and Stomach Presenting as Hematochezia

Authors' Contribution:
Study Design A
Data Collection B
Statistical Analysis C
Data Interpretation D
Manuscript Preparation E
Literature Search F
Funds Collection G

ABCDEF 1 **Marco Bustamante-Bernal**
ABC 1 **Juan Galvis**
ABC 1 **Dubier Matos**
ABC 1 **Omar Sosa**
ABC 1 **Saad H. Syed**
BD 2 **Osvaldo Padilla**
D 3 **Brian Davis**
ABCDEFG 4 **Marc J. Zuckerman**

1 Department of Internal Medicine, Paul L. Foster School of Medicine, Texas Tech University Health Science Center, El Paso, TX, U.S.A.
2 Department of Pathology, Paul L. Foster School of Medicine, Texas Tech University Health Science Center, El Paso, TX, U.S.A.
3 Department of Surgery, Paul L. Foster School of Medicine, Texas Tech University Health Science Center, El Paso, TX, U.S.A.
4 Department of Internal Medicine, Division of Gastroenterology, Paul L. Foster School of Medicine, Texas Tech University Health Science Center, El Paso, TX, U.S.A.

Corresponding Author: Marco Bustamante-Bernal, e-mail: marco.a.bustamante@ttuhsc.edu; Marc J. Zuckerman, e-mail: Marc.Zuckerman@ttuhsc.edu
Conflict of interest: None declared

Patient: Female, 51
Final Diagnosis: Burkitt's lymphoma of the rectum and stomach
Symptoms: Hematochezia
Medication: —
Clinical Procedure: EGD and colonoscopy
Specialty: Gastroenterology and Hepatology

Objective: Rare disease

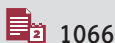Background: Burkitt's lymphoma (BL) is an uncommon cause of non-Hodgkin lymphoma in adults and accounts for only 0.1–0.5% of all malignant tumors of the colon and rectum. Very few cases of rectosigmoid and stomach BL have been reported in adults.

Case Report: A 51-year-old Hispanic woman presented with a 1-month history of hematochezia, associated with a foreign-body sensation in the rectum and 7 kg weight loss. Initial laboratory workup showed normocytic anemia and positive fecal occult blood. Computed tomography of the abdomen revealed an asymmetric appearance of the stomach and pylorus with nodularity of the mucosa and thickening of the posterior wall, and a 10.8-cm rectal mass. Esophagogastroduodenoscopy and colonoscopy were performed and biopsies of the stomach and rectum were obtained; histopathology demonstrated involvement by Burkitt's lymphoma in the gastric body nodule and rectal mass. After 4 cycles of chemotherapy, a follow-up abdominal CT demonstrated complete resolution of the mural thickening of the rectum and no intra-abdominal lymphadenopathy.

Conclusions: Our case illustrates the importance of considering BL in the extensive differential diagnosis of rectal bleeding, change in bowel habits, and other lower and upper GI symptoms, since the rapidly growing nature of this rare malignancy requires a prompt diagnosis and initiation of appropriate therapy.

MeSH Keywords: Burkitt Lymphoma • Gastrointestinal Hemorrhage • Rectal Neoplasms • Stomach Neoplasms


Full-text PDF: <http://www.amjcaserep.com/abstract/index/idArt/896070>



1066



7



18



Background

Burkitt's lymphoma (BL) is an aggressive form of non-Hodgkin's B-cell lymphoma [1]. Three clinical forms of Burkitt's lymphoma are described: endemic, sporadic, and immunodeficiency-associated. Endemic BL refers to those cases occurring in Africa, usually in children who present with involvement of multiple nodal and extranodal sites [2]. Sporadic BL has no geographic predilection and occurs worldwide; it accounts for 1% to 2% of lymphomas in the adult population [2]. Immunodeficiency-associated BL occurs mainly in patients infected with HIV, transplant recipients taking immunosuppressives, and in people with congenital immunodeficiencies [2]. Very few cases of rectal BL have been reported in adults [3–6]. We report a rare case of BL with rectosigmoid and stomach involvement presenting with hematochezia.

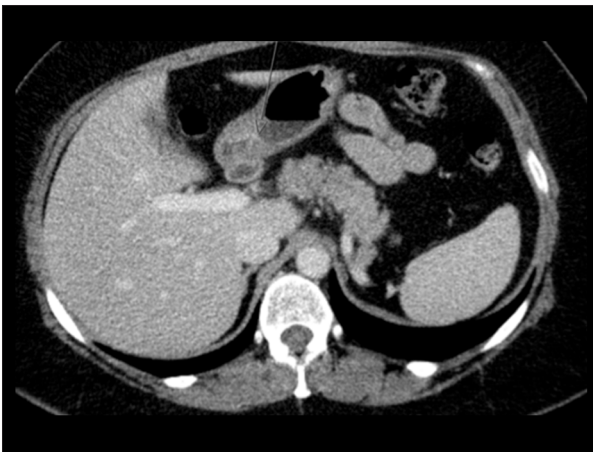


Figure 1. CT scan showing asymmetric appearance of the stomach and pylorus with nodularity of the mucosa and thickening of the posterior wall (arrow).

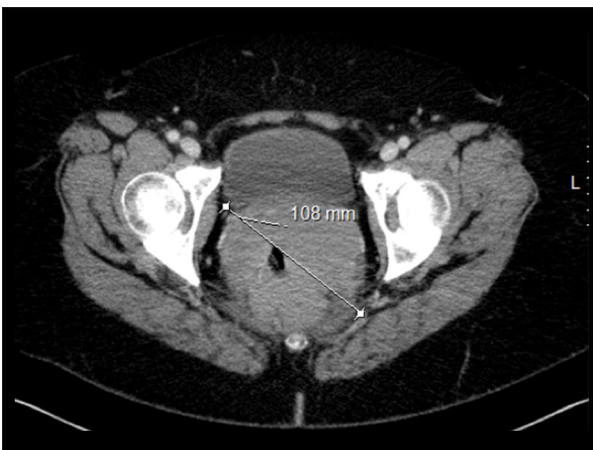


Figure 2. CT scan showing a 10.8-cm diameter circumferential mass encasing the low to high rectum to the level of the rectosigmoid junction with apparent infiltration to the anorectal junction.

Case Report

A 51-year-old Hispanic woman presented with a 1-month history of hematochezia, associated with a foreign-body sensation in the rectum and 7-kg weight loss. She was taking naproxen for intermittent lower back pain, did not smoke cigarettes or use illegal drugs, and drank alcohol occasionally. Surgical history was significant for fallopian tube ligation. Family history was negative for malignancy. Physical examination revealed a non-distended abdomen, normal bowel sounds, left lower quadrant tenderness, no masses, and no signs of peritoneal irritation. A large, irregular, hard rectal mass was palpated on digital rectal examination. Initial laboratory workup revealed a white blood count of 7460/mm³, hemoglobin 10.8 g/dl, mean corpuscular volume 93.7 fl, platelets 273 000/mm³, total bilirubin 0.9 mg/dl, alkaline phosphatase 93 U/L, AST 17 U/L, ALT 17 U/L, LDH 731 U/L, HIV ELISA-negative, and fecal occult blood test positive. Computed tomography (CT) of the abdomen revealed an asymmetric appearance of the stomach and pylorus, with nodularity of the mucosa and thickening of the posterior wall (Figure 1), and a 10.8-cm rectal mass with infiltration of adjacent pelvic organs, abdominal and pelvic lymphadenopathy, and serosal implants in the sigmoid colon (Figure 2).

Esophagogastroduodenoscopy showed diffuse moderate inflammation characterized by erosions, erythema, granularity, and shallow ulcerations in the gastric body and antrum and 1 small non-bleeding mucosal nodule on the greater curvature of stomach (Figure 3). Colonoscopy revealed 2 infiltrative, submucosal, non-circumferential, non-obstructing masses – 1 in the distal sigmoid colon at 20 cm from the anus (Figure 4), and 1 in the distal rectum at approximately 5 to 15 cm from the anus.

Histopathology demonstrated involvement by Burkitt's lymphoma in the gastric body nodule and sigmoid mass at 40 cm

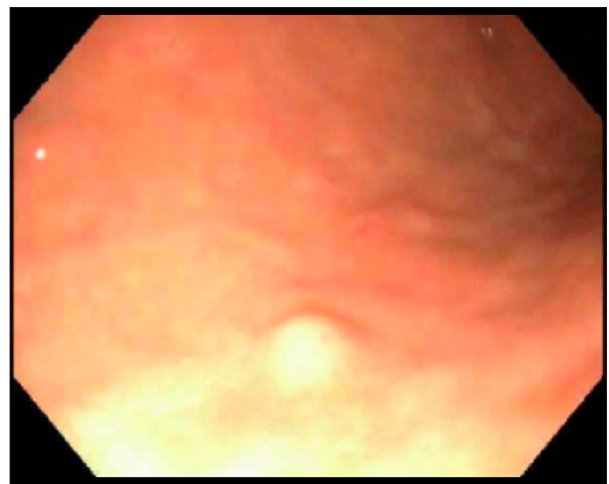


Figure 3. Endoscopic image showing a small mucosal nodule on the greater curvature of the stomach.

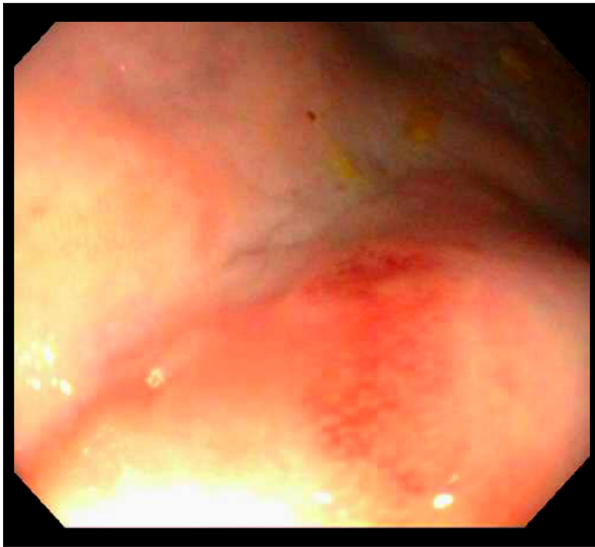

Figure 4. Endoscopic image showing an infiltrative, submucosal, non-circumferential, non-obstructing mass in the distal sigmoid colon approximately 40 cm from the anus.

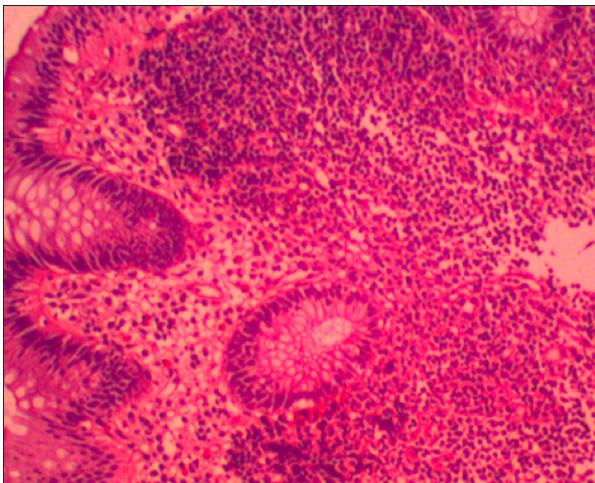


Figure 5. Biopsy of the colon shows colonic epithelium with infiltration by mononuclear cells in the lamina propria, which was proven to be Burkitt's lymphoma (hematoxylin-eosin stain, 10x magnification).

from the anus (Figures 5 and 6). Fluorescence *in situ* hybridization (FISH) study showed a MYC rearrangement by the separation of the duet probe of this oncogene region in 65% of examined cells, consistent with Burkitt's lymphoma (Figure 7). BCL-2 was negative in neoplastic B-cells; Ki-67 showed a high proliferative index with nuclear staining in approximately 100% of neoplastic B-cells. Epstein-Barr virus (EBV) serology was suggestive of past infection: EBV viral capsid antigen (VCA) IgM <0.09, EBV VCA IgG, and EBV nuclear antigen (EBNA) IgG >5.0 (reference range: <0.9 negative, 0.91–1.09 equivocal, >1.1 positive). Further investigation revealed bone marrow infiltration, demonstrated by bone marrow biopsy, and lumbar puncture

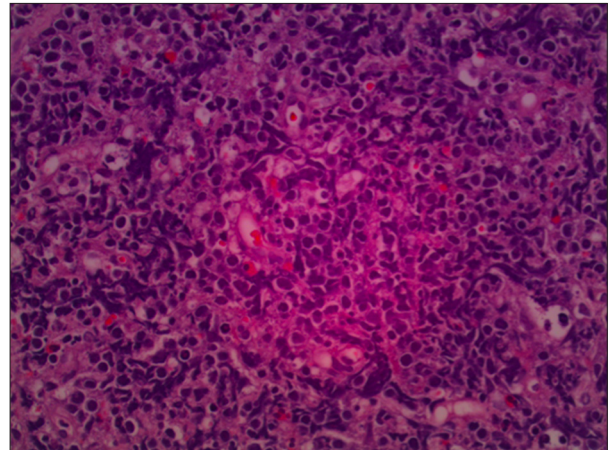


Figure 6. Higher magnification (40x) demonstrates medium-sized lymphocytes with scant cytoplasm and a diffuse chromatin pattern. Also shown are clear spaces consisting of macrophages with phagocytized apoptotic bodies, which imparts a "starry sky" appearance.

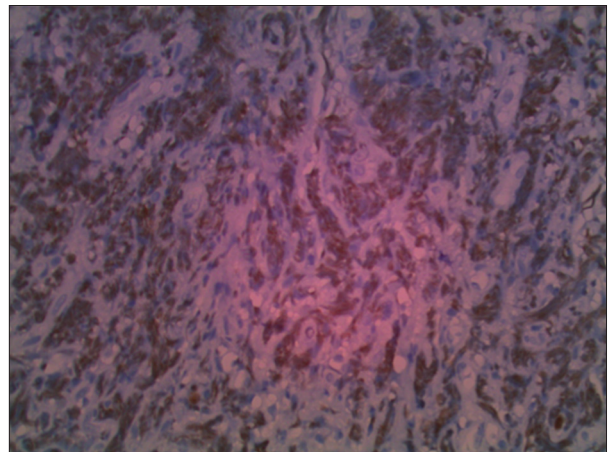


Figure 7. Immunohistochemical stain of C-myc, which has positive nuclear staining in the vast majority of the neoplastic cells. This provides immunohistochemical support for the diagnosis of Burkitt's lymphoma.

was negative for CNS involvement. Chemotherapy with doxorubicin, vincristine, and cyclophosphamide was started, and after 4 cycles a follow-up abdominal CT demonstrated complete resolution of the mural thickening of the rectum and no intra-abdominal lymphadenopathy.

Discussion

Our patient presented with hematochezia and was found to have the rare entity of BL involving the rectum and sigmoid, as well as the stomach. Based on an extensive literature search, this is the second case report of BL with simultaneous involvement of the rectosigmoid and the stomach [7].

BL accounts for 1–2% of all cases of non-Hodgkin's lymphoma (NHL). NHL of the GI tract is mostly found in the stomach (about 50–60%) and small intestine (about 30%), while the large bowel and rectum account for only 10% of all cases [9]. Primary non-Hodgkin's lymphoma (NHL) of the rectum accounts for 0.1–0.5% of all malignant rectal tumors. Of this small proportion, BL represents only 1% of the cases [8]. Therefore, primary BL of the rectum accounts for 0.001% of all rectal malignancies.

When BL presents as a primary tumor in the GI tract, the tumor most commonly arises in the ileocecal region, where an increased concentration of lymphoid tissue is present. It is rare in other parts of the colon [10].

Abdominal BL presents with abdominal pain, abdominal distention, constipation, back pain secondary to tumor infiltration of retroperitoneal lymph nodes, ascites, nausea, vomiting, melena or hematochezia [2,11,12]. These unspecific clinical manifestations lead to further radiologic and endoscopic examinations of the GI tract.

Endoscopy is important to establish the diagnosis of GI BL by taking biopsies of the affected area and to define tumor extension and infiltration. Although there are no pathognomonic lesions, several endoscopic signs have been associated with BL in the stomach (submucosal nodules [13], single or multiple tumors with or without ulceration [14], diffuse ulceration of the stomach [15], and thickening of gastric folds [16]) and colon (polypoid masses [7] and partially obstructive heterogeneous non-ulcerated masses [5]). As there is no definitive test

that establishes the diagnosis of BL, it is important to recognize that GI endoscopy is one of many tools used in combination with other imaging and histopathologic techniques to increase the diagnostic accuracy of this rare malignancy [17].

With frequent involvement of the central nervous system and bone marrow, adults were once thought to have a less favorable outcome than pediatric patients with BL. However, several studies suggest that treatment with intensive chemotherapy (with several known agents active in BL, such as cyclophosphamide, vincristine, methotrexate, doxorubicin, and cytarabine) and adequate CNS prophylaxis can be curative even in the setting of advanced stage or immunodeficiency [18]. With high-intensity, brief-duration regimens, 65% to 100% of adults achieve a complete response, with 47% to 86% of patients maintaining these remissions at least 1 year following therapy [2].

Conclusions

BL is a rare malignancy in adults that infrequently involves multiple lesions in the GI tract. We report a patient who presented with involvement of the rectum and stomach. Our case report illustrates the importance of including BL in the extensive differential diagnosis of hematochezia, change in bowel habits, and other unspecific lower and upper GI symptoms. Although BL is a rapidly growing malignancy, it has a very good prognosis if therapy is initiated in a timely manner. A multidisciplinary approach is needed because prompt diagnosis is essential to achieving better outcomes.

References:

1. Yustein J, Dang C: Biology and treatment of Burkitt's lymphoma. *Curr Opin Hematol*, 2007; 14: 375–81
2. Blum KA, Lozanski G, Byrd JC: Adult Burkitt leukemia and lymphoma. *Blood*, 2004; 104: 3009–20
3. Greif F, Burstein Y, Hammer B: Burkitt's lymphoma protruding through the anus: report of an unusual case. *Dis Colon Rectum*, 1988; 31: 629–31
4. Matkovic S, Jelic S, Manojlovic N, Milanovic N: Non-Hodgkin's lymphomas with primary localization in large bowel and rectum. *Med Sci Monit*, 2000; 6(1): 68–74
5. Palakodeti S, Hoda K, Munroe C: Perirectal Burkitt lymphoma presenting as an unusual cause of lower gastrointestinal bleeding. *Clin Gastroenterol Hepatol*, 2014; 12(4): A23–24
6. Dinh M, Matkowskyj K, Stosor V: Colorectal lymphoma in the setting of HIV: Case report and review of the literature. *AIDS Patient Care STDS*, 2009; 23(4): 227–30
7. Priebe WM: The endoscopic appearance of Burkitt's lymphoma involving the stomach and colon. *Gastrointest Endosc*, 1986; 32(5): 352–54
8. Burmestier T, Schwartz S, Horst HA et al: Molecular heterogeneity of sporadic adult Burkitt-type leukemia/lymphoma as revealed by PCR and cytogenetics: correlation with morphology, immunology and clinical features. *Leukemia*, 2005; 19: 1391–98
9. Freudenberg S, Palma P, Grobholz R et al: HIV-related and Epstein-Barr virus-associated anal Burkitt's lymphoma: Report of a case. *Dis Colon Rectum*, 2005; 48: 1656–59
10. Gence A, Sahin C, Celayir C, Yavuz H: Primary Burkitt lymphoma presenting as a solitary rectal polyp in a child. *Pediatr Surg Int*, 2008; 24: 1215–17
11. Meyer C, Wilsey M, Hale G et al: Primary Burkitt's lymphoma of the colon- An uncommon cause of acute constipation and abdominal pain. *Fetal Pediatric Pathol*, 2012; 31: 254–59
12. Ferry J: Burkitt's lymphoma: Clinicopathologic features and differential diagnosis. *Oncologist*, 2006; 11: 375–83
13. Rodrigues-Pinto E, Goncalves R, Fonseca E, Macedo G: Gastroduodenal Burkitt's lymphoma in an immunocompetent patient. *Rev Esp Enferm Dig*, 2013; 105(9): 553–54
14. Chia Chieng JH, Garret J, Ding SL, Sullivan M: Clinical presentation and endoscopic features of primary gastric Burkitt lymphoma in childhood, presenting as a protein-losing enteropathy: a case report. *Journal of Medical Case Reports*, 2009; 3: 7256
15. Ziade F, von der Weid N, Becko-Popovic M, Nydegger A: Burkitt's lymphoma – an atypical presentation. *BMC Pediatrics*, 2012; 12: 113
16. Doycheva I, Tanner S, Zhou D, Samadder J: A rare cause of gastric malignancy: Burkitt's lymphoma. *Endoscopy*, 2013; 45: E432–33
17. Claudi R, Viola P, Cotellese R, Angelucci D: Atypical primary Burkitt lymphoma of the thyroid gland: A practical approach for differential diagnosis and management. *Am J Case Rep*, 2010; 11: 169–73
18. Magrath J, Adde M, Shad A et al: Adults and children with small non-cleaved-cell lymphoma have a similar excellent outcome when treated with the same chemotherapy regimen. *J Clin Oncol*, 1996; 14: 925–34