



## Anterior To Psoas lumbar and lumbosacral combined with posterior reconstruction in Adult Spinal Deformity: A bicentric European study



Marco Teli<sup>a,b,\*</sup>, Giuseppe E. Umana<sup>c</sup>, Paolo Palmisciano<sup>c</sup>, Maggie K. Lee<sup>a</sup>, Simon R. Clark<sup>a</sup>, Christian Soda<sup>d</sup>

<sup>a</sup> Department of Neurosurgery, The Walton Centre NHS Trust, Liverpool, UK

<sup>b</sup> Department of Spinal Surgery, Rizzola Academy, Venice, Italy

<sup>c</sup> Department of Neurosurgery, Cannizzaro Hospital, Catania, Italy

<sup>d</sup> Department of Neurosurgery, Hospital Borgo Roma, Verona, Italy

### ARTICLE INFO

Handling Editor: F Kandziora

#### Keywords:

Adult spinal deformity  
Lateral lumbar interbody fusion  
Oblique lateral interbody fusion  
PROM  
Spinal surgery

### ABSTRACT

**Introduction:** Lateral lumbar fusion via the trans-psoas approach is popular in adult deformity reconstruction. To overcome its limitations (neurological damage to the plexus and lack of applicability to the lumbosacral junction), a modified anterior-to-psoas (ATP) approach has been described and used.

**Research question:** To investigate the results of ATP lumbar and lumbosacral fusion, in a cohort of adult patients treated with combined anteroposterior approaches for adult spinal deformity (ASD).

**Materials and methods:** ASD patients surgically treated at two tertiary spinal centres were followed up. Forty patients were treated with combined ATP and posterior surgery: 11 with open lumbar lateral interbody-fusions (lumbotomy LLIF) and 29 with lesser invasive oblique lateral interbody-fusions (OLIF). Preoperative demographics, aetiology, clinical characteristics, and spinopelvic parameters were comparable between the two cohorts.

**Results:** At a minimum 2-year follow-up, both cohorts showed significant improvements in patient reported outcome measures (PROMs), i.e. Visual Analogue Scale and Core Outcome Measures Index, as well as radiological parameters, with no significant differences based on the type of surgical approach. No significant differences were found in major ( $P = 0.457$ ) and minor ( $P = 0.071$ ) complications between the two cohorts.

**Discussion and conclusion:** Anterolateral lumbar interbody fusions, whether performed via a direct or oblique approach, proved to be safe and effective adjuvants to posterior surgery in patients with ASD. No significant complication differences were noted between techniques. In addition, the anterior-to-psoas approaches limited the risks of post-operative pseudoarthrosis by providing solid anterior support to lumbar and lumbosacral segments, demonstrating a positive impact on PROMs.

### 1. Introduction

Adult spinal deformity (ASD) and related symptoms represent major causes of disability in ageing patients. Surgical correction is an option when conservative measures are exhausted, but the roles of posterior-only versus combined anterior-posterior approaches remain controversial (Neuman et al., 2016). Historically, anterior approaches relied upon the ability of direct retroperitoneal techniques to correct thoracolumbar deformities (Dakwar et al., 2010). However, there are concerns on the intrinsic morbidity of open anterior reconstruction. Therefore, a trend

towards lesser invasive thoracolumbar and lumbosacral techniques has developed (Umana et al., 2020). In lumbar surgery, a pivotal role has been played by the trans-psoas approach (Matur et al., 2020). This, when applied to adult deformity patients, has inherent limitations in not being able to reach the lumbosacral junction safely, and in being linked with variable incidences of neural plexus injury, either temporary or less often permanent. To overcome these limitations, modified anterior-to-psoas (ATP) approaches have been described. ATP routes can be accomplished with a standard lumbotomy-type direct approach (namely, Lateral Lumbar Interbody Fusion - LLIF in this paper) or via a modified

**Abbreviations:** Adult Spinal Deformity, ASD; Oblique Lateral Interbody Fusion, OLIF; Anterior-to-Psoas, ATP.

\* Corresponding author. Department of Spinal Surgery, Rizzola Academy, Via Gorizia 1, 30027, San Donà di Piave, Italy.

E-mail address: [marcoteli@hotmail.com](mailto:marcoteli@hotmail.com) (M. Teli).

<https://doi.org/10.1016/j.bas.2023.101718>

Received 30 May 2022; Received in revised form 29 December 2022; Accepted 30 January 2023

Available online 3 February 2023

2772-5294/© 2023 The Authors. Published by Elsevier B.V. on behalf of EUROSPINE, the Spine Society of Europe, EANS, the European Association of Neurosurgical Societies. This is an open access article under the CC BY-NC-ND license (<http://creativecommons.org/licenses/by-nc-nd/4.0/>).

oblique lumbarotomy (namely, oblique lateral interbody fusion - OLIF), which allows a lesser invasive and extensile route from L2 to S1 (Matur et al., 2020), with sparing of the innervation of the abdominal muscles and lower chance of postoperative muscle atony.

In this bicentric study, we report our experience with ATP anterior column reconstruction of the lumbar and lumbosacral spine, combined with posterior instrumentation in patients with ASD, focusing on surgical technique, patient reported outcome measures (PROMs) and complications. We have compared clinical data of patients treated with direct LLIF with matching patients treated with OLIF.

## 2. Methods

### 2.1. Study design

In this prospective cohort study, we recruited consecutive ASD patients treated from June 2016 to June 2020 at two European tertiary referral spine centres. All enrolled patients received anterior column support with antero-posterior LLIF or OLIF surgery, combined with long posterior instrumentation at either centre, where the senior authors and their team practiced. Indications for LLIF prevailed at the beginning of the surgical experience as dedicated retractors and implants for OLIF became available at a later stage. Once these were an established asset (from the year 2017 onwards) indications for OLIF prevailed in patients whose reconstruction was intended to span the lumbosacral junction. Patients were included if they were diagnosed with adult idiopathic deformities (AID) or de-novo deformities (DND) and experienced disabling symptoms resistant to  $\geq 2$  years of conservative management or previous spinal surgery. Patients were excluded if they had underlying malignancy or severe systemic illness, with a resulting American Society of Anaesthesiology (ASA) score higher than II. Patients who underwent prior retroperitoneal surgery or presented with proven osteopenia or osteoporosis on a recent lumbar spine DEXA scan were not excluded. This study was approved by the ethics research committee of each centre and was devised following the Strengthening the Reporting of Observational Studies in Epidemiology (STROBE) guidelines (Von Elm et al., 2007) (Appendix). Informed consent was obtained from all patients and all procedures were performed in accordance with the Helsinki Declaration of 1975.

### 2.2. Outcome measures

Patients were followed-up for  $\geq 2$ -years after surgery, prospectively collecting the following data: demographics, body-mass-index (BMI), aetiology, vertebral levels, spinopelvic parameters, surgical protocols, estimated blood loss (EBL), length of hospital-stay, post-operative complications, post-treatment PROMs. Spinopelvic parameters were measured by Consultants and Fellow trainees on full-spine standing X-Rays and/or EOS scans pre-operatively, at 3-months, 1-year and minimum 2-year follow-ups, including: coronal Cobb angle (CA), lumbar lordosis measured from the inflection point to the upper endplate of S1 (LL), pelvic incidence (PI), pelvic tilt (PT), sacral slope (SS), sagittal vertical axis (SVA), thoracic kyphosis from the upper to the lower thoracic inflection point (TK), and Roussouly's morphotypes (Roussouly et al., 2005). PROMs included visual analogue scale (VAS) scores for back and leg pain, and core outcome measures index (COMI) scores assessed by independent, non-clinical hospital staff preoperatively, at 3-months, 1-year, and minimum 2-year follow-ups (Mannion et al., 2009a, 2009b). The minimal clinically important difference (MCID) of COMI score variations between preoperative and follow-up measurements was set at 2.2 (Mannion et al., 2009a). Patients' satisfaction rates were also assessed at 2-year follow-ups as per standard protocol with the Spine Tango registry assessment tool (Mannion et al., 2009a, 2009b). Minor complications included: proximal junctional kyphosis (PJK) not requiring reintervention, superficial wound infection, transient ileus, transient radiculopathy, and urinary tract infection. Major complications

included: venous thromboembolism, deep wound infection requiring surgical debridement, intraoperative blood loss in excess of 2000 ml, mechanical implant failure, proximal junctional failure (PJF) requiring reintervention, and sepsis.

### 2.3. Surgical cohorts

Patients were divided into 1) cohort "L" including patients undergoing a LLIF approach from T11 to L5 and 2) cohort "O" including patients undergoing OLIF at any level from L2 to S1. Both cohorts shared identical screening criteria, operating-room settings, intraoperative cell salvage and neuromonitoring, and posterior instrumentation, and differed in anterior instrumentation only at L5-S1 (rectangular Peek cages from L1 to L5 and trapezoidal titanium cages in L5-S1). Levels to be anteriorly instrumented were identified on coronal and sagittal curves at full-spine standing X-Rays and/or EOS scans, and degree of flexibility (i.e., presence of disc vacuum) demonstrated on pre-operative CT and/or full-spine supine MRI scans (Fig. 1). Anterior surgery was never planned at levels with proven bony ankylosis on CT scans. The Rossouly's morphotype was assessed before surgery based on spinopelvic parameters, and every attempt was made to reproduce the original morphotype in the anterior and posterior reconstruction.

After administration of i.v. antibiotic prophylaxis (second generation cephalosporins) and tranexamic acid (1g), the lumbar spine was approached from the convexity (right or left) side with either a curvilinear flank incision (cohort L) or oblique abdominal incision (cohort O) (Fig. 2) centred over the middle of the curvature described by the levels to be instrumented. At a difference with trans-psoas approaches, the surgical table was not broken to avoid undue stretching of the lumbar plexus (Fig. 3). In cohort L, an orthogonal ( $90^\circ$ ) direction of the approach made some posterior retraction of the psoas major necessary to gain access to the disc space and to introduce an interbody cage. In cohort O, the same approach was aimed obliquely at  $45^\circ$  at the virtual space between psoas major and the vessels, with a minor amount of psoas retraction made necessary to expose the disc and insert a cage with an orthogonal manoeuvre. Of note, in cohort O, whenever indicated by pathology and made possible by the anatomy of the vessels, the lumbosacral junction was approached and instrumented with an adequately lordotic titanium cage. The two types of cages differed in material and size. Peek cages spanned the entire apophyseal ring from side to side and were positioned as anterior as possible in the anterior column to facilitate the restoration of segmental lordosis (Figs. 1, 4 and 5). Titanium cages were specifically developed and positioned to span 75% of the apophyseal ring and avoid violating the contralateral foramen to the side of insertion (Figs. 1 and 4). They too were inserted as anteriorly as possible for the same reason as above. In both cohorts, the anterior longitudinal ligament could be identified and sectioned under direct vision when felt necessary, to improve coronal and sagittal segmental correction. The design of the cages was such, that no locking screw was ever utilised: despite this, no instances of mobilisation or change of position were noted even in the two patients who had staged surgeries (one per cohort). Demineralised bone marrow was used as interbody graft in all cases.

In no instances an approach surgeon was needed, as ligation of the segmental vertebral as well as tributary (iliolumbar) veins was doable under direct vision and proper illumination by a surgical headlamp. Spinal cord neuromonitoring is not strictly necessary in ATP approaches where the lumbar plexus is always protected by the bulk of the psoas major. Nevertheless, it was used in all our cases and set up before the start of the anterior reconstruction for convenience and used to monitor spinal cord and roots' function during the posterior part of the reconstruction too.

Once done with ATP surgery, the patient was kept under general anaesthesia and positioned prone on a radiolucent spinal frame. Bilateral pedicle screw instrumentation done with the aid of real time navigation and intraoperative 3D imaging. Monoaxial large size screws (7.5 mm) could thus be applied to the apexes of lumbar curves as well as sacrum

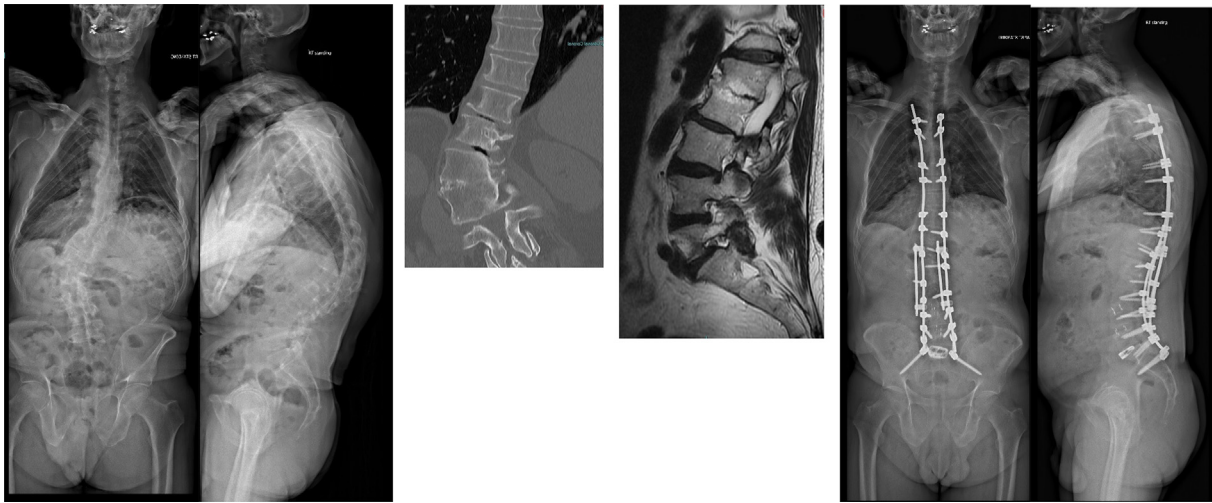


Fig. 1. Preoperative and follow up imaging, L3 to S1 OLIF case with combined asymmetric L2 PSO and posterior long thoraco-pelvic instrumentation.

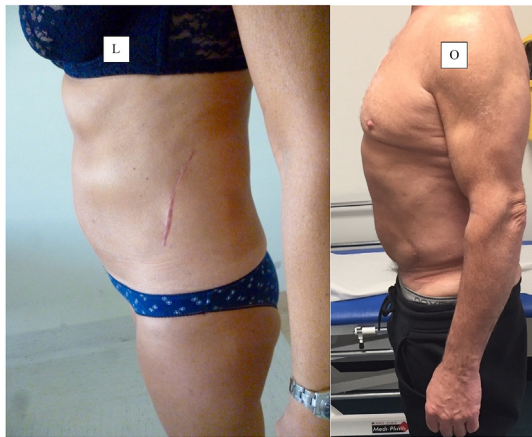


Fig. 2. Lumbotomy - LLIF (L) vs OLIF (O) abdominal scars after 3 level surgeries.

and ilium (in this case, 8.5 mm diameter screws were positioned with a S2-alar-iliac trajectory), with segmental polyaxial screws left to the upper

instrumented as well as concave pedicles. In all instances, 5.5 Cobalt Chrome rods were cut, bent, and applied to match the shape of the desired correction. Smith Petersen osteotomies were done at levels where cages had been inserted anteriorly. Pedicle subtraction osteotomies, often asymmetric, were reserved to ankylosed or previously fused segments. Spinal stenosis was treated intraoperatively with direct decompression if due to facet joint overgrowth and/or calcified ligamenta flava, or with indirect decompression on levels affected by foraminal or soft posterior stenosis. Posterior autologous bone grafting was augmented by 20 ml of demineralised bone matrix in all cases.

2.4. Statistical analysis

A SPSS V.25 software (IBM Corp, Armonk, NY) was used for all analyses, and a bilateral P-value <0.05 was considered significant. Continuous variables were presented as median and ranges, while categorical variables as frequencies and percentage. Chi-square contingency analyses and t-test group comparisons were performed to test differences among study groups in categorical and continuous variables, respectively.

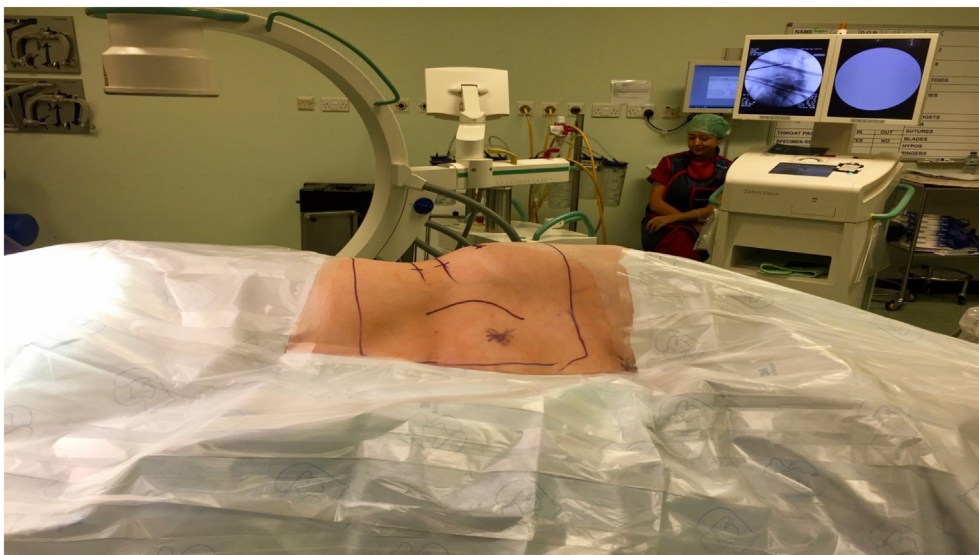


Fig. 3. Intraoperative position for ATP approaches.



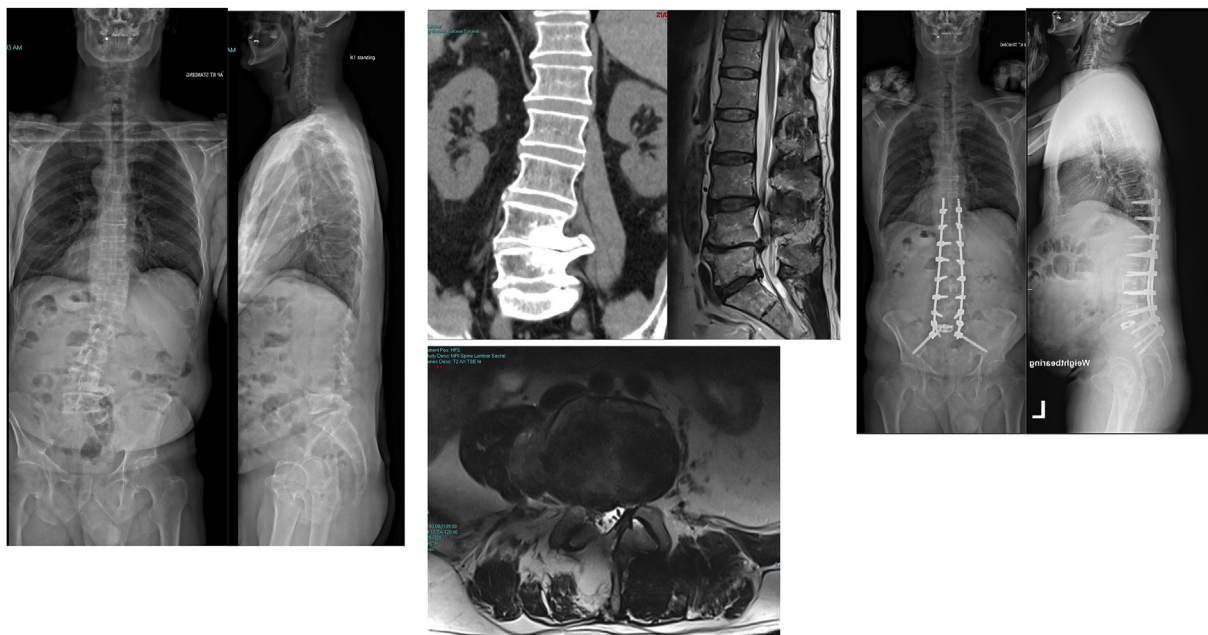


Fig. 4. Preoperative and follow up imaging, L3 to S1 OLIF case in a Patient with isolated, congenital absence of the left psoas major, with combined short thoracopelvic instrumentation.

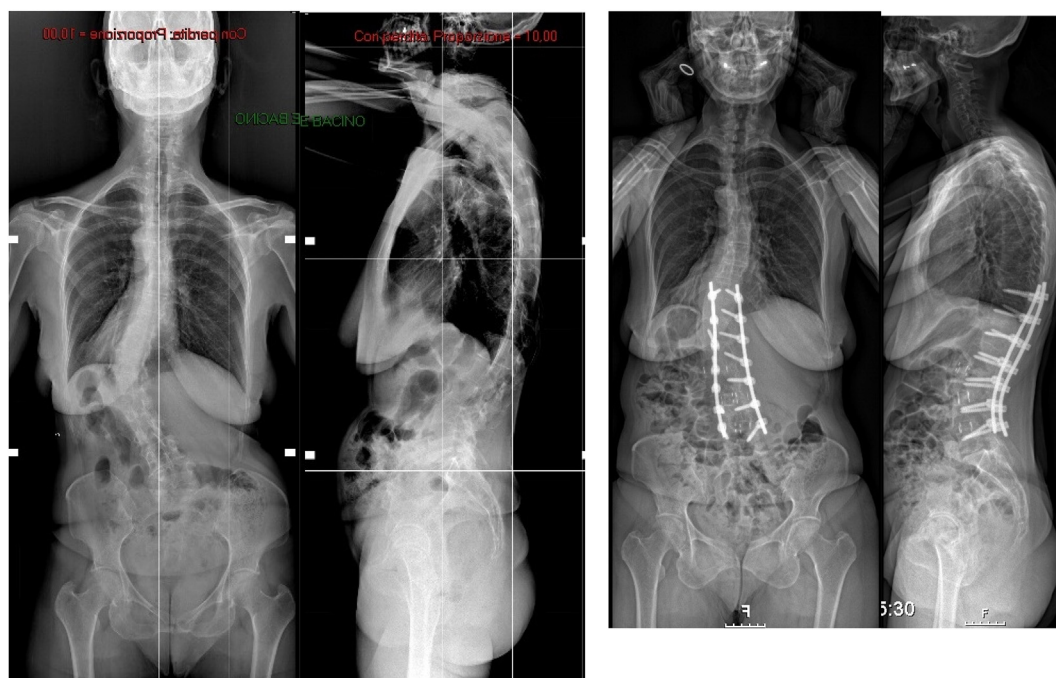

Fig. 5. Preoperative and follow up imaging, L2 to L5 LLIF case with combined posterior short thoracolumbar instrumentation.

### 3. Results

#### 3.1. Study population and baseline clinical characteristics

A total of 40 patients were enrolled: 29 in cohort “O” (OLIF) and 11 in cohort “L” (LLIF). Demographics and clinical features were comparable between the two cohorts, with a median age of 63 years (range, 45–76), a female prevalence (72.5%), and a median BMI of 28 (range, 22–34) (Table 1). No significant differences in baseline spinopelvic parameters were noted between the two groups. Roussouly’s morphotypes were equally distributed with type 3 being the most common preoperative

sagittal profile (17 Patients overall, 42.5%, Table 1).

#### 3.2. Characteristics of surgical approaches

All patients bar two underwent same-day combined anterior-posterior surgeries. In two, one per each cohort, surgeries were staged for purely organisational issues. The most frequently treated anterior levels were L2 to L5 (62.5%), and posterior levels were T10 to Pelvis (35%) (Table 2). 18 patients had posterior fusion to the pelvis, while only 1 patient had posterior fusion from L1 to S1 without pelvic fixation. Rates of concurrent L5-S1 transforaminal lateral interbody fusion (TLIF) were

**Table 1**  
Summary and comparison of baseline characteristics in ATP cohorts.

Characteristics	OLIF technique	LLIF technique	P-value
<b>Cohort size (no.)</b>	29	11	
<b>Demographics</b>			
Median age (range) (years)	65 (54–76)	62 (45–71)	0.171 <sup>a</sup>
Female, no. (%)	19 (65.5%)	10 (90.9%)	0.108 <sup>^</sup>
BMI, median (range)	28 (22–34)	27 (22–32)	0.386 <sup>a</sup>
<b>Aetiology</b>	No. (%)	No. (%)	0.189 <sup>^</sup>
Adult idiopathic deformity	7 (24.1%)	5 (45.5%)	
De novo deformity	22 (75.9%)	6 (54.5%)	
<b>Baseline Comorbidities</b>	No. (%)	No. (%)	0.067 <sup>^</sup>
Depression	6 (20.7%)	2 (18.2%)	
Hypertension	13 (44.8%)	1 (9.1%)	
Hypothyroidism	3 (10.3%)	2 (18.2%)	
Obesity	2 (6.9%)	3 (27.3%)	
Type II Diabetes	2 (6.9%)	2 (18.2%)	
	No. (%)	No. (%)	
<b>Scoliosis, vertebral levels</b>			
			0.974 <sup>^</sup>
<b>L2-S1</b>	11 (37.9%)	4 (36.4%)	
<b>L2-L5</b>	4 (13.8%)	2 (18.2%)	
<b>L1-L5</b>	3 (10.3%)	1 (9.1%)	
<b>L3-S1</b>	3 (10.3%)	1 (9.1%)	
<b>T12-S1</b>	2 (6.9%)	0 (0%)	
<b>L1-L4</b>	2 (6.9%)	1 (9.1%)	
<b>T11-L5</b>	1 (3.4%)	0 (0%)	
<b>T11-S1</b>	1 (3.4%)	1 (9.1%)	
<b>L1-L3</b>	1 (3.4%)	0 (0%)	
<b>L2-L4</b>	1 (3.4%)	1 (9.1%)	
<b>Spondylolisthesis, vertebral levels</b>			
			0.357 <sup>^</sup>
<b>L4-L5</b>	7 (24.1%)	5 (45.5%)	
<b>L3-L4</b>	3 (10.3%)	0 (0%)	
<b>L5-S1</b>	1 (3.4%)	1 (9.1%)	
<b>Not present</b>	18 (62.1%)	5 (45.5%)	
<b>Stenosis, vertebral levels</b>			
			0.954 <sup>^</sup>
<b>L3-L5</b>	7 (24.1%)	2 (18.2%)	
<b>L2-L5</b>	6 (20.7%)	3 (27.3%)	
<b>L2-S1</b>	3 (10.3%)	1 (9.1%)	
<b>L3-S1</b>	3 (10.3%)	1 (9.1%)	
<b>L1-L4</b>	2 (6.9%)	0 (0%)	
<b>L1-S1</b>	1 (3.4%)	0 (0%)	
<b>L3-L4</b>	1 (3.4%)	1 (9.1%)	
<b>Not present</b>	6 (20.7%)	3 (27.3%)	
<b>Rossouly's sagittal morphotype</b>			
			0.822 <sup>^</sup>
<b>1</b>	4 (13.8%)	1 (9.1%)	
<b>2</b>	7 (24.1%)	3 (27.3%)	
<b>3</b>	12 (41.4%)	5 (45.5%)	
<b>4</b>	6 (20.7%)	2 (18.2%)	
<b>Baseline sagittal balance and spinopelvic parameters</b>			
Coronal Cobb angle, median (range)	31° (2°–70°)	45° (2°–65°)	0.217 <sup>a</sup>
Lumbar lordosis, median (range)	33° (12°–49°)	30° (12°–49°)	0.661 <sup>a</sup>
Pelvic incidence, median (range)	55° (26°–72°)	56° (26°–66°)	0.876 <sup>a</sup>
Pelvic incidence-lumbar lordosis mismatch, median (range)	22° (–8°–53°)	29° (–8°–50°)	0.717 <sup>a</sup>
Pelvic tilt, median (range)	30° (3°–52°)	29° (20°–38°)	0.968 <sup>a</sup>
Sacral slope, median (range)	26° (4°–43°)	25° (4°–43°)	0.941 <sup>a</sup>
Sagittal vertical axis (mm), median (range)	41 (–12–77)	16 (–12–61)	0.341 <sup>a</sup>
Thoracic kyphosis, median (range)	34° (21°–50°)	36° (21°–50°)	0.594 <sup>a</sup>
Roussouly type of sagittal alignment, median (range)	3 (1–4)	3 (1–4)	0.447 <sup>a</sup>
ISSLS expected lumbar lordosis [(PI + TK)/2 + 10°], median (range)	53° (40°–67°)	55° (45°–64°)	0.501 <sup>a</sup>
Schwab expected lumbar lordosis [PI+9°], median (range)	64° (35°–81°)	65° (35°–75°)	0.876 <sup>a</sup>

Abbreviations: **ISSLS**, the International Society for the Study of the Lumbar Spine; **LLIF**, lateral lumbar interbody fusion; **OLIF**, oblique lateral interbody fusion.

<sup>a</sup> Two-tailed *t*-test; <sup>^</sup>Chi-square test. P < 0.05 set for statistical significance. **Bold** for significant differences.

**Table 2**  
Summary and comparison of treatment protocols between cohorts.

Characteristics	OLIF technique	LLIF technique	P-value
<b>Cohort size (no.)</b>	29	11	
<b>Treatment Characteristics</b>			
	No. (%)	No. (%)	
<b>Anterior levels operated per session</b>			
T11-L5	0 (0%)	1 (9.1%)	0.165 <sup>^</sup>
L1-L4	0 (0%)	1 (9.1%)	
L1-L5	0 (0%)	1 (9.1%)	
L2-L4	2 (6.9%)	1 (9.1%)	
L2-L5	16 (55.2%)	5 (45.4%)	
L2-S1	8 (27.6%)	0 (0%)	
L3-L5	3 (10.3%)	2 (18.2%)	
<b>Posterior levels operated per session</b>			
T10-Pelvis	9 (31.0%)	3 (27.3%)	0.300 <sup>^</sup>
T10-L5	5 (17.2%)	3 (27.3%)	
L2-Pelvis	4 (13.8%)	0 (0%)	
T11-L5	3 (10.3%)	3 (27.3%)	
T11-Pelvis	3 (10.3%)	0 (0%)	
L2-L5	2 (6.9%)	0 (0%)	
T3-Pelvis	1 (3.4%)	0 (0%)	
T9-Pelvis	1 (3.4%)	0 (0%)	
L1-S1	1 (3.4%)	0 (0%)	
T4-L5	0 (0%)	1 (9.1%)	
T4-Pelvis	0 (0%)	1 (9.1%)	
Concurrent TLIF at L5-S1 level	4 (13.8%)	6 (54.5%)	0.008 <sup>^</sup>
Asymmetrical pedicle subtraction osteotomy	3 (10.3%)	1 (9.1%)	0.906 <sup>^</sup>
Laminectomy	12 (41.4%)	2 (18.2%)	0.170 <sup>^</sup>
Revision in patients undergoing laminectomy	4/12 (33.3%)	1/2 (50%)	
Estimated blood loss (ml), median (range)	1200 (282–4500)	1200 (750–1850)	0.527 <sup>a</sup>
Length of hospital stay (days), median (range)	14 (6–90)	6 (4–15)	0.013 <sup>a</sup>

Abbreviations: **LLIF**, lateral lumbar interbody fusion; **OLIF**, oblique lateral interbody fusion; **TLIF**, transforaminal lumbar interbody fusion.

<sup>a</sup> Two-tailed *t*-test; <sup>^</sup>Chi-square test. P < 0.05 set for statistical significance. **Bold** for significant differences.

significantly higher in cohort “L” (P = 0.008). The median EBL was comparable between the two cohorts (P = 0.527), while the median length of hospital-stay was significantly higher in cohort “O” (P = 0.013). No significant differences were found comparing OLIF vs LLIF based on aetiology for both estimated blood loss (P = 0.073 in AID; P = 0.053 in DND) and hospital-stay (P = 0.136 in AID; P = 0.400 in DND).

**3.3. Treatment outcomes**

We found no differences in 2-year post-treatment PROMs scores between the two cohorts. By contrast, significant differences were found between all pre-operative and 2-years post-operative PROMs scores for each cohort (Table 3). VAS back and leg pain scores were significantly lower at 2-years follow-up, with median changes of –5/–5 in cohort “O” and –5/–4 in cohort “L”. Median COMI changes were –5.5 in cohort “O” and –6.5 in cohort “L”, and MCIDs of ≥2.2 points were achieved in 86.2% and 100% patients respectively. At 2-years follow-up, most patients reported to be “very satisfied” (44.8%; 72.7%) or “satisfied” (34.5%; 27.3%) respectively in cohorts “O” and “L”.

We recorded no statistical differences in 2-year post-operative spinopelvic parameters between the two cohorts either (Table 3). In both, significant differences were found for all spinopelvic parameters between pre-operative and 2-years post-operative data (Table 3). We also found a

**Table 3**  
Summary and comparison of post-treatment outcomes between cohorts.

Characteristics	OLIF technique	LLIF technique	P-value
Cohort size (no.)	29	11	
Post-treatment radiological outcomes at 2-years follow-up	Median (range)	Median (range)	
Coronal Cobb angle	8° (0°–23°)	12° (0°–19°)	0.502 <sup>a</sup>
Lumbar lordosis	45° (24°–64°)	45° (24°–64°)	0.610 <sup>a</sup>
Pelvic tilt	19° (10°–30°)	17° (10°–29°)	0.585 <sup>a</sup>
Sacral slope	36° (–3°–62°)	40° (–3°–51°)	0.691 <sup>a</sup>
Sagittal vertical axis (mm)	12.5 (0–43)	15 (0–43)	0.768 <sup>a</sup>
Roussouly type of sagittal alignment, median (range)	3 (2–4)	3 (2–4)	0.616 <sup>a</sup>
Roussouly's sagittal morphotype			
1	4 (13.8%)	1 (9.1%)	0.756 <sup>^</sup>
2	8 (27.6%)	4 (36.4%)	
3	13 (44.8%)	4 (36.4%)	
4	4 (13.8%)	2 (18.2%)	
Post-treatment clinical outcomes			
VAS score, back pain			
Preoperative, median (range)	8 (3–10)	9 (7–10)	0.353 <sup>a</sup>
Change at 2-year follow-up, median (range)	–5 (–9 – +3)	–5 (–8–0)	0.502 <sup>a</sup>
VAS score, legs pain			
Preoperative, median (range)	8 (2–10)	5 (2–10)	0.237 <sup>a</sup>
Change at 2-year follow-up, median (range)	–5 (–10––1)	–4 (–10––2)	0.905 <sup>a</sup>
COMI score			
Preoperative, median (range)	9 (7–10)	9 (7–10)	0.853 <sup>a</sup>
Change at 2-year follow-up, median (range)	–5.5 (–9.3––7)	–6.5 (–8––4.2)	0.394 <sup>a</sup>
Reduction of ≥2.2 points at 2-year follow-up, no. (%)	26 (89.7%)	11 (100%)	0.267 <sup>^</sup>
Patient satisfaction rates at 2-years follow-up			0.373 <sup>^</sup>
Very satisfied, no. (%)	13 (44.8%)	8 (72.7%)	
Satisfied, no. (%)	12 (41.4%)	3 (27.3%)	
Somewhat dissatisfied, no. (%)	1 (3.4%)	0 (0%)	
Dissatisfied, no. (%)	3 (10.3%)	0 (0%)	

Abbreviations: **COMI**, core outcome measures index; **LLIF**, lateral lumbar interbody fusion; **OLIF**, oblique lateral interbody fusion; **VAS**, visual assessment scale.

<sup>a</sup> Two-tailed *t*-test; <sup>^</sup>Chi-square test. *P* < 0.05 set for statistical significance. **Bold** for significant differences.

reduction in post-operative median CA (–25°; –30°), PT (–8°; –11°), and SVA (–20 mm; –12 mm) and an increase in post-operative median LL (+15°; +19°), SS (+7°; +11°), and TK (+10°; +9°) in cohorts “O” and “L”, respectively. At 2-year follow-up, 33 out of 40 (82.5%) patients had spinopelvic parameters reflecting their predicted Roussouly morphotype with type 3 still being the most prevalent, which made it possible to avoid upper thoracic fusions except in hyperkyphotic (morphotype 4) or rigid kyphotic patients. The remaining 7 (17.5%) Patients had type 3 and 4 profiles that were flattened into type 2 and 3 respectively (Table 3).

**3.4. Complications**

A total of 29 patients (72.5%) developed complications, but no statistical differences were found between the two cohorts (Table 4). No significant differences in complications were found comparing OLIF vs LLIF based on aetiology (*P* = 0.793 in AID; *P* = 0.944 in DND) either. Nevertheless, once complications were stratified as mechanical (pseudoarthrosis, PJK) or approach related (infections, iatrogenic neurological injuries, acute vascular events) it was apparent that mechanical complications overwhelmingly affected patients affected by DND compared to AID (9 Vs 2, *P* = 0.043) (Table 4). Major complications were reported in 18 patients (45%). In cohort “O”, 5 patients (17.2%) had extensive EBL (>2000 ml) while 3 (10.3%) had deep posterior wound infections treated

**Table 4**  
Summary and comparison of complications between cohorts.

Characteristics	OLIF Technique	LLIF technique	P-value
Cohort size (no.)	29	11	
Post-operative complications	No. (%)	No. (%)	
Minor	7 (24.1%)	6 (54.5%)	0.071 <sup>^</sup>
Transient radiculopathy	4 (13.8%)	0 (0%)	
Urinary tract infection	4 (13.8%)	0 (0%)	
Proximal junction kyphosis not requiring re-intervention	3 (10.3%)	0 (0%)	
Superficial wound infection	3 (10.3%)	0 (0%)	
Transient ileus + bowel distention	3 (10.3%)	0 (0%)	
Persistent not-debilitating radiculopathy	0 (0%)	5 (45.4%)	
Persistent not-debilitating leg paresthesia	0 (0%)	1 (9.1%)	
Major	14 (48.3%)	4 (36.4%)	0.457 <sup>^</sup>
Extensive blood loss (>2000 ml) + blood transfusion	5 (17.2%)	0 (0%)	
Proximal junction failure requiring re-intervention (M <sup>o</sup> )	4 (13.8%)	0 (0%)	
Deep wound infection requiring surgical debridement	3 (10.3%)	0 (0%)	
Sepsis	2 (6.9%)	0 (0%)	
Ruptured rod requiring re-intervention (M <sup>o</sup> )	1 (3.4%)	2 (18.2%)	
Stroke + venous embolism	1 (3.4%)	0 (0%)	
Pseudoarthrosis requiring re-intervention (M <sup>o</sup> )	1 (3.4%)	2 (18.2%)	
Screw loosening requiring re-intervention (M <sup>o</sup> )	0 (0%)	1 (9.1%)	
Persistent radiculopathy requiring re-intervention	0 (0%)	1 (9.1%)	
No complications	8 (27.6%)	3 (27.3%)	
M <sup>o</sup> = mechanical complications	6 (20.7%)	5 (45.4%)	0.892 <sup>^</sup>

Abbreviations: **COMI**, core outcome measures index; **FU**, follow-up; **VAS**, visual assessment scale.

<sup>a</sup>Two-tailed *t*-test. *P* < 0.05 set for statistical significance. **Bold** for significant differences.

with surgical debridement, intravenous antibiotics, and vacuum assisted closure. In cohort “L”, 2 patients (18.2%) and 1 patient (9.1%) suffered respectively from broken rods and screw loosening that required re-intervention. PJKs requiring surgical treatment (4 in cohort “O”), and pseudoarthrosis with rod breakages (2 in cohort “L”) were also reported. In cohort “O”, 1 patient (3.4%) with PJK sustained an incomplete thoracic spinal cord injury with motor ataxia, and 1 (3.4%) had a nearly fatal early postoperative brain thromboembolism due to a previously undiagnosed interatrial septal defect. Minor complications were reported in 13 patients (32.5%). In cohort “O”, 3 cases (10.3%) of asymptomatic PJKs were observed, not requiring re-intervention at the latest follow-up: all of them had their profile inappropriately turned into a type 2 (flattened kyphosis and lordosis compared to their preoperative status) from their original type 3. In cohort “L”, 5 patients (45.4%) had exacerbation of pre-existing lumbar radiculopathy requiring prolonged pain treatment, and 1 patient (9.1%) had persistent non-debilitating leg paresthesia. In cohort “O”, 3 patients (10.3%) had superficial posterior wound infection treated with oral antibiotics, 4 (13.8%) urinary tract infection managed with oral antibiotics and 2 (6.9%) transient ileus requiring restriction of oral intake and parenteral nutrition. In cohort “L”, 1 patient (3.4%) suffered an abdominal wall pseudo-herniation (this Patient declined surgical reconstruction). No cases of abdominal wound infections were recorded.

**4. Discussion**

In this study, ATP approaches combined with long posterior instrumentation were correlated with clinical improvement and patient's satisfaction in the treatment of ASD. In our cohorts, rates of MCID were at



the upper margin of the distribution reported in the literature for both combined trans-psoas and posterior-only techniques, and patterns of minor complications settled at the lower end of the spectrum (Barone et al., 2017; Zhang et al., 2019). Of particular interest, our rate of post-surgical pseudoarthrosis (5%) is lower than that reported in the literature for patients treated with posterior-only techniques (Dettori, 2021), and is comparable with that reported for patients treated with trans-psoas approaches and posterior fusion (Lee et al., 2020). These findings may advocate for the use of ATP surgery to provide stable and prolonged fusion even in elderly and fragile ASD patients.

One of the main benefits of ATP techniques is the ability to avoid the violation of the psoas major muscle and to preserve the adjacent lumbar plexus, thus preventing the onset of lower limb motor deficits (Saigal et al., 2016). Indeed, no case of iliopsoas or quadriceps weakness, either transitory or permanent, were reported in either cohort. ATP approaches also allowed for direct visualisation and section of the anterior longitudinal ligament to release the kyphotic and/or scoliotic segment while ensuring safe avoidance of the major abdominal vessels (Miscusi et al., 2020). Perhaps for this reason, no significant intraoperative vascular accident occurred in our study. However, 17.2% of our patients in cohort "O" experienced extensive blood loss (>2000 ml) requiring blood transfusion, while patients in cohort "L" showed reduced blood loss not requiring any transfusion. A possible explanation may derive from the fact that 75.6% of patients in cohort "O" had *de novo* deformity, which is frequently characterised by older age-related degenerative alterations of spinal and paraspinal structures. This, on the other hand, may well be a confounding factor when analysing results.

Nowadays, there is a trend towards single-positioning anterior surgery for ASD surgery (Shriver et al., 2015). From a technical point of view, we noted that OLIF allowed extensive access to the lumbar and lumbosacral spine without the need for patient re-positioning for a separate L5/S1 fusion, as documented by the lower rate of concurrent L5-S1 TLIF in our cohort "O" (13.8%) compared to cohort "L" (72.7%).

We strongly support the feasibility of combining ATP approaches and posterior surgeries in same-day operations. Adequate surgical planning and resources may be required, namely experienced surgical teams and advanced equipment, like cell-saving machines and intraoperative neurophysiology. Same-day surgeries are well tolerated in ASD patients and proved to be beneficial in terms of operating room planning.

We found that ATP techniques may favour the restoration of both coronal and sagittal profiles of a deformed lumbar spine, aiding in achieving the planned spinopelvic parameters with posterior osteotomies and instrumentation. Anteriorly positioned, large-sized cages manage to correct spinal deformities based on patients' profiles while avoiding middle column-type osteotomies, thus limiting the risk of potentially serious side effects (Dobbs et al., 2006; Lau et al., 2020).

Throughout the whole study, we used the value of the sagittal profile's restoration, calculated on PI, PT, SS, and inflection point values, to select the most appropriate surgical correction strategy (Demirkiran et al., 2016). Our protocol proved to be valuable in limiting the occurrence of mechanical complications, leading to lower rates of such complications as compared to similar studies (Bari et al., 2020). From our experience, we support the theory that the goal of ASD surgery is to restore the LL not in terms of calculated formulas, but in relation to the spinal inflection points (i.e., sagittal morphotype) (Bortz et al., 2020; Pizonas et al., 2020). For this reason, we believe that ATP surgery combined with posterior approaches represents an extremely valuable tool tailored on patient's anatomy, especially with regards to the satisfactory 2-year PROMs scores achieved in both cohorts.

Nevertheless, in this study we report a 72.5% rate of complications, major in 45% and minor in 32.5% of cases. A 72.5% overall complication would be construed as high despite there are examples in the literature where this figure is approached or surpassed when identical PROMs are utilised within the Spine Tango platform (Simon et al., 2018). This could be explained by the prospective nature of our data collection, by the absence of dropouts, by the inclusion of a EBL >2000 ml as major

complication, and by the fact that as tertiary referral hospitals we treated cases that were severe at baseline as shown by the average COMI pre-operative scores.

Despite no statistical difference was found between cohorts, a definite trend towards an increased incidence of major complication was noted in cohort "O" (48.3% vs 36.4%). Once stratified by aetiology, it was apparent that major complications mainly affected patients with DND. By contrast, a greater incidence of minor complications was noted in cohort "L" (54.5% vs 24.1% in cohort "O"), mainly characterised by worsening or persistence of radiculopathy in 45.4% of patients. We again emphasise that the proportion of *de novo* cases was higher in group "O", although this difference was not statistically significant ( $p = 0.189$ ). The groups were also comparable in terms of other confounders, such as age and gender. However, we further analysed the association between the aetiology of the spinal deformity (AID and DND) and the presence/absence of postoperative complications (both major and minor) and found a weak overall correlation ( $r = 0.41$ ). However as represented above, mechanical complications were far more prevalent in patients affected by DND.

In consideration of the bicentric setting of the present investigation, the external validity offered by the corresponding literature makes our findings generalisable to surgeons specialising in ASD correction worldwide. Hence, ATP approaches proved to be effective and safe in adjusting posterior correction of ASD, each with its own surgical nuances.

#### 4.1. Limitations

Limitations of this study include its limited size, the subjective measurements of radiological spinopelvic parameters, and the non-homogeneous distribution of patients between the two cohorts, which may have reduced the statistical power of our analyses. A larger sample size could potentially have increased the statistical power and decreased the type II error rate. Further studies on the subject, with larger sample sizes are clearly necessary to increase knowledge on ATP surgery and decrease potential drawbacks of it when applied to ASD reconstruction surgery.

## 5. Conclusion

ATP approaches are effective, versatile, and safe lesser invasive techniques for ASD correction, as they seem to cause negligible risk to vascular and neural structures located in the retroperitoneal space. OLIF allows an extensive approach to the lumbar spine from L2 to S1 for complete anterior column reconstruction, while LLIF may be more suitable in fragile elderly patients with *de novo* deformities, due to the observed reduced rates of intraoperative blood loss and surgical times.

#### Funding

No funds, grants, or other support was received.

#### Availability of data and material

All authors confirm the appropriateness of all dataset and software used for supporting the conclusion.

#### Code availability

Not applicable.

#### Authors' contributions

All authors contributed to the study conception and design. Material preparation, data collection and analysis were performed by MT, GEU, PP, LS, MKL and SRC. The first draft of the manuscript was written by MT and all authors commented on previous versions of the manuscript. All

authors read and approved the final manuscript.

### Ethics approval

Analysis of data was approved by departmental research committee in 2018 and 2020.

### Consent to participate

Obtained from all enrolled patients.

### Consent for publication

Obtained from all enrolled patients.

### Declaration of competing interest

Simon Clark and Marco Teli declare signed affiliations to Medtronic UK for educational purposes. The other authors have no relevant financial or non-financial interests to disclose.

### References

- Bari, T.J., Hansen, L.V., Gehrchen, M., 2020. Surgical correction of Adult Spinal Deformity in accordance to the Roussouly classification: effect on postoperative mechanical complications. *Spine Deform* 8, 1027–1037. <https://doi.org/10.1007/s43390-020-00112-6>.
- Barone, G., Scaramuzza, L., Zagra, A., et al., 2017. Adult spinal deformity: effectiveness of interbody lordotic cages to restore disc angle and spino-pelvic parameters through completely mini-invasive trans-psoas and hybrid approach. *Eur. Spine J.* 26, 457–463. <https://doi.org/10.1007/s00586-017-5136-1>.
- Bortz, C., Passias, P., Pierce, K., et al., 2020. Radiographic benefit of incorporating the inflection between the cervical and thoracic curves in fusion constructs for surgical cervical deformity patients. *J. Craniovertebral Junction Spine* 11, 131. [https://doi.org/10.4103/jcvjs.JCVJS\\_57\\_20](https://doi.org/10.4103/jcvjs.JCVJS_57_20).
- Dakwar, E., Cardona, R.F., Smith, D.A., Uribe, J.S., 2010. Early outcomes and safety of the minimally invasive, lateral retroperitoneal transpsoas approach for adult degenerative scoliosis. *Neurosurg. Focus* 28, 1–7. <https://doi.org/10.3171/2010.1.FOCUS09282>.
- Demirkiran, G., Theologis, A.A., Pekmezci, M., et al., 2016. Adult spinal deformity correction with multi-level anterior column releases. *Clin. Spine Surg. A Spine Publ.* 29, 141–149. <https://doi.org/10.1097/BSD.0000000000000377>.
- Dettori, J.R., 2021. Spine treatment appraisal report (STAR): interbody fusion does not fully protect against rod failure in long posterior spinal fusion for adult spinal deformity. *Global Spine J.* 11, 124–125. <https://doi.org/10.1177/2192568220972721>.
- Dobbs, M.B., Lenke, L.G., Kim, Y.J., et al., 2006. Anterior/posterior spinal instrumentation versus posterior instrumentation alone for the treatment of adolescent idiopathic scoliotic curves more than 90. *Spine* 31, 2386–2391. <https://doi.org/10.1097/01.brs.0000238965.81013.c5>.
- Lau, D., Haddad, A.F., Deviren, V., Ames, C.P., 2020. Asymmetrical pedicle subtraction osteotomy for correction of concurrent sagittal-coronal imbalance in adult spinal deformity: a comparative analysis. *J. Neurosurg. Spine* 33, 822–829. <https://doi.org/10.3171/2020.5.SPINE20445>.
- Lee, K.Y., Lee, J.-H., Kang, K.-C., et al., 2020. Minimally invasive multilevel lateral lumbar interbody fusion with posterior column osteotomy compared with pedicle subtraction osteotomy for adult spinal deformity. *Spine J.* 20, 925–933. <https://doi.org/10.1016/j.spinee.2019.12.001>.
- Mannion, A.F., Porchet, F., Kleinstück, F.S., et al., 2009a. The quality of spine surgery from the patient's perspective: Part 2. Minimal clinically important difference for improvement and deterioration as measured with the Core Outcome Measures Index. *Eur. Spine J.* 18, 374–379. <https://doi.org/10.1007/s00586-009-0931-y>.
- Mannion, A.F., Porchet, F., Kleinstück, F.S., et al., 2009b. The quality of spine surgery from the patient's perspective. Part 1: the Core Outcome Measures Index in clinical practice. *Eur. Spine J.* 18, 367–373. <https://doi.org/10.1007/s00586-009-0942-8>.
- Matur, A.V., Mejia-Munne, J.C., Plummer, Z.J., et al., 2020. The history of anterior and lateral approaches to the lumbar spine. *World Neurosurg.* 144, 213–221. <https://doi.org/10.1016/j.wneu.2020.09.083>.
- Miscusi, M., Trungu, S., Ricciardi, L., et al., 2020. The anterior-to-psoas approach for interbody fusion at the L5–S1 segment: clinical and radiological outcomes. *Neurosurg. Focus* 49, E14. <https://doi.org/10.3171/2020.6.FOCUS20335>.
- Neuman, B.J., Baldus, C., Zebala, L.P., et al., 2016. Patient factors that influence decision making: randomization versus observational nonoperative versus observational operative treatment for adult symptomatic lumbar scoliosis. *Spine* 41, E349–E358. <https://doi.org/10.1097/BRS.0000000000001222>.
- Pizones, J., Perez-Grueso, F.J.S., Moreno-Manzanaro, L., et al., 2020. Ideal sagittal profile restoration and ideal lumbar apex positioning play an important role in postoperative mechanical complications after a lumbar PSO. *Spine Deform* 8, 491–498. <https://doi.org/10.1007/s43390-019-00005-3>.
- Roussouly, P., Gollogly, S., Berthonnaud, E., Dimnet, J., 2005. Classification of the normal variation in the sagittal alignment of the human lumbar spine and pelvis in the standing position. *Spine* 30, 346–353. <https://doi.org/10.1097/01.brs.0000152379.54463.65>.
- Saigal, R., Mundis, G.M., Eastlack, R., et al., 2016. Anterior Column Realignment (ACR) in adult sagittal deformity correction. *Spine* 1. <https://doi.org/10.1097/BRS.0000000000001483>.
- Shriver, M.F., Zeer, V., Alentado, V.J., et al., 2015. Lumbar spine surgery positioning complications: a systematic review. *Neurosurg. Focus* 39, E16. <https://doi.org/10.3171/2015.7.FOCUS15268>.
- Simon, M., Halm, H., Quante, M., 2018. Perioperative complications after surgical treatment in degenerative adult de novo scoliosis. *BMC Musculoskel. Disord.* 19, 10–21. <https://doi.org/10.1186/s12891-017-1925-2>.
- Umana, G.E., Scalia, G., Perrone, C., et al., 2020. Safety and efficacy of navigated trocarless pedicle screw placement: technical note. *Interdiscip. Neurosurg. Adv. Tech. Case Manag.* 21. <https://doi.org/10.1016/j.inat.2020.100771>.
- Von Elm, E., Altman, D.G., Egger, M., et al., 2007. The strengthening the reporting of observational studies in Epidemiology (STROBE) statement: guidelines for reporting observational studies. *Ann. Intern. Med.* 147, 573. <https://doi.org/10.7326/0003-4819-147-8-200710160-00010>.
- Zhang, Y., Hai, Y., Tao, L., et al., 2019. Posterior multiple-level asymmetrical ponte osteotomies for rigid adult idiopathic scoliosis. *World Neurosurg.* 127, e467–e473. <https://doi.org/10.1016/j.wneu.2019.03.173>.