



OPEN ACCESS

Diagnosis and management of temporomandibular joint dysfunction before surgery: a case report

Ken Tateno, Tsutomu Mieda, Katsushi Doi

Department of Anesthesiology,
Saitama Medical University
Hospital, Iruma-gun, Japan

Correspondence to

Dr Ken Tateno;
tateno_k@saitama-med.ac.jp

Accepted 7 September 2021

SUMMARY

We present a case of colorectal cancer with temporomandibular joint dysfunction and discuss the management of the case. Type IIIb temporomandibular disorder involves anterior dislocation of the articular disk, trismus and difficult intubation. A 68-year-old woman was scheduled for colectomy. The day before surgery, the patient had temporomandibular pain. On examination, the mouth opening was 13 mm. We diagnosed type IIIb temporomandibular disorder. A simple splint was fabricated with gauze and she bit it. The mouth opening was 55 mm on the day of surgery. The pain disappeared, and intubation was uneventful. Temporomandibular disorders are generally treated by dentists. It is beneficial for general hospitals without a dentistry department to employ a dental anaesthesiologist to assist in potentially difficult intubations in patients with temporomandibular disorders.

BACKGROUND

Safe airway management is very important in general anaesthesia because tracheal intubation is required in many surgical cases. Indeed, it is important to evaluate the condition of the oral cavity prior to intubation.

Sufficient mouth opening is required for safe tracheal intubation. Type IIIb temporomandibular disorders may cause trismus, making intubation difficult. As deaths due to trismus after induction of anaesthesia have been already reported, we should develop strategies to manage difficult intubation cases.¹ Especially, it is safer to perform general anaesthesia after improving trismus.

Colorectal cancer is a slow-growing cancer, but the prognosis worsens if initial treatment is delayed.² It has been reported that it takes approximately 4 months on average for temporomandibular disorders to be completely cured.³ It is not realistic to prioritise the treatment of temporomandibular disorders to ensure safe intubation in patients with colon cancer who develop such disorders.

A patient requiring orotracheal intubation needs improvement of a trismus before undergoing surgical procedures to do it safely. The disorder can be managed with simple treatment methods implemented by dental anaesthesiologists in general hospitals without dentistry departments.

CASE PRESENTATION

A 68-year-old woman was diagnosed with sigmoid colon cancer, and laparoscopic colectomy was planned for the next day. The day before surgery, she had left temporomandibular joint pain and difficulty in opening her mouth fully. The opening excursion was 13 mm. We confirmed the mouth

opening and closing position using radiography (Schuller's method) (figure 1). Bone ankyloses were not observed and there was no clicking. When palpated, there was no pain or inflammation around the temporomandibular joint.

Tooth movement and tooth loss were observed because of a periodontal disease, and the occlusal diameter further deviated. The periodontal disease and the deviated occlusal diameter were thought to have caused anterior dislocation of the articular disk. We hypothesised that an overload was subsequently being applied to one of the temporomandibular joints.

We diagnosed the patient with type IIIb temporomandibular disorder. Therefore, a simple splint was created to manage this disorder. As there were no materials for producing a splint in our hospital, gauze was used as a simple splint to raise the bite (figure 2). The patient was instructed to use the splint at all times, except when eating and drinking.

The mouth opening was 55 mm on the day of surgery. The pain disappeared and intubation was not problematic.

DIFFERENTIAL DIAGNOSIS

The disorders that could cause sudden trismus are the following: pseudogout, gout, tetanus, mandibular fracture and temporomandibular disorder type IIIb. The patient had no history of pseudogout or gout, no limb spasms, and there was no inflammation around the temporomandibular joint. There were no signs of face traumas, and the fracture could not be confirmed on radiographic findings. The patient had previously been aware of a click when opening the mouth. It was diagnosed that temporomandibular disorder type IIIa was developed to type IIIb.

TREATMENT

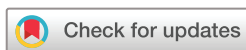A makeshift dental splint was fabricated out of gauze and worn by the patient at all times, except when eating and drinking.

OUTCOME AND FOLLOW-UP

The mouth opening was 55 mm on the day of surgery and the pain had resolved. Tracheal intubation for colectomy was performed safely and without incident.

DISCUSSION

Here, we present a case, in which a dental anaesthesiologist treated a patient with type IIIb temporomandibular joint disease and trismus 1 day before colectomy using a simple splint.



© BMJ Publishing Group Limited 2021. Re-use permitted under CC BY-NC. No commercial re-use. See rights and permissions. Published by BMJ.

To cite: Tateno K, Mieda T, Doi K. *BMJ Case Rep* 2021;**14**:e244635. doi:10.1136/bcr-2021-244635

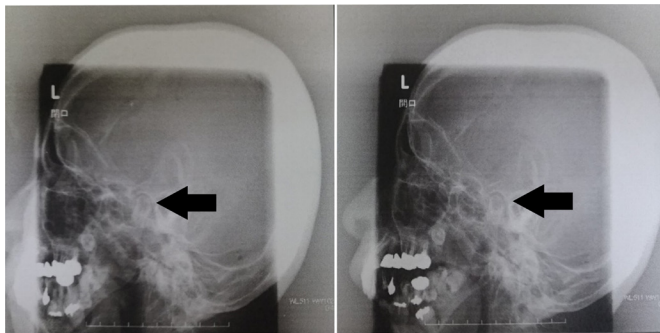


Figure 1 Schuller's radiographic method (left temporomandibular joint). As indicated by the arrows, the mandibular condyle has not moved forward even in the open position. The temporomandibular joint have not bone ankyloses and no fractures in the mandible. This figure is published with the patient's consent.

Treatment of temporomandibular disorder type IIIb includes drug administration, manipulation, mobilisation, splints and surgery. Drug therapy was considered unnecessary because there was no evidence of inflammation. Manipulation and mobilisation were avoided in this case because the patient's teeth were in poor condition because of periodontal disease. Surgical treatment was avoided because it was very invasive and could have affected the treatment of rectal cancer.

A splint was selected for this case. This treatment was decided based on our previous experience of using a splint for treating a patient with acute temporomandibular disorder type IIIb, wherein improvement was seen in 1 day. The cure was possible in 1 day because it was treated early in the acute phase; especially, it may have taken much time in the chronic phase.

Splints used to treat temporomandibular disorders include stabilisation, repositioning and pivot splints. Stabilisation or pivot splints are used often for type IIIb temporomandibular

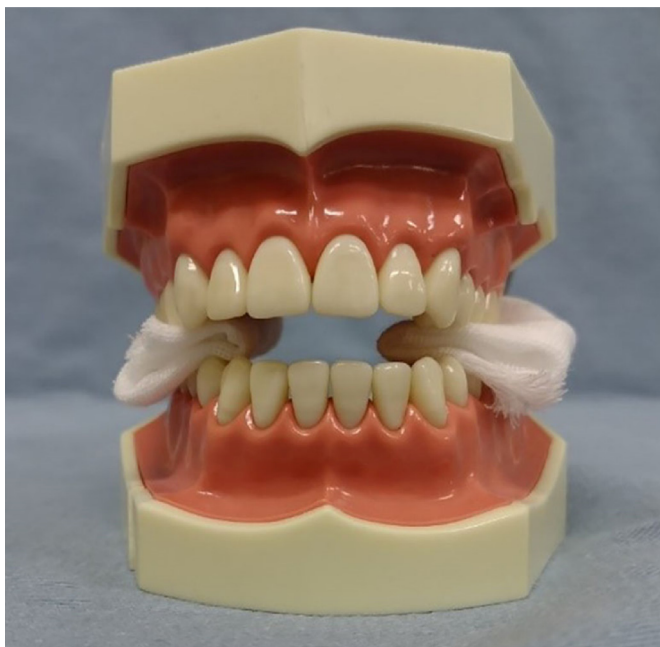

Figure 2 Splint with gauze (jaw model). In this case, a method similar to a pivot splint was used, in which the molars were raised mainly with gauze.

disorders. In this case, a method similar to a pivot splint was used, in which the molars were raised mainly with gauze. We did not use a stabilisation splint because it covers the front teeth and puts a burden on the front teeth of patients with periodontal disease. Repositioning splints are used to stabilise the jaw after manipulation. The latter is difficult with a gauze splint.

Manipulation is effective in cases of trismus in emergencies, such as after induction of anaesthesia. This method rapidly improves trismus. It is effective for emergency response because the degree of opening is improved after a single procedure. The response to splint treatment is generally slower than the response to manipulation. It cannot be used for emergency locking. However, because it slowly works on the temporomandibular joint, it is less invasive and has fewer complications. If trismus is attributed to temporomandibular disorder type IIIb, muscle relaxants are not effective because the disk limits jaw movement. It is very important to work on creating a space between the mandibular fossa and the condyle and to return the articular disk. Healthcare practitioners involved in airway management may need to learn manipulation which may reduce complications caused by hypoxia.

In this case, we performed gauze splint treatment because of the urgent need for colorectal cancer surgery. The surgery can be performed with spinal or epidural anaesthesia, but it is not always 100% effective compared with general anaesthesia. Therefore, there is a possibility of switching to general anaesthesia during the surgical procedure. Switching to general anaesthesia for management presents a high risk of breathing only with a mask for a long time.

Safe intubation through the nose is also possible in the awake state; however, it might be difficult for an inexperienced surgeon because of increased secretions in the pharynx caused by nasal bleeding and irritation during the insertion of the tracheal tube. Repeated intubation can increase the chance of complications and cause hypoxia.⁴ If the operator is not familiar with these procedures, tracheal intubation should be selected from the beginning.

Anaesthetic management of patients with trismus has been reported to be difficult.⁵⁻⁷ Preoperative evaluation and management of trismus are important. Preoperative evaluation can reduce problems related to temporomandibular disorders.⁸ If a dentist had been consulted prior to surgery and trismus was managed/prevented, patient troubles may have been prevented. If a patient can open the mouth before the operation, anaesthesia could be performed more safely than awake nasotracheal intubation and tracheostomy.

In a questionnaire regarding oral injuries, 80.5% of the respondents had experienced dental injuries.⁹ In patients with temporomandibular joint disorders, where intubation is required, precise evaluation of the oral cavity by a dentists is highly advisable.¹⁰

If a problem occurs in the oral cavity, the initial response can be handled swiftly by a dental anaesthesiologist. Therefore, we suggest that a dental anaesthesiologist should be available in general hospitals without a dentistry department.

Learning points

- ▶ Difficult intubations can lead to adverse events during surgery and, ultimately, to death.
- ▶ A simple splint was used to manage a type IIIb temporomandibular disorder and allow safe intubation for colectomy.

Acknowledgements I would like to thank Ko Ito associate professor Department of Oral and Maxillofacial Surgery, Saitama Medical University, Saitama, Japan to gave me advice on how to treat temporomandibular disorders.

Contributors KT initiated the data collection and designated the work, wrote the manuscript and contributed to surgical management. TM cowrote the manuscript and contributed in the follow-up of the patient. KD performed the critical revision of the article and final approval of the version to be published.

Funding The authors have not declared a specific grant for this research from any funding agency in the public, commercial or not-for-profit sectors.

Competing interests None declared.

Patient consent for publication Consent obtained directly from patient(s).

Provenance and peer review Not commissioned; externally peer reviewed.

Open access This is an open access article distributed in accordance with the Creative Commons Attribution Non Commercial (CC BY-NC 4.0) license, which permits others to distribute, remix, adapt, build upon this work non-commercially, and license their derivative works on different terms, provided the original work is properly cited and the use is non-commercial. See: <http://creativecommons.org/licenses/by-nc/4.0/>.

REFERENCES

- Hannig KE, Hauritz RW, Jessen C, *et al*. Acute awake fiberoptic intubation in the ICU in a patient with limited mouth opening and hypoxemic acute respiratory failure. *Case Rep Anesthesiol* 2019;2019:1–5.
- Khorana AA, Tullio K, Elson P, *et al*. Time to initial cancer treatment in the United States and association with survival over time: an observational study. *PLoS One* 2019;14:e0213209.
- Zhang S-H, He K-X, Lin C-J, *et al*. Efficacy of occlusal splints in the treatment of temporomandibular disorders: a systematic review of randomized controlled trials. *Acta Odontol Scand* 2020;78:580–9.
- Patel K, Mastenbrook J, Pfeifer A, *et al*. Successful intubation of a difficult airway using a yankauer suction catheter. *J Emerg Med* 2019;57:383–6.
- Yasuda A, Miyazawa N, Inoue E, *et al*. Anesthetic management of a juvenile hyaline fibromatosis patient with trismus and cervical movement limitation. *Anesth Prog* 2021;68:117–8.
- Shamim F, Bahadur A, Ghandhi D, *et al*. Management of difficult airway in a pregnant patient with severely reduced mouth opening. *J Pak Med Assoc* 2021;71:1011–3.
- Taharabaru S, Sato T, Nishiwaki K. Difficult airway management in a patient with nicolaides-baraitser syndrome who had a small jaw and limited mouth opening. *Anesth Prog* 2021;68:47–9.
- Gadotti IC, Geronimo M, Rodriguez G, *et al*. Evaluation of temporomandibular joint by anesthesiologists in Florida when conducting Orotracheal intubation-a pilot study. *J Clin Med* 2020;9:3229.
- Doğan Özgür, Altintepe Doğan SS, Altintepe N. An analysis of anesthesiologists' awareness, knowledge, and attitudes toward peri-anesthetic dental trauma. *Dent Traumatol* 2021. [Epub ahead of print: 03 Jul 2021]. doi:10.1111/edt.12702
- Giraudon A, de Saint Maurice G, Biais M, *et al*. Dental injury associated with anaesthesia: an 8-year database analysis of 592 claims from a major French insurance company. *Anaesth Crit Care Pain Med* 2018;37:49–53.

Copyright 2021 BMJ Publishing Group. All rights reserved. For permission to reuse any of this content visit <https://www.bmj.com/company/products-services/rights-and-licensing/permissions/>
BMJ Case Report Fellows may re-use this article for personal use and teaching without any further permission.

Become a Fellow of BMJ Case Reports today and you can:

- ▶ Submit as many cases as you like
- ▶ Enjoy fast sympathetic peer review and rapid publication of accepted articles
- ▶ Access all the published articles
- ▶ Re-use any of the published material for personal use and teaching without further permission

Customer Service

If you have any further queries about your subscription, please contact our customer services team on +44 (0) 207111 1105 or via email at support@bmj.com.

Visit casereports.bmj.com for more articles like this and to become a Fellow