



REVIEW ARTICLE

Pre-prosthetic orthodontics



Hayam Alfallaj*

Department of Dentistry, College of Dentistry, King Saud bin Abdulaziz University for Health Sciences, Riyadh, Saudi Arabia
King Abdullah International Medical Research Center, Riyadh, Saudi Arabia
Department of Prosthetics and Dental Geriatrics, Faculty of Dentistry, The University of British Columbia, Vancouver, Canada

Received 3 May 2019; revised 19 August 2019; accepted 21 August 2019
 Available online 27 August 2019

KEYWORDS

Orthodontics;
 Interdisciplinary;
 Crown-lengthening;
 Worn-teeth;
 Tilted-molar

Abstract For some patients, pre-prosthetic orthodontic intervention is necessary to optimize both esthetic and functional aspects of dental treatment. This review will focus on the following topics: orthodontics treatment with multiple missing teeth, correction of anterior deep vertical overlap, anterior worn dentition, up-righting of tilted teeth, and orthodontic crown lengthening. This review will aid restorative dentists in identifying which patients could benefit from orthodontic intervention, and in understanding how orthodontic treatment can be utilized to improve patient prognosis in restorative treatment.

© 2019 Production and hosting by Elsevier B.V. on behalf of King Saud University. This is an open access article under the CC BY-NC-ND license (<http://creativecommons.org/licenses/by-nc-nd/4.0/>).

Contents

1. Introduction	8
2. Pre-prosthetic orthodontic intervention:	8
2.1. Orthodontics treatment with multiple missing teeth	8
2.2. Excessive vertical overbite	9
2.3. Worn anterior teeth	10
2.4. Up-righting of tilted molars	12
2.5. Orthodontics extrusion for crown lengthening purpose	13
3. Conclusion	13
Ethical approval	13
Declaration of Competing Interest	13
References	13

* Address: King Saud bin Abdulaziz University for Health Sciences, College of Dentistry, PO Box 3660, Riyadh 11481, Saudi Arabia.
 E-mail address: Hayam.alfallaj@alumni.ubc.ca.

Peer review under responsibility of King Saud University.



1. Introduction

The need for orthodontic tooth movement prior to restorative treatment is necessary for some patients, in order to optimize both esthetic and functional aspects of dental treatment. Within the literature, most articles regarding pre-prosthetic orthodontics are either clinical reports or clinicians' opinions, both of which are among the lowest levels of evidence (Richards et al., 2008). Nevertheless, such articles can help restorative dentists to recognize which patients could benefit from orthodontics intervention, and to understand how orthodontics treatment can be utilized to improve the prognosis of restorative treatment.

Planning for treatment of patients who require pre-prosthetic orthodontics must always begin with a diagnostic wax-up, which is an important tool that enables both the orthodontist and the restorative dentist to visualize the final results. The orthodontist should confirm that the changes in tooth position on the diagnostic cast can be achieved in the patient's mouth; the restorative dentist should confirm that tooth position is ideal for future restorations that are both esthetically and functionally acceptable. Adequate communication and planning between the restorative dentist, orthodontist, and other clinicians before the implementation of any treatment is a very important step; each of these clinicians should know the particular stage at which he or she should intervene, how much time is needed to fulfill the objectives of his or her intervention, and the cost of the provided treatment. The patient will expect to know this information before agreeing to the proposed treatment plan (Kokich and Spear, 1997).

Before discussing orthodontic interventions that can be used for restorative purposes, it is important to understand the concept of anchorage. Proffit defined anchorage as "resistance to unwanted movement." Accordingly, for every favorable force that causes desired tooth movement, there is an equal unfavorable force in the opposite direction, which is exerted by the same orthodontics appliance. Anchorage is the resistance to these undesired forces. Generally, anchorage is provided by the teeth; however, many adult patients may not have an adequate number of teeth, or may have periodontally compromised teeth with insufficient strength to resist undesired forces. Therefore, orthodontists sometimes recommend the use of Temporary Anchorage Devices (TADs), which are small titanium alloy or stainless-steel screws mainly used for adult patients with multiple missing teeth, or used in cases where absolute anchorage is required (Mizrahi and Mizrahi, 2007; Bidra and Uribe, 2012). TADs are typically placed in the buccal or palatal alveolar bone, in a location dependent on the required movement, and are attached to the bone by mechanical means without osseointegration; therefore, they can be easily removed when treatment is completed. TADs have different lengths (5–12 mm) and diameters (1.2–2 mm); the orthodontist must place them carefully to ensure that there is adequate attached gingiva and a minimum space of 2 mm between the roots. Complications of these type of screws include: contacting the adjacent root, implant loosening or fracture, and damage to the adjacent anatomical structure (Mizrahi and Mizrahi, 2007).

Pre-prosthetic orthodontic intervention is needed in a variety of situations. For brevity, this review will focus on the following topics:

- Orthodontics treatment with multiple missing teeth.
- Correction of anterior deep vertical overlap.
- Anterior worn dentition.
- Up-righting tilted teeth.
- Orthodontics crown lengthening.

2. Pre-prosthetic orthodontic intervention:

2.1. Orthodontics treatment with multiple missing teeth

A notable situation that requires prosthetic orthodontic interdisciplinary treatment is when a patient requires comprehensive orthodontics treatment to correct tooth alignment in combination with multiple missing teeth. In these cases, a thorough communication between the restorative dentist and the orthodontist is essential in order to decide whether space closure or space opening is more appropriate for the final treatment outcomes. Moreover, the selection of the final prosthetic treatment, whether removable partial denture, fixed partial dentures, or implant-supported prosthesis is also required at the start of the planning process, to correctly plan spaces between the teeth for future pontics or implant-supported crowns (Pinho et al., 2012; Uribe et al., 2013).

Given that the anchorage provided by the reduced number of teeth is limited in such cases, the orthodontist can use either TADs, or for those have selected implant-supported prosthesis as the final treatment, the implant could be placed before or during the orthodontics treatment to anchor the teeth during subsequent movement (Kokich, 1996a, 1996b; Uribe et al., 2013). Implant placement before or during orthodontics treatment increases the risk of improper implant positioning, which may compromise the esthetic and function of future implant crowns. Therefore, diagnostic set-up for the corrected tooth position and wax-up for the missing teeth are essential at the planning stage; these enable accurate planning of the final implant position (Kokich, 1996a, 1996b; Mitrani, 2008). In order to construct a surgical guide for implant placement, the orthodontist should change the position of the existing teeth on a cast to simulate the outcome of the treatment objectives, then the restorative dentist should plan the position of the implants based on a wax-up of the future implant crowns, the information regarding implant position should then be transferred to the original cast since the guide will be seated on the existing teeth before the orthodontic treatment. New digital software may be valuable in such situations to design and fabricate a surgical guide to place definitive implants before orthodontic therapy (Bayraktaroglu et al., 2015). The software enables clinicians to virtually change the position of the existing teeth, and planning the size, shape, and location of the future implant-supported crowns, in order to fabricate a surgical guide that will set on the patient teeth and guide the surgeon to place the implants in proper future implant abutment position.

2.2. Excessive vertical overbite

According to the glossary of prosthodontics, the term “vertical overlap” has been defined as “the distance teeth lap over their antagonists as measured vertically; especially the distance maxillary central incisal edges extend below those of mandibular teeth” (*The Glossary of Prosthodontic Terms: Ninth Edition, 2017*). In general, vertical overlap is a situation in which one-third of maxillary anterior teeth cover the mandibular incisors; there is extreme variation in the extent of anterior vertical overlap in clinically healthy dentitions (*Akerly, 1977*). However, there are some situations of excessive vertical overlap that can cause trauma to the soft tissue or tooth wear; in addition, “deep bite” or “overclosure” can preclude restoration of missing anterior teeth with removable or fixed restorations at the existing incisal plane, without compromising the esthetic nature of the dentition, its function within the patient, or the structural integrity of the restoration itself (*Torbjorner and Fransson, 2004; Beddis et al., 2014*). Such traumatic overclosure exists primarily in patients with Angle class II malocclusion; the management of these situations requires more complex treatment. Notably, some situations may require restorative treatment alone; this treatment will involve an increase in the vertical dimension through restoration of the occlusal surface of posterior teeth with direct or indirect restorations, which will provide more space for the anterior restorations (*Torbjorner and Fransson, 2004; Ergun and Yucel, 2014*). Another method to manage such situations is orthodontic correction of the

excessive anterior vertical overlap, followed by restorative treatment (*Akerly, 1977; Capp and Warren, 1991; Beddis et al., 2014*). Deep vertical overbite can be treated orthodontically by either intrusion of anterior teeth, extrusion of posterior teeth, or a combination of both. However, extrusion of posterior teeth is more prone to relapse, as the contraction of masticatory muscles may return the posterior teeth to their original positions. Thus, segmented intrusion of the anterior teeth is preferable in adult patients (*Weiland et al., 1996*). The use of implant anchorage is helpful in such patients, as it provides absolute anchorage to manage the intrusion of anterior teeth (*Ohnishi et al., 2005; Ishihara et al., 2014*).

For orthodontic treatment of patients with deep vertical overlap, Kokich recommended the following approach (*Kokich, 2008*):

1. Identify the correct occlusal plane on cephalometric radiograph using a fixed landmark. Posteriorly, the occlusal plane originates from the contact between maxillary and mandibular 2nd molars. Anteriorly, the other end of the occlusal plane may be regarded as the level of the upper lip at rest (*Fig. 1*).
2. By studying the relationship between maxillary and mandibular anterior teeth with the correct occlusal plane, the clinician can determine whether the deep vertical overbite is caused by overeruption of maxillary or mandibular anterior teeth. This determination can be made by identifying the incisal edge of the maxillary central incisor and mea-

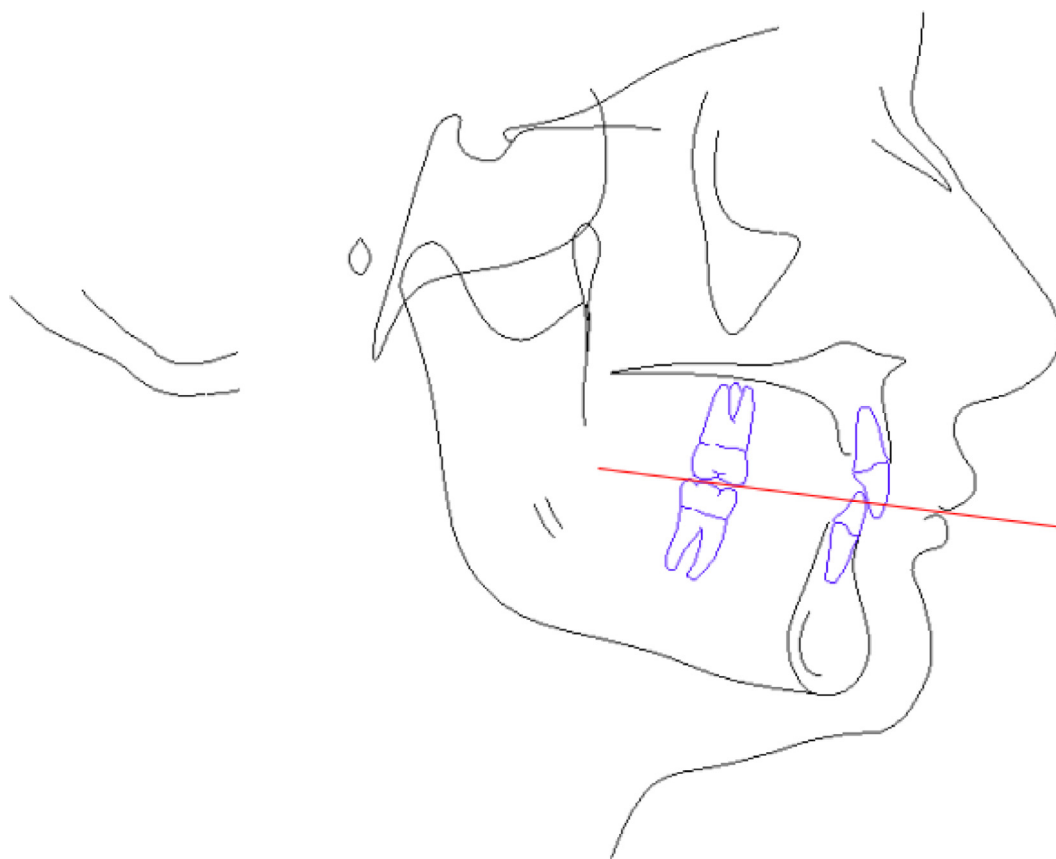


Fig. 1 Cephalometric tracing for a patient with excessive anterior overbite. The red line indicates the correct occlusal plane connecting the occlusal surface of the second molars posteriorly and upper lip in rest position anteriorly.

suring its distance from the correct occlusal plane. Notably, age affects the distance between the incisal edge and upper lip. Thus, maxillary anterior teeth are expected to be 2–3 mm below the anterior end of the plane in young people; this distance is shortened for older people. If the distance exceeds expected values, the maxillary anterior teeth are the likely source of the deep bite. For mandibular anterior teeth, the incisal edge should be at the level of the occlusal plane; if these teeth are above the occlusal plane, they are over-erupted and may need to be intruded.

3. Evaluate the gingival margin position:

- o If the gingival margins of the central incisors are located coronally to the canines, the clinician should identify the cause of this uneven gingival margin.
- o If the cemento-enamel junction is within 1 mm of the gingival margin and the incisal edges of the anterior teeth show a degree of tooth wear, the anterior teeth may have experienced compensatory eruption or den-toalveolar extrusion. Thus, the clinician would need to further intrude the teeth apically, in order to correct the gingival margin position; in this situation, the width-to-length proportion of the final restorations that fit the patient's esthetic would be an important determinant for the extent of intrusion. However, if the cemento-enamel junction is located more than 1 mm apical to the gingival margins, the gingiva may have experienced altered passive eruption and its length should be corrected surgically (Kokich, 1996a, 1996b).

- o Importantly, prior to the implementation of any orthodontics treatment, restorative dentists and orthodontists should agree on a specific treatment plan and must use the gingival margins (not the incisal edge) as a reference for tooth intrusion, particularly if the patient shows a high smile line.

4. Most patients with deep anterior overbite can be treated by orthodontics treatment alone. However, for patients with severe facial disproportion, surgical intervention is required to correct excessive vertical overlap. For example, in patients with significant shortening of lower facial height, orthodontic treatment will correct the deep overbite, but cannot enhance facial appearance. Therefore, a mandibular sagittal split osteotomy and rotation of the mandible in the chin area will decrease vertical overbite and increase lower facial height.

2.3. Worn anterior teeth

Another type of challenging situation that requires a multidisciplinary approach involves short anterior clinical crowns due to a habit of anterior bruxism, combined with posterior teeth of normal height that maintain their vertical dimension (Fig. 2). In this type of situation, the anterior teeth will continue to erupt with the bone and surrounding tissue (compensatory eruption), thereby maintaining contact with the opposing teeth; this will result in short clinical crowns and

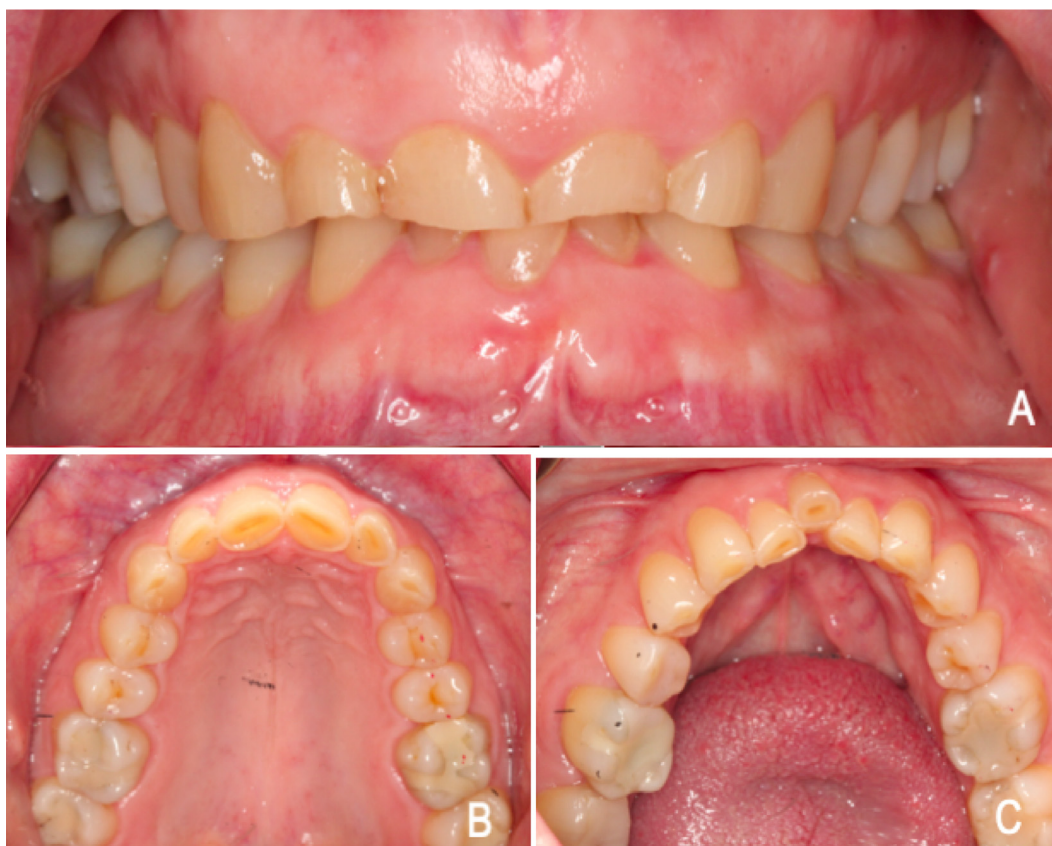

Fig. 2 Intra-oral photographs for a patient with anterior worn-down dentition due to protrusive bruxism habit. A: anterior retracted smile view, shows anterior teeth with short clinical crown and inconsistent gingival margins level, and posterior teeth with normal clinical height. B and C: Maxillary and mandibular occlusal view, shows signs of moderate to severe tooth wear on anterior teeth only.

inconsistent marginal gingiva (Turner and Missirlian, 1984; Kokich, 2008).

To restore the anterior dentition in such situations, the restorative dentist can use one of the following approaches:

1. Orthodontics intrusion of the worn anterior teeth.
2. Surgical crown lengthening of the worn anterior teeth.
3. Enhancement of the vertical dimension through restoration of the occlusal surface of posterior teeth, thereby gaining the space needed for restoration of anterior teeth.
4. Utilization of the Dahl concept

A. Orthodontics intrusion of worn anterior teeth

Although orthodontics intrusion is a lengthy treatment that requires a high degree of patient compliance, it is an ideal treatment option because of its less invasive nature, compared to other options; this aids in correction of the gingival margin and eliminates the need to perform incisal reduction for crown preparation (Fig. 3).

At the planning phase, the restorative dentist can use the amount of tooth displayed at rest and the amount of lip mobility to determine how he or she will lengthen the short worn down anterior teeth, then in most of the cases, the treatment will be a combination of orthodontic intrusion and restoratively adding to the incisal edge (Spear, 2016). In such situations, the gingival margins should be used as a reference for intrusion of worn teeth, rather than the incisal edges. The guide for the amount of anterior tooth intrusion will be determined on the basis of adjacent non-worn teeth. For example, if central and lateral incisors are worn and over-erupted, the central incisor should be intruded until its gingival margin reaches the same level as the gingival margin of the non-worn canine; while the gingival margin of the lateral incisor should be located 1 mm coronally (Kokich, 2007). In addition, the width-to-length proportion of the final restorations that fit the patient's esthetic is an important determinant for the amount of intrusion (Spear, 2016). During orthodontics treatment and after intrusion of teeth, discrepancy in the incisal edges becomes more apparent and may result in an anterior open bite. Therefore, to establish proper anterior guidance, the orthodontics bracket might

need to be removed, thus allowing the restorative dentist to build provisional restorations using composite material on the anterior dentition. Orthodontic brackets can then be bonded again to continue the orthodontics treatment or complete the stabilization period (Kokich and Spear, 1997; Kokich, 2007; Kokich, 2008; Spear, 2016). Following orthodontic correction of the gingival margin, the position of the teeth should be maintained for at least 6 months to aid in reorienting the periodontal fiber into a more stable position, thus preventing re-extrusion of the teeth. After the worn anterior teeth have received final ceramic or metal-ceramic restorations, the patient should be provided with a bite splint and asked to wear it while sleeping; this is regarded as a method of stabilizing the occlusion and can help to protect the final restorations (Kokich, 2007).

A restorative dentist should consider a few aspects when referring a patient for orthodontics intrusion. Notably, in a comparison of the bone level and root length of 57 periodontally sound anterior teeth using periapical radiography, Bellamy et al. studied the effect of tooth intrusion on the surrounding bone and root length. They found that the alveolar bone level of intruded teeth remained relatively constant relative to the cemento-enamel junction, which indicated that the bone would follow the teeth during intrusion movement. Moreover, they found significant apical root resorption for maxillary and mandibular anterior teeth (1.73 mm and 1.37 mm, respectively), following the intrusion. These findings suggest that the restorative dentist should consider the future crown to root ratio for patients who require orthodontic intrusion (Bellamy et al., 2008; Spear, 2016).

B. Surgical crown lengthening

Another method to treat patients with anterior attrition is the application of a surgical crown lengthening procedure to correct the discrepancy in gingival margins and achieve greater retention and resistance for future restorations. Typically, this procedure is followed by elective endodontic treatment, post and core buildups, and restoration of the teeth (Kokich, 2007; Kokich, 2008). Table 1 shows the differences between surgical crown lengthening and orthodontic intrusion for worn anterior teeth.

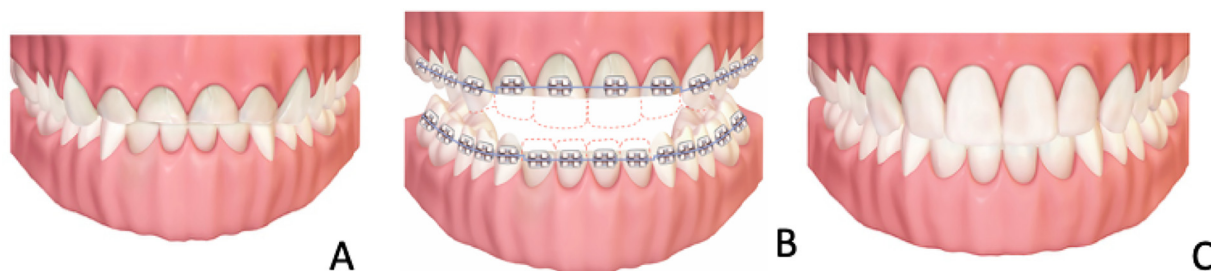


Fig. 3 Illustrations for anterior worn-down dentition case treated with a combination of orthodontic intrusion of anterior teeth followed by restorative treatment to build the incisal guidance and to improve the esthetic of the anterior teeth. A: An illustration for the clinical presentation of worn-down anterior teeth due to anterior bruxism habit. B: Orthodontic treatment to intrude the short anterior teeth, the gingival margins of the adjacent non-worn teeth should be used to determine the amount of tooth intrusion. Red dotted lines indicate the future restoration outline. C: clinical presentation of the case after completion of the restorative treatment.

Table 1 Differences between surgical crown lengthening and orthodontic intrusion for worn anterior teeth.

Crown lengthening	Orthodontic intrusion
Incisal reduction is required, which might necessitate intentional endodontics treatment (Kokich, 2007)	Preserves tooth structure (incisal reduction is not required)
Affects crown to root ratio (Kokich, 2008)	Affects crown to root ratio by apical resorption (Bellamy et al., 2008)
Invasive treatment (Kokich, 2008)	Long treatment time (Saha and Summerwill, 2004)
Margins on root surface; patient may experience sensitivity from exposed root surface (Saha and Summerwill, 2004)	Requires patient compliance (Saha and Summerwill, 2004)
Black triangles are expected between the teeth, which compromises the esthetic outcome. This happens primarily due to the wide discrepancy in the incisal dimension of the crown compared to the narrower diameter root (Saha and Summerwill, 2004)	

C. Increasing the occlusal vertical dimension with posterior restoration

The occlusal vertical dimension can be increased by restoring posterior teeth in one or both arches, thereby providing restorative space for worn anterior teeth (Turner e Missirlian, 1984; Kokich, 2008).

D. Dahl concept

This simple orthodontic concept has been described as a noninvasive technique to create anterior interocclusal space for restorative material without affecting clinical crown height (Dahl et al., 1975). This concept begins with the use of a removable chrome cobalt appliance that solely covers the palatal surface of the anterior teeth, thus allowing disocclusion of posterior teeth. Over a period of time, the posterior teeth will over-erupt to reestablish occlusion; this creates interocclusal space between anterior teeth, through a combination of the intrusion of the anterior teeth in contact with the appliance and the eruption of posterior teeth. Subsequently, the concept can be used with many direct and indirect fixed restorations (Dahl et al., 1975; Hemmings et al., 2000; Saha and Summerwill, 2004; Poyser et al., 2005).

The disadvantage of this concept is that the patient will experience difficulties in chewing and speaking, and periodontal and pulpal symptoms are expected to be caused by the application of excessive occlusal forces to the anterior teeth. In addition, the duration needed for these appliances is unpredictable and might range from 6 to 24 months. Finally, some reports have described failure of the posterior teeth to reestablish occlusion (Poyser et al., 2005).

2.4. Up-righting of tilted molars

Tilted posterior teeth constitute a common clinical problem that interferes with restorative treatment and replacement of missing teeth. This occurs mainly because of the loss of the interproximal contact due to tooth extraction, or the loss of tooth tissue structure (e.g., extensive proximal caries); this causes loss of proximal contact area and eventual tilting of adjacent teeth, ectopic eruption of some teeth, and ankylosed infra-eruption (Stern et al., 1981; Kennedy, 2009). The most frequently affected tooth is the mandibular second molar, as the first mandibular molar is frequently lost. It is important to note that not all teeth adjacent to the edentulous area are subjected to tilting. If the remaining teeth are well intercuspated by the opposing arch, drifting or tilting will be minimal and rare (Stern et al., 1981; Simon, 1984).

Consequences of tilting typically involve the formation of infrabony defects on the mesial side of the tilted tooth. Alterations of this area are likely to result in a defect of gingival tonus and the formation of a pseudo-pocket, thereby rendering the tissue more susceptible to periodontal disease (Stern et al., 1981).

In patients who require replacement of a missing tooth adjacent to a tilted molar, the restorative dentist can use the following approaches (Revah et al., 1985):

- When the tilt of the molar tooth is not severe, the dentist can perform enameloplasty on the tilted tooth, if the restorative plan is to replace the missing tooth with an implant or removable denture. Slight modification of tooth reduction will be sufficient when preparing the tooth for fixed partial denture.
- Use of a locked attachment or telescopic crown.
- Alignment of the tilted tooth via orthodontic treatment.

There are several advantages of aligning the tooth via orthodontic treatment. This approach can eliminate the infrabony defect on the mesial side of the tilted tooth, simplify the preparation of the tilted abutment tooth to receive a fixed partial denture, aid in aligning the occlusal plane, and aid in transmission of occlusal forces through the long axes of the tooth (Becker et al., 1982). For adjunctive orthodontics treatment to return the tilted tooth to its normal position, both removable and fixed prosthodontics appliances can be used, each with unique benefits and limitations. Fixed appliances generally require more technical skills for application, but any tooth movement can be achieved if adequate anchorage is provided (Becker et al., 1982). Anchorage can be obtained by utilizing the anterior two premolars and canine, or by using a mini orthodontic implant. This movement will result in distal and lingual tipping of the second molar, and the treating dentist should eliminate any occlusal interference that might result from treatment (Simon, 1984). In contrast, removable appliances are dependent on patient compliance, and are limited to tipping movement without bodily or root movement. However, they can be used to temporarily increase the vertical dimension, thus clearing the tooth for movement without occlusal interferences (Becker et al., 1982).

The average time required for such treatment is 3 months; however, this time is affected by the extent of tooth tipping,

root length, remaining periodontal support, and amount of applied forces (Simon, 1984).

2.5. Orthodontics extrusion for crown lengthening purpose

Maintenance of the restorative margins within 0.5 to 1 mm in the gingival sulcus and approximately 3 mm coronal to the bone level is crucial for ensuring the health of the periodontium (Baba et al., 2014). However, in patients with subgingival caries, deep existing restoration, or subgingival defect, the restorative dentist might need to refer the patient for clinical crown lengthening to prevent invasion of the biological width. In this situation, the clinician must choose one of two options: surgical crown lengthening or orthodontic crown lengthening with rapid and high extrusion forces, which may result in movement of the tooth without the attachment apparatus (Potashnick and Rosenberg, 1982; Alsahhaf and Att, 2016).

The advantages of orthodontic extrusion over surgical crown lengthening are that orthodontic extrusion provides a more favorable crown to root ratio, eliminates the risk of compromising the alveolar bone support of the adjacent teeth, and will not compromise the esthetic of the tooth that requires crown lengthening (Potashnick and Rosenberg, 1982). Some authors have described the need for corrective surgical crown lengthening after extrusion, in order to correct the coronal position of the free gingival margin (Ingber, 1976; Ivey et al., 1980). However, in a randomized clinical study, Carvalho et al reported that patients who received fiberotomy treatment which includes an intrasulcular incision through the junctional epithelium and connective tissue, combined with root planing each week during the force eruption and stabilization periods, needed significantly less surgical correction procedures following orthodontics treatment, compared to patients who did not receive fiberotomy treatment (Carvalho et al., 2006). This could be explained by the elimination of the transmission of tensile forces, generated by supra-crestal fibers to the bone, thus prevents bone formation coronal to the sound remaining fiber attachment (Pontoriero et al., 1987; Schwimer et al., 1990).

The treatment of an isolated tooth with orthodontics extraction typically begins with endodontic treatment, followed by placement of post and core and temporary crown; segmented orthodontic treatment is then initiated with extrusion that is activated weekly with approximately 50 mg extrusion forces. This is expected to result in extrusion of 1 mm per week. The dentist must ensure that there is no contact between the extruded and opposing teeth during the active treatment period. After achieving the proper dentogingival relationship, the tooth position must be stabilized for 6 to 8 weeks to allow bone remodeling before final restoration (Ingber, 1976; Schwimer et al., 1990; Carvalho et al., 2006). Restorative procedures after completion of the crown lengthening require greater comprehension by the restorative dentist, as the gingival margin of the crown will be on the smaller mesio-distal diameter root; thus, the final crown will require a greater degree of taper from the gingival margin to the contact area. Importantly, the dentist must balance between overcontour restoration that might affect gingival health and tapered restoration that will reveal black triangles between teeth (Ingber, 1976).

3. Conclusion

- Understanding the influence of orthodontic treatment on esthetic and functional outcomes will facilitate proper planning of restorative treatment.
- Adequate communication between the orthodontist and restorative dentist prior to orthodontics intervention, during treatment, and before bracket debonding is essential for success in multidisciplinary treatment scenarios.
- Diagnostic wax-up is a critical tool in nearly all situations involving pre-prosthetic orthodontics, as it helps clinicians to establish their treatment objectives and visualize the final results of the treatment.

Ethical approval

No ethical approval required.

Declaration of Competing Interest

No conflict of interest.

References

- Akerly, William B., 1977. Prosthodontic treatment of traumatic overlap of the anterior teeth. *J. Prosthet. Dent.* 38 (1), 26–34. [https://doi.org/10.1016/0022-3913\(77\)90263-3](https://doi.org/10.1016/0022-3913(77)90263-3).
- Alsahhaf, Abdulaziz, Att, Wael, 2016. Orthodontic extrusion for pre-implant site enhancement: Principles and clinical guidelines. *J. Prosthodont. Res.* 60 (3), 145–155. <https://doi.org/10.1016/j.jpor.2016.02.004>.
- Baba, Nadim Z., Goodacre, Charles J., Jekki, Rami, Won, John, 2014. Gingival displacement for impression making in fixed prosthodontics. *Dent. Clin. North Am.* 58 (1), 45–68. <https://doi.org/10.1016/j.cden.2013.09.002>.
- Bayraktaroglu, H.C., Kim, J.S., Londono, J., Baker, P.S., 2015. Digital design of a surgical guide for placement of definitive implants before orthodontic treatment. *J. Prosthet. Dent.* 114 (2), 174–177.
- Becker, Adrian, Zalkind, Maya, Stern, Noah, 1982. The tilted posterior tooth. Part II: Biomechanical therapy. *J. Prosthet. Dent.* 48 (2), 149–155. [https://doi.org/10.1016/0022-3913\(82\)90101-9](https://doi.org/10.1016/0022-3913(82)90101-9).
- Beddis, H.P. et al, 2014. The restorative management of the deep overbite. *Br. Dent. J.* 217 (9), 509–515. ISSN 0007-0610.
- Bellamy, Lucien J., Kokich, Vincent G., Weissman, Jake A., 2008. Using orthodontic intrusion of abraded incisors to facilitate restoration. *J. Am. Dent. Assoc.* 139 (6), 725–733. <https://doi.org/10.14219/jada.archive.2008.0254>.
- Bidra, A.S., Uribe, F., 2012. Preprosthetic orthodontic intervention for management of a partially edentulous patient with generalized wear and malocclusion. *J. Esthet. Restor. Dent.* 24 (2), 88–100. ISSN 1496-4155.
- Capp, N.J., Warren, K., 1991. Restorative treatment for patients with excessive vertical overlap. *Int. J. Prosthodont.* 4 (4), 353–360. ISSN 0893-2174 (Print) 0893-2174.
- Carvalho, C.V. et al, 2006. Orthodontic extrusion with or without circumferential supracrestal fiberotomy and root planing. *Int. J. Periodont. Restorat. Dent.* 26 (1), 87–93.
- Dahl, BJØRN L., Krogstad, Olaf, Karlsen, Kjell, 1975. An alternative treatment in cases with advanced localized attrition. *J. Oral Rehabil.* 2 (3), 209–214. <https://doi.org/10.1111/jor.1975.2.issue-310.1111/j.1365-2842.1975.tb00914.x>.

- Ergun, Gulfer, Yucel, Ayse Seda, 2014. Full-mouth rehabilitation of a patient with severe deep bite: a clinical report: Rehabilitation of severe deep bite. *J. Prosthodont.* 23 (5), 406–411. <https://doi.org/10.1111/jopr.2014.23.issue-510.1111/jopr.12113>.
- The Glossary of Prosthodontic Terms: Ninth Edition. *J Prosthet Dent.* vol. 117, no. 5s, pp. e1–e105, May 2017. ISSN 0022-3913.
- Hemmings, Kenneth W., Darbar, Ulpee R., Vaughan, Simon, 2000. Tooth wear treated with direct composite restorations at an increased vertical dimension: Results at 30 months. *J. Prosthet. Dent.* 83 (3), 287–293. [https://doi.org/10.1016/S0022-3913\(00\)70130-2](https://doi.org/10.1016/S0022-3913(00)70130-2).
- Inger, Jeffrey S., 1976. Forced Eruption: Part II. A method of treating nonrestorable teeth—Periodontal and restorative considerations. *J. Periodontol.* 47 (4), 203–216. <https://doi.org/10.1902/jop.1976.47.4.203>.
- Ishihara, Yoshihito, Kuroda, Shingo, Sugawara, Yasuyo, Kurosaka, Hiroshi, Takano-Yamamoto, Teruko, Yamashiro, Takashi, 2014. Long-term stability of implant-anchored orthodontics in an adult patient with a Class II Division 2 malocclusion and a unilateral molar scissors-bite. *Am. J. Orthodont. Dentofacial Orthoped.* 145 (4), S100–S113. <https://doi.org/10.1016/j.ajodo.2013.07.016>.
- Ivey, David W., Calhoun, Richard L., Kemp, William B., Dorfman, Howard S., Wheless, John E., 1980. Orthodontic extrusion: Its use in restorative dentistry. *J. Prosthet. Dent.* 43 (4), 401–407. [https://doi.org/10.1016/0022-3913\(80\)90209-7](https://doi.org/10.1016/0022-3913(80)90209-7).
- Kennedy, D.B., 2009. Treatment strategies for ankylosed primary molars. *Eur. Arch. Paediatr. Dent.* 10 (4), 201–210. <https://doi.org/10.1007/BF03262683>.
- Kokich, V.G., 1996a. Esthetics: the orthodontic-periodontic restorative connection. *Semin. Orthodont.*, 21–30
- Kokich, V.G., 1996b. Managing complex orthodontic problems: the use of implants for anchorage. *Semin. Orthod.* 2 (2), 153–160. ISSN 1073-8746 (Print) 1073-8746.
- Kokich, Vincent G., 2007. Interdisciplinary management of anterior guidance: A case report. *Adv. Esthet. Interdiscip. Dent.* 3.
- Kokich, Vincent G., Spear, Frank M., 1997. Guidelines for managing the orthodontic-restorative patient. *Semin. Orthodont.* 3 (1), 3–20. [https://doi.org/10.1016/S1073-8746\(97\)80036-9](https://doi.org/10.1016/S1073-8746(97)80036-9).
- Kokich, V.G., 2008. Altering vertical dimension in the perio-restorative patient: the orthodontic possibilities. In: Cohen, M. (Ed.). *Interdisciplinary treatment planning: principles, design, implementation.* Chicago: Quintessence Pub., c2008-, 2008. cap. Altering vertical dimension in the perio-restorative patient: the orthodontic possibilities.
- Mitrani, R., 2008. Orthodontic forced eruption: an essential component of interdisciplinary treatment planning. In: Cohen, M. (Ed.). *Interdisciplinary treatment planning principle, design, implementation.* Chicago Quintessence Pub. p. 450.
- Mizrahi, Eliakim, Mizrahi, Basil, 2007. Mini-screw implants (temporary anchorage devices): orthodontic and pre-prosthetic applications. *J. Orthodont.* 34 (2), 80–94. <https://doi.org/10.1179/146531207225021987>.
- Ohnishi, H. et al, 2005. A mini-implant for orthodontic anchorage in a deep overbite case. *Angle Orthod.* 75 (3), 444–452. ISSN 0003-3219 (Print) 0003-3219.
- Pinho, Teresa, Neves, Manuel, Alves, Célia, 2012. Multidisciplinary management including periodontics, orthodontics, implants, and prosthetics for an adult. *Am. J. Orthodont. Dentofacial Orthoped.* 142 (2), 235–245. <https://doi.org/10.1016/j.ajodo.2010.10.026>.
- Pontoriero, R. et al, 1987. Rapid extrusion with fiber resection: a combined orthodontic-periodontic treatment modality. *Int. J. Periodont. Restorat. Dent.* 7 (5), 30–43. ISSN 0198-7569 (Print) 0198-7569.
- Potashnick, S.R., Rosenberg, E.S., 1982. Forced eruption: Principles in periodontics and restorative dentistry. *J. Prosthet. Dent.* 48 (2), 141–148. [https://doi.org/10.1016/0022-3913\(82\)90100-7](https://doi.org/10.1016/0022-3913(82)90100-7).
- Poyser, N J, Porter, R W J, Briggs, P F A, Chana, H S, Kelleher, M G D, 2005. The Dahl Concept: past, present and future. *Br. Dent. J.* 198 (11), 669–676. <https://doi.org/10.1038/sj.bdj.4812371>.
- Revah, Abraham, Rehany, Aliza, Zalkind, Maya, Stern, Noah, 1985. The tilted posterior tooth. Part III: Abutment for a fixed partial denture. *J. Prosthet. Dent.* 54 (3), 325–330. [https://doi.org/10.1016/0022-3913\(85\)90542-6](https://doi.org/10.1016/0022-3913(85)90542-6).
- Richards, D. et al, 2008. *Evidence-based dentistry: managing information for better practice.* London ISBN, 1850970521.
- Saha, Shuva, Summerwill, Anthony J., 2004. Reviewing the concept of Dahl. *Dent. Update* 31 (8), 442–447. <https://doi.org/10.12968/denu.2004.31.8.442>.
- Schwimer, Charles W., Rosenberg, Edwin S., Schwimer, David H., 1990. Rapid extrusion with fiberotomy. *J. Esthet. Restor. Dent.* 2 (3), 82–88. <https://doi.org/10.1111/jerd.1990.2.issue-310.1111/j.1708-8240.1990.tb00615.x>.
- Simon, Robert L., 1984. Rationale and practical technique for uprighting mesially inclined molars. *J. Prosthet. Dent.* 52 (2), 256–259. [https://doi.org/10.1016/0022-3913\(84\)90107-0](https://doi.org/10.1016/0022-3913(84)90107-0).
- Spear, F.M., 2016. Interdisciplinary management of worn anterior teeth facially generated treatment planning. *Dent. Today* 35 (5), 104–107. ISSN 8750-2186 (Print) 8750-2186.
- Stern, N., Revah, A., Becker, A., 1981. The tilted posterior tooth. Part I: etiology, syndrome, an prevention. *J. Prosthet. Dent.* 46 (4), 404–407. ISSN 0022-3913 (Print) 0022-3913.
- Torbjorner, A., Fransson, B., 2004. Biomechanical aspects of prosthetic treatment of structurally compromised teeth. *Int. J. Prosthodont.* 17 (2), 135–141. ISSN 0893-2174 (Print) 0893-2174.
- Turner, Kenneth A., Missirlan, Donald M., 1984. Restoration of the extremely worn dentition. *J. Prosthet. Dent.* 52 (4), 467–474. [https://doi.org/10.1016/0022-3913\(84\)90326-3](https://doi.org/10.1016/0022-3913(84)90326-3).
- Uribe, Flavio, Janakiraman, Nandakumar, Nanda, Ravindra, 2013. Interdisciplinary approach for increasing the vertical dimension of occlusion in an adult patient with several missing teeth. *Am. J. Orthodont. Dentofacial Orthoped.* 143 (6), 867–876. <https://doi.org/10.1016/j.ajodo.2012.05.022>.
- Weiland, Frank J., Bantleon, Hans-Peter, Droschl, Helmut, 1996. Evaluation of continuous arch and segmented arch leveling techniques in adult patients—a clinical study. *Am. J. Orthodont. Dentofacial Orthoped.* 110 (6), 647–652. [https://doi.org/10.1016/S0889-5406\(96\)80042-4](https://doi.org/10.1016/S0889-5406(96)80042-4).