

Surgeon-modified fenestrated endovascular aortic repair for ruptured anastomotic aneurysm after open thoracoabdominal repair

Silvan Jungi, MD, Zoe Sangalli, MD, Jürg Schmidli, MD, PhD, and Vladimir Makaloski, MD, PhD, Bern, Switzerland

ABSTRACT

We report the case of a 60-year-old female patient with a contained rupture of a proximal anastomotic pseudoaneurysm after previous open repair of a type IV thoracoabdominal aneurysm. A repeat open repair was considered to be too risky. We performed an urgent endovascular repair with a thoracic stent-graft and a surgeon-modified fenestrated aortic cuff with two fenestrations. The final angiogram and postoperative imaging studies showed complete aneurysm exclusion without any endoleak. Surgeon-modified fenestrated endovascular aortic repair is a feasible treatment option for emergency cases for which repeat open repair or custom-made complex endovascular repair is not an option. (*J Vasc Surg Cases Innov Tech* 2021;7:484-7.)

Keywords: Aortic surgery; Endovascular surgery; Ruptured aneurysm

A 60-year-old female patient had presented to another hospital with a sudden onset of abdominal, back, and left flank pain, constipation, and loss of appetite. A computed tomography angiogram (CTA) revealed a contained rupture of a proximal anastomotic pseudoaneurysm of the aorta at the level of the diaphragm. Previously, she had undergone open repair of type IV open thoracoabdominal aortic aneurysm (Fig 1). The patient was hemodynamically stable. The C-reactive protein and white blood cell count were normal at admission. A mycotic anastomotic aneurysm was deemed very unlikely.

Four years previously, the patient had undergone type IV open thoracoabdominal aortic repair. A surgeon-modified xenopericardial tube graft was used primarily to replace the abdominal aorta owing to the suspicion of a mycotic aneurysm at that time. The proximal anastomosis was at the level of the diaphragm and the distal anastomosis at the infrarenal aorta. All renovisceral vessels were directly reimplanted into the xenopericardial tube graft, with the right renal artery and superior mesenteric artery reimplanted as a single patch. The

left renal artery had originally been reimplanted higher than the superior mesenteric artery and lower than the celiac trunk. After negative results from the microbiologic and histopathologic analyses, the initial antibiotic therapy was stopped. The last CTA (2 years before her current presentation) showed regular postoperative findings without signs of infection or anastomotic irregularities. Her comorbidities consisted of cystectomy and an ileal conduit for a urothelial tumor, hysterectomy, multiple sclerosis, and severe malnourishment.

Because of her comorbidities and the previous open repair, a repeat open repair was considered too risky. In addition, complex endovascular repair with a custom-made fenestrated endovascular aortic device was rejected owing to the long manufacturing time.

Using multiplanar reconstruction, endovascular repair with a thoracic stent-graft and a back-table prepared surgeon-modified fenestrated aortic cuff with two fenestrations for the celiac trunk and left renal artery was planned. The procedure was performed with the patient under general anesthesia. The patient provided written informed consent, and she was specifically informed that the surgeon-modified stent graft would be used outside the instructions for use.

A 25-mm aortic cuff (Medtronic Endurant II Stent-Graft System; Medtronic Inc, Santa Rosa, Calif) was modified with two fenestrations: one with a 7-mm diameter for the celiac trunk and one with a 6-mm diameter for the left renal artery (Fig 2). Two separate pieces of snare were circularly sewn onto the fenestrations with 5-0 Ethibond running suture (Ethicon, Johnson & Johnson, Raritan, NJ; Fig 2). Next, the surgeon-modified aortic cuff was resheathed (Fig 2). Percutaneous bilateral femoral access using Proglide (Abbott Vascular, Santa Clara, Calif) as preclosure device was performed. A 25-mm thoracic stent graft (Medtronic Navion Thoracic Stent-Graft System; Medtronic Inc) was implanted with

From the Department of Cardiovascular Surgery, Inselspital, Bern University Hospital, University of Bern.

Author conflict of interest: V.M. is a consultant and proctor for Medtronic. S.J., Z.S., and J.S. have no conflicts of interest.

SJ and ZS contributed equally to this article and share co-first authorship.

Correspondence: Vladimir Makaloski, MD, PhD, Department of Cardiovascular Surgery, Inselspital, Bern University Hospital, University of Bern, Freiburgstrasse 18, Bern 3010, Switzerland (e-mail: vladimir.makaloski@insel.ch).

The editors and reviewers of this article have no relevant financial relationships to disclose per the Journal policy that requires reviewers to decline review of any manuscript for which they may have a conflict of interest.

2468-4287

© 2021 The Authors. Published by Elsevier Inc. on behalf of Society for Vascular Surgery. This is an open access article under the CC BY-NC-ND license (<http://creativecommons.org/licenses/by-nc-nd/4.0/>).

<https://doi.org/10.1016/j.jvscit.2021.06.002>

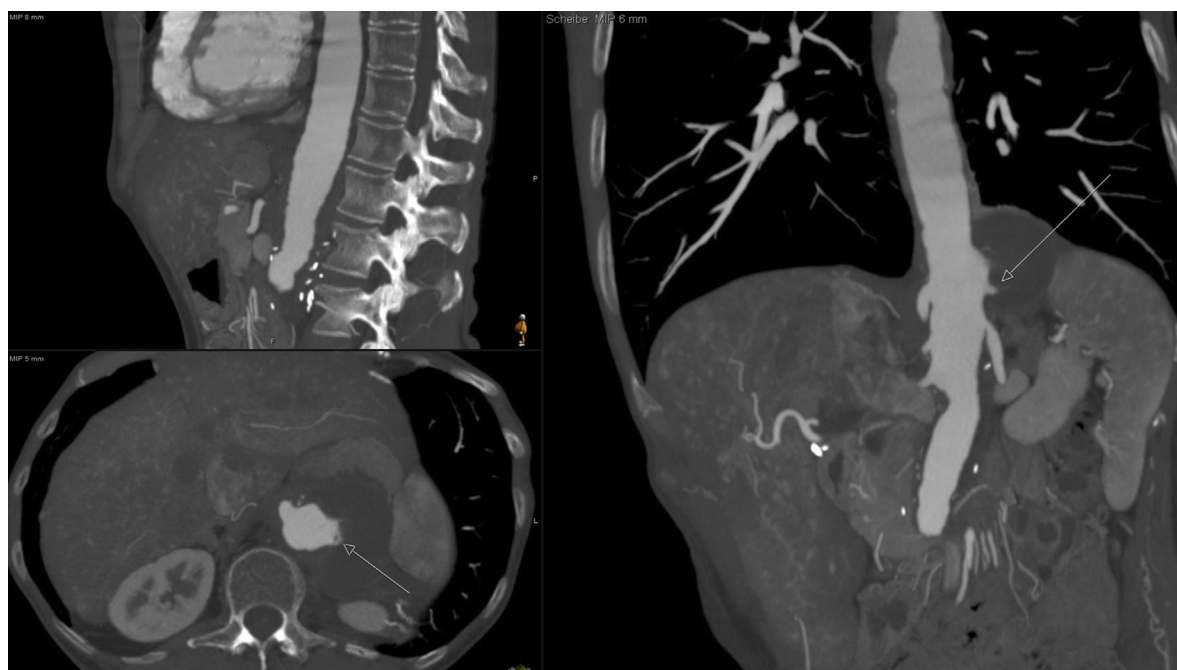


Fig 1. Multiplanar reconstruction of the coronal, axial, and sagittal planes of the preoperative computed tomography angiogram. The *arrows* mark the rupture site.

the distal end just proximal to the celiac trunk to create a sufficient landing zone for the cuff (Fig 3). Both the supra-iliac native descending aorta and the surgeon-modified pericardial tube graft had a 22- to 23-mm inner-to-inner diameter, representing moderate oversizing for both stent grafts (range, 9%-13%). We cannulated both target arteries before cuff insertion to secure access in the case of cuff malpositioning and to visualize the origin of both vessels (Fig 3). The surgeon-modified cuff was deployed with the fenestrations at the level of the target vessel and the tip capture closed (Fig 3). Through a 7F steerable sheath (Oscor Destino Twist; Oscor, Palm Harbor, Fla) from the contralateral groin, first the celiac trunk and then the left renal artery were cannulated and bridged with balloon-expandable covered stents (Advanta V12; Getinge, Gothenburg, Sweden), 7 × 22 mm for the celiac trunk (vessel diameter, 6 mm) and 6 × 22 mm for the left renal artery (vessel diameter, 5 mm). Both stents were flared with an 8 × 20-mm balloon.

The final angiogram and CTA on postoperative day 2 demonstrated complete aneurysm exclusion, without signs of an endoleak and a perfused celiac trunk and left renal artery without any stent issues (Fig 4). Both percutaneous groin accesses required surgical revision on postoperative day 1 because of stenosis of the

common femoral artery caused by the closure devices. The patient was discharged home on postoperative day 5. A follow-up CTA at 6 months showed complete aneurysm exclusion and patent target vessels.

The patient gave written informed consent for the publication of her case details and images.

DISCUSSION

We have reported the case of a patient with a contained rupture of an anastomotic pseudoaneurysm after previous type IV open thoracoabdominal aortic repair. The patient was successfully treated with a surgeon-modified fenestrated stent-graft. Although endovascular aneurysm repair with off-the-shelf stent-grafts is preferred for the treatment of ruptured infrarenal aneurysms, the endovascular treatment options are limited for emergent cases presenting with ruptured aortic aneurysms involving the visceral segment.¹ Custom-made fenestrated or branched stent-grafts will not be immediately available owing to the long manufacturing time of 4 to 8 weeks. Open repair might be an option for some patients. However, the mortality for urgent aortic repair involving the visceral segment has remained high. Endovascular aneurysm repair using a chimney or snorkel technique could be a feasible option.² However, the use of parallel stent-grafts in the

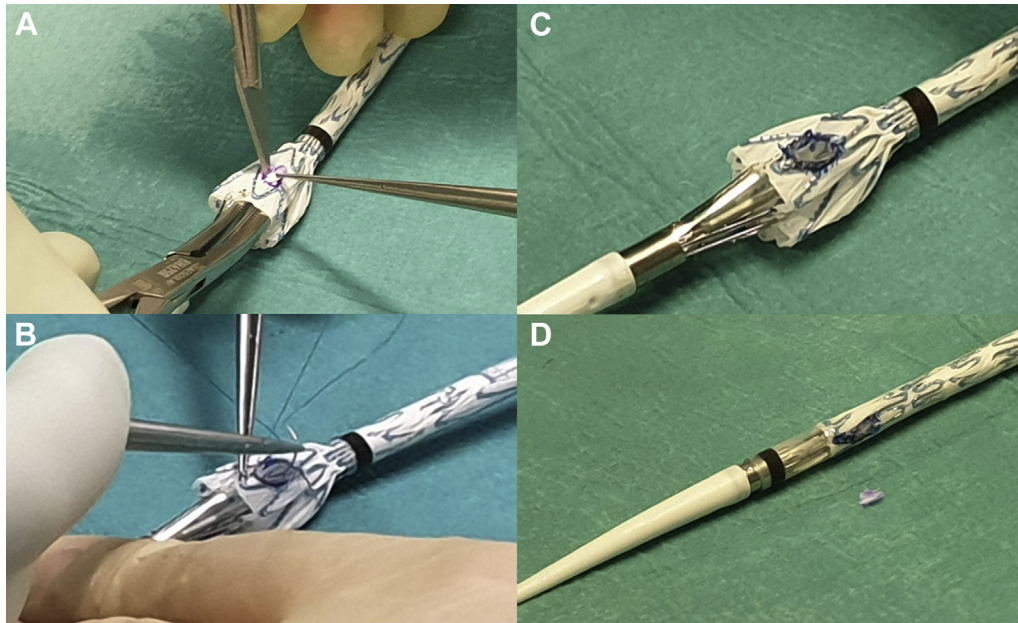


Fig 2. Ex situ preparation of the fenestration for the celiac artery. **A**, Cutting of the fenestration with the scalpel. **B**, Suturing a snare ring around the fenestration. **C**, Complete fenestration. **D**, Fenestration after resheathing.

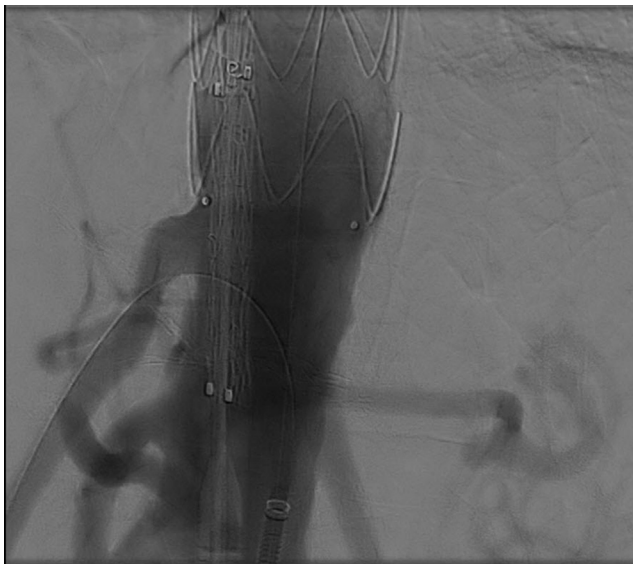


Fig 3. Deployment of the thoracic stent graft showing the custom-made stent graft in place and the celiac artery cannulated.

visceral segment require bilateral upper extremity access, which results in a higher stroke rate and an additional risk of type Ia endoleaks compared with the use of fenestrated stent-grafts.² Surgeon-modified fenestrated stent-graft aortic repair is an alternative endovascular approach in these situations.³ In our patient, we used a thoracic stent-graft to create a landing

zone for the surgeon-modified aortic cuff, both of which were available as off-the-shelf products. We have used the Medtronic stent-grafts regularly for elective and emergency abdominal and thoracic cases for the previous 20 years. It is essential to know the stent-graft with all its disadvantages, before starting with a surgeon modification. For the present patient, we modified an aortic cuff, because it is shorter than a thoracic stent-graft and can, therefore, be deployed more accurately and safely. By cannulating the target vessel and placing the bridging stents with the use of a steerable sheath from the groin, no upper extremity access was necessary, thus reducing the risk of stroke and bleeding from the upper extremity access. When more than one surgeon-modified fenestration will be used, such as in the present case, the correct creation of the fenestrations in the stent-graft and its precise deployment can be technically demanding. A recent study of surgeon-modified fenestrated stent-grafts for the treatment of acute juxtarenal and thoracoabdominal aortic aneurysms reported that the 30-day mortality rate had decreased significantly from the first half of the patients compared with the second half, confirming the learning curve for such treatment.⁴ Nevertheless, a back-table surgeon-modified fenestrated endovascular aortic repair could be a possible treatment option for emergency cases for which repeat open repair would be of highest risk and a custom-made fenestrated stent-graft would require too long for manufacture.

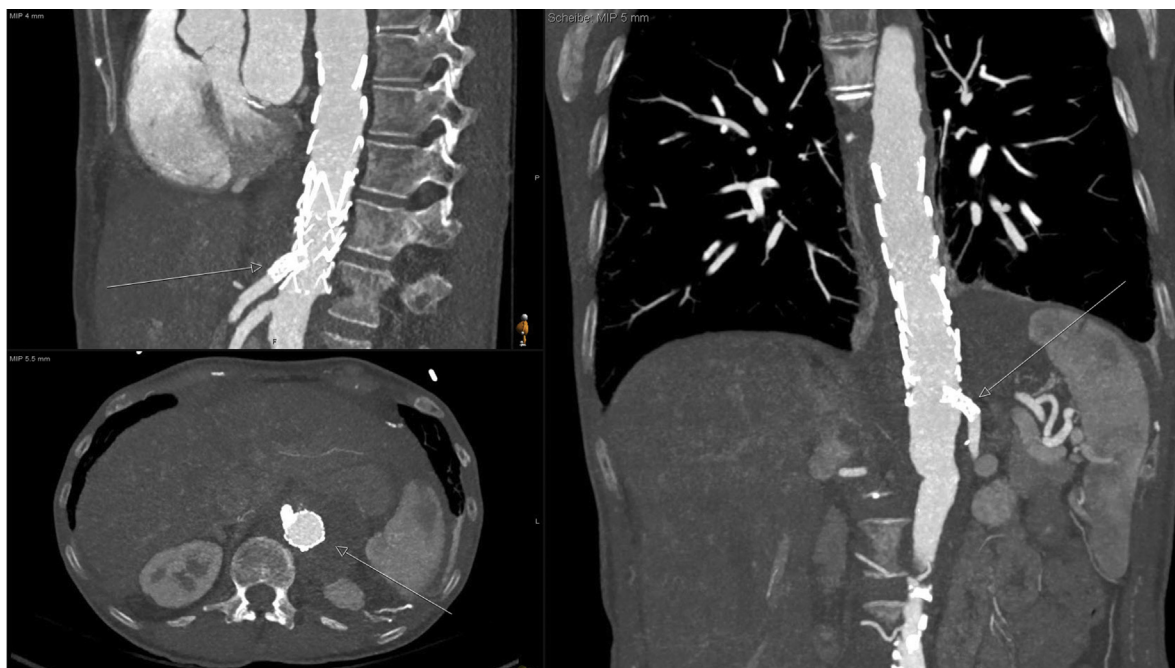

Fig 4. Postoperative computed tomography angiogram showing the correct position of the custom-made stent-graft and the stent-grafts for the celiac artery (*arrow*) and left renal artery (*arrow*) with complete aneurysm sealing (*arrow*) and no signs of an endoleak.

REFERENCES

1. Kontopodis N, Galanakis N, Antoniou SA, Tsetis D, Ioannou CV, Veith FJ, et al. Meta-analysis and meta-regression analysis of outcomes of endovascular and open repair for ruptured abdominal aortic aneurysm. *J Vasc Surg* 2020;71:1451.
2. O'Donnell TFX, Patel VI, Deery S, Li C, Swerdlow NJ, Liang P, et al. The state of complex endovascular abdominal aortic aneurysm repairs in the Vascular Quality Initiative. *J Vasc Surg* 2018;67:e98.
3. Ricotta JJ, Tsilimparis N. Surgeon-modified fenestrated-branched stent grafts to treat emergently ruptured and symptomatic complex aortic aneurysms in high-risk patients. *J Vasc Surg* 2012;56:1535-42.
4. Juszcak MT, Vezzosi M, Khan M, Mascaro J, Claridge M, Adam D. Endovascular repair of acute juxtarenal and thoracoabdominal aortic aneurysms with surgeon-modified fenestrated endografts. *J Vasc Surg* 2020;72:435-44.

Submitted Dec 16, 2020; accepted Jun 11, 2021.