

Combination therapy of low-fluence photodynamic therapy and intravitreal ranibizumab for choroidal neovascular membrane in choroidal osteoma

Rodney J Morris, Varsha V Prabhu, Parag K Shah, V Narendran

Choroidal osteoma is an unusual form of intraocular calcification seen in otherwise healthy eyes. It is a benign idiopathic osseous tumor of the choroid, typically seen in young females. Choroidal neovascular membrane (CNVM) is a complication seen in one-third of these patients and carries a poor visual outcome. We report a case of a 25-year-old hyperthyroid female with choroidal osteoma and subfoveal CNVM in her left eye which was successfully treated using low-fluence photodynamic therapy (PDT) with verteporfin followed by a single injection of intravitreal ranibizumab.

Key words: Low-fluence photodynamic therapy, choroidal neovascular membrane, choroidal osteoma, ranibizumab

Cite this article as: Morris RJ, Prabhu VV, Shah PK, Narendran V. Combination therapy of low-fluence photodynamic therapy and intravitreal ranibizumab for choroidal neovascular membrane in choroidal osteoma. *Indian J Ophthalmol* 2011;59:394-6.

Access this article online

Quick Response Code:



Website:

www.ij.o.in

DOI:

10.4103/0301-4738.83622

Choroidal osteoma is a rare, benign ossifying tumor of the choroid of unknown etiology, seen in healthy young females in the second or third decade of life.^[1] The tumor is unilateral in 75% of cases and is located in a juxtapapillary or peripapillary location. Rarely, it is confined to the macula only.^[2]

It is yellowish-white in color, relatively flat (up to 2.5 mm thick), around 2–22 mm in basal dimensions, and round or oval in shape with geographic or scalloped edges.^[3]

Growth, decalcification, subretinal fluid, hemorrhage, and choroidal neovascular membrane (CNVM) are known complications of choroidal osteoma. CNVM is seen in one-third of patients^[4] and is a major cause of visual impairment.

Department of Retina and Vitreous, Aravind Eye Hospital and Postgraduate Institute of Ophthalmology, Coimbatore – 641 014, Tamilnadu, India

Correspondence to: Dr. Rodney J. Morris, Department of Retina and Vitreous, Aravind Eye Hospital, Avinashi Road, Coimbatore- 641 014, Tamil Nadu, India. E-mail: rodneyjmorris@gmail.com

Manuscript received: 04.11.09; Revision accepted: 23.09.10

The cause for CNVM is speculative but it is postulated that neovascular fronds from choroid grow through the thinned degenerated Retinal Pigment Epithelium (RPE)–Bruch's membrane complex overlying the osteoma.^[5] Argon laser photocoagulation is difficult due to lack of melanin in the tumor, and also, the potential for hemorrhage and disciform scarring is more.

In this case report, we present a case of a young female patient presenting with unilateral osteoma with secondary CNVM treated with combination therapy of low-fluence photodynamic therapy (PDT), followed by a single injection of intravitreal ranibizumab.

Case Report

A 25-year-old lady presented with progressive defective vision in the Left Eye (LE) of 3-month duration. She was a known case of hyperthyroidism and was on medical treatment for the same. There was no history of any previous ocular trauma.

Ocular examination revealed best corrected visual acuity (BCVA) of 20/20 in the Right Eye (RE) and 20/80 in the LE. The pupillary reactions and slit-lamp biomicroscopic examination of the anterior segment were normal in both eyes. Fundus examination of the RE was normal, while the LE showed a yellowish-orange lesion of 1 disc diameter (DD) having well-defined scalloped margins with pseudopod extensions superiorly and subretinal hemorrhage in the fovea [Fig. 1a]. Fundus fluorescein angiography (FFA) showed an area of delineation of around 1 DD in the foveal avascular zone. It also revealed a lacy pattern of early hyperfluorescence with leakage of dye in the late phase suggestive of classic CNVM along with blocked fluorescence temporally due to hemorrhage [Fig. 1b]. RE was angiographically normal. Optical coherence tomography confirmed the presence of the subfoveal CNVM with fluid and central macular thickness (CMT) of 203 μ m [Fig. 1c]. B-scan ultrasonography showed a highly reflective mass lesion around 2 mm in basal dimension in the posterior pole and shadowing of orbital soft tissues posterior to the lesion. A-scan ultrasonography showed a high spike corresponding to the anterior surface of the lesion suggestive of choroidal osteoma [Fig. 2]. Thus we came to a clinical diagnosis of choroidal osteoma with secondary subfoveal CNVM.

Subfoveal classic nature of CNVM prompted us to treat the patient with combination therapy, i.e., low-fluence PDT followed by an intravitreal injection of ranibizumab 48 h later. After an informed written consent and physician fitness, low-fluence PDT with a light dose 25 J/cm², power 300 mw/cm², exposure time of 83 s, and spot size of 3100 μ m as per standard low-fluence specifications was given. Forty-eight hours post-PDT, 0.5 mg intravitreal ranibizumab (Lucentis; Novartis, India) was injected in the same eye under aseptic precautions. The patient was reviewed 4 weeks postinjection and her BCVA improved to 20/20. Fundus examination showed absorbed hemorrhage and resolved CNVM [Fig. 3a]. FFA showed minimal hyperfluorescence with staining in the late phase suggestive of scarring [Fig. 3b]. OCT showed that CMT reduced to 166 μ m with the resolved fluid [Fig. 3c]. At 15-month follow-up, FFA showed regressed, scarred CNVM [Fig. 4a] and OCT [Fig. 4b] showed dry macula. She maintained the good vision.

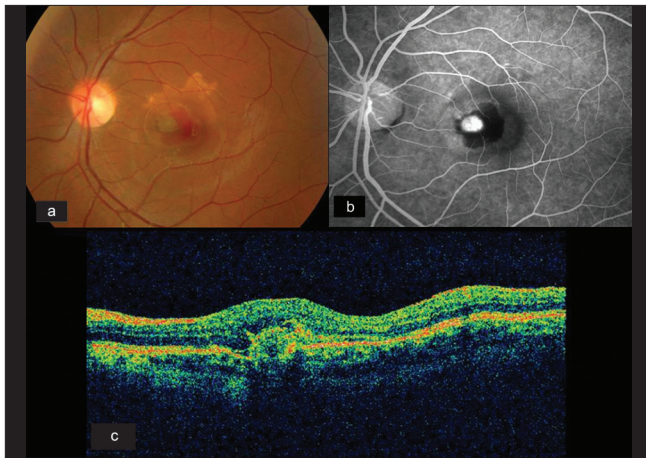


Figure 1: (a) Fundus photograph of the left eye showing yellowish-orange lesion with scalloped margins and pseudopod borders and subretinal hemorrhage in fovea. (b) Late phase angiography shows intense leakage of the dye and blocked fluorescence from hemorrhage suggestive of CNVM. (c) Oblique OCT scan showing subfoveal hyperreflectivity in the RPE layer with the fluid suggestive of CNVM

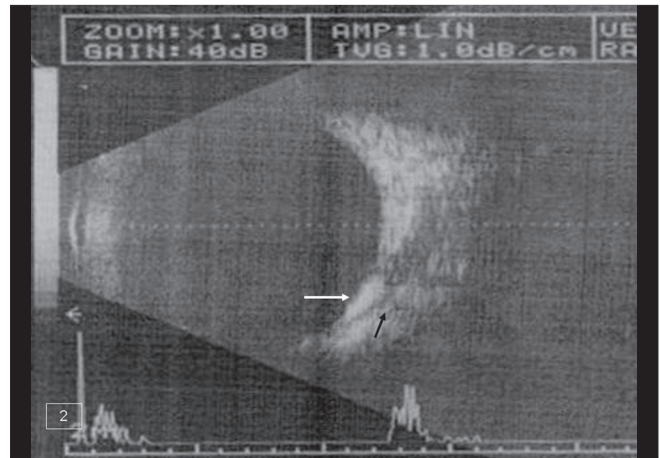


Figure 2: Ultrasound B-scan showing hyperreflective mass lesion in the posterior pole (white arrow) with aftershadowing of orbital soft tissue posterior to it (black arrow) suggestive of choroidal osteoma

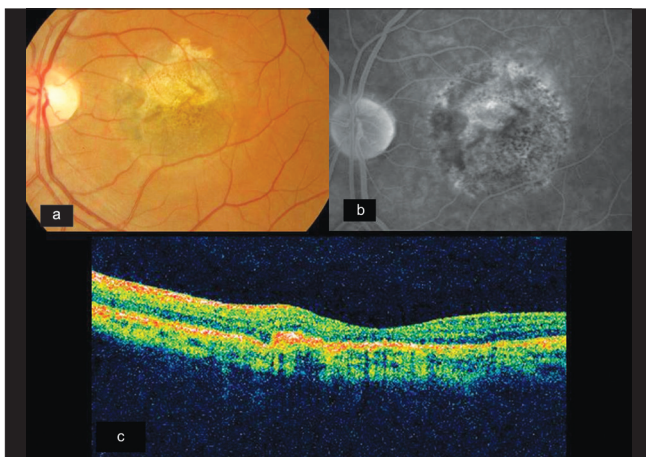


Figure 3: (a) Fundus photograph of the same eye showing absorbed hemorrhage and resolved CNVM posttreatment. (b) Late phase angiogram showing an absence of leakage and staining of scar tissue posttreatment. (c) Oblique OCT scan suggesting hyperreflectivity in the RPE layer and the absence of the fluid indicating scarred CNVM posttreatment

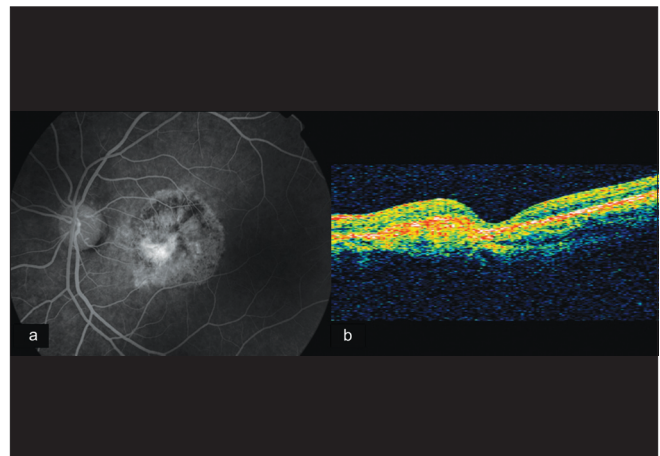


Figure 4: (a) 15-month follow-up FFA showing a scarred, inactive CNVM. (b) Horizontal transverse OCT scan showing a scarred CNVM with a normal foveal contour and absence of fluid

Discussion

Forty-seven percent cases of choroidal osteoma develop CNVM by 10 years and 56% by 20 years.^[4] It carries a dismal prognosis. PDT has successfully caused closure of extrafoveal CNVM in choroidal osteoma.^[6] CNVM in osteoma is subretinal in location and PDT causes selective closure of CNVM (angio-occlusion) and acts independent of intrinsic pigmentation of the tumor. Using low fluence, we intend to cause minimal damage to overlying neurosensory retina, adjacent choriocapillaries, and thinned RPE-Bruch's membrane complex. Post-PDT, there is an upregulation of vascular endothelial growth factor (VEGF) and pigment epithelium derived factor (PEDF) which has varied implications.^[7] PEDF limits hypoxia-induced retinal

damage allowing surrounding choroidal vessel recovery and VEGF upregulation causes recurrent growth of CNVM beginning a week post-PDT. Multiple anti-VEGF injections have been reported to cause Bruch's membrane rupture in conditions where the Bruch's membrane is calcified and brittle.^[8] Combination therapy reduces the number of anti-VEGF injections, hence reducing the risk of vision-threatening complications. Strategies to combat the post-PDT spike of VEGF increases effectiveness of PDT. Bevacizumab has shown to be an effective alternative to manage secondary CNVM in choroidal osteoma,^[9] but it lacks Food and Drugs Administration (FDA)'s approval. Ranibizumab is a monoclonal antibody derived from the same parent murine antibody as bevacizumab and also FDA-approved for treatment of CNVM in wet age-related macular degeneration (AMD). It has been successfully used both as monotherapy and in combination with PDT in the treatment of CNVM secondary to AMD.^[10] Combination therapy rationale of giving finitism to treatment along with a marked improvement in visual acuity without untoward effects following the treatment of the CNVM secondary to choroidal

osteoma has been successfully documented in our case.

A detailed search and analysis of content in medical databases like Medline and Embase failed to reveal mention of any case study illustrating successful treatment of CNVM in choroidal osteoma with combination therapy of low-fluence PDT followed by a single dose of intravitreal ranibizumab. However, a larger prospective trial with a much longer follow-up will be required to reach conclusive results.

References

1. Chen J, Lee L, Gass JD. Choroidal osteoma: Evidence of progression and decalcification over 20 years. *Clin Exp Optom.* 2006;89:90-4.
 2. Kadrmas EF, Weiter JJ. Choroidal osteoma. *Int Ophthalmol Clin* 1997;37:171-82.
 3. Shields CL, Shields JA, Augsburger JJ. Choroidal osteoma. *Surv Ophthalmol* 1988;33:17-27.
 4. Aylward GW, Chang TS, Pautler SE, Gass JD. A long-term follow-up of choroidal osteoma. *Arch Ophthalmol* 1998;116:1337-41.
 5. Grand MG, Burgess DB, Singerman LJ, Ramsej J. Choroidal osteoma. Treatment of associated subretinal neovascular membranes. *Retina* 1984;4:80-4.
 6. Battaglia Parodi M, Da Pozzo S, Toto L, Saviano S, Ravalico G. Photodynamic therapy for choroidal neovascularization associated with choroidal osteoma. *Retina* 2001;21:660-7.
 7. Schmidt-Erfurth U, Schlötzer-Schrehard U, Cursiefen C, Michels S, Beckendorf A, Naumann GO. Naumann. Influence of Photodynamic Therapy on Expression of Vascular Endothelial Growth Factor (VEGF), VEGF Receptor 3, and Pigment Epithelium-Derived Factor. *Invest Ophthalmol* 2003;44:4473-80.
 8. Sen PR, Rishi P, Sen P, Rishi E, Shroff D. Rapid progression of angioid streaks following intravitreal bevacizumab. *Can J Ophthalmol* 2009;44:p39-40.
 9. Ahmadi H, Vafi N. Dramatic response of choroidal neovascularization associated with choroidal osteoma to the intravitreal injection of bevacizumab (Avastin). *Graefes Arch Clin Exp Ophthalmol.* 2007;245:1731-3.
 10. Kumar A, Gopalakrishnan K, Sinha S. Combination photodynamic therapy and intravitreal ranibizumab in neovascular AMD in a north Indian population: A pilot study. *Retina* 2008;28:1132-7.
-