

# Central post-stroke pain due to injury of the medial lemniscus in a patient with medullary infarction

Sung Ho Jang, Hyeok Gyu Kwon\*

Central post-stroke pain (CPSP), which is neuropathic pain associated with a brain lesion following a stroke, was first described by Dejerine and Roussy in 1906 in a thalamic infarct patient (Dejerine and Roussy, 1906; Watson and Sandroni, 2016). Since then, many studies have suggested that the pathophysiological mechanism underlying CPSP is activated by injury to the somatosensory nervous system (Watson and Sandroni, 2016). There are two major pathways within the somatosensory nervous system: the spinothalamic tract (STT), which is chiefly responsible for pain and touch sensations, and the medial lemniscus (ML) pathway, which is mainly involved in proprioception and tactile discrimination (Naidich et al., 2009). Many studies have suggested that STT injury is a major pathogenetic mechanism of CPSP, but a few studies have suggested that ML injury is related to the development of CPSP (Kim and Choi-Kwon, 1999; Seghier et al., 2005; Kim, 2007; Hong et al., 2010; Jang et al., 2017).

Diffusion tensor tractography (DTT), the results of which are derived from diffusion tensor imaging (DTI), has made possible the three-dimensional reconstruction of neural tracts such as the STT and the ML pathway in the human brain (Jang and Kwon, 2013). Several DTT-based studies have demonstrated that STT injury is associated with the pathophysiological mechanism underlying CPSP in stroke patients (Hong et al., 2010; Jang et al., 2017). Hong et al. (2010) reported that STT injury was related to the presence of CPSP in 30 patients with intracerebral hemorrhage. Subsequently, Jang et al. (2017) reported that CPSP was due to STT damage in five patients with cerebral infarction. However, there are no DTT-based studies regarding the relationship between CPSP and ML injury. Therefore, in the current study, we used DTT to show ML injury in a patient with medullary infarction affecting both pyramids and both ML areas.

A 67-year-old male patient was recruited from a university hospital and he presented with quadriplegia and numbness of the right hand due to a medullary infarction that affected both pyramids and both ML areas and was related to the presence of vertebral artery stenosis (Figure 1A). His treatment included conservative management and rehabilitation. Six weeks after stroke onset, he was relocated to the department of rehabilitation at our university hospital. At that time, he presented with quadriplegia (motor weakness of all four extremities [Fair/Good]) and gait disturbance [Functional

Ambulation Category: 3.5, full score: 5]) and pain in the right upper and lower limbs and the left hand (Frese et al., 1987; Bijur et al., 2001; Cunha et al., 2002). The characteristics and severity of his pain were assessed as follows: continuous pain without allodynia or hyperalgesia and numbness (visual analog scale scores: 3 [right upper and lower limbs] and 2 [left hand]) (Bijur et al., 2001). Brain magnetic resonance images obtained 6 weeks after onset showed leukomalactic lesions in both pyramids and both ML areas in the medulla (Figure 1A). Motor-evoked potentials were obtained from the tibialis anterior; latency and amplitudes for the right hemisphere were 31.1 ms and 1.3 mV, respectively, while those for the left hemisphere were 32.3 ms and 1.0 mV, respectively. In addition, somatosensory-evoked potentials were obtained from the posterior tibial nerve. The P37 and N45 latencies of the right hemisphere were 42.8 and 50.3 ms, respectively, while those for the left hemisphere were 37.7 and 48.2 ms, respectively. An electromyographic study showed no evidence of radiculopathy or peripheral neuropathy. A normal subject (68-year-old male) was recruited from the same university hospital. Signed informed consent was obtained from the patient and a healthy subject, and the study protocol was approved by the Institutional Review Board of Yeungnam University Hospital (YUMC 2019-06-032) on June 21, 2019.

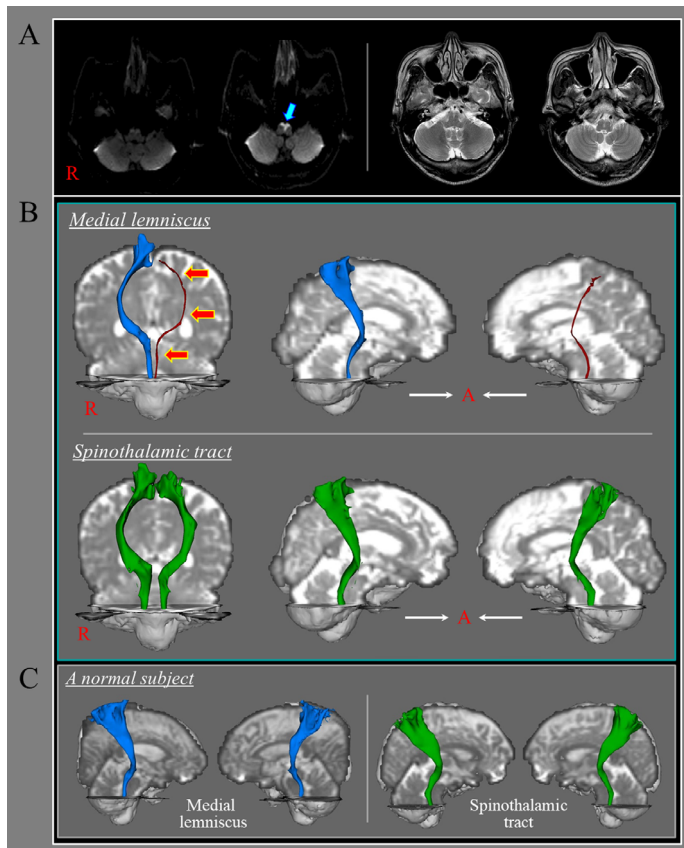
At 6 weeks after infarct onset, DTI data were acquired using a six-channel head coil on a 1.5T Philips Gyrosan Intera (Philips, Ltd., Best, the Netherlands) with 32 gradients. Imaging parameters were as follows: acquisition matrix = 96 × 96; reconstructed to matrix = 192 × 192; field of view = 240 × 240 mm<sup>2</sup>; repetition time = 10,398 ms; echo time = 72 ms; parallel imaging reduction factor = 2; echo-planar imaging factor = 59; b = 1000 s/mm<sup>2</sup>; and slice thickness = 2.5 mm. Probabilistic tractography as provided in the default tractography option in Brain Diffusion Software of Oxford Centre (Oxford University, Oxford, UK) for Functional Magnetic Resonance Imaging was used to perform fiber tracking. For ML and STT reconstruction, seed regions of interest (ROIs) were positioned in accordance with the reported anatomy at the level of the medulla (ROI for ML: medio-posterior to the pyramid in the medulla, ROI for STT: posterior to the inferior olivary nucleus and anterior to the inferior cerebellar peduncle in the medulla) (Jang and Kwon, 2013). The target ROI was placed on the area of

the ventro-postero-lateral nucleus of the thalamus and the primary somatosensory cortex (Jang and Kwon, 2013).

At 6 weeks post-onset, DTT was able to fully reconstruct the STT in both hemispheres. In contrast, DTT reconstruction revealed that the left ML pathway was thinner than the right ML pathway (Figure 1B).

In the current study, we investigated the state of the STT and the ML pathway in a patient with CPSP in the right upper and lower limbs and the left hand following medullary infarction affecting both pyramids and both ML areas. At 6 weeks post-onset, DTT revealed that the left ML pathway was thinner than the right pathway, suggesting an injury of the left pathway due to the infarction in the left ML area. In contrast, the right ML and both STTs were shown to have normal configurations. Based on those results, the patient's CPSP in the right upper and lower limbs might be at least partially ascribed to the infarction in the left ML area, whereas the CPSP of the left hand might be related to the infarction in the right ML area, even though the right ML revealed a normal configuration. The difference in CPSP severity between that of both right limbs and that of the left hand only corroborates the difference in the DTT results of the left and right ML pathways.

Several studies have used DTT to demonstrate that STT injury was associated with the development of CPSP (Seghier et al., 2005; Hong et al., 2010; Jang et al., 2017). Regarding the ML, a few studies showed that a lesion related to the ML was associated with the presence of CPSP (Kim and Choi-Kwon, 1999; Kim, 2007). Kim and Choi-Kwon (1999) examined 55 patients in two groups (lateral medullary infarction (LMI) group: 41 patients; medial medullary infarction (MMI) group: 14 patients) in an investigation into sensory sequelae on the face, body, and limbs. The members of the LMI group showed numbness (10 patients), burning (9 patients), and cold (7 patients) sensations in the face, and cold (18 patients), numbness (15 patients), and burning (12 patients) sensations in the body/limbs. In contrast, the MMI group showed numbness (9 patients), squeezing (3 patients), and cold (1 patient) sensations in the body/limbs (Kim and Choi-Kwon, 1999). The authors also suggested that the sensory sequelae in the LMI group frequently had a delayed onset (up to 6 months), whereas there was immediate onset of sensory sequelae in the MMI group (Kim and Choi-Kwon, 1999). In 2007, Kim investigated a 55-year-old male patient with CPSP following both LMI (first infarct) and MMI (second infarct). After the initial LMI, which included the STT, the patient had CPSP that, gradually improved. However, his CPSP was aggravated because of the occurrence of the secondary MMI, which included the ML (Kim, 2007). Aside from those studies, to our best knowledge, this case report is the first to demonstrate an ML injury in a patient with CPSP after medullary infarction



**Figure 1 | Results of diffusion tensor tractography for the medial lemniscus and spinothalamic tract of a patient with medullary infarction.**

(A) Diffusion weighted images at onset and T2-weighted magnetic resonance (MR) images at 6 weeks after onset show medullary infarctions in both pyramids and medial lemniscus areas (blue arrow). (B) Results of diffusion tensor tractography for the medial lemniscus pathway and spinothalamic tract at 6 weeks after onset. The left medial lemniscus pathway is thinner (orange arrows) than the right medial lemniscus pathway and those of a normal subject spinothalamic tract reveals a normal configuration in both hemispheres compared with those of a normal subject (68-year-old male) who recruited the same university hospital. (C) The medial lemniscus pathway and spinothalamic tract of a normal subject.

using DTT. However, limitations of this study should be considered. First, although the CRPS mainly occurred because of injury of the somatosensory nervous system, it should be also considered with various factors. Second, DTT results can be affected by the DTI scanning conditions; moreover, analysis of DTT results is operator dependent. Third, both false-positive and false-negative DTT results can occur throughout the white matter of the brain due to the presence of partial volume effects and complex fiber configurations including crossing or ‘kissing’ fibers.

In conclusion, using DTT, we demonstrated ML pathway injury in a patient with CPSP following medullary infarction. Our results suggest that DTT-based evaluation of the ML pathway can be helpful in elucidating the pathophysiological mechanism of CPSP in stroke patients. However, because this is a single case report, further studies involving larger numbers of patients should be conducted to substantiate the results described herein.

**Sung Ho Jang, Hyeok Gyu Kwon\***

Department of Physical Medicine and Rehabilitation, College of Medicine, Yeungnam

University, Daegu, Republic of Korea (Jang SH) Department of Physical Therapy, College of Health Science, Eulji University, Seongnam, Republic of Korea (Kwon HG)

\*Correspondence to: Hyeok Gyu Kwon, PhD, khg0715@hanmail.net.

<https://orcid.org/0000-0002-6654-302X>

(Hyeok Gyu Kwon)

**Date of submission:** December 23, 2019

**Date of decision:** January 19, 2020

**Date of acceptance:** August 10, 2020

**Date of web publication:** December 12, 2020

<https://doi.org/10.4103/1673-5374.301036>

**How to cite this article:** Jang SH, Kwon HG (2021)

Central post-stroke pain due to injury of the medial lemniscus in a patient with medullary infarction. *Neural Regen Res* 16(7):1351-1352.

**Author contributions:** Study design and conception, data acquisition, manuscript development and writing: SHJ. Data acquisition and analysis, fundraising, manuscript writing, and technical support: HGK. Both authors approved the final version of this paper.

**Conflicts of Interest:** Both authors report no disclosures relevant to the manuscript.

**Financial support:** This work was supported by a grant from Eulji University in 2019 (to HGK).

**Institutional review board statement:** Approval for the study was obtained from the Institutional

Review Board of Yeungnam University Hospital (YUMC 2019-06-032) on June 21, 2019.

**Declaration of participant consent:** Both authors certify that they have obtained the appropriate participant consent form. In the form, the participants have given their consent for their images and other clinical information to be reported in the journal. The participants understand that their names and initials will not be published and due efforts will be made to conceal their identity.

**Reporting statement:** This study followed the CARE REport (CARE) statement.

**Biostatistics statement:** No statistical method was used in this study.

**Copyright license agreement:** The Copyright License Agreement has been signed by both authors before publication.

**Data sharing statement:** Datasets analyzed during the current study are available from the corresponding author on reasonable request.

**Plagiarism check:** Checked twice by iThenticate.

**Peer review:** Externally peer reviewed.

**Open access statement:** This is an open access journal, and articles are distributed under the terms of the Creative Commons Attribution-NonCommercial-ShareAlike 4.0 License, which allows others to remix, tweak, and build upon the work non-commercially, as long as appropriate credit is given and the new creations are licensed under the identical terms.

## References

- Bijur PE, Silver W, Gallagher EJ (2001) Reliability of the visual analog scale for measurement of acute pain. *Acad Emerg Med* 8:1153-1157.
- Cunha IT, Lim PA, Henson H, Monga T, Qureshy H, Protas EJ (2002) Performance-based gait tests for acute stroke patients. *Am J Phys Med Rehabil* 81:848-856.
- Dejerine J, Roussy J (1906) Le syndrome thalamique. *Review Neurology* 14:521-532.
- Frese E, Brown M, Norton BJ (1987) Clinical reliability of manual muscle testing. Middle trapezius and gluteus medius muscles. *Phys Ther* 67:1072-1076.
- Hong JH, Bai DS, Jeong JY, Choi BY, Chang CH, Kim SH, Ahn SH, Jang SH (2010) Injury of the spino-thalamo-cortical pathway is necessary for central post-stroke pain. *Eur Neurol* 64:163-168.
- Jang SH, Kwon HG (2013) Anatomical location of the medial lemniscus and spinothalamic tract at the pons in the human brain: a diffusion tensor tractography study. *Somatosens Mot Res* 30:206-209.
- Jang SH, Lee J, Yeo SS (2017) Central post-stroke pain due to injury of the spinothalamic tract in patients with cerebral infarction: a diffusion tensor tractography imaging study. *Neural Regen Res* 12:2021-2024.
- Kim JS (2007) Medial medullary infarct aggravates central poststroke pain caused by previous lateral medullary infarct. *Eur Neurol* 58:41-43.
- Kim JS, Choi-Kwon S (1999) Sensory sequelae of medullary infarction: differences between lateral and medial medullary syndrome. *Stroke* 30:2697-2703.
- Naidich TP, Duvernoy HM, Delman BN, Sorensen AG, Kollias SS, Haacke EM (2009) Duvernoy's Atlas of the Human Brain Stem and Cerebellum. High-Field MRI: Surface Anatomy, Internal Structure, Vascularization and 3D Sectional Anatomy. Springer, Vienna.
- Seghier ML, Lazeyras F, Vuilleumier P, Schnider A, Carota A (2005) Functional magnetic resonance imaging and diffusion tensor imaging in a case of central poststroke pain. *J Pain* 6:208-212.
- Watson JC, Sandroni P (2016) Central neuropathic pain syndromes. *Mayo Clin Proc* 91:372-385.

C-Editor: Zhao M; S-Editor: Li CH; L-Editor: Song LP; T-Editor: Jia Y