

## Open interlocked nailing without a targeting device or X-ray guidance for non-union of the femur: a case series

Alfred O. Ogbemudia · Anire Bafor ·  
Efosa Igbinovia · Peter E. Ogbemudia

Received: 21 January 2009 / Accepted: 13 September 2010 / Published online: 29 September 2010  
© The Author(s) 2010. This article is published with open access at Springerlink.com

**Abstract** From October 2005 to August 2007, we operated on six patients who had femoral non-unions and performed interlocked intramedullary nailing without X-ray guidance or a targeting device. There were three fractures of the distal femur, two fractures of the mid-shaft and one of the proximal femur. Fatigue failure of a non-interlocked Kuntscher nail and one nail migration were the presenting features in two patients. The presence of sclerosis of the bone ends in four cases and a need for cancellous bone grafts at the site of non-union in all patients made wide dissection and open reduction unavoidable. There was a limb length discrepancy in all patients before surgical intervention. Partial weight bearing was commenced at 6 weeks post-operation. There was no case of wound infection. There was no misplaced screw. Minimum range of knee flexion was 105° at 2 months post-operation. These early results call for a closer look at this cheap, safe and effective means of handling femoral non-union in third world societies where there is paucity of instrumentation and implants for interlocked nailing.

**Keywords** Kuntscher nail · Interlocked intramedullary nailing · Femur · Cortical window

### Introduction

Interlocked intramedullary nailing is a standard technique for internal fixation of femoral fractures. It has the capacity

to prevent malrotation, shortening and angulation of comminuted femoral fractures [1]. Cost of the C-arm X-ray machine, instrumentation and implants as well as the absence of a safe and readily affordable alternative technique of using interlocked nails have made this excellent fixation method inaccessible to most patients in many third world countries. Until there is improved health care financing and spending in these societies, where a significant percentage live on less than one US dollar per day [2], patients and orthopaedic trauma care providers do not have any hope of affording state of the art facilities for interlocked intramedullary nailing in the foreseeable future.

The practice of intramedullary nailing in a number of developing countries has remained to a large extent limited to the reamed intramedullary nailing technique popularized by Kuntscher [3]. In those hospitals where image intensifiers are available via donor agencies, accessories such as lead jackets, dosimeters and related requirements for safety may not be within reach. The risk of radiation injury to health personnel may be unquantifiable in such settings. Besides, overexposure to such radiation may have deleterious effect on surgeons, operating room personnel as well as patients [4–6].

The alternative is non-operative treatment, but non-union of femoral fractures is a common complication of traditional bone-setter treatment in developing countries such as Nigeria [7]. Prolonged immobilization is a likely cause of osteoporosis in these patients presenting with non-union. In severely osteoporotic bones, internal fixation with plate and screws may increase the risk of implant failure due to loosening.

Adjuvant to the treatment of non-unions is bone grafts which will help to re-vitalize the site of atrophic non-union. A newer method such as the use of shockwaves is not as effective in atrophic non-union as in hypertrophic

---

A. O. Ogbemudia (✉) · A. Bafor · E. Igbinovia ·  
P. E. Ogbemudia  
Department of Orthopaedics and Trauma, University of Benin  
Teaching Hospital, Benin City, Edo State, Nigeria  
e-mail: alfredoghgho@yahoo.com

non-union [10]. Avoidance of macro-motion through stable internal fixation is also desirable in achieving union [8, 9]. To this end, interlocked intramedullary nailing combines the biomechanical advantages of nailing with some of the anti-rotation ability of plate and screws but without the associated impairment to the periosteal blood supply. The good results reported following the use of unlocked intramedullary nails notwithstanding [3]; a safe, affordable and effective way of carrying out an interlocked intramedullary nailing procedure in the absence of image intensifiers, targeting devices and fracture tables is needed for units where these facilities are not routinely available. To this end, we used an anterolateral cortical window to facilitate distal locking. A second nail of equal length was used as a template and guide for proximal locking and determining the site of the anterolateral cortical window. We report our experience with interlocked intramedullary nailing without assistance of X-ray image intensification, a fracture table or targeting device in an orthopaedic centre in a developing country (Table 1).

## Materials and methods

All patients presenting with non-union of diaphyseal and meta-diaphyseal femoral fractures (fractures sited 7.5 cm proximal to the articular surface of the femoral condyle or 7.5 cm distal to the tip of the greater trochanter) who gave informed consent for interlocked intramedullary nailing during the period between October 2005 and April 2007 were included in this review. Patients who refused consent were treated with plate and screws or the unlocked Kuntscher intramedullary nail (K-nail). Standard K-nails of sizes 12 and 13 were converted to interlocking nails by drilling one hole at the proximal end (The hole was placed obliquely at 130° to the long axis of the nail and started at 2 cm below the end of the slot for extraction) and two holes at the distal end. The nail was then sterilized by autoclaving. The two distal holes were regarded as necessary to minimize the risk of angulation of the distal fragment in a

meta-diaphyseal fracture. The age and sex of the patients were noted. The perioperative data included degree of knee flexion before surgery and at 8 and 20 weeks after operation; the operation time; estimated blood loss (EBL) during surgery; blood loss from the wound drain; type of anaesthesia; time spent applying the interlocking screws; length of hospital stay and the incidence of implant failure. In the perioperative period and during follow-up, the occurrence of complications such as wound infections, malrotation, inaccurate placement of interlocking screws or neurovascular injury was noted. Of the five patients who refused consent, two insisted on traditional treatment by bone setters. The remaining three were treated with the conventional Kuntscher nails.

## Modification of the Kuntscher nail

The proximal 130° hole was created as individual transverse holes on opposite sides of an oblique line that subtended an angle of 130° to the axis of the nail. The holes were then gradually widened by a 5-mm carbon-tipped drill, connected and aligned. The inferior transverse holes were simply drilled perpendicular to the long axis of the nail.

## Operative procedure

The procedures were done under epidural anaesthesia. The limb was adducted to the extent that the ipsilateral popliteal fossa lays over the contralateral knee to ease access to the proximal end of the intramedullary canal through the piriformis fossa. Through a surgical exposure and under direct vision, the ends of the fragments on either side of the non-union were nibbled to free them of fibrous tissue. A smooth tipped 2-mm guide wire was introduced into the proximal fragment through the piriform fossa. The intramedullary canal was reamed over the guide wire with hollow reamers, to a size higher than the size of the nail intended for fixation, until the tip of the reamer became visible at the fracture site. The distal fragment was canalized using reamers of appropriate size. A modified Kuntscher nail, of appropriate length, was threaded over the guide-wire and advanced until only a finger-breadth of the nail was palpable above the piriform fossa. The longitudinal slit in the nail was directed posteriorly. Another nail of equal length was placed parallel to the one in the intramedullary cavity and used as a rough guide to the likely site for interlocking screws placement. A 5 cm incision was made over the site. The intramedullary cavity of the distal end femur was exposed through a longitudinal anterolateral cortical window, measuring about 1 cm by 0.5 cm, which was made on the lateral condyle. With the aid of a 1-mm Kirschner wire with the tip slightly bent, the site of each hole on the nail was identified. A 3.2-mm drill

**Table 1** Details of the patients and results of interlocked nailing of the femur

No.	Age/sex	Fracture site	Initial care	Implant type	Outcome
1	23/F	Distal femur	Traction	M–K nail	Union
2	24/F	Distal femur	TBS	M–K nail	Union
3	65/M	Middle third	TBS	M–K nail	Union
4	28/F	Upper femur	K-nail	M–K nail	Union
5	28/M	Distal femur	TBS	M–K nail	Union
6	39/M	Middle third	K-nail	M–K nail	Union

*M–K nail* modified kuntscher nail, *TBS* traditional bone setter

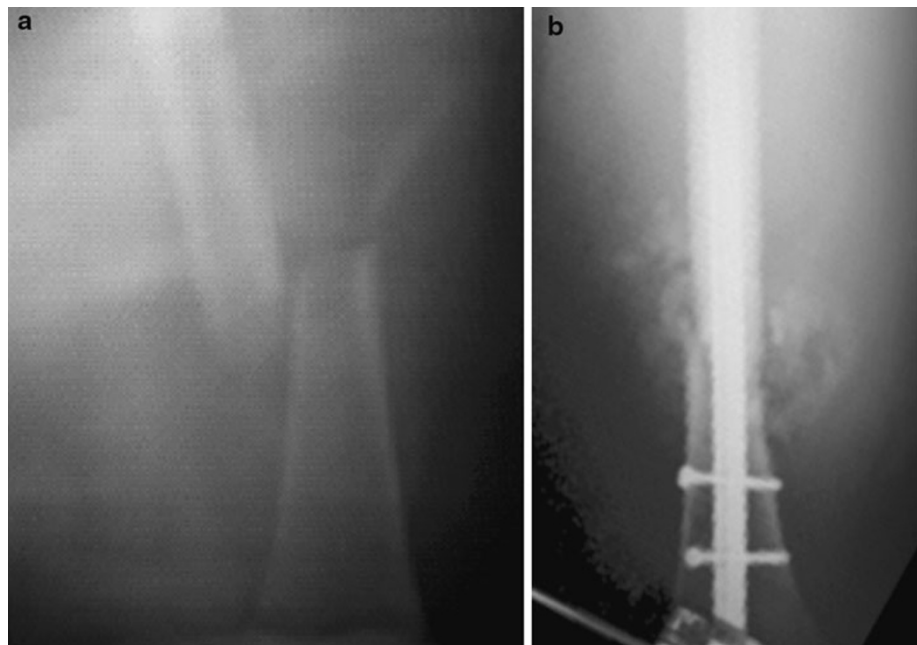
bit was used to drill through the near cortex and the far cortex with the drill bit passing through the hole in the nail. A 4.5-mm tap was used to tap the holes, and a 4.5-mm cortical screw was placed across as an interlocking screw. The same procedure was repeated for the next hole. With the aid of the similar nail, the lateral part of the oblique proximal hole was targeted, and a 2-mm Kirschner wire (K-wire) was drilled through the bone and the lateral part of the hole at 130 degrees to the axis of the nail. The presence of the Kirschner wire in the lumen of the nail was confirmed by a probe placed into the lumen of the nail. The hole made by the K-wire was drilled with a 3.2-mm drill bit, and a self-tapping malleolar screw was used as the proximal locking screw. Post-operative antibiotics, analgesics and anticoagulants were given. The operated limb was elevated on a pillow for 5 days with the knee in 15° flexion. Each drain was removed on the 2nd day post-surgery irrespective of the volume of blood in it. The patients commenced static quadriceps exercises on the 3rd day after the operation and were ambulated on a pair of axillary crutches (non-weight bearing) from the 5th day after surgery. All stitches were removed on the 14th day after operation. The patients were discharged home on the 24th day after the operation. Partial weight bearing with bilateral axillary crutches was commenced at 6 weeks after surgery and continued till the 24th week after surgery. Ambulation with the aid of a walking stick commenced at 24 weeks post-operation. X-rays were done within the first 10 days after surgery and repeated at 16, 24, 32 and 52 weeks after surgery. Union was deemed to be present when X-rays in two orthogonal planes showed the absence of a visible fracture line(s). For those patients who refused

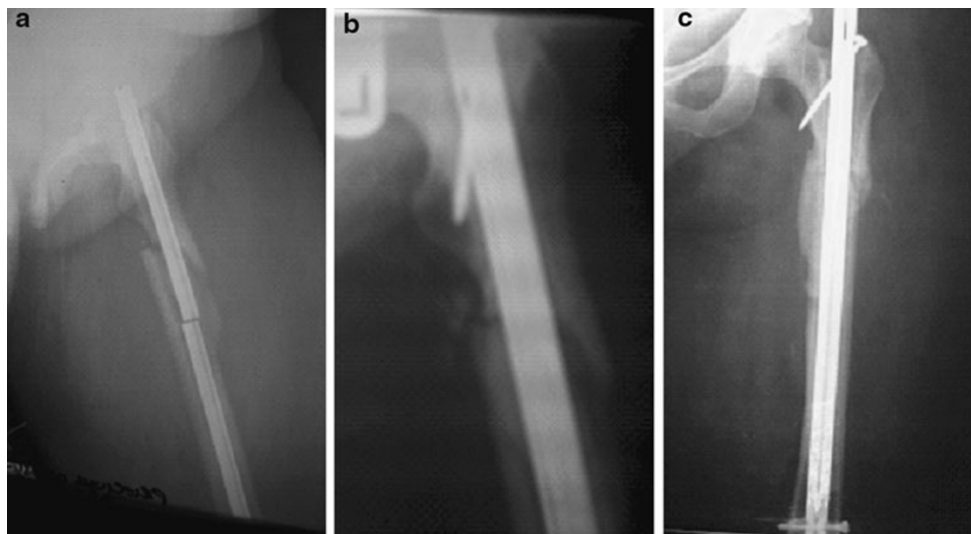
consent and had the unlocked intramedullary nailing, the major differences in post-operative care entailed the application of a plaster of Paris boot cast with an anti-rotation bar for 14 days post-operation and commencement of non-weight bearing on the 21st day after surgery. Follow-up visits continued until they were either lost to follow-up or had the implants removed.

## Results

There were three women and three men. The average age of the patients was 37 years (23–65 years). The average operation time was 142 min (110–245 min). The average blood loss at surgery was 650 ml (400–850 ml). An average of 180 ml (150–280 ml) of blood was drained in the first 24 h after surgery. There was no case of wound infection, malrotation, implant failure and non-union. There was no misplaced screw out of eighteen (Figs. 1 and 2). Placement of all screws took an average time of 72 min (52–90 min). The patients left the hospital on the 14th day post-operation (14–15th day). All the fractures went on to union within 32 weeks after surgery. Range of knee flexion was 105°–130° at 8 weeks post-operation. The shortest follow-up period was 78 weeks, and the longest was 156 weeks. The three patients who refused consent and had the unlocked intramedullary nailing were able to achieve union in 32, 52 and 64 weeks, respectively. There was some loss of reduction and proximal nail migration (Fig. 3a, b) in the patient who went on to union after a 16 month period of partial weight bearing. These patients left the hospital on the 24th day post-operation (22–27th day). The average blood loss at

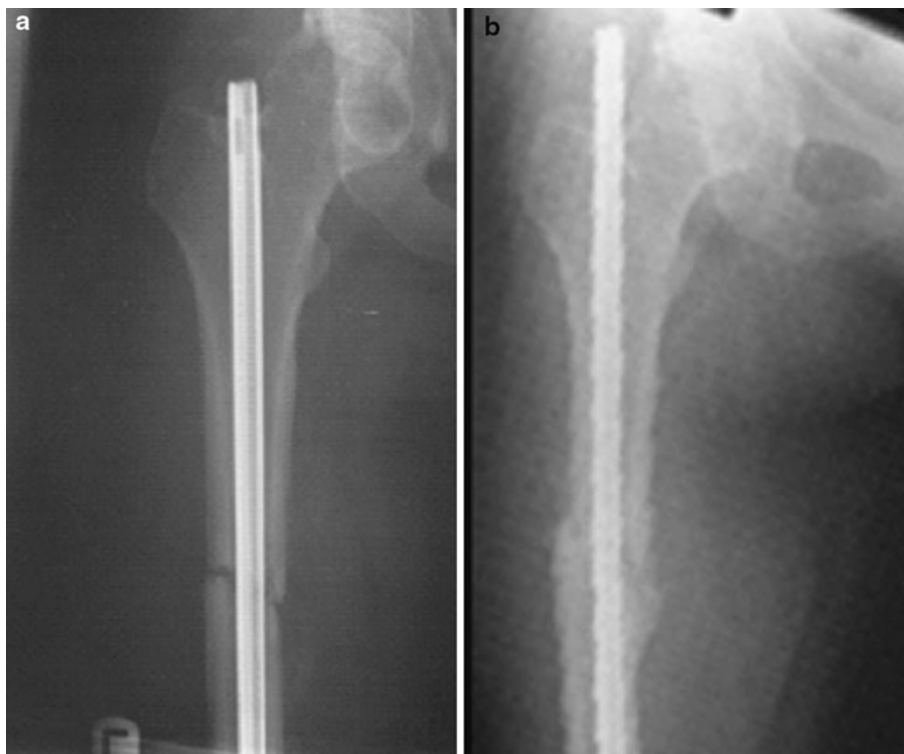
**Fig. 1** **a** Pre-operative X-rays of case 1. **b** Post-operative X-rays of case 1 (16 weeks post-operation)





**Fig. 2** **a** Pre-operative X-rays of case 4. **b** Post-operative X-rays of case 4 (4th day post-operation). **c** Post-operative X-rays of case 4 (32 weeks post-operation)

**Fig. 3** **a** X-ray of a mid-shaft femoral fracture treated without locking showing good alignment (1 week post-operation; 3 weeks post-fracture). **b** X-ray (AP view) of the same patient showing proximal nail migration and loss of some alignment in spite of ongoing callus formation (32 weeks post-operation)



surgery was 520 ml (420–600 ml). The average operation time was 108 min (90–126 min).

### Discussion

These cases represent the early results of Kuntscher intramedullary nail fixation using interlocking screws without the aid of a C-arm X-ray image intensifier, targeting device

and fracture table in our centre. The technique we have described is devoid of the risk of radiation injury to the surgeon and patient. The interlocked Kuntscher intramedullary nailing enabled us to commence ambulation in our centre on the 5th day after fixation instead of the 21st day for the unlocked Kuntscher nail. Partial weight bearing, which could have commenced from the 5th day post-operation, was deliberately delayed for 6 weeks in order to avoid the risk of implant failure; such a complication

would have brought significant financial hardship on these patients who largely live on less than one US dollar per day and would indirectly support the adherents of traditional methods of treating fractures. In addition, this technique reduced the duration of stay from 24 to 14 days. There was no loss of reduction in those who had interlocked Kuntscher nailing.

We consider this technique superior to the unlocked open Kuntscher nailing that is still frequently done in a number of developing countries [3]. A treatment option that enables a shortened hospital stay and early ambulation without compromising the quality of fixation will be of great value in low income societies where patients' preference for traditional treatment by bone setters remains popular and is a cause of non-union. Indeed, the prolonged duration of bed stay during fracture treatment in developing countries like Nigeria may be a key contributor to the continued patronage of traditional bone setters in spite of the reported poor outcome of their treatment methods [7, 11, 12]. Although this method of interlocking nail fixation will not match closed nailing performed under image intensifier guidance in terms of speed of surgery and blood loss, the technique offers indigent patients in developing economies the opportunity to get an affordable, effective and safe means of operative treatment for atrophic non-union of the femur. The anterior cortical window access for distal locking had been described by Kanellopoulos et al. [13] as a salvage technique for distal locking when their image intensifier developed a fault. Our technique offers solutions to problems that are common in developing countries but may become valuable in any setting following an isolated X-ray guidance failure. Converting a regular K-nail to an interlocking nail simply increases the number of patients that can afford interlocked nailing whilst the modification in technique increases the number of facilities that can undertake such procedures. This technique would enable patients in underprivileged societies to benefit from the superiority of interlocked intramedullary nails. Furthermore, this technique will spare operating room personnel the risk of exposure to ionizing radiations beyond safe limits during image intensifier guided intramedullary nailing [6] in developing nations where the number of patients needing treatment is overwhelming in contrast to few health personnel. The surgical implants generation network (SIGN) interlocked nailing without image intensifier is a notable and valuable alternative that will make the distal cortical window rarely necessary, but it is at this moment not widely available and accessible in Nigeria [14, 15] and many other developing nations.

The major limitation of this study is the small number. This shortcoming, however, should not detract from the usefulness of this open interlocked intramedullary nailing technique.

In conclusion, when viewed in the light of the dearth of equipment and manpower, unreliable healthcare financing and inappropriate maintenance of equipment to ensure radiation safety for patients and health personnel, the open distal cortical window for interlocked nailing has the potential of increasing the number of indigent patients in developing countries that can receive the benefits of interlocked nailing, and this may have an added effect of increasing patients' confidence in operative fracture management.

**Open Access** This article is distributed under the terms of the Creative Commons Attribution Noncommercial License which permits any noncommercial use, distribution, and reproduction in any medium, provided the original author(s) and source are credited.

## References

1. Winqvist RA (1993) Locked femoral nailing. *J Am Acad Ortho Surg* 1:95–105
2. Living on less than one dollar per day. [http://www.swivel.com/data\\_sets/show/1005626](http://www.swivel.com/data_sets/show/1005626)
3. AA Olasinde (2006) Open Kuntscher Nailing Of Closed Femoral Shaft Fractures: revisited. *The Internet Journal of Third World Medicine* 3(2)
4. Rugh Roberts, Wohlfromm Marlis, Varma Andre (1969) Low-dose X-Ray effects on the precleavage mammalian zygote. *Radiat Res* 37:401–414
5. Damilakis J, Perisinakis K, Vrahoriti H, Kontakis G, Varveris H (2002) Gourtsoyiannis n embryo/fetus radiation dose and risk from dual X-ray absorptiometry examinations. *Osteoporos Int* 13:716–722
6. Levin PE, Schoen RW Jr, Browner BD (1987) Radiation exposure to the surgeon during closed interlocking intramedullary nailing. *J Bone Joint Surg (American)* 69:761–766
7. Nwadiaro HC, Nwadiaro PO, Kidmas AT, Ozoilo KN (2006) Outcome of traditional bone setting in the middle belt of Nigeria. *Niger J Surg Res* 8:44–48
8. Megaro A, Marchesi S, Pazzaglia UE (2007) Surgical treatment of aseptic nonunion in long bones: review of 193 cases. *J Orthop Traumatol* 8:11–15
9. Kesemenli CC, Subasi M, Arslan H, Necmioglu S (2002) A Kapukaya Treatment of humeral diaphyseal nonunions by interlocked nailing, autologous bone grafting. *Acta Orthop Belg* 68:471–475
10. Wang CJ, Chen HS, Chen CE, Yang KD (2001) Treatment of nonunions of long bone fractures with shock waves. *Clin Orthop* 387:95–101
11. Ofiaeli RO (1991) Complications of methods of fracture treatment used by traditional healers: a report of three cases necessitating amputation at Ihiala, Nigeria. *Trop Doct* 21:182–183
12. Onuminya JE (2004) The role of the traditional bonesetter in primary fracture treatment in Nigeria. *S Afr Med J* 94: 652–658
13. Kanellopoulos AD, Yiannakopoulos CK, Vossinakis L, Badras LS (2003) Distal locking of femoral nails under direct vision through a cortical window. *J Orthop Trauma* 17:574–577
14. Shah RK, Moehring HD, Singh RP, Dhakal A (2004) Surgical implant generation network (SIGN) intramedullary nailing of open fractures of the tibia. *Int Ortho* 28:163–166
15. Ikem I, Ogunlusi J, Ine H (2007) Achieving interlocking nails without using an image intensifier. *Int Ortho* 31:487–490