

Use of a rigidizing overtube for altered-anatomy ERCP

Mike Tzuhen Wei, MD,^{1,2} Shai Friedland, MD,^{1,2} Rabindra R. Watson, MD,³ Joo Ha Hwang, MD, PhD¹



ERCP is important in managing biliary and pancreatic disorders.¹ However, the success of altered anatomy ERCP depends on overcoming challenges including traversing the variable length of the afferent jejunal limb, intubating the surgical anastomosis, cannulating the papilla, and restrictions of tools depending on the endoscope used.^{1,2}

Developments to help achieve altered-anatomy ERCP have included the multibending backward-oblique-viewing duodenoscope,³ variable-stiffness duodenoscope,⁴ and multibending forward-viewing endoscope.⁵ Although single-balloon and double-balloon enteroscopes can be used to perform altered-anatomy ERCP, the long endoscope length limits the use of conventional ERCP accessories.¹ Short-type single-balloon and double-balloon enteroscopes have been developed but are not widely used.⁶ Given the challenges with altered-anatomy ERCP, developing new tools to improve procedural success is important.

The U.S. Food and Drug Administration approved the Pathfinder Endoscope Overtube (Neptune Medical, Burlingame, Calif, USA) in August 2019.^{7,8} The Pathfinder Endoscope Overtube is an 85-cm-long single-use overtube (16.5 mm diameter) that can exist in 2 states, flexible or rigidized (Fig. 1). Once the flexible overtube and the endoscope are advanced and in the most reduced position, vacuum application stiffens the overtube up to 15 times. The rigidizing overtube can be used in upper endoscopy, colonoscopy, and enteroscopy. We present 2 cases of altered-anatomy ERCP (Video 1, available online at www.VideoGIE.org).

CASE 1

A 53-year-old woman with a history of recurrent pyogenic cholangitis secondary to choledochal cysts leading to a Roux-en-Y hepaticojejunostomy (in 1993) presented for management of intrahepatic stones. Since 1993, the patient had undergone 2 surgical revisions and multiple ERCPs. Six months before the current presentation, she underwent an ERCP that identified a severe localized stricture at the hepaticojejunostomy anastomosis that could not be traversed. Interventional radiology subsequently helped place a percutaneous biliary drain and later a fully covered metal stent across the hepaticojejunostomy.

During the current procedure, a thin colonoscope was introduced with the rigidizing overtube, and the scope easily reached the widely patent jejunojunction anastomosis. The afferent jejunal limb was traversed and the scope reached the hepaticojejunostomy and identified the fully covered metal

stent (Fig. 2). Contrast injection demonstrated a patent stent and mild dilatation of the intrahepatic bile ducts. The stent was removed, and with the overtube maintained in its rigidized position, the endoscope easily returned to the hepaticojejunostomy. The anastomosis was characterized by 2 orifices. The smaller of the 2 orifices was dilated, and plastic stents were placed in this orifice as well as in different branches of the intrahepatic ducts (Fig. 3).

CASE 2

A 49-year-old man with a history of World Health Organization grade I insulinoma leading to pylorus-

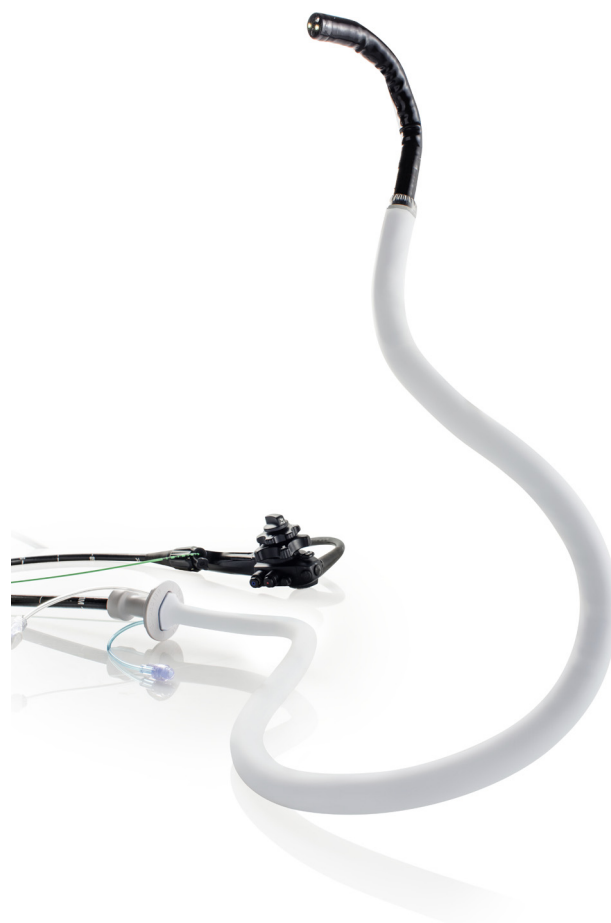

Figure 1. The Pathfinder endoscope is an 85-cm-long single-use overtube that can exist in 2 states, flexible or stiffened. Application of a vacuum stiffens the endoscope up to 15 times.

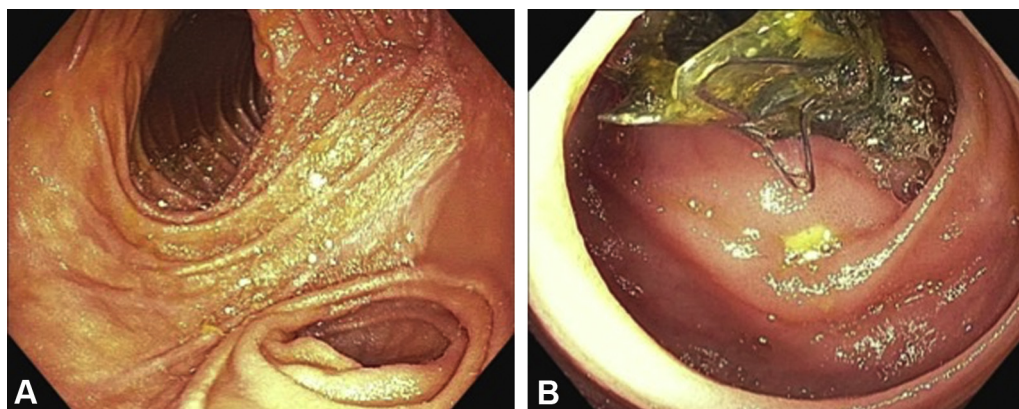


Figure 2. Case 1. **A**, Widely patent jejunojunal anastomosis with healthy-appearing mucosa. **B**, Fully covered metal stent found across the hepaticojejunostomy.

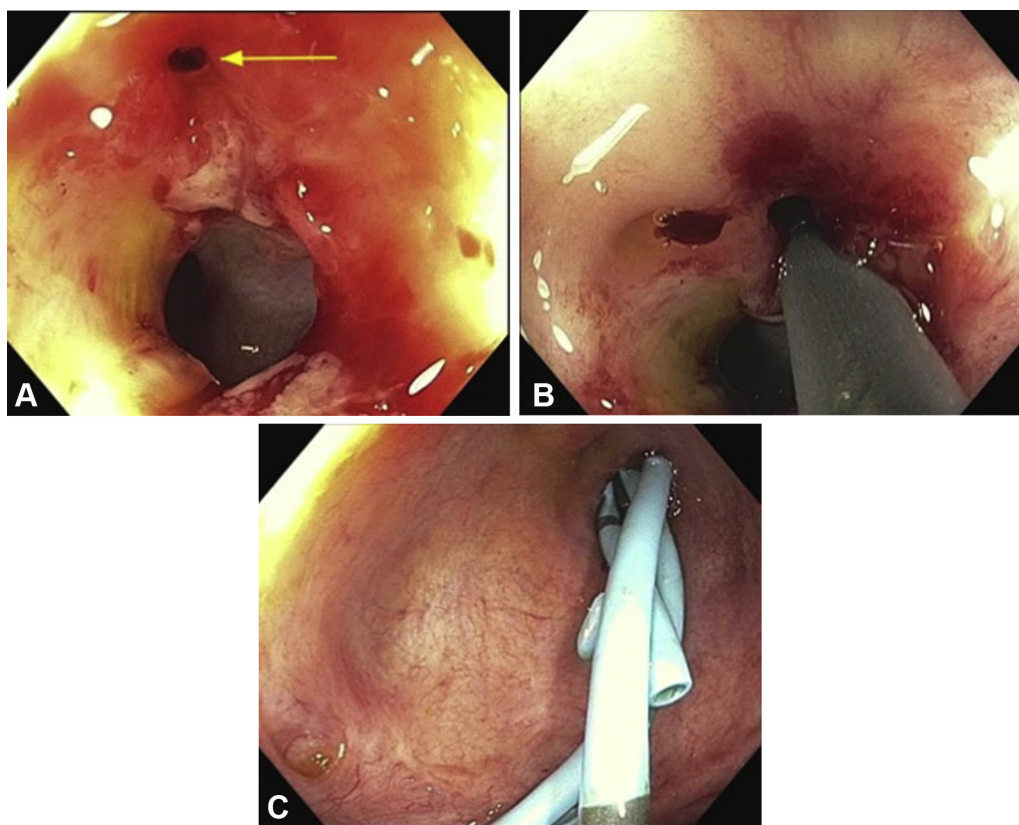


Figure 3. **A**, Hepaticojejunostomy site after removal of stent. The anastomosis was characterized by 2 orifices. The smaller orifice is marked with the *arrow*. **B**, Dilation of the smaller orifice was performed. **C**, Plastic stents were placed in the smaller of the 2 orifices at the hepaticojejunostomy anastomosis as well as in different branches of the intrahepatic ducts.

preserving Whipple 6 months earlier presented for altered-anatomy ERCP. Three months after Whipple, the patient had biliary obstruction. ERCP at the time identified a completely occluded choledochojejunostomy. Interventional radiology placed a right-sided transhepatic biliary drain, which was later converted to a right-sided transhepatic internal-external biliary drain with the stricture traversed by a plastic catheter.

During the current procedure, a thin colonoscope and overtube were introduced and demonstrated a widely patent postpyloric anastomosis. The choledochojejunostomy was identified in the afferent jejunal loop. The bile duct was cannulated alongside the catheter, and cholangiogram demonstrated mild dilation of the common hepatic duct and normal caliber of the intrahepatic ducts. Dilation of the choledochojejunostomy anastomosis was performed,

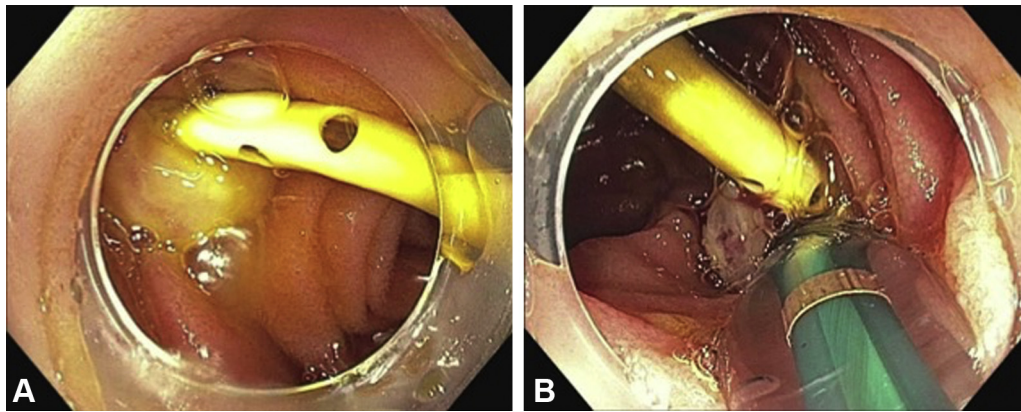


Figure 4. Case 2. **A**, Stricture choledochojejunostomy with drain by interventional radiology. **B**, Balloon dilation of the choledochojejunostomy stricture was performed.

and a double-pigtail plastic stent was inserted into the common bile duct (Fig. 4).

Our 2 cases demonstrate the utility of the rigidizing overtube in accomplishing altered-anatomy ERCP. Success varies with intubation and cannulation in ERCP for patients with surgically altered anatomy.² The rigidizing overtube is a simple tool to overcome the challenges of altered-anatomy ERCP. Although both cases had undergone ERCP before, the performance of ERCP in the current presentation was significantly enhanced with the rigidizing overtube. The overtube reduces looping, allowing for increased distances that shorter scopes (such as a side-viewing duodenoscope) are unable to achieve. This is particularly important in managing gastric loops and the tight angulation at surgical anastomoses, including the jejunojunctionostomy anastomosis. The overtube can accommodate an endoscope up to 11.5 mm in diameter and as such can be used with a duodenoscope, thin colonoscope, or therapeutic upper endoscope, allowing traditional ERCP tools to be used, unlike with single-balloon or double-balloon enteroscopy. Furthermore, the overtube can help stabilize the endoscope tip, allowing for fine therapeutic maneuvers. Overall, we believe that these benefits come with very minimal increased risk beyond the average risk of altered-anatomy ERCP. In fact, by reducing looping, decreasing procedural time, and improving ease of procedure, performing altered-anatomy ERCP with a rigidizing overtube may actually decrease risk as well as cost. However, additional safety and cost-effectiveness studies will be needed to better evaluate these possibilities.

Although additional studies are needed, here we have demonstrated its use in assisting with the challenging altered-anatomy ERCP.

DISCLOSURE

Dr Friedland is a consultant for Capsovision. Dr Watson is a consultant/speaker for Apollo Endosurgery, Boston Scientific, and Neptune Medical. Dr Hwang is a

consultant for Olympus, Medtronic, Boston Scientific, Micro-Tech, and Lumendi. All other authors disclosed no financial relationships.

REFERENCES

- Moreels TG. ERCP in the patient with surgically altered anatomy. *Curr Gastroenterol Rep* 2013;15:343.
- Krutsri C, Kida M, Yamauchi H, et al. Current status of endoscopic retrograde cholangiopancreatography in patients with surgically altered anatomy. *World J Gastroenterol* 2019;25:3313-33.
- Imazu H, Kanazawa K, Ikeda K, et al. Initial evaluation of a novel multibending backward-oblique viewing duodenoscope in endoscopic retrograde cholangiopancreatography. *Endoscopy* 2012;44:99-102.
- Adler DG. Initial report of a variable stiffness duodenoscope for use during endoscopic retrograde cholangiopancreatography. *J Clin Gastroenterol* 2011;45:590-2.
- Koo HC, Moon JH, Choi HJ, et al. The utility of a multibending endoscope for selective cannulation during ERCP in patients with a Billroth II gastrectomy (with video). *Gastrointest Endosc* 2009;69:931-4.
- Yamauchi H, Kida M, Okuwaki K, et al. Short-type single balloon enteroscope for endoscopic retrograde cholangiopancreatography with altered gastrointestinal anatomy. *World J Gastroenterol* 2013;19:1728-35.
- United States Food and Drug Administration. Pathfinder Endoscope Overtube. Food and Drug Administration. Available at: https://www.accessdata.fda.gov/cdrh_docs/pdf19/K191415.pdf. Accessed July 30, 2020.
- Wei MT, Hwang JH, Watson RR, et al. Novel rigidizing overtube for colonoscope stabilization and loop prevention (with video). *Gastrointest Endosc*. Epub 2020 Jul 30.

Stanford University, Stanford, California (1), Veterans Affairs Palo Alto, Palo Alto, California (2), California Pacific Medical Center, San Francisco, California (3).

If you would like to chat with an author of this article, you may contact Dr Wei at mtwei@stanford.edu.

Copyright © 2020 American Society for Gastrointestinal Endoscopy. Published by Elsevier Inc. This is an open access article under the CC BY-NC-ND license (<http://creativecommons.org/licenses/by-nc-nd/4.0/>).

<https://doi.org/10.1016/j.vgie.2020.08.003>