

A Case Report of Vogt's Limbal Girdle and Retinitis Pigmentosa in a Thirteen-Year-Old Boy: A Rare and Unusual Association

A.P. Vignesh Renuka Srinivasan Swathi Karanth Sai Vijitha

Department of Ophthalmology, Jawaharlal Institute of Postgraduate Medical Education and Research (JIPMER), Pondicherry, India

Key Words

Vogt's limbal girdle · Retinitis pigmentosa · Abiotrophy

Abstract

Aim: To describe a rare case of Vogt's limbal girdle in a boy with retinitis pigmentosa. **Methods:** A 13-year-old boy from India presented to us with progressive diminution of vision and nyctalopia for 5 years. On examination, he had the characteristic features of retinitis pigmentosa with the fundus showing disc pallor, bony spicules and arteriolar attenuation. His anterior segment examination showed Vogt's limbal girdle in both eyes. **Results:** Vogt's limbal girdle is a corneal degeneration usually seen in elderly individuals. This is the first time it is seen in association with retinitis pigmentosa. It has also never been reported at such a young age. **Conclusion:** We report a rare case where Vogt's limbal girdle was observed in a 13-year-old boy with retinitis pigmentosa. This gives further insight into the pathogenesis of the disease.

© 2015 S. Karger AG, Basel

Introduction

Vogt's limbal girdle is a degenerative condition of the cornea usually seen in elderly individuals; it is rarely seen under the age of 40 years. The term retinitis pigmentosa refers to a group of hereditary retinal dystrophies with characteristic retinal and electroretinographic findings in which the photoreceptors undergo progressive degeneration. The usual anterior segment associations of retinitis pigmentosa include keratoconus, posterior subcapsular

cataract and myopia. We report this case of a rare association of Vogt's limbal girdle with retinitis pigmentosa.

Case Presentation

A 13-year-old Indian boy presented to us with progressive diminution of vision in both the eyes for 5 years. He also complained of poor vision at night. No associated systemic anomaly or syndromic association was found. His father was a diagnosed case of retinitis pigmentosa. The patient was positive for a RHO gene mutation. His vision was 20/200 in both eyes. On examination, his fundus showed typical features of retinitis pigmentosa with disc pallor, bony spicules and arteriolar attenuation (fig. 1). The findings were bilateral and symmetrical. His electroretinogram showed extinguished cone and rod responses in both the eyes (fig. 2). Visual fields were severely constricted (fig. 3). On examination of his anterior segment, we found a bilateral symmetrical crescentic white band in the interpalpebral limbus suggestive of Vogt's limbal girdle type 2 (fig. 4). He also had posterior subcapsular cataract in both eyes. Optical coherence tomography revealed a mild degree of foveal atrophy in the right eye (fig. 5). The patient's loss of vision could be attributed to the reduced photoreceptor function, cataract and foveal atrophy.

Discussion

Retinitis pigmentosa is a hereditary rod-cone dystrophy usually leading to a progressive loss of vision and night blindness. It is a kind of abiotrophy of the retina. It is associated with a number of corneal segment associations like keratoconus band-shaped keratopathy [1, 2]. Crawford [3] described a case of granular corneal dystrophy associated with retinitis pigmentosa, both contributing to vision loss. Mataftsi et al. [4] described 6 patients with retinitis pigmentosa in a sample size of 200 patients with Bietti's corneal dystrophy, and the prevalence was 3%. There are also reports of corneal cloudiness and retinitis pigmentosa in mucopolysaccharidoses [5]. Hayasaka et al. [6] described a case of retinitis pigmentosa in a man's right eye, and corneal opacity, corneoidridal adhesion and normal retina in the left eye. Seneca et al. [7] described a case resembling Kearns-Sayre syndrome showing dystrophic features in the cornea and retina. Vogt's limbal girdle has rarely been associated with the disease. It is a corneal degeneration, and it is an age-related condition. It has rarely been seen in patients less than 40 years old [8]. It is a chalky white band in the interpalpebral limbus. Since the limbal girdle is a degenerative condition, the general process of abiotrophy in retinitis pigmentosa would have contributed to the development of the corneal degeneration at this age, which is usually an age-related condition. To the best of our knowledge, this is the first time Vogt's limbal girdle is associated with retinitis pigmentosa. It is also the first time it is reported at such a young age. The potential pathophysiological mechanisms causing both conditions may coexist, and thus this aspect deserves further study.

Statement of Ethics

Written informed consent was obtained from the patient and the parent for publication of this case report and any accompanying images. A copy of the written consent is available for review by the Editor of this journal.

Disclosure Statement

The authors declare that there is no conflict of interest regarding the publication of this paper.

References

- 1 Moschos M, Droutsas D, Panagakis E, Tsioulis G, Tsalouki M: Keratoconus and tapetoretinal degeneration. *Cornea* 1996;15:473–476.
- 2 Fishman GA, Anderson RJ, Lourenco P: Prevalence of posterior subcapsular lens opacities in patients with retinitis pigmentosa. *Br J Ophthalmol* 1985;69:263–266.
- 3 Crawford C: Retinitis pigmentosa and granular dystrophy: a rare and unique combination in one patient. *Binocul Vis Strabolog Q Simms Romano* 2013;28:36–38.
- 4 Mataftsi A, Zografos L, Millá E, Secrétan M, Munier FL: Bietti's crystalline corneoretinal dystrophy: a cross-sectional study. *Retina* 2004;24:416–426.
- 5 Cotlier E: Letter: Corneal cloudiness and retinitis pigmentosa in the mucopolysaccharidoses. *N Engl J Med* 1975;292:812.
- 6 Hayasaka S, et al: Retinitis pigmentosa in a man's right eye and corneal opacity, corneoid adhesion, and normal retina in the left eye. *Ann Ophthalmol* 2000;32:185–187.
- 7 Seneca S, Verhelst H, De Meirleir L, Meire F, Ceuterick-De Groote C, Lissens W, et al: A new mitochondrial point mutation in the transfer RNA(Leu) gene in a patient with a clinical phenotype resembling Kearns-Sayre syndrome. *Arch Neurol* 2001;58:1113–1118.
- 8 Sugar HS, Kobernick S: The white limbus girdle of Vogt. *Am J Ophthalmol* 1960;50:101–107.

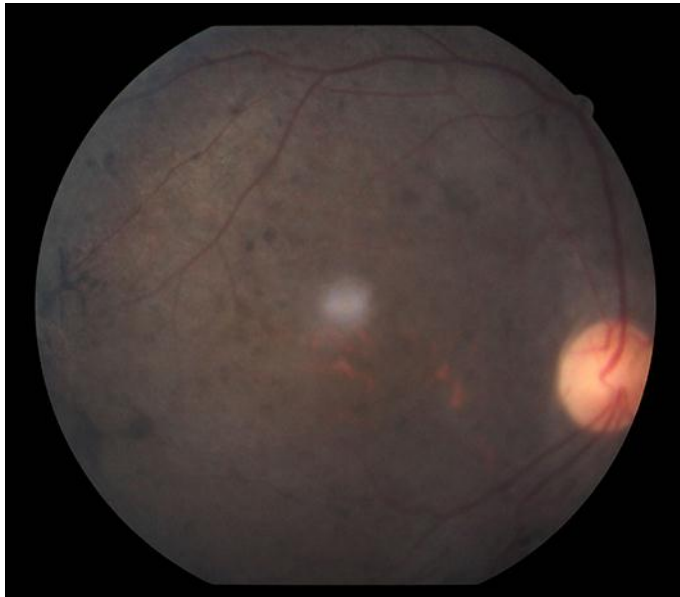


Fig. 1. Fundus photograph showing features of retinitis pigmentosa.

Vignesh et al.: A Case Report of Vogt's Limbal Girdle and Retinitis Pigmentosa in a Thirteen-Year-Old Boy: A Rare and Unusual Association

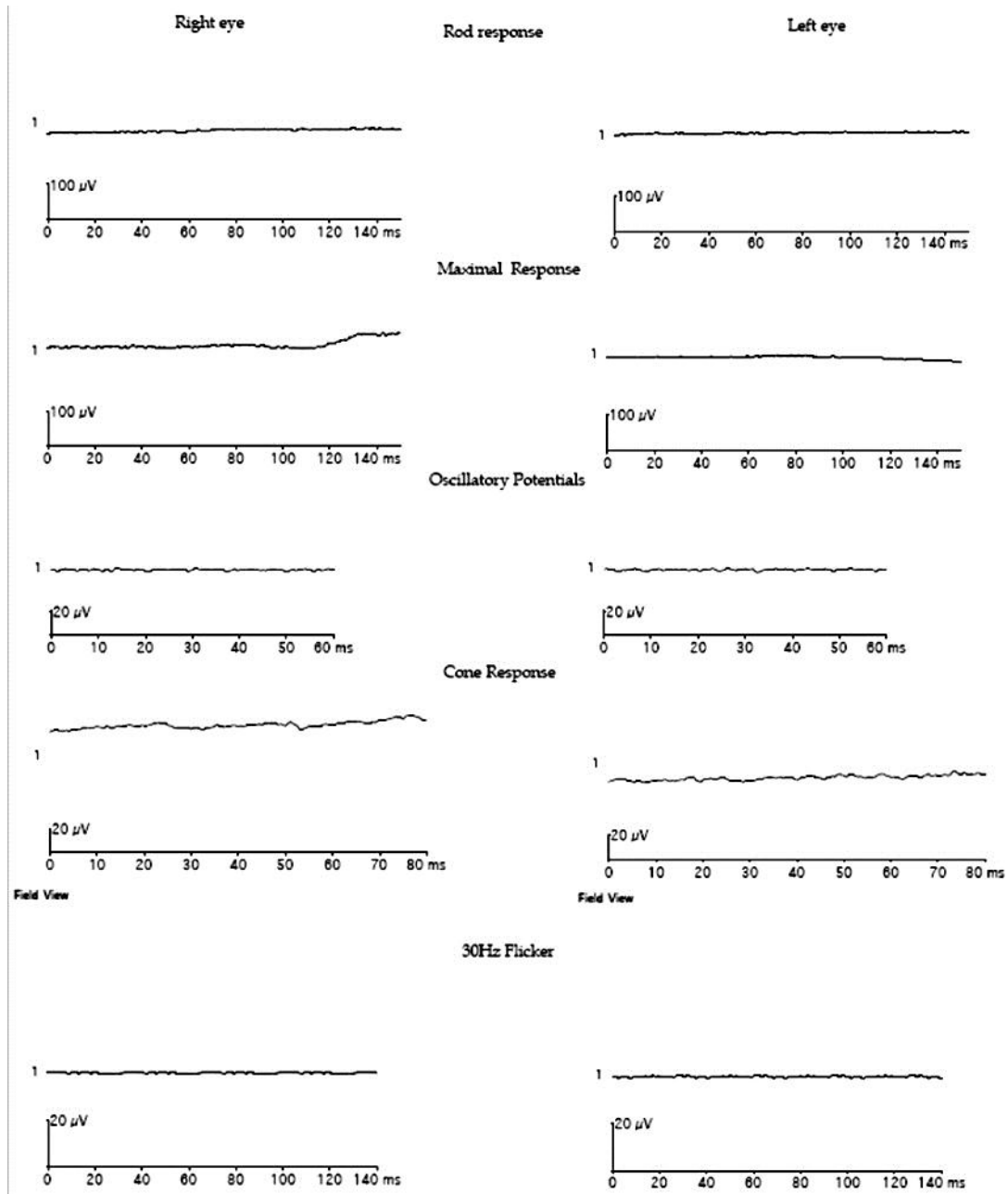


Fig. 2. Electroretinogram of the patient.

Vignesh et al.: A Case Report of Vogt's Limbal Girdle and Retinitis Pigmentosa in a Thirteen-Year-Old Boy: A Rare and Unusual Association




Fig. 3. Visual fields of the patient.

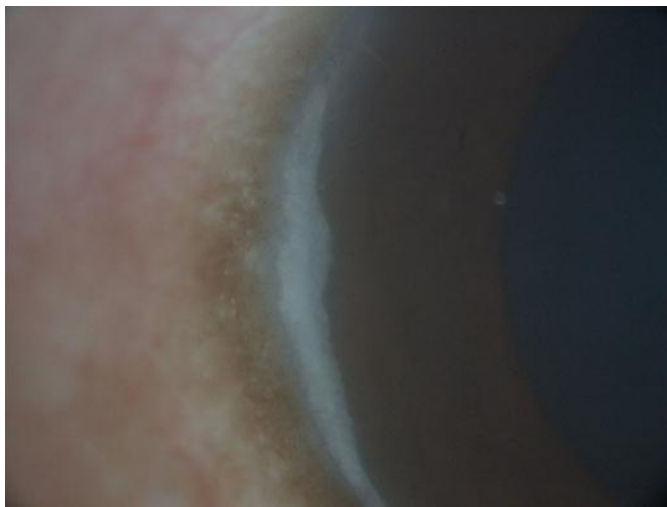


Fig. 4. Anterior segment picture showing Vogt's limbal girdle.

Vignesh et al.: A Case Report of Vogt's Limbal Girdle and Retinitis Pigmentosa in a Thirteen-Year-Old Boy: A Rare and Unusual Association

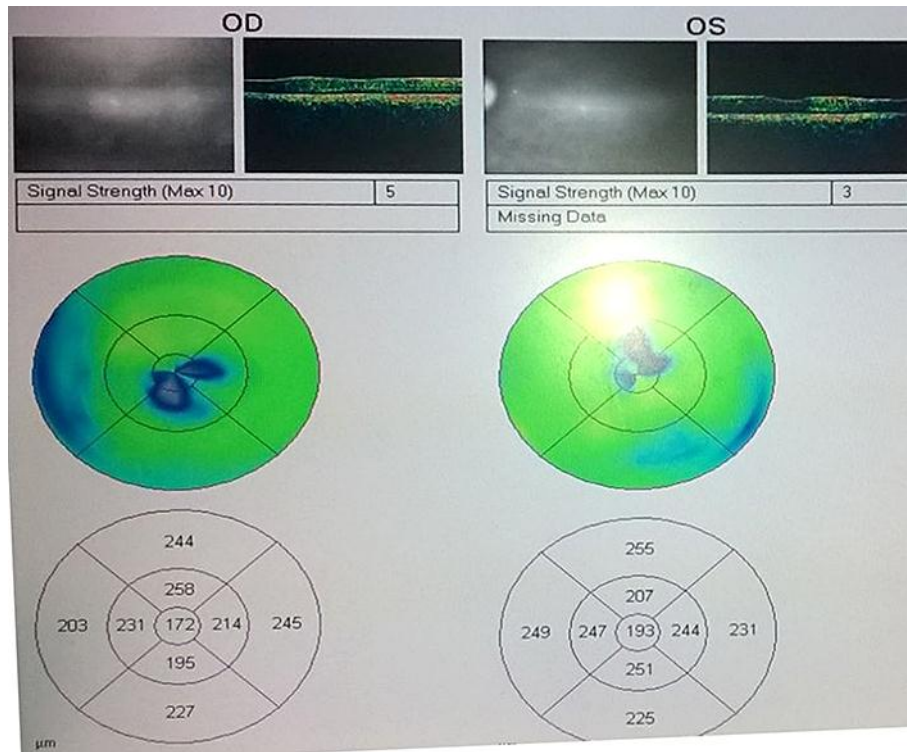


Fig. 5. Optical coherence tomography showing foveal atrophy.