

A rare case of type 1 C split cord malformation with single dural sheath

Kanwaljeet Garg, Ashok K. Mahapatra, Vivek Tandon

Department of Neurosurgery, All India Institute of Medical Sciences, New Delhi, India

ABSTRACT

Split cord malformation (SCM) is a rare congenital anomaly in which the cord is split over a portion of its length to form double dural tubes (SCM type I) or two hemicords in a single dural sheath (SCM type II). Dachling Pang classified SCM into 2 types with type I SCM consisting of two hemicords, each contained within its own dural sheath and separated by rigid osseocartilaginous median septum. We report a rare case of SCM type 1 c in which there was a single dural sheath.

Key words: Hemicord, pang's classification, split cord malformation.

Introduction

Split cord malformation (SCM) is a rare congenital anomaly in which the cord is split over a portion of its length to form double dural tubes (SCM type I) or two hemicords in a single dural sheath (SCM type II). Dachling Pang^[1] classified SCM into 2 types with type I SCM consisting of two hemicords, each contained within its own dural sheath and separated by rigid osseocartilaginous median septum. We report a rare case of SCM type 1 c in which there was a single dural sheath. Only one case of single dural sheath in type 1 SCM has been reported in English literature till now.^[2]

Case Report

A 10-month-old girl presented to us with a tuft of hair over the lower back since birth. She was moving her lower limbs less as compared to her upper limbs. Bladder and bowel functions were not impaired. Examination revealed tuft of hair in midline in the lumbar region. She also had scoliosis with curvature towards the left side. Her head size was normal for her age. Noncontrast Computed tomography spine revealed bony spur at the level of L3 vertebral body [Figure 1] and

it was directed superiorly [Figure 2]. Magnetic resonance imaging scan was done which showed spinal dysraphism in the lumbosacral region with split cord malformation type 1 with two hemicords separated by a spur [Figure 3 and 4]. Cord was ending at L3 [Figure 3].

D 12 to L 4 laminotomy was done. Intraoperatively split cord was extending downwards from L 1. There was bony septum arising from posterior surface of L 3 vertebral body and it was ascending up to L 2 level. There was a single dural sac and the bony septum was indenting the dural sac from anterior aspect, not dividing the posterior dura into two sheaths (contrary to what is seen usually in Type I split). The conus was split into two halves by the septum and there was a single filum. The septum was seen at the lower part of split only, making it type I C split (as per the classification given by Mahapatra and Gupta).^[1,6] The septum was excised and both the dural envelopes were opened and sutured into one sheath. The filum was thickened and detethering was also done. The patient developed weakness in both her lower limbs in the post-operative period. She was given methylprednisolone intravenous for 48 h and at the time of discharge (post-operative day 7), she had recovered power in both lower limbs up to the preoperative level.

Discussion

Ollivier^[3] in 1837, first described a case of diplomyelia. He used this term to describe an abnormality of the spinal cord, in which the dura was separated by a bone spur or rigid fibrous band to create 2 sleeves, each containing a portion of spinal cord divided sagittally into 2 parts. Bruce *et al.*,^[4] used the term diastematomyelia to describe a spinal cord split by a midline bony spur, reserving the term 'diplomyelia' for a true doubling of the spinal cord, without a spur. Feller and Stenberg,^[5] first implicated a notochordal cleft, caused by persistence of a

Access this article online	
Quick Response Code:	Website: www.asianjns.org
	DOI: 10.4103/1793-5482.161196

Address for correspondence:

Prof Ashok Kumar Mahapatra, Room No 720, Department of Neurosurgery, Cardio-Neuro Centre, All India Institute of Medical Sciences New Delhi, India. E-mail: akmahapatra22000@gmail.com

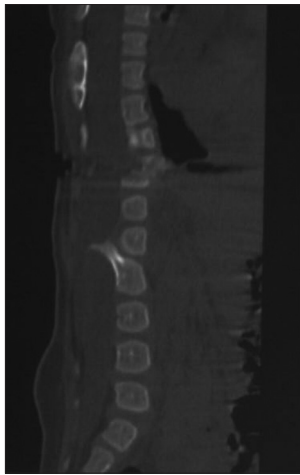


Figure 1: NCCT spine (sagittal view) showing bony spur attached to L3 and extending superiorly

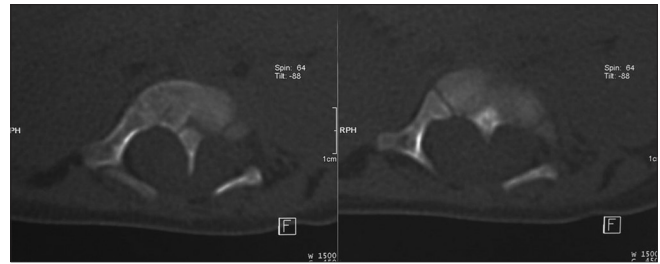


Figure 2: NCCT spine (axial view) showing bony spur attached to posterior surface of vertebral body

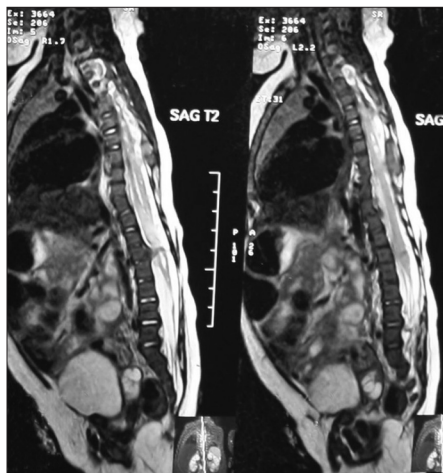


Figure 3: MRI spine (sagittal view) showing cord ending at L3

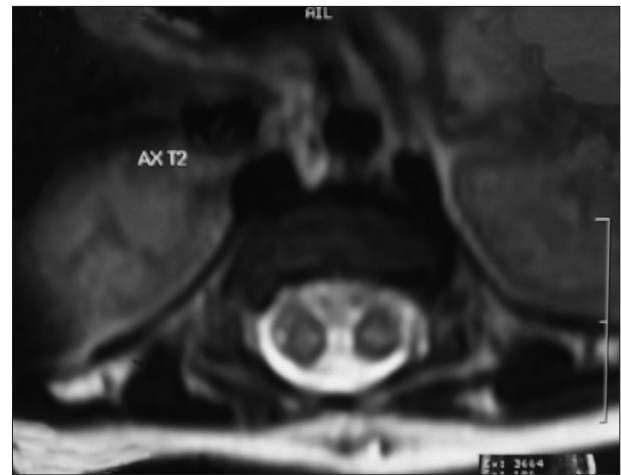


Figure 4: MRI spine (axial view) showing two hemicords separated by spur

midline cell rest that resulted in diastematomyelia. Bentley and Smith,^[6] coined the term ‘split notochord syndrome’, to describe this particular theory. Laale^[7] produced notochordal and subsequent spinal cord duplications in zebra fish embryos with ethanol.

Several authors have proposed theories to explain the genesis of split cord malformation. Gardner^[8] proposed the hydromyelic theory, advocating rupture of an intact neural tube by cerebrospinal fluid as the cause of spina bifida defects. Primary mesodermal abnormality theory was advocated by Lichtenstein.^[9] Hendrick^[10] proposed on the accessory neurenteric canal hypothesis.

Initially, diplomyelia and diastematomyelia were thought to be two different entities. Diplomyelia was thought to be a true duplication of the spinal cord at certain segments^[11,12] and the diastematomyelia was thought to be caused by the bony spur, which suggested that it resulted from meso-dermal invasion of the neural tube.^[13,14] This was effectively disproved by Pang *et al.*,^[1] and Pang.^[15] They proposed a unified theory of embryogenesis

and advocated a new classification, recommending the term ‘split cord malformation’ for all double spinal cords. The unified theory proposes that all split cord malformations originate from one basic ontogenetic error, occurring around the same time, when the primitive neurenteric canal closes. This basic error leads to the formation of an ‘accessory neurenteric canal’ through the midline embryonic disc that maintains communication between yolk sac and amnion, and enables a contact between ectoderm and endoderm within the canal depending on the timing of the formation of the endomesenchymal tract and subsequent mesenchymal infiltration. Thus the neural tube would split into 2 separate components with an intervening fibrocartilaginous or bony septum (Type 1 SCM), or remain a single dural tube with a split cord by fibrous tissues (Type 2 SCM). This would also explain the presence of commonly associated spinal abnormalities such as dermal sinus tracts, spinal lipomas, dermoids, neurenteric cysts, and even a meningocele or myelomeningocele, as these abnormalities can arise from various ectodermal or endodermal remnants.

Pang *et al.*,^[1] and Pang^[15] divided SCM into two types. Type I SCM consists of two hemicords, each contained within its own dural sheath and being separated by a rigid osseocartilaginous median septum. A type II SCM consists of two hemicords housed in a single dural sheath being separated by a non-rigid, fibrous median septum.

Mahapatra and Gupta^[16] in 2005, based on their intraoperative findings in regards to the level of the spur and its relation to the split, proposed a subclassification of the existing Pang classification of primary SCM type I (a-d); Ia, a bone spur in the center with an equally duplicated cord above and below the spur; Ib, a bone spur at the superior pole of the split with no space above it and a large duplicated cord lower down; Ic, a bone spur of the lower pole with a large duplicated cord above; and Id, a bone spur straddling the bifurcation with no space above or below the spur. According to these two classification systems, our case conforms to type I c but with single dural tube.

Our case is unique in many respects, firstly there was a single dural sheath containing two hemicords (conus) with a bony septum indenting the single dural sac, contrary to two dural sacs seen in type I split cord malformations. Other unique feature of our case was that the bony septum was attached to the posterior surface of L3 vertebra and was extending superiorly up to L2 level without any attachment to L1 or L2 vertebral body.

Findings of our case are not explained by the classification proposed by Pang *et al.*, as there was a single dural sheath containing two hemicords, with a bony septum indenting the single dural sac. Only one case of type I SCM with single dural sheath is reported in English literature to the best of our knowledge, that too by the senior author of this paper (Mahapatra).^[2] In previous patient, authors reported a long-segment type 1 split cord malformation, with two-level split cord malformation and a single dural sac and the spur was at the lower end of split. There was a bony spur arising from the D 11 body level without a separate dural covering but with 2 cords. The split of the cord extended from D 5 to D 11 level.

Conclusion

Unified theory of embryogenesis is the most common accepted theory for split cord malformation, however it does not explain type 1 split with single dural sheath. One should be ready to

anticipate such findings and avoid injury to the cord during surgery.

References

1. Pang D, Dias MS, Ahab-Barmada M. Split cord malformation: I: A unified theory of embryogenesis for double spinal cord malformations. *Neurosurgery* 1992;31:451-80.
2. Singh PK, Khandelwal A, Ailawadhi P, Gupta D, Mahapatra AK. Long-segment type I split cord malformation with two-level split cord malformation and a single dural sac at the lower split. *Peditr Neurosurg* 2011;47:227-9.
3. Ollivier C. *Traité des maladies de la moelle épinière*. Paris: Mequignon-Marvis; 1837.
4. Bruce A, McDonald S, Pirie JH. A second case of partial doubling of the spinal cord. *Rev Neurol Psychiatry* 1906;4:6-19.
5. Feller A, Stenberg H: Zur Kenntnis der Fehlbildungen der Wirbelsäule. I. Die Wirbelkörperspalte und ihre formale Genese. *Virchows Arch Am* 1929;272:613-40.
6. Bentley JF, Smith JR. Developmental posterior enteric remnants and spinal malformations; the split notochord syndrome. *Arch Dis Child* 1960;35:76-86.
7. Laale HW. Ethanol-induced notochord and spinal cord duplications in the embryo of the Zebrafish. *J Exp Zool* 1971;178:51-64.
8. Gardner JW: Myelocoele; rupture of the neural tube? *Clin Neurosurg* 1968;15:57-79.
9. Lichtenstein BW. "Spinal dysraphism" -spina bifida and myelodysplasia. *Arch Neurol Psychiatry* 1940;44:792-810.
10. Hendrick EB. On diastematomyelia. *Prog Neurol Surg* 1971;4:277-88.
11. Cohen J, Sledge CB: Diastematomyelia: An embryological interpretation with report of a case. *Am J Dis Child* 1960;100:257-63.
12. Muller F, O'Rahilly R. The development of the human brain, the closure of the caudal neuropore, and the beginning of secondary neurulation at stage 12. *Anat Embryol (Berl)* 1987;176:413-30.
13. Beardmore HE, Wiglesworth FW. Vertebral anomalies and alimentary duplications: Clinical and embryological aspects. *Pediatr Clin North Am* 1958;5:457-74.
14. Bremer JL: Dorsal intestinal fistula; accessory neurenteric canal; diastematomyelia. *AMA Arch Pathol* 1952;54:132-8.
15. Pang D. Split cord malformation. II. Clinical syndrome. *Neurosurgery* 1992;31:481-500.
16. Mahapatra AK, Gupta DK. Split cord malformations: A clinical study of 254 patients and a proposal for a new clinical-imaging classification. *J Neurosurg* 2005;103:531-6.

How to cite this article: Garg K, Mahapatra AK, Tandon V. A rare case of type 1 C split cord malformation with single dural sheath. *Asian J Neurosurg* 2015;10:226-8.

Source of Support: Nil, Conflict of Interest: None declared.