

## Interphotoreceptor retinoid-binding protein as biomarker in systemic autoimmunity with eye inflections

F. J. Descamps<sup>a</sup>, D. Kangave<sup>b</sup>, B. Cauwe<sup>a</sup>, E. Martens<sup>a</sup>, K. Geboes<sup>c</sup>,  
A. Abu El-Asrar<sup>d</sup>, G. Opdenakker<sup>a</sup> \*

<sup>a</sup> Department of Microbiology and Immunology, Rega Institute for Medical Research, University of Leuven, Leuven, Belgium

<sup>b</sup> Diabetes Centre, College of Medicine, King Saud University, Riyadh, Saudi Arabia

<sup>c</sup> Department of Pathology, University of Leuven, Belgium

<sup>d</sup> Department of Ophthalmology, College of Medicine, King Saud University, Riyadh, Saudi Arabia

Received: November 22, 2007; Accepted: January 23, 2008

### Abstract

Autoimmune diseases of the eye, exemplified by Behçet disease and Vogt-Koyanagi-Harada disease, are a major cause of blindness. We studied interphotoreceptor retinoid-binding protein (IRBP), a dominant autoimmune antigen in the eye. Aqueous humour samples from 28 patients with active uveitis were analysed for immunoglobulin G (IgG) content as a marker for blood-ocular barrier breakdown and by gelatinase B zymography for the detection of inflammation. The data were correlated with the presence of intact IRBP ( $\approx 140$  kD) as determined by Western blot analysis and with the clinical disease activity. Aqueous humour samples from control eyes and eyes with low disease activity showed positive immunoreactivity for intact IRBP. The IRBP signal weakened or disappeared with higher disease activity. Significant positive correlations were observed between disease activity and levels of gelatinase B/matrix metalloproteinase-9 (MMP-9) ( $r_s = 0.713$ ;  $P < 0.001$ ) and IgG ( $r_s = 0.580$ ;  $P = 0.001$ ). Significant negative correlations were found between levels of IRBP and disease activity ( $r_s = -0.520$ ;  $P = 0.005$ ) and levels of MMP-9 ( $r_s = -0.727$ ;  $P < 0.001$ ) and of IgG ( $r_s = -0.834$ ;  $P < 0.001$ ). Whereas neutrophil elastase converted intact IRBP into an immunoreactive 55 kD peptide *in vitro*, the conversion by neutrophil degranulates resembled more the *in vivo* context with a complete degradation of IRBP. Reversal of inflammation with immunosuppressive therapy was accompanied with reappearance of intact IRBP and disappearance of IgG and MMP-9. The analysis of IRBP proteolysis is useful as a biomarker for uveitis and suggests that inhibition of proteinases might become a therapeutic strategy in an inflammatory context of a damaged blood-ocular barrier.

**Keywords:** autoimmunity • uveitis • IRBP • proteolysis matrix metalloproteinase

### Introduction

Autoimmunity implies the loss of tolerance in the B or T cell compartment towards particular autoantigens, followed by an adaptive tissue-damaging immune response. In autoimmune diseases, like multiple sclerosis (MS) and autoimmune uveitis (AU), the immune response is directed against autoantigens that are hidden behind physical barriers, respectively, the blood-brain

barrier (BBB) and the blood-ocular barrier. In the initial stages of MS and AU, physical barriers are compromised so that, by confrontation of immune cells with autoantigens, immunological ignorance is abolished as a mechanism of peripheral tolerance. Matrix metalloproteinases-2 (MMP-2) and -9 (MMP-9) and tissue plasminogen activator (t-PA) have been shown to be involved in the breakdown of physical barriers by degrading basement membranes and proteins associated with tight junctions or other membrane protein complexes [1, 2].

A previously unexpected role of extracellular proteolysis in autoimmunity is the release of sequestered epitopes from intact autoantigens, in other words the breakdown of molecular barriers. Protein degradation products and short peptides may indeed be presented by antigen-presenting cells through the classical pathway

\*Correspondence to: Ghislain OPDENAKKER, MD, PhD,  
Department of Microbiology and Immunology, Rega Institute for Medical  
Research, University of Leuven, Minderbroedersstraat 10, B-3000  
Leuven, Belgium.  
Tel.: 32 16 33 7341  
Fax: 32 16 33 7340  
E-mail: ghislain.opdenakker@rega.kuleuven.be

of uptake, endosomal loading into major histocompatibility complex (MHC) class II, cross-presentation into MHC class I and cell membrane presentation, and also by non-classical extracellular binding in MHC class II grooves, skipping the classical intracellular route [3]. For myelin proteins, it has been shown that the extracellular proteolysis by gelatinase B releases a burden of immunodominant epitopes that may act as encephalitogens in MS [4]. For rheumatoid arthritis, collagen type II degradation was suggested as a source for disease-promoting peptides [5].

AU is a clinically heterogeneous group of diseases [6]. Behçet disease, Vogt-Koyanagi-Harada disease, ankylosing spondylitis, chronic endophthalmitis after cataract surgery and idiopathic uveitis are different presentations of eye inflammations. The exact cause of Vogt-Koyanagi-Harada disease remains unknown, but evidence suggests that it involves a T lymphocyte-mediated autoimmune process directed against one or more antigens found on or associated with melanocytes. Recently, it was demonstrated that proteins of the tyrosinase family are the antigens specific to Vogt-Koyanagi-Harada disease, and that Vogt-Koyanagi-Harada disease is characterized by a T helper type 1 cell-mediated immune response [7, 8]. Behçet disease is a systemic vasculitis with unclear aetiology and pathogenesis. High prevalence of HLA-B51, T helper type 1 cell-mediated immune response, neutrophil hyperfunction and increased expression of heat shock protein 60 in the patients are considered important in the pathogenesis [9]. Ankylosing spondylitis is an autoimmune disease, associated with the expression of class I MHC antigen HLA-B27 [10]. Chronic postoperative bacterial endophthalmitis is most often observed after cataract surgery [11], whereas idiopathic uveitis forms a clinically heterogeneous group of other diseases with eye inflammation of unknown origin.

For the activation of T cells, an inflammatory context is required, which induces the expression of essential co-stimulatory signals. Inflammatory sites are characterized by a pro-inflammatory cytokine profile and up-regulated proteolytic activity. Gelatinase B, alias MMP-9, is one of these extracellular proteases and is released in tissues in response to pro-inflammatory stimuli. In endotoxin-induced uveitis, MMP-9 activity was shown to correlate with neutrophil accumulation [12]. The sensitive detection of gelatinase B/MMP-9 by gelatin zymography analysis makes it a suitable marker for objective scoring of eye inflammation with the use of microlitre samples from the vitreous or the aqueous humour. The fact that gelatinase B is a prototypic activation product of various leukocyte types ensures that gelatinolytic analysis can be used for evaluation of acute or chronic inflammation, involving myeloid or lymphoid cells.

Interphotoreceptor retinoid-binding protein (IRBP) is a dominant autoantigen in AU [13]. We detected IRBP proteolysis in the eye and analysed aqueous humour samples from patients with active uveitis associated with Behçet disease, Vogt-Koyanagi-Harada (VKH) disease, ankylosing spondylitis, chronic endophthalmitis and from patients with idiopathic uveitis, using Western blot analysis for IRBP. Our results indicate that the breakdown of IRBP is associated with clinical inflammatory scores and with innate (MMP-9) and adaptive (immunoglobulin G, IgG) immunological parameters.

## Materials and methods

### Patients

Twenty-eight patients with active uveitis seen at the outpatient clinic of King Abdulaziz University Hospital were included in this observational study. The patients were 18 males and 10 females. The mean age was  $30.2 \pm 12.2$  years (range, 14–54 years). All the patients were investigated to determine the nature of their disease and associated systemic illnesses. Eleven patients had VKH disease, 10 had Behçet disease, two had ankylosing spondylitis, three had idiopathic uveitis and two had chronic endophthalmitis caused by *Propionibacterium acnes* after extracapsular cataract extraction and intraocular lens implantation. All the patients had panuveitis except those with ankylosing spondylitis who had anterior uveitis. Two patients (52 and 57 years old, respectively) who had undergone elective cataract extraction, with no prior history of uveitis, served as controls. Patients were examined using slit-lamp biomicroscopy, indirect ophthalmoscopy and fluorescein angiography. In each patient, the uveitis activity was graded as previously described [14, 15]. Anterior chamber cells were clinically graded on a 0–5 scale as follows: 0 = <5 cells/field, 1+ = 5 to 10 cells/field, 2+ = 11 to 20 cells/field, 3+ = 21 to 50 cells/field, 4+ = >50 cells/field, 5+ = hypopyon formation. None of the patients was on topical or systemic therapy on presentation.

Aqueous humour (100–200  $\mu$ l) was aspirated from each patient by means of limbic paracentesis using a 27-gauge needle attached to a tuberculin syringe, after the application of topical local anaesthetic oxybuprocaine hydrochloride 0.4% (Benoxinate, Chauvin Pharmaceuticals Ltd., Kingston, England). The procedure was performed under a surgical microscope. The samples were snap-frozen and maintained at  $-70^{\circ}\text{C}$  until use. All aqueous humour samples from patients with uveitis were obtained before therapy. In two patients, repeated aqueous humour samples were obtained after treatment.

Post-mortem donor eyes, also used for corneal transplantations, were used to purify human IRBP to homogeneity. This donor tissue was obtained from the Ophthalmology Department of the University Hospital Leuven, Belgium.

All procedures followed the tenets of the Declaration of Helsinki, and informed consent was obtained from all patients and the control subjects. The study was approved by the Research Center, College of Medicine, King Saud University.

### Gel zymography and Western blot analysis

The presence of gelatinase B/MMP-9 in aqueous fluids was determined by zymography according to standardized laboratory protocols [15]. For immunoblot analysis, equal volumes of aqueous fluid were mixed with sample buffer and separated on 12% SDS-polyacrylamide gels. After electrophoresis was complete, the proteins were transferred from the gels to polyvinylidene difluoride (PVDF) membranes. The membranes were blocked with 5% non-fat dry milk in Tris-buffered saline containing 0.1% Tween 20 and then probed with a mouse monoclonal antibody raised against human IRBP, developed at the Wills Eye Hospital and kindly provided by Dr. L. Donoso [16]. After washing, the membrane was incubated with peroxidase-conjugated secondary antibody at room temperature for 1 hr. Finally, the proteins were detected using a chemiluminescence kit (ECL, Amersham Biosciences).

## ELISA

IgG concentrations in aqueous fluids were determined using a commercially available ELISA (Immundiagnostik AG, Bensheim, Germany). The solution optical density in individual wells was determined with an iEMS Reader MF (Labsystems, Helsinki, Finland) spectrophotometer.

## Purification of human IRBP

First, we established the purification procedure with bovine material. Bovine eyes were collected, the retinas removed and extracted as described [17]. Human IRBP purification was done on post-mortem donor retinas. Retinas were pooled in 0.14 M NaCl, 10 mM Tris solution (pH 7.0) (1ml/retina), stirred at low speed (20 rpm) and filtered through plastic mesh (0.8 mm pore size). Material from the internal surface of the retinal pigment epithelium (RPE), still in the eyecup, was extracted by rinsing with the same buffer. Filtered (0.2  $\mu$ m) crude extract was then stirred with 5 ml ConcanavalinA-Sepharose beads (Pharmacia) for 1 hr at room temperature. The supernatant was discarded and the beads washed two times with five volumes of carrier beads. IRBP was eluted by stirring the beads in 20 ml of 50 mM  $\alpha$ -methyl-D-mannoside (Sigma, St. Louis, MO, USA) in the same buffer. The supernatant from methylmannoside treatment was applied to a Pharmacia mono-Q column for anion exchange chromatography. Elution was carried out with a 0.1–0.5 M NaCl gradient in 10 mM Tris buffer (pH 7.5). IRBP, identified by SDS-PAGE and Western blot analysis, eluted at approximately 0.33 M NaCl and was about 90% pure. Further purification was accomplished by gel filtration chromatography on a Superose 75 column in 20 mM Tris/HCl pH7.4, 0.15 M NaCl.

## Preparation of neutrophilic degranulate

Neutrophils were isolated from human blood, re-suspended in degranulation buffer (20 mM Tris/HCl, pH 7.4, 113 mM NaCl, 10 mM CaCl<sub>2</sub>) at 10<sup>7</sup> cells per ml and stimulated to degranulate with 0.5  $\mu$ M formyl-methionyl-leucyl-phenylalanine (fMLP) at 37°C for 20 min. Subsequently, the cells were removed by centrifugation.

## Statistical analysis

Because of the large variances in the raw data for gelatinase B, IgG and IRBP, the correlations between these variables and the disease activity were investigated using Spearman's rank correlation coefficient. The differences were considered significant if the *P* value was <0.05.

## Results

### The presence of IRBP in aqueous humour samples is related to uveitic activity, gelatinase B content and blood-ocular barrier integrity

We measured IRBP immunoreactivity by Western blot analysis in aqueous humour samples. In parallel, gelatinase B/MMP-9 and

IgG levels were measured in aqueous humour samples, as parameters of immune cell activation and integrity of the blood-ocular barrier, and clinical disease activity was scored. Table 1 gives an overview of the data. In addition, on each zymography or Western blot analysis, a control aqueous humour sample and molecular weight standardization were included. Figure 1A shows the immunoreactivities of IRBP (top part) and IgG (lower part) in Western blot analysis and the gelatin zymographic analysis of MMP-9 (middle part). Gelatinase B and IgG were absent in control samples and gelatinase B zymolysis gradually increased with clinically increased disease activity. IgG levels increased in aqueous humour samples from patients with disease activity 4 and 5. Aqueous humour samples from control eyes and eyes with low disease activity showed positive immunoreactivity for intact IRBP. The IRBP signal weakened or disappeared with higher disease activity. In fact, patients with disease activity of 4 or 5 had markedly decreased intact IRBP. This disappearance substantiates proteolysis of IRBP.

With the use of scanning densitometry and appropriate standardization, we quantified gelatinase B/MMP-9 nM concentrations and levels of immunoreactive intact IRBP (expressed as scanning units), whereas IgG levels ( $\mu$ g/ml) were titrated by ELISA. Figure 1B summarizes these data and illustrates that the highest clinical uveitis scores (4 and 5) were associated with increased levels of MMP-9 and IgG and with decreased levels of intact IRBP. Table 2 shows Spearman's rank correlation coefficients between the studied variables. The levels of IgG and gelatinase B in aqueous humour samples from patients with uveitis were positively and significantly correlated with the disease activity. Significant negative correlations were found between the levels of IRBP and disease activity, the levels of IgG and of gelatinase B. A significant positive correlation was found between the levels of gelatinase B and IgG.

## Degradation of IRBP *in vitro*

Gelatinase A (MMP-2), elastase and cathepsin G activity were previously found in subretinal fluid of retinal detachment (RD) patients and were hypothesized to be important for the loosening of RPE cells from their monolayer [18]. Since IRBP is a secreted protein, we tested each of these enzymes as candidate proteases. Pure enzyme preparations were added to crude vitreous fluid containing full-length IRBP. Neutrophil elastase cleaved IRBP more efficiently compared to MMP-2 and cathepsin G (data not shown). Therefore, further characterization of the cleavage of IRBP by neutrophil elastase was performed. The degradation of human IRBP in function of time was investigated by sampling a 10  $\mu$ l reaction mixture containing 400 nM IRBP and 8 nM elastase (enzyme : substrate ratio = 1:50; incubation at 37°C). A Western blot analysis of 1  $\mu$ l samples, which were taken at various time-points, is shown in Fig. 2A. Almost complete degradation of full-length IRBP was obtained within 80 min. After 160 min., only a 55 kD fragment was detected in the reaction mixture. At other time-points, also other molecular weight degradation products were detected.

**Table 1** Clinical features and matrix metalloproteinase-9 (MMP-9), immunoglobulin G (IgG) and interphotoreceptor retinoid-binding protein (IRBP) levels

Diagnosis	Disease activity	MMP-9 SU/ml	IgG µg/ml	IRBP SU/ml
VKH	1+	0	0	25
VKH	1+	332	26	34
I	3+	778	0	194
I	4+	536	36	106
B	3+	272	0	175
VKH	4+	1320	158	0
VKH	4+	1145	225	0
B	2+	0	0	272
B	Hypopyon	1532	152	0
VKH	3+	1316	142	0
B	3+	205	0	126
B	4+	656	0	162
AS	3+	452	0	312
VKH	2+	152	0	161
VKH	2+	465	0	125
VKH	1+	538	0	97
VKH	1+	0	0	387
I	1+	0	0	212
B	Hypopyon	198	3	29
B	Hypopyon	4400	13	0
AS	2+	526	116	0
CE	4+	2812	77	0
B	3+	183	0	198
B	1+	0	0	212
VKH	3+		0	201
VKH	3+	71.6	0	245
CE	4+	1072.4	14	0
B	Hypopyon	1532	152	0

VKH, Vogt-Koyanagi-Harada disease; I, idiopathicuveitis; B, Behçet disease; AS = ankylosing spondylitis; CE = chronic endophthalmitis; MMP-9 = matrix metalloproteinase-9; IgG = immunoglobulin G; IRBP = interphotoreceptor retinoid-binding protein.

**Table 2** Spearman's correlation coefficients between clinical disease and laboratory parameters

	Disease activity	MMP-9 (SU/ml)	IgG (µg/ml)
MMP-9 (SU/ml)	$r_s = 0.713$ $P < 0.001^*$		
IgG (µg/ml)	$r_s = 0.580$ $P = 0.001^*$	$r_s = 0.696$ $P < 0.001^*$	
IRBP (SU/ml)	$r_s = -0.520$ $P = 0.005^*$	$r_s = -0.727$ $P < 0.001^*$	$r_s = -0.834$ $P < 0.001^*$

$r_s$  correlation coefficients and  $P$  values for the paired variables.

MMP-9, matrix metalloproteinase-9; IgG, immunoglobulin G;

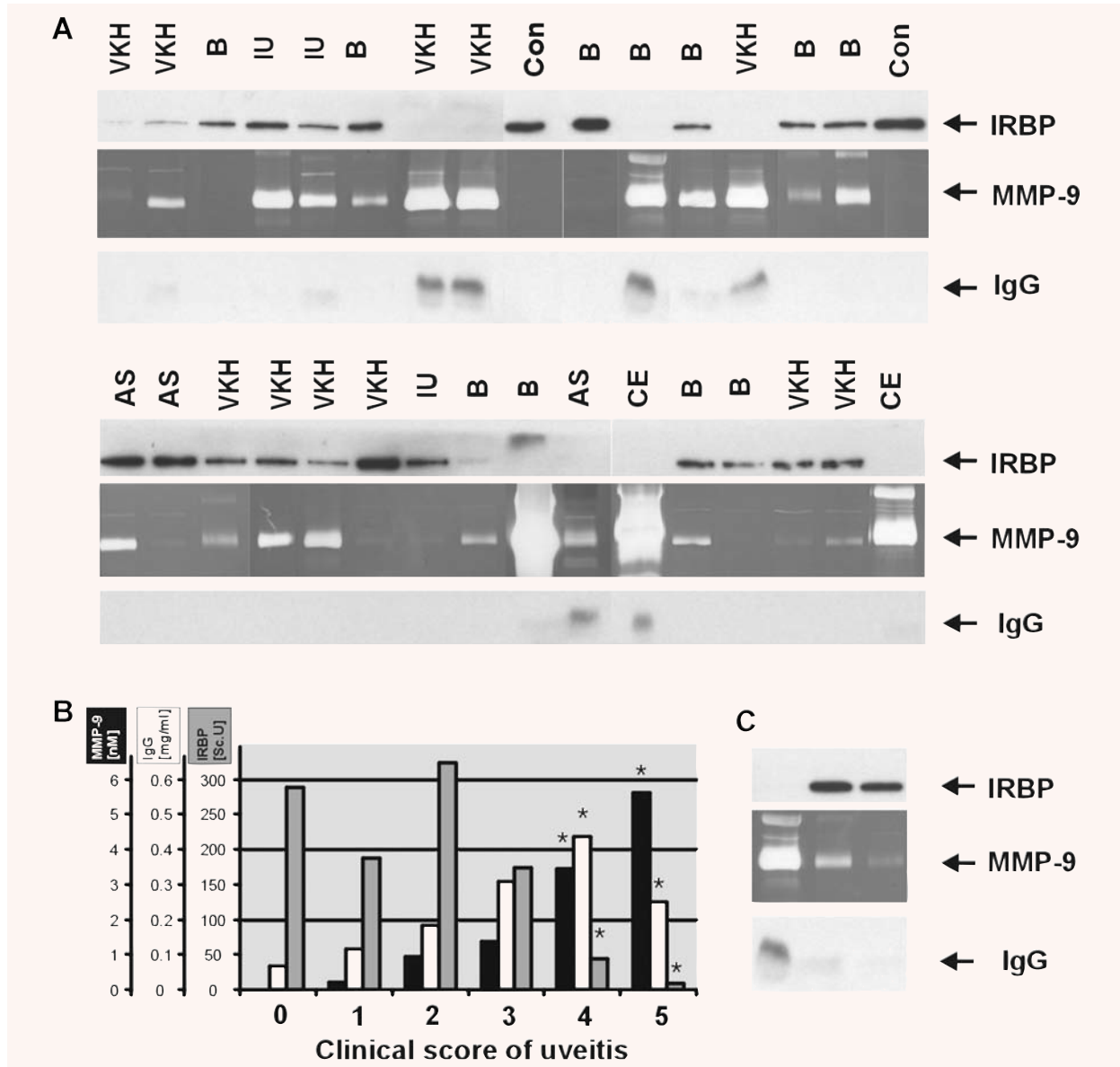
IRBP, interphotoreceptor retinoid binding protein.

\*Statistically significant at 5% level of significance.

As a representation of leukocyte protein release and a natural source of extracellular proteases, we used conditioned medium of human neutrophils that had been stimulated to degranulate with the bacterial formylpeptide fMLP. IRBP (400 nM) was incubated with 0.4 µl neutrophilic degranulate which is a physiologically relevant amount since it yields a final MMP-9 concentration that is comparable to that of aqueous humour samples from patients with uveitis (~1 nM). By the presence of other proteases in the neutrophil degranulate, IRBP was completely proteolysed, similarly as observed *in vivo*.

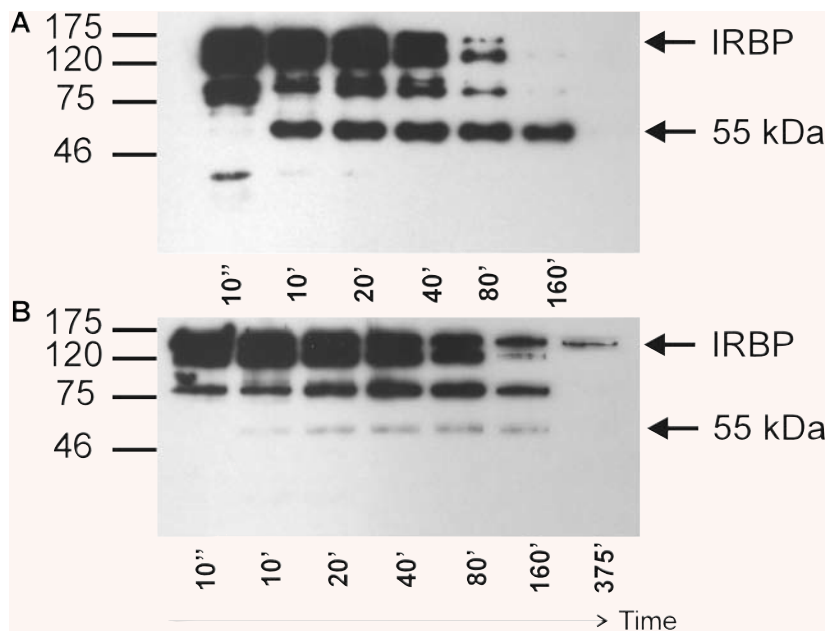
## Effect of treatment

The biological links between the used parameters were tested further by analysis of aqueous humour samples from two patients with systemic autoimmune disease with eye affliction, before and after treatment. One patient had uveitis (clinically scored 3) associated with ankylosing spondylitis before treatment (Fig. 1A, lower part, first lane from left). One week after topical corticosteroid treatment, MMP-9 disappeared (Fig. 1A, lower part, second lane from left). The other patient with Behçet disease had hypopyon before treatment, high IgG and MMP-9 levels and no detectable intact IRBP. The presence of the covalent complex between MMP-9 and neutrophil gelatinase B-associated lipocalin is a further indication of high neutrophil counts in the aqueous humour of this patient with Behçet disease (Fig. 1C). We could evaluate two additional serial samples after initiation of topical and systemic corticosteroids combined with cyclosporine A therapy in this patient. During this therapy, the MMP-9 and IgG levels gradually and progressively disappeared and intact IRBP reappeared. The re-appearance of intact IRBP in the aqueous fluid, concomitant with clinical improvement, further substantiates that IRBP breakdown is



**Fig. 1** Interphotoreceptor retinoid-binding protein (IRBP) degradation in uveitis **(A)** Analysis of patient samples and controls. The upper part shows the Western blot analyses of the  $\approx 140$  kD IRBP protein. The central part with dark background is the gelatin zymography test and the lower part visualizes immunoglobulin G (IgG) immunoreactivity. The diagnoses of patients are abbreviated as follows: VKH, Vogt-Koyanagi-Harada; B, Behçet; I, idiopathic uveitis; AS, ankylosing spondylitis; CE, chronic endophthalmitis; con, control sample. **(B)** Parametric analysis according to clinical scores of uveitis. Gelatinase B/MMP-9 scanning units were titrated by zymography analysis and compared with a pure preparation of human MMP-9 to convert the data to nM concentrations. IgG was assessed by ELISA and expressed in mg/ml, whereas IRBP levels were densitometrically scanned and are expressed as arbitrary scanning units per  $\mu$ l. \* denotes significant difference ( $p < 0.05$ ) from group with clinical score 0. **(C)** Effect of topical and systemic corticosteroids and cyclosporine A therapy in a patient with Behçet disease and hypopyon. The first lane shows the analysis before treatment was started, that is complete absence of IRBP immunoreactivity, high levels of MMP-9 and covalent neutrophil gelatinase B-associated lipocalin (NGAL) complex and of IgG. The second lane illustrates that, 1 week after the initiation of treatment, IRBP reappears, while MMP-9 and IgG levels decrease. Finally in the third lane, 2 weeks after treatment, IRBP remains prominently visible, while MMP-9 is barely and IgG is not detectable.





**Fig. 2** IRBP is cleaved *in vitro* by neutrophil enzymes (**A**) Human IRBP was purified and incubated for different time intervals with neutrophil elastase. Samples were analysed by Western blot with an IRBP-specific antibody. The arrow indicates the 55 kD cleavage product. (**B**) When degranulates of fMLP-stimulated human neutrophils were used as source of enzymes, the 55 kD reaction product of IRBP generated by neutrophil elastase (arrow) is degraded by other proteinases. In this instance, the disappearance of immunoreactivity at  $\approx 140$  kD is a measure of IRBP proteolysis. Incubation times are indicated in minutes; at the left a molecular mass standardization is included in kD.

a useful marker of uveitic inflammation, whereas regaining intact IRBP may be a sign of effective treatment.

## Discussion

An important trigger for the loss of tolerance towards autoantigens is the conversion – by some means – of the hidden nature of a particular autoantigen to a more accessible nature, which facilitates antigen presentation and subsequent activation of autoreactive T cells. With reference to AU, the anatomical blood-ocular barrier makes the eye an immunoprivileged organ, masking IRBP and other AU-related autoantigens. Breakdown of the blood-ocular barrier is therefore a crucial step for the development of autoimmunity. In addition, the extracellular degradation of autoantigens themselves abolishes a molecular barrier, which may hide immunodominant epitopes inside the molecule.

IRBP is a 136 kD glycoprotein synthesized in photoreceptors and secreted into the interphotoreceptor matrix (IPM). It has been suggested that IRBP plays a role in the trafficking of 11-*cis* retinal and all *trans* retinol between photoreceptors and the RPE, as a part of the rod visual cycle. IRBP was originally considered to be unique for the IPM but recently, IRBP (among other components of the rod visual cycle) was also shown to be expressed in the ciliary epithelium, distributed along the non-pigmented epithelial cells, and secreted into the aqueous humour [19]. This may shed new light on the hidden nature of IRBP and its role of dominant autoantigen [6, 20]. The aqueous

is indeed less safe for antigens to stay hidden, since it is constantly renewed by the ciliary body and irrigated *via* the trabecular meshwork into the serum. Yet, IRBP was never detected in serum and was suggested to accumulate in the aqueous [19].

We confirmed intact IRBP to be present in normal aqueous humour, but meanwhile demonstrate its absence in a uveitic context. Seeing the correlation between uveitic activity both with gelatinase B levels and IgG levels, we may think of two factors that may determine the disappearance of IRBP from the aqueous humour. First, blood-ocular barrier integrity may be important for IRBP not to leak to the plasma, similar to retention of IgGs on the other side of the barrier. Second, the proteolytic activity in the aqueous may result in IRBP degradation, considering gelatinase B as a measure and marker for total proteolytic activity released upon activation of leukocytes. In concordance, we showed IRBP to be highly susceptible to cleavage by neutrophilic degranulate, as a representation of leukocyte-released proteinase. The neutrophil is a predominant infiltrating cell in ocular diseases as demonstrated for endotoxin-induced uveitis [21, 22] and experimental autoimmune uveoretinitis [23, 24]. Moreover, neutrophil accumulation correlates with MMP-9 activity in endotoxin-induced uveitis [12]. Both pure leukocyte elastase and, to a lesser extent, pure gelatinase B (data not shown) can degrade IRBP, but only the cleavage pattern generated by neutrophilic degranulate resembled the data from *in vivo* samples. Together, this suggests that leukocyte elastase is an IRBP degrading protease and that other proteases may participate in the further degradation of IRBP. IRBP-peptides may then reach secondary lymphoid organs and thus initiate (or exacerbate) the

immune response against IRBP, according to the REGA concept or remnant epitopes generate autoimmunity [25]. In addition to the relevance of proteolysis in autoantigen processing in the heterogeneous groups of AU conditions [6–10, 26], the concept is also applicable in other forms of eye inflammation, including chronic endophthalmitis, infections and idiopathic forms of eye inflammation [27].

Finally, our study also demonstrates that reversal of IRBP degradation, and hence avoidance of a positive autoimmune feedback loop, is obtained after immunosuppressive therapy. We show that corticosteroids, known to reduce cellular MMP-9 and MMP-2 production *in vitro* [28], also reduce MMP-9 levels *in vivo*, diminish IgG levels, which might indicate a restoration of

the blood-ocular barrier, and result in the re-appearance of intact IRBP. The analysis of intact IRBP is thus not only a marker of absence of inflammation, but also of regression of disease by adequate treatment.

## Acknowledgements

The present study was supported by the Geconcerteerde Onderzoeksacties (GOA 2006-2010), the Centre of Excellence (EF/05/015), the Charcot Foundation of Belgium and the Fund for Scientific Research-Flanders.

## Reference

1. Agrawal S, Anderson P, Durbeej M, van Rooijen N, Ivars F, Opdenakker G, Sorokin LM. Dystroglycan is selectively cleaved at the parenchymal basement membrane at sites of leukocyte extravasation in experimental autoimmune encephalomyelitis. *J Exp Med.* 2006; 203: 1007–79.
2. Cauwe B, Van den Steen PE, Opdenakker G. The biochemical, biological and pathological kaleidoscope of cell surface substrates processed by matrix metalloproteinases. *Crit Rev Biochem Mol Biol.* 2007; 42: 113–85.
3. Santambrogio L, Sato AK, Carven GJ, Belyanskaya SL, Strominger JL, Stern LJ. Extracellular antigen processing and presentation by immature dendritic cells. *Proc Natl Acad Sci USA.* 1999; 96: 15056–61.
4. Proost P, Van Damme J, Opdenakker G. Leukocyte gelatinase B cleavage releases encephalitogens from human myelin basic protein. *Biochem Biophys Res Commun.* 1993; 192: 1175–81.
5. Van den Steen PE, Proost P, Grillet B, Brand DD, Kang AH, Van Damme J, Opdenakker G. Cleavage of denatured natural collagen type II by neutrophil gelatinase B reveals enzyme specificity, post-translational modifications in the substrate, and the formation of remnant epitopes in rheumatoid arthritis. *FASEB J.* 2002; 16: 379–89.
6. Lambe T, Leung JC, Ferry H, Bouriez-Jones T, Makinen K, Crockford TL, Jiang HR, Nickerson JM, Peltonen L, Forrester JV, Cornall RJ. Limited peripheral T cell anergy predisposes to retinal autoimmunity. *J Immunol.* 2007; 178: 4276–83.
7. Yamaki K, Gocho K, Hayakawa K, Kondo I, Sakuragi S. Tyrosinase family proteins are antigens specific to Vogt-Koyanagi-Harada disease. *J Immunol.* 2000; 165: 7323–9.
8. Imai Y, Sugita M, Nakamura S, Toriyama S, Ohno S. Cytokine production and helper T cell subsets in Vogt-Koyanagi-Harada disease. *Curr Eye Res.* 2001; 22: 312–18.
9. Pay S, Simsek I, Erdem H, Dinç A. Immunopathogenesis of Behçet's disease with special emphasis on the possible role of antigen presenting cells. *Rheumatol Int.* 2007; 27: 417–24.
10. Khan MA, Mathieu A, Sorrentino R, Akkoc N. The pathogenetic role of HLA-B27 and its subtypes. *Autimmun Rev.* 2007; 6: 183–9.
11. Meisler DM, Mandelbaum S. Propionibacterium-associated endophthalmitis after cataract extraction. Review of reported cases. *Ophthalmol.* 1989; 96: 59–61.
12. Cuello C, Wakefield D, Di Girolamo N. Neutrophil accumulation correlates with type IV collagenase/gelatinase activity in endotoxin induced uveitis. *Br J Ophthalmol.* 2002; 86: 290–5.
13. Wang M, Bai F, Pries M, Buus S, Prause JU, Nissen MH. Identification of MHC Class I H-2 K<sup>b</sup>/D<sup>b</sup>-restricted immunogenic peptides derived from retinal proteins. *Invest Ophthalmol Vis Sci.* 2006; 47: 3939–45.
14. Forrester JV, Ben Ezra D, Nussenblatt RB, Tabbara KF, Timonen P. Grading of intermediate and posterior uveitis. In: Tabbara KF, Nussenblatt RB, editors. Posterior uveitis: diagnosis and management. Boston: Butterworth-Heinemann; 1994. p. 5–18.
15. Abu El-Asrar AM, Struyf S, Descamps FJ, Al-Obeidan SA, Proost P, Van Damme J, Opdenakker G, Geboes K. Chemokines and gelatinases in the aqueous humor of patients with active uveitis. *Am J Ophthalmol.* 2004; 138: 401–11.
16. Tighe PJ, Powell-Richards A, Sewell HF, Fischer D, Donoso L, Dua HS. Epitope discovery using bacteriophage display: the minimum epitope of an anti-IRBP antibody. *Exp Eye Res.* 1999; 68: 679–84.
17. Adler AJ, Chader GJ, Wiggert B. Purification and assay of interphotoreceptor retinoid-binding protein from the eye. *Methods Enzymol.* 1990; 89: 213–23.
18. Immonen I, Kontinen YT, Sorsa T, Tommila P, Siren V. Proteinases in subretinal fluid. *Graefes Arch Clin Exp Ophthalmol.* 1996; 234: 105–9.
19. Salvador-Silva M, Ghosh S, Bertazzoli-Filho R, Boatright JH, Nickerson JM, Garwin GG, Saari JC, Coca-Prados M. Retinoid processing proteins in the ocular ciliary epithelium. *Mol Vis.* 2005; 11: 356–65.
20. Dua HS, Abrams M, Barrett JA, Gregerson DS, Forrester JV, Donoso LA. Epitopes and idiotypes in experimental autoimmune uveitis: a review. *Curr Eye Res.* 1992; 11: 59–65.
21. Jacquemin E, de Kozak Y, Thillaye B, Courtois Y, Goureau O. Expression of inducible nitric oxide synthase in the eye from endotoxin-induced uveitis rats. *Invest Ophthalmol Vis Sci.* 1996; 37: 1187–96.
22. McMenamin PG, Crewe J. Endotoxin-induced uveitis. Kinetics and phenotype of the inflammatory cell infiltrate and the

- response of the resident tissue macrophages and dendritic cells in the iris and ciliary body. *Invest Ophthalmol Vis Sci.* 1995; 36: 1949–59.
23. **Gritz DC, Montes C, Atalla LR, Wu GS, Sevanian A, Rao NA.** Histochemical localization of superoxide production in experimental autoimmune uveitis. *Curr Eye Res.* 1991; 10: 927–31.
  24. **Wu GS, Zhang J, Rao NA.** Peroxynitrite and oxidative damage in experimental autoimmune uveitis. *Invest Ophthalmol Vis Sci.* 1997; 38: 1333–9.
  25. **Opdenakker G, Van Damme J.** Cytokine-regulated proteases in autoimmune diseases. *Immunol Today.* 1994; 15: 103–7.
  26. **DeVoss J, Hou Y, Johannes K, Lu W, Liou GI, Rinn J, Chang H, Caspi RR, Fong L, Anderson MS.** Spontaneous autoimmunity prevented by thymic expression of a single self-antigen. *J Exp Med.* 2006; 203: 2727–35.
  27. **Levinson RD.** Immunogenetics of ocular inflammatory disease. *Tissue Antigens.* 2007; 69: 105–12.
  28. **Shapiro SD, Campbell EJ, Kobayashi DK, Welgus HG.** Dexamethasone selectively modulates basal and lipopolysaccharide-induced metalloproteinase and tissue inhibitor of metalloproteinase production by human alveolar macrophages. *J Immunol.* 1991; 146: 2724–9.