



Case report

Management of cerebrospinal fluid leak in the lateral recess of the sphenoid sinus with transpterygoid approach: A case report

Moudi Merlin Mona, Budi Sutikno*

Department of Otorhinolaryngology-Head and Neck Surgery, Faculty of Medicine, Universitas Airlangga – Dr. Soetomo General Academic Hospital, Surabaya, Indonesia

ARTICLE INFO

Keywords:

Cerebrospinal fluid leak
Lateral sinus sphenoid
Rhinology disease
Transethmoid-pterygoid endoscopy

ABSTRACT

Background: Cerebrospinal fluid (CSF) leak that occurred in the lateral sphenoid sinus is a rare and difficult case. This paper aims to report a case of defect closure in the lateral recess of the sphenoid sinus endoscopically with a transpterygoid approach.

Case presentation: A 38-year-old Indonesian woman reported a CSF leak, and identified a defect in the lateral recess of the left sphenoid sinus. CSF leak was repaired with endoscopic transtethmoid-pterygoid or transpterygoid endoscopic surgery and no CSF leak was found. The surgical procedure was successful even though it was only performed by an otorhinolaryngologist.

Discussion: Endoscopic transtethmoid-pterygoid or transpterygoid endoscopic surgery is effective in repairing defects in the lateral recess of the sphenoid sinus in which surgical procedure is performed by a single otorhinolaryngologist.

Conclusion: Endoscopic transpterygoid approach gained access to lateral site of sphenoid sinus was an effective approach in managing CSF leak of lateral sphenoid recess. Closure of the defect using a bone graft and mucosa of the middle turbinate was proven to be effective. It had been carried out successfully in Indonesia.

1. Introduction

Cerebrospinal fluid (CSF) leak is a rare condition, that can lead to meningitis if not diagnosed quickly and correctly [1,2]. A CSF leakage can be caused by 80%–90% trauma or 4%–10% non-trauma [2] in which there are 14–55% of idiopathic reported in non-traumatic cases [3]. A CSF leak in the lateral sphenoid sinus can be repaired with a transtethmoidal-pterygoid or endoscopic endonasal transpterygoid approach [4,5]. In Indonesia, cases of cerebrospinal fluid leakage are very rare, so we are interested in reporting them based on the 2020 surgical case report (SCARE) guidelines [6].

2. Case presentation

A 38-year-old Indonesian woman complained of clear discharge from her left nose for eight months every day in Dr. Soetomo General Academic Hospital, Surabaya, Indonesia. The watery discharge came out spontaneously, not continuously, increased when the patient is in a sitting position, head down, straining, and tasted salty. There were no

complaints of nasal obstruction, nasal pain, headache, olfactory disturbances, and eye disorders. No abnormality was found in the right nasal cavity. The patient had a history of meningioma nine months ago. Rhinorrhea was found in the left nasal cavity, no mucosal edema or hyperemia was found, the right nasal cavity was normal. The handkerchief test did not reveal any residual-colored liquid or changes in the stiffness of the fabric [7]. Nasoendoscopy revealed clear fluid came out from the left sphenoid ostium. CT scan of the paranasal sinuses showed an opacity of fluid density in the lateral recess of the left sphenoid sinus (Fig. 1).

The surgery was performed under general anesthesia by a single otorhinolaryngologist. The evaluation of the left nasal cavity showed clear watery fluid in the left sphenoid recess came out of the left sphenoid sinus ostium. The surgery began with partial resection of the left middle turbinate, uncinectomy, middle meatal antrostomy, widening to the posterior wall of the maxillary sinus, anterior ethmoidectomy, removing the basal lamella of middle and superior turbinates, and posterior ethmoidectomy. The process continued with partial resection of superior turbinate and sphenoidectomy, identification of

* Corresponding author: Budi Sutikno, Department of Otorhinolaryngology-Head and Neck Surgery, Faculty of Medicine, Universitas Airlangga – Dr. Soetomo General Academic Hospital, Jl. Mayjend Prof. Dr. Moestopo No. 6-8, Airlangga, Gubeng, Surabaya, East Java 60286, Indonesia.

E-mail addresses: budi-s@fk.unair.ac.id, budisutikno104@gmail.com (B. Sutikno).

<https://doi.org/10.1016/j.ijscr.2021.106594>

Received 21 September 2021; Received in revised form 7 November 2021; Accepted 9 November 2021

Available online 12 November 2021

2210-2612/© 2021 Published by Elsevier Ltd on behalf of IJS Publishing Group Ltd. This is an open access article under the CC BY-NC-ND license

(<http://creativecommons.org/licenses/by-nc-nd/4.0/>).

the sphenopalatine foramen, ligation of the sphenopalatine artery and its branches. The medial aspect of the posterior wall of the maxillary sinus was partially removed. The upper portion of the medial pterygoid process of the sphenoid bone was also removed by Kerrison rongeur. A sphenoidectomy was widened laterally, revealing a bony defect characterized by meningocele and CSF flow in the anterosuperolateral sphenoid recess (Fig. 2).

Meningocele was reduced by bipolar cauterization, the sphenoid sinus mucosa was removed, the defect was closed with an inlay insertion of a middle turbinate bone graft, a middle turbinate mucosal graft was evaluated, no more CSF flow was found, fibrin glue was applied, and absorbable hemostatic agent (Surgicel®) and gelfoam were placed (Fig. 3). Fifty milliliters of bleeding, no CSF flow was found on the final inspection intraoperatively. Postoperatively, the patient received 1 g of ceftriaxone twice daily intravenously, 15 mL of oral laxative three times daily. Bed rest with head elevation 15–30° for seven days postoperatively.

Seven days after surgery, the patient was discharged with the oral antibiotic ciprofloxacin 500 mg twice daily. Two weeks postoperatively, nasal washing with 0.9% NaCl was started twice daily. The patient was advised not to strain, lean forward, and weight lifting of more than seven kilograms for two weeks, and open mouth whilst sneezing or coughing. The postoperative visit on one, two, four, and six months showed no CSF leakage. The patient was followed up for up to two years and had serial visits every 6 months (Fig. 4).

3. Discussion

A CSF leak in the lateral recess of the sphenoid sinus is suspected to be due to a congenital abnormality of Sternberg's canal dehiscence, exacerbated by a history of meningiomas in which the tumor was increasing intracranial pressure resulting in CSF leakage [8]. The etiology of CSF leak is congenital, tumor-related, traumatic, and idiopathic [9]. Non-traumatic CSF rhinorrhea is more common in adult women >30 years old, with a ratio of 1:2 for men and women [9]. A CSF leak can occur at any location, including defects in the lamina cribrosa 35%, sphenoid sinus 26%, anterior ethmoid 18%, frontal sinus 10%, posterior ethmoid 9%, and inferior clivus 2% [8,9]. Symptoms of rhinorrhea due to CSF leak are clear watery discharge [10]. Rhinorrhea can be persistent or intermittent, usually unilateral and associated with changes in position or certain activities [10].

The teapot sign test was carried out on patients with positive results [11], followed by a handkerchief test that did not leave a mark and did not change the stiffness of the handkerchief so that a CSF leak was

suspected [7]. Identification of suspicious CSF leak includes the teapot sign test, handkerchief test, and β 2-transferrin [12]. The nasoendoscopy finding with clear watery discharge in the sphenoid recess is suspected a CSF [3]. Nasoendoscopy is performed to identify the site of the CSF leak but can be negative in some cases [13]. CT scan is the best diagnostic option for identifying skull base defects [3,13]. Skull base defects can be identified by CT scan in 80% of cases [3,13].

Factors contributing to CSF leak in the sphenoid sinus are congenital skull base defects, tumors, trauma, and increased intracranial pressure [14]. Lateral wall defects of the sphenoid sinus accounted for 9.8% of the normal population at autopsy [14,15]. Most CSF leaks close spontaneously within 7–10 days; non-closing CSF leaks increase the risk of meningitis [16]. The treatment of choice for CSF leak in the lateral sphenoid sinus recess defect is transnasal endoscopic surgery that has become the standard for repairing CSF leaks with low morbidity and a highly successful rate of 90% [15,16].

A transpterygoid approach is an option for defects closure in the lateral sphenoid recess due to its ability to expose the lateral sphenoid recess [17]. This approach involves performing a partial or total middle turbinate resection [17]. Maxillary sinuses are opened widely, anterior and posterior ethmoidectomy, and sphenoidectomy [18]. The optic nerve and internal carotid artery are identified. The sphenopalatine artery is identified and cauterized [18]. The medial pterygoid process is removed so that the lateral extension of the sphenoid sinus can be seen [17,18]. Bone and mucosal grafts of the middle turbinate are used to close the defect, in combination with fibrin glue and gelfoam [17]. The sphenoid sinus mucosa around the defect is removed as cleanly as possible with a curette so that the graft adheres to the surface of the defect well [18]. There is no CSF flow during the evaluation of surgical duration after insertion of bone grafts and mucosa of the middle turbinate [19]. The graft to cover the defect can be fat, fascia, mucosa, bone, cartilage, synthetic material, or a combination of these materials [17–19].

Antibiotics are given to prevent meningitis, although this is still a matter of debate [17]. Antibiotics can significantly reduce the incidence of meningitis [17]. Restrictions on patient activity are advised postoperatively [18]. Bed rest with head elevation 15–30° for seven days to prevent an increase in intracranial pressure which can lead to the release of the graft [17,18]. Bed rest with the head elevated or reverse Trendelenburg is to prevent increased intracranial pressure [17–20].

4. Conclusion

A case report of a 38-year-old Indonesian woman with CSF leak in

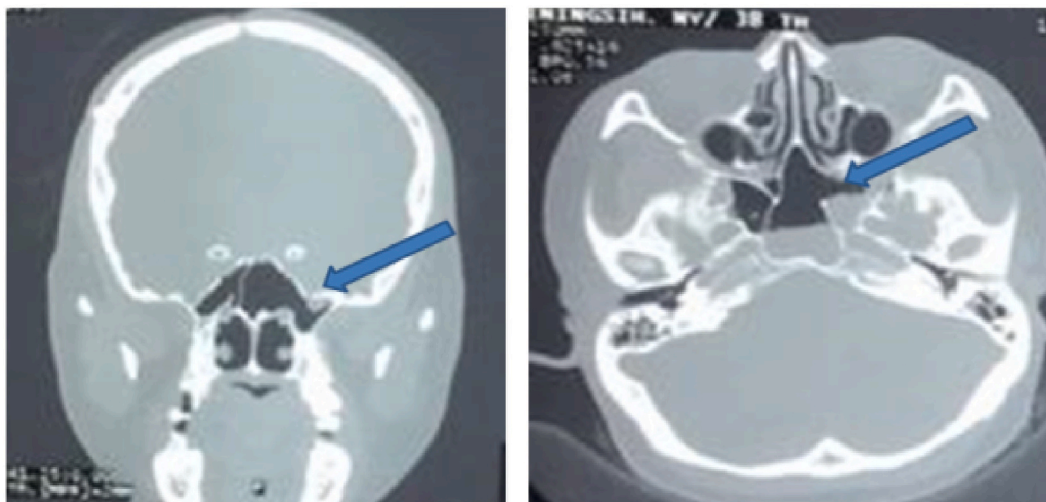


Fig. 1. Axial and coronal CT scan of the paranasal sinuses shows an opacity of fluid density in the lateral recess of the left sphenoid sinus (arrow).

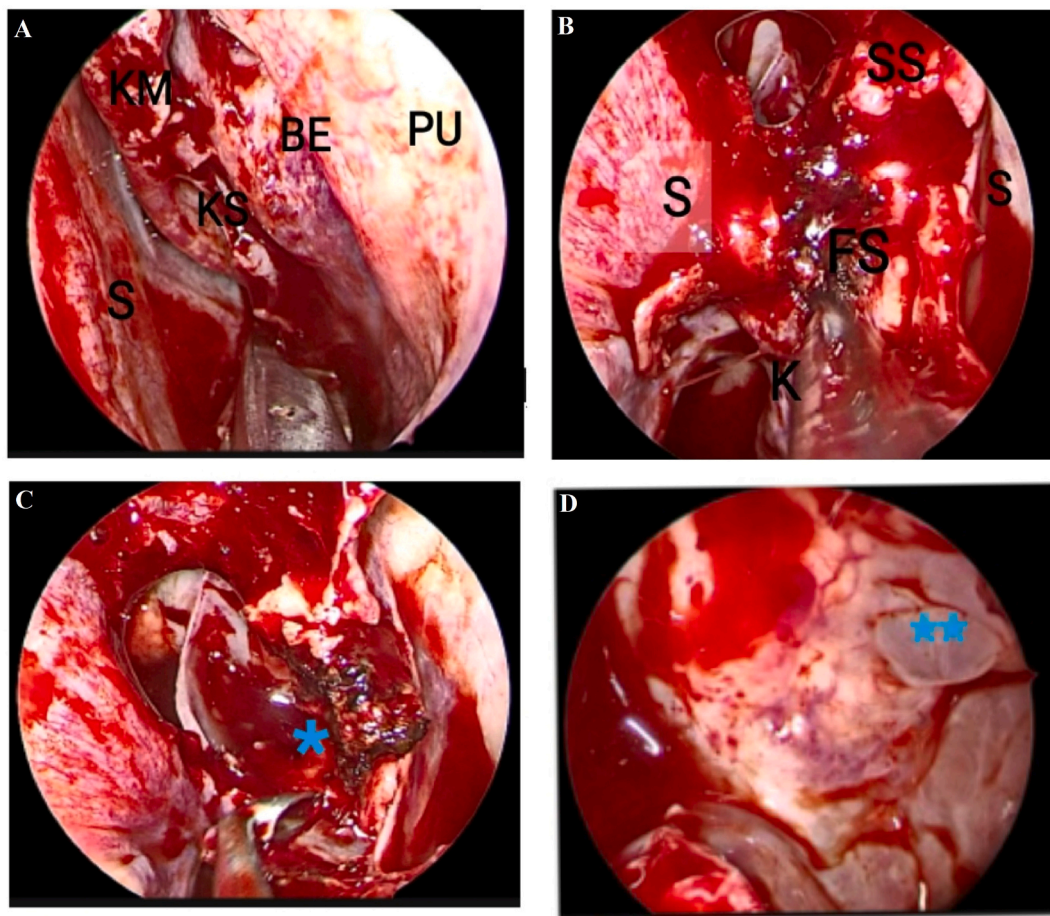


Fig. 2. Left nasal cavity. A. Resection of the middle turbinate, B. sphenoidectomy, C. lateral recess of the sphenoid sinus (*), D. bone defect is seen marked by anterosuperolateral meningocele (**). Seen on the image (S) of the septum, (KM) of the remnant of the middle turbinate, (BE) ethmoid bulla, (KS) superior turbinate, (PU) unciniate process, (FS) sphenopalatine foramen, (SM) maxillary sinus, (SS) sphenoid sinus, (K) choana.

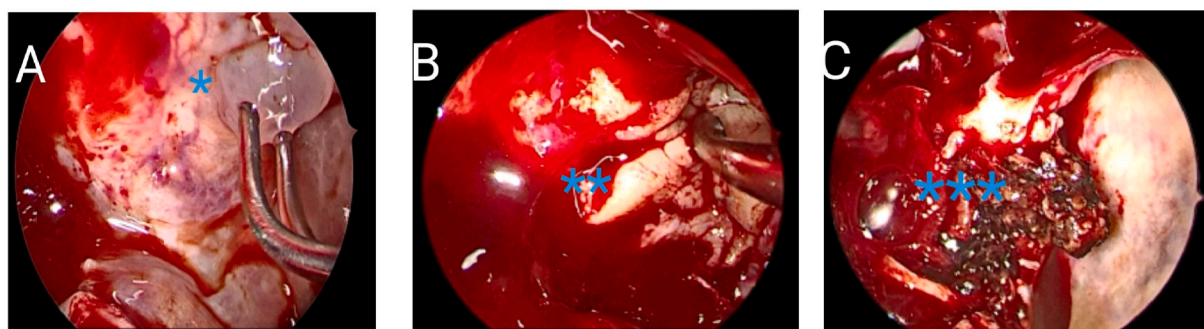


Fig. 3. Left nasal cavity. A. Meningocele bipolar cauterization (*), B. bone and mucosal graft of middle turbinate (**), C. fibrin glue and gelfoam layer (***)

the lateral recess of the sphenoid sinus who underwent endoscopic sinus surgery with transpterygoid approach by a single otorhinolaryngologist. Defect closure was successfully performed using bone and mucosal graft of the middle turbinate. Postoperative nasoendoscopy evaluation on one, two, four, and six months showed no leakage, the graft was viable and attached to its position.

Consent

Written informed consent was obtained from the patient for publication of this case report and accompanying images. A copy of the written consent is available for review by the editor-in-chief of this

journal on request.

Provenance and peer review

Not commissioned, externally peer-reviewed.

Ethical approval

We have conducted an ethical approval based on the Declaration of Helsinki at the Ethical Committee in Dr. Soetomo General Academic Hospital, Surabaya, Indonesia.

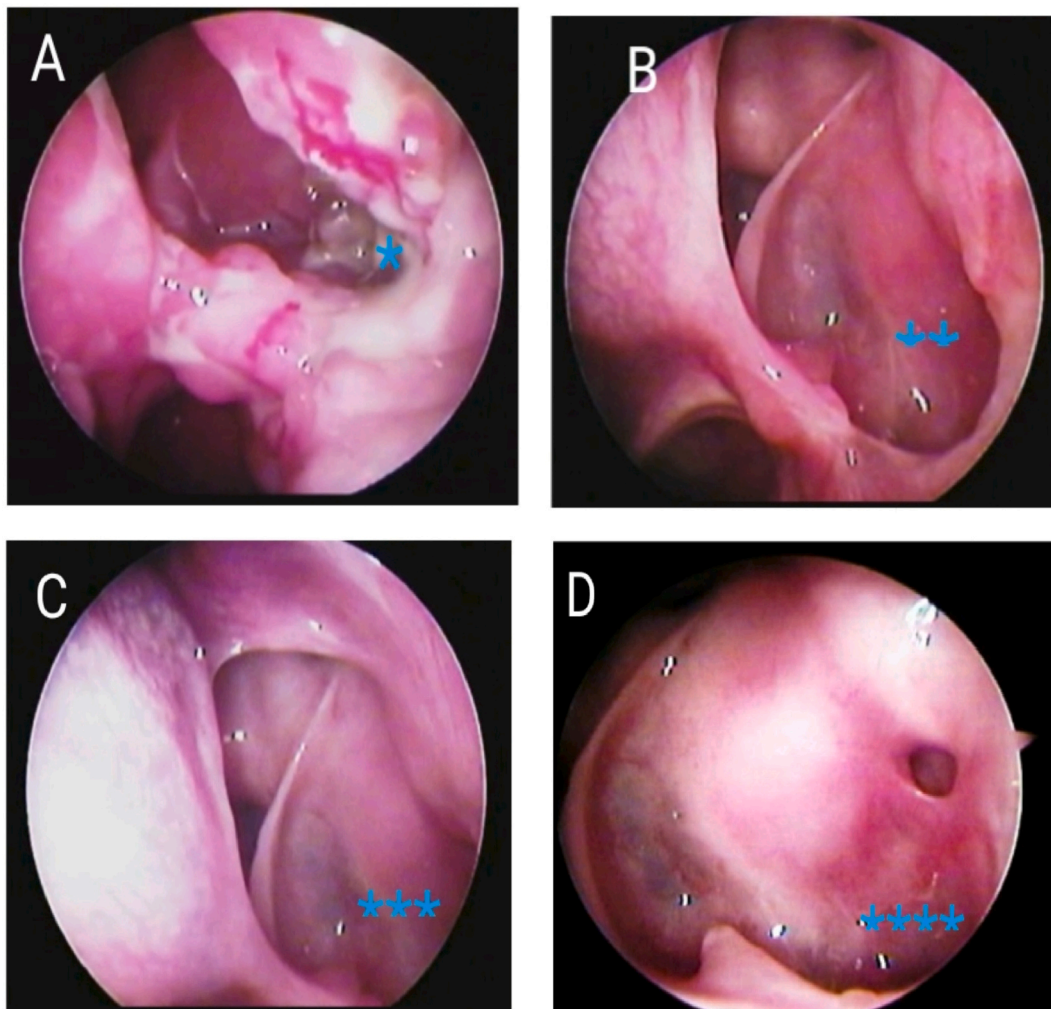


Fig. 4. Nasoendoscopy of the left nasal cavity showed no CSF leak, the mucosal graft was attached to its position. A. One month (*), B. two months (**), C. four months (***), D. six months postoperatively (****).

Funding

None.

Guarantor

Budi Sutikno.

Research registration number

Not applicable.

Credit authorship contribution statement

All authors contributed toward data analysis, drafting and revising the paper, gave final approval of the version to be published and agree to be accountable for all aspects of the work.

Declaration of competing interest

The authors declare that they have no conflict of interest.

Acknowledgment

The authors would like to thank Fis Citra Ariyanto for editing and

proofing assistance.

References

- [1] J.S. Virk, B. Elmiyeh, H.A. Saleh, Endoscopic management of cerebrospinal fluid rhinorrhea: the charing cross experience, *J.Neurol.Surg.B Skull Base* 74 (2) (2013) 61–67, <https://doi.org/10.1055/s-0033-1333620>.
- [2] A. Keshri, R. Jain, R.S. Manogaran, S. Behari, D. Khatri, A. Mathialagan, Management of spontaneous CSF rhinorrhea: an institutional experience, *J.Neurol. Surg.B Skull Base* 80 (5) (2019) 493–499, <https://doi.org/10.1055/s-0038-1676334>.
- [3] A.S. Enghard, V. Volgger, A. Leunig, C.S. Meßmer, G.J. Ledderose, Spontaneous nasal cerebrospinal fluid leaks: management of 24 patients over 11 years, *Eur. Arch. Oto-rhino-laryngol.* 275 (10) (2018) 2487–2494, <https://doi.org/10.1007/s00405-018-5089-y>.
- [4] N.S. Alexander, M.R. Chaaban, K.O. Riley, B.A. Woodworth, Treatment strategies for lateral sphenoid sinus recess cerebrospinal fluid leaks, *Arch.Otolaryngol.Head Neck Surg.* 138 (5) (2012) 471–478, <https://doi.org/10.1001/archoto.2012.614>.
- [5] A.Z. Maxfield, S.K. Mueller, A.R. Raquib, A.R. Sedaghat, R.W. Bergmark, R. B. Metson, et al. 5(3) (2020) 375–380, <https://doi.org/10.1002/lio2.412>.
- [6] R.A. Agha, T. Franchi, C. Sohrabi, G. Mathew, A. Kerwan, The SCARE 2020 guideline: updating consensus Surgical CAse REport (SCARE) guidelines, *Int.J. Surg.(Lond.Engl.)* 84 (2020) 226–230, <https://doi.org/10.1016/j.ijsu.2020.10.034>.
- [7] J.W. Oh, S.H. Kim, K. Whang, Traumatic cerebrospinal fluid leak: diagnosis and management, *Korean J. Neurotrauma* 13 (2) (2017) 63–67, <https://doi.org/10.13004/kjnt.2017.13.2.63>.
- [8] B.C. Lobo, M.M. Baumanis, R.F. Nelson, Surgical repair of spontaneous cerebrospinal fluid (CSF) leaks: a systematic review, *Laryngoscope Investig. Otolaryngol.* 2 (5) (2017) 215–224, <https://doi.org/10.1002/lio2.75>.
- [9] N. Kim-Orden, J. Shen, M. Or, K. Hur, G. Zada, B. Wrobel, Endoscopic endonasal repair of spontaneous cerebrospinal fluid leaks using multilayer composite graft

- and vascularized pedicled nasoseptal flap technique, *Allergy Rhinol.* 10 (2019), 2152656719888622, <https://doi.org/10.1177/2152656719888622>.
- [10] C. Martín-Martín, G. Martínez-Capoccioni, R. Serramito-García, F. Espinosa-Restrepo, Surgical challenge: endoscopic repair of cerebrospinal fluid leak, *BMC Res. Notes* 5 (2012) 459, <https://doi.org/10.1186/1756-0500-5-459>.
- [11] T.N. Janakiram, V. Subramaniam, P. Parekh, Endoscopic endonasal repair of sphenoid sinus cerebrospinal fluid leaks: our experience, *Indian J. Otolaryngol. Head Neck Surg.* 67 (4) (2015) 412–416, <https://doi.org/10.1007/s12070-015-0924-6>.
- [12] A.E. Kita, D.W. Bradbury, Z.D. Taylor, D.T. Kamei, M.A. St John, Point-of-care cerebrospinal fluid detection, *Otolaryngology–head and neck surgery : official journal of American Academy of otolaryngology-head and neckSurgery* 159 (5) (2018) 824–829, <https://doi.org/10.1177/0194599818789075>.
- [13] M.A. Eryilmaz, M. Arıçgil, M.A. Alan, Multilayered closure of cerebrospinal fluid rhinorrhea with inlay fascia lata, autologous fat, and outlay fascia lata: our experience, *ORL J. Otorhinolaryngol. Relat. Spec.* 78 (5) (2016) 289–295, <https://doi.org/10.1159/000451002>.
- [14] M. Tomaszewska, E. Brożek-Mądry, A. Krzeski, Spontaneous sphenoid sinus cerebrospinal fluid leak and meningoencephalocele - are they due to patent Sternberg's canal? *Wideochirurgia i inne techniki maloinwazyjne = Videosurgery and other miniinvasive techniques.* 10 (2) (2015) 347–358, <https://doi.org/10.5114/wiitm.2014.47097>.
- [15] G. Bozkurt, M. Turri-Zanoni, E. Coden, F. Russo, H.A. Elhassan, S. Gallo, et al., Endoscopic endonasal transpterygoid approach to sphenoid sinus lateral recess defects, *J. NeuroL. Surg. B Skull Base* 81 (5) (2020) 553–561, <https://doi.org/10.1055/s-0039-1692639>.
- [16] M.N. El-Tarabishi, S.A. Fawaz, S.M. Sabri, M.M. El-Sharnobi, A. Sweed, A modification of endoscopic endonasal approach for management of encephaloceles in sphenoid sinus lateral recess, *European archives of Oto-rhinolaryngology : official journal of the european Federation of Oto-Rhino-Laryngological Societies (EUFOS): affiliated with the german Society for Oto-Rhino-Laryngology - Head and Neck Surgery.* 273 (12) (2016) 4305–4314, <https://doi.org/10.1007/s00405-016-4125-z>.
- [17] R.F. Schmidt, O.J. Choudhry, J. Raviv, S. Baredes, R.R. Casiano, J.A. Eloy, et al., Surgical nuances for the endoscopic endonasal transpterygoid approach to lateral sphenoid sinus encephaloceles, *Neurosurg. Focus* 32 (6) (2012) E5, <https://doi.org/10.3171/2012.3.Focus1267>.
- [18] A. Spina, N. Boari, F. Calvanese, P. De Domenico, M. Cannizzaro, M. Trimarchi, et al., Transcranial extradural subtemporal repair for sphenoid sinus lateral recess meningoencephalocele: technical note, *Neurosurg. Rev.* (2021), <https://doi.org/10.1007/s10143-021-01581-7>.
- [19] G.M. Oakley, R.R. Orlandi, B.A. Woodworth, P.S. Batra, J.A. Alt, Management of cerebrospinal fluid rhinorrhea: an evidence-based review with recommendations, *Int. Forum Allergy Rhinol.* 6 (1) (2016) 17–24, <https://doi.org/10.1002/alr.21627>.
- [20] G. Fyrmpas, I. Konstantinidis, P. Selviaridis, J. Constantinidis, Management of spontaneous cerebrospinal fluid leaks of the sphenoid sinus: our experience, *J. Laryngol. Otol.* 128 (9) (2014) 797–802, <https://doi.org/10.1017/s0022215114001698>.