

# Levels of beta-trace protein in optic disc pit with macular detachment

Karim Makdoui,<sup>1</sup> Torbjörn K. Nilsson<sup>2,3</sup> and Sven Crafoord<sup>1</sup>

<sup>1</sup>Faculty of Medicine and Health, Department of Ophthalmology, Örebro University, Örebro, Sweden

<sup>2</sup>Department of Medical Biosciences/Clinical Chemistry, Umeå University, Umeå, Sweden

<sup>3</sup>Faculty of Medicine and Health, Department of Biomedicine, Örebro University, Örebro, Sweden

## ABSTRACT.

**Background:** To report beta-trace protein ( $\beta$ TTP) levels in the subretinal fluid (SRF) of four patients with a macular detachment associated with optic disc pit (ODP).

**Methods:** Four patients with a serous retinal detachment involving the macula was operated by pars plana vitrectomy (PPV) with  $C_2F_6$  gas tamponade and peeling of internal limiting membrane (ILM). Patients with a follow-up period exceeding one year postoperatively were included in the study. The SRF was drained using a fine cannula without laser photocoagulation, and the samples were analysed using particle-enhancing nephelometry. The levels of  $\beta$ TTP were compared to 20 routine cerebrospinal fluid (CSF) samples.

**Results:** In four of the five samples from SRF had relatively low  $\beta$ TTP levels, with a mean concentration of 6.6 mg/l (range 2.0 to 23.1 mg/l) compared to 16.0 mg/l (range 6.3–26.8 mg/l) in CSF. The only SRF sample within the range corresponding to normal CSF was the first sample from patient 4, and the analysis of the renewed aspirate during the second operation was 2.8 mg/l. Postoperatively, the regression of SRF was slow, but regression of SRF in the foveal region took place in all cases; however, visual acuity (VA) was improved in only half of the patients.

**Conclusion:** The results from the analysed SRF regarding  $\beta$ TTP concentration in these patients indicate that the SRF in ODP is not identical to CSF, as the concentrations of  $\beta$ TTP differ.

**Key words:** beta trace – beta-trace protein – optic disc pit –  $\beta$ -trace protein

Acta Ophthalmol. 2017; 95: 815–819

© 2017 The Authors. Acta Ophthalmologica published by John Wiley & Sons Ltd on behalf of Acta Ophthalmologica Scandinavica Foundation.

This is an open access article under the terms of the Creative Commons Attribution-NonCommercial License, which permits use, distribution and reproduction in any medium, provided the original work is properly cited and is not used for commercial purposes.

doi: 10.1111/aos.13527

## Introduction

Optic disc pit (ODP) is a developmental defect in the optic nerve head, consisting of a round or oval depression in the neuroretinal rim, most frequently located temporally (Brown et al. 1980; Georgalas et al. 2011). Clinically, the condition can be

asymptomatic, but a decrease in VA can arise from cystoid macular oedema, retinoschisis (RS) or a serous detachment of the retina (Gass 1969; Lincoff et al. 1988; Trichonas & Kaiser 2014).

Several publications have described successful management through different, predominately surgical approaches such as laser photocoagulation,

macular buckling, PPV, with or without laser photocoagulation, ILM peeling and vitreous gas tamponade (Annesley et al. 1987; Theodosiadis & Theodosiadis 2000; Hirakata et al. 2005, 2012; Rizzo et al. 2012). The exact pathophysiology, however, remains unknown. The retinal structure often has an appearance similar to the one seen in RS (Theodosiadis & Theodosiadis 2000; Lalwani et al. 2007; Imamura et al. 2010; Hirakata et al. 2012) and can lead to permanent loss of vision and the development of a macular hole, especially if the duration of SRF has been long (Sobol et al. 1990; Bonnet 1991).

The exact pathophysiological mechanisms for the development of subretinal and intraretinal fluid are unknown. Most likely, however, these findings originate either from a direct communication between the ODP and the subarachnoid space or that the unnaturally strong attachment between the posterior hyaloid at the site of the ODP allows fluid to leakage into or through the retina (Johnson & Johnson 2004; Jain & Johnson 2014).

Beta-trace protein ( $\beta$ TTP) is a molecule used for confirming the presence of CSF leakage into the nasal cavity due to its relatively high concentration in CSF. It is also found in, for example, perilymph, serum, urine, amniotic fluid and central nervous system (CNS) (Melegos et al. 1996; Tumani et al. 1998). Also,  $\beta$ TTP levels are high in retina, interphotoreceptor matrix and retinal pigment epithelial (RPE) cells, possibly being both an enzymatically active molecule as well as carrying out

intercellular transport between RPE and photoreceptor cells (Beuckmann et al. 1996). We wanted to investigate if the subretinal optic pit fluid originates from CSF or not, using  $\beta$ TP as a biomarker of CSF. We here report our findings in a consecutive series of four patients.

## Materials and Methods

The study adhered to the tenets of the declaration of Helsinki and involved treatment and follow-up of four patients with diagnosed ODP, including a macular detachment. Approval for the study was given by the regional review board, and a written informed consent was collected from all included subjects. The patients were referred to the Department of Ophthalmology, Örebro University Hospital. Preoperatively, the clinical diagnosis was confirmed by slit-lamp examination by a vitreoretinal surgeon and macular detachment was further evaluated by optical coherence tomography (OCT) examination. All patients were otherwise healthy with no prior history of ocular disease. Information about age, gender and OCT findings is shown in Table 1. Only patients with a follow-up time exceeding 1 year after the initial operation were included in the study.

The patients were all operated with PPV, peeling of the ILM and vitreous gas tamponade with  $C_2F_6$  between April 2012 and June 2014. During the procedure, after the ILM peeling, SRF was aspirated by placing a fine cannula

(gauge size specified in Table 1) through the retina superior to the macular region, within temporal the vascular arcades. No photocoagulation treatment was done after drainage. Subsequently, the small fluid volume was transferred into the bottom of an Eppendorf tube that had been pre-weighed on a high-resolution balance (Sartorius Cubis MSA, Sartorius AG, Göttingen, FRG). Thereafter, the tube was rapidly taken to the laboratory, weighed again, and the change in weight was considered to be a measure of the volume of the aspirated fluid, under the assumption that 1 mg of SRF  $\approx$  1  $\mu$ l. From the initial weighing, the tubes were kept in sealed plastic bags and care was taken not to touch them, except by sterile instruments. Values around 3  $\mu$ l were typically obtained. Samples were then diluted with reagent buffer sufficiently to fill the minimum requirement of the analytical instrument (50  $\mu$ l). Assay of  $\beta$ -trace protein was performed by particle-enhancing nephelometry using the reagent kit "N Latex  $\beta$  TP" (Siemens, Marburg, FRG) on a BN Prospec® nephelometer (Dade Behring, Marburg, FRG). The measuring range was 0.25–16 mg/l and the coefficient of variation 8%. To get a picture of the typical CSF levels, we also analysed  $\beta$ TP concentrations in 20 consecutive de-identified CSF samples sent to our routine laboratory for CSF protein isoelectric focusing analysis. Resolution of SRF after vitrectomy was slow in all patients.

**Table 1.** Specific information on patient characteristics, OCT findings and gauge size of aspiration needle used for sampling of SRF.

Patient number	Age at surgery	Sex	Eye	Aspiration needle size	OCT findings
1	50	Male	Left	42 gauge	SRF + RS
2	13	Female	Left	39 gauge	SRF
3	21	Female	Right	39 gauge	SRF + RS + MH
4	60	Female	Left	30 gauge	SRF

SRF= Subretinal fluid, RS= Retinoschisis, MH= Full-thickness macular hole, OCT = optical coherence tomography.

**Table 2.** Data on follow-up time (in months), visual acuity (VA) before surgery as well as at the latest control visit and beta-trace protein ( $\beta$ TP) concentration in SRF.

Patient number	Follow-up time	Preop VA	Postop VA	$\beta$ TP in SRF (mg/l)
1	43	0.2	0.62	2.0
2	32	0.77	0.77	2.4
3	20	0.2	0.5	2.5
4	28	0.5	0.31	23.1/2.8

## Results

Complete regression of fluid in the macular region occurred in all patients and the end of the follow-up period. However, one patient had to undergo the surgery twice. Visual acuity (VA) before surgery and at the end of follow-up period is specified in Table 2. It improved in two and worsened in one of the four operated eyes.

### Patient 1

Preoperatively, OCT showed a pronounced RS with a retinal detachment involving the macula (Fig. 1). After the surgery, the SRF level, RS and VA were improved; however, resolution of the macular detachment was delayed with a gradual disappearance of SRF (Fig. 2). At the latest visit, the retina was reattached without SRF or RS (Fig. 3).

### Patient 2

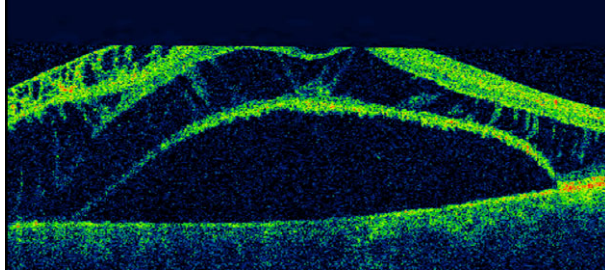
In this patient, the SRF regressed adequately after the surgery (Figs 4 and 5); however, VA did not change during the study period.

### Patient 3

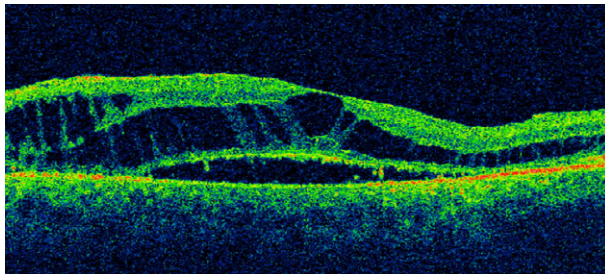
Optical coherence tomography (OCT) examination before surgery confirmed a full-thickness macular hole as well as a RS in the affected eye (Fig. 6). During the operation, a retinal tear developed, when posterior vitreous detachment was induced. Treatment with laser photocoagulation was conducted preoperatively and, as in all other cases, a vitreous gas tamponade was given. No rhegmatogenous retinal detachment developed. The macular hole closed and the intraretinal oedema disappeared, but as in patient 1, complete regression of the SRF involving the macular region disappeared gradually during the follow-up period (Figs 7-8).

### Patient 4

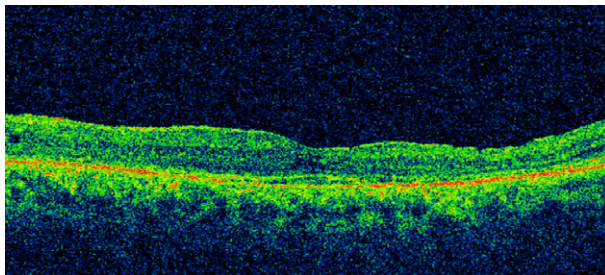
After surgery, due to a macular detachment without RS (Fig. 9), there was a tendency towards a decrease in SRF level, but after 9 months the retinal detachment involving the macula was higher than before surgery (Fig. 10), why a new PPV procedure was scheduled. Again, drainage using



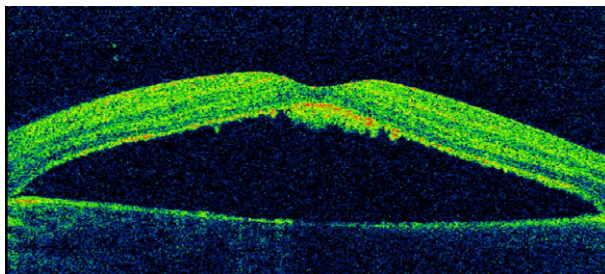
**Fig. 1.** Spectral domain optical coherence tomography picture of patient 1 the day before surgery. The intraretinal fluid is more accentuated towards the optic disc, and the macular elevation due to subretinal fluid is high.



**Fig. 2.** Two months postoperatively, the retinal structure is still thickened, but the fluid under the macula has decreased.



**Fig. 3.** At the end of the follow-up period, 43 months after vitrectomy, the retinal structure has normalized and no subretinal fluid remains.



**Fig. 4.** Preoperative optical coherence tomography image the day prior to vitrectomy of patient 2 shows a serous detachment without retinoschisis.

a 30-gauge cannula and sampling of SRF for  $\beta$ TTP was done and 16 per cent  $C_2F_6$  vitreous gas tamponade was given. The macula was reattached and regression of SRF occurred. Twelve months after the second procedure, phacoemulsification was conducted and at latest examination, 17 months after the second vitrectomy, only

traces of SRF remained outside the macular region (Fig. 11).

**Beta-trace protein concentrations in SRF and CSF**

The analysed subretinal aspirate had a mean  $\beta$ TTP concentration of 6.6 mg/l (range 2.0–23.1 mg/l). These values for

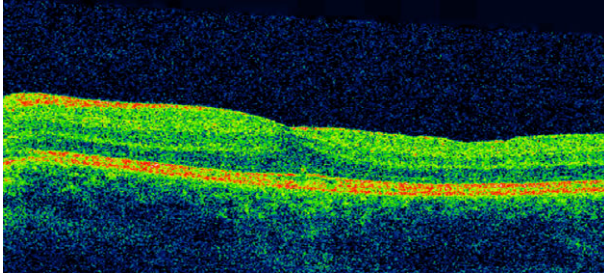
each patient are specified in Table 2. The only test within the range corresponding to normal CSF was the first sample from patient 4, who underwent two operations due to deterioration in VA and SRF. However, the analysis done from the aspirate during the second operation was 2.8 mg/l. In a series of consecutive CSF samples sent to our routine laboratory, the mean  $\beta$ TTP concentration was 16.0 mg/l (range 6.3–26.8 mg/l).

**Discussion**

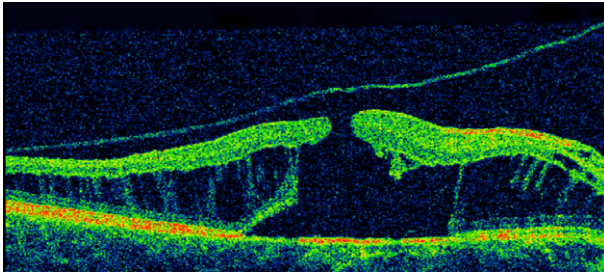
In this report, we describe a technique to analyse the levels of  $\beta$ TTP found in the subretinal space during PPV to try to validate if the levels are equal to those found in CSF. The results in these four patients are not entirely conclusive. The  $\beta$ TTP concentrations from three of them were considerably lower than those normally found in CSF, but the first sample from the fourth patient was within the interval typically found in CSF. This is to our knowledge the first published work where the SRF from humans has been extracted and analysed regarding presence of CSF proteins in ODP.

The pathogenesis in ODP is still not fully understood, but several articles have emphasized posterior vitreous traction on the pit and an abnormally strong vitreoretinal interface as principal features for development of the RS-like retinal structure as well as the development of the macular detachment (Brown et al. 1980; Johnson & Johnson 2004; Theodossiadi et al. 2007; Hirakata et al. 2012; Ooto et al. 2014). This would allow leakage of fluid into the retina, creating the separation of retinal layers, and furthermore leading to the detachment of the retina. Surgical management by induction of a posterior vitreous detachment, with or without peeling of ILM, supports the hypothesis that traction is an imperative pathophysiological component (Hirakata et al. 2005, 2012; Rizzo et al. 2012; Avci et al. 2013), as does the reported spontaneous healing of macular detachment after posterior vitreous detachment (Bonnet 1991).

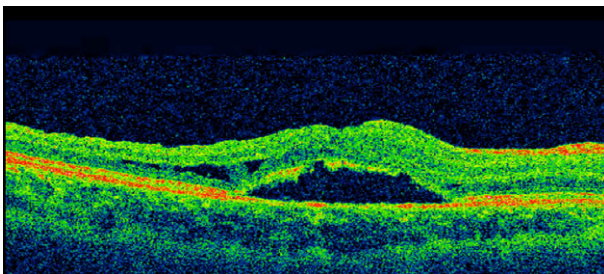
Low concentrations of  $\beta$ TTP compared to normal CSF levels (Tumani et al. 1998; Reiber et al. 2003; Mase et al. 2003), as found in four of the five samples from the patients evaluated here, support this hypothesis.



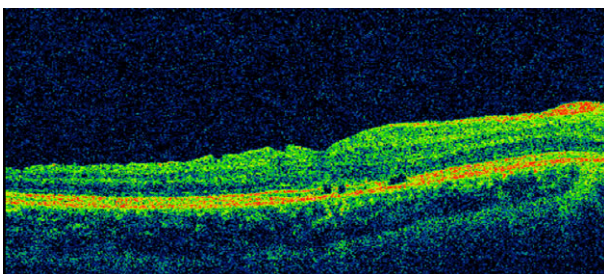
**Fig. 5.** Optical coherence tomography of the macular region at the latest examination, 32 months postoperatively, without subretinal fluid.



**Fig. 6.** Preoperative optical coherence tomography picture of patient 3 on the day of pars plana vitrectomy shows a marked retinoschisis, predominately in the outer plexiform layer, and a full-thickness macular hole.



**Fig. 7.** Nine months postoperatively, a resolution of the most of the intraretinal fluid has occurred with healing of the macular hole, but a small subretinal fluid level is still seen.



**Fig. 8.** At the latest visit, 20 months after vitrectomy, minor defects are observed at the photoreceptor layer, in the foveal region, but there is no level of subretinal fluid.

However, fluid from the vitreous space filtered through the retina as well as the existence of a direct passage into the retinal tissue through the pit, causing a RS, would have reduced the levels of the protein in the subretinal space. It also cannot be ruled out that due to the low elevation and small volume of the submacular detachment inhibited proper assessment of the protein levels

in the fluid, either by dilution from vitreous fluid into the aspirate or incomplete drainage by the small-gauge cannula. The presence of RS could also affect the accuracy of sampling of the SRF, making the exact origin of the fluid slightly uncertain in two of the four eyes with ODP. Furthermore, a potential source of bias when recording low protein concentrations is the

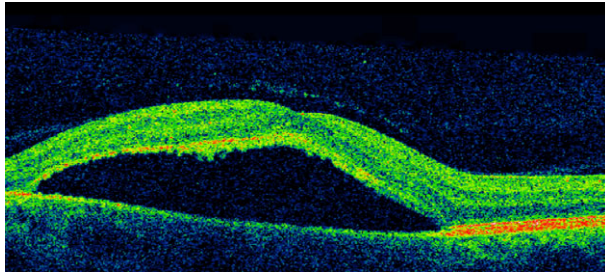
possibility of proteolytic degradation with subsequent loss of antigenic determinants. These factors could then contribute to a spuriously low  $\beta$ TTP in the aspirates, but we judge this to be at best a distant possibility.

The final case tested had an order of magnitude higher  $\beta$ TTP, typical of CSF concentrations, which could indicate that in fact there was a direct conduit between the SRF to the subarachnoid space. However, given the presence of  $\beta$ TTP in retinal and RPE cells, the higher concentration of the molecule may perhaps have originated from these cells and not CSF, leading to a false-positive estimation. Also, the repeated analysis during the second operation in this patient was considerably lower than the first sample, indicating that the renewed SRF was similar to the levels found in the other three patient samples. It is a possibility that the larger cannula size in the final patient may have contributed to retinal damage resulting in an inaccurately high value of the protein in this case although the drainage of the SRF was successful.

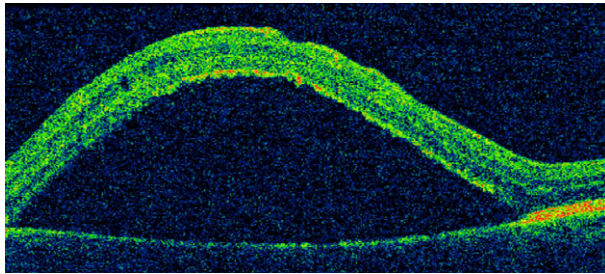
Hence, the arguments for a false low  $\beta$ TTP in the first three patients appear weaker to us than the arguments for an erroneously high  $\beta$ TTP in patient 4. If so, this would favour the concept of optic pit fluid as a kind of low-protein ultrafiltrate, in analogy with, for instance, renal cyst fluid. Although histopathological studies on ODP have found defects supporting passage between the optic disc anomaly and the subretinal space, a direct communication with the subretinal and subarachnoid spaces has to our knowledge not been confirmed (Christoforidis et al. 2012).

It is, however, possible that an uninterrupted pathway between these compartments exists in some of the patients with ODP, or alternatively that tractional forces from the posterior hyaloid as well as a communication between these spaces both contribute to the development of optic pit maculopathy. These explanations would nonetheless explain the variability between the two samples received from the final patient.

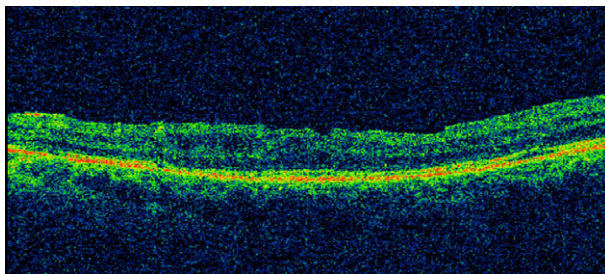
We conclude that, although our findings cannot differ definitively between the two alternative or synergistic pathophysiological explanations described previously, results so far



**Fig. 9.** In patient 4 the day before vitrectomy, optical coherence tomography shows a detached macula without retinoschisis.



**Fig. 10.** After an initial improvement, optical coherence tomography image, 9 months postoperatively, depicts high detachment involving the fovea.



**Fig. 11.** The central macula is reattached, 28 months after the initial pars plana vitrectomy.

indicate that the SRF in ODP is not identical to CSF, as the concentrations of  $\beta$ TTP differ. Additional cases may resolve some of the open issues, and we advocate the assay of  $\beta$ TTP or other biomarkers of CSF to be included in future studies of this condition. As little is known regarding the concentrations of  $\beta$ TTP in the normal human vitreous and retina, in addition to other conditions where SRF is found, determination of  $\beta$ TTP could be of value in research yet to come.

### Ethical Approval

All procedures performed in studies involving human participants were in accordance with the ethical standards of the institutional and/or national research committee and with the 1964 Helsinki declaration and its later amendments or comparable ethical standards.

### Informed Consent

Informed consent was obtained from all individual participants included in the study.

### References

Annesley W, Brown G, Bolling J, Goldberg R & Fischer D (1987): Treatment of retinal detachment with congenital optic pit by krypton laser photocoagulation. *Graefes Arch Clin Exp Ophthalmol* **225**: 311–314.

Avci R, Yilmaz S, Inan UU, Kaderli B, Kurt M, Yalcinbayir O, Yildiz M & Yucel A (2013): Long-term outcomes of pars plana vitrectomy without internal limiting membrane peeling for optic disc pit maculopathy. *Eye (Lond)* **27**: 1359–1367.

Beuckmann CT, Gordon WC, Kanaoka Y et al. (1996): Lipocalin-type prostaglandin D synthase (beta-trace) is located in pigment epithelial cells of rat retina and accumulates within interphotoreceptor matrix. *J Neurosci* **16**: 6119–6124.

Bonnet M (1991): Serous macular detachment associated with optic nerve pits. *Graefes Arch Clin Exp Ophthalmol* **229**: 526–532.

Brown GC, Shields JA & Goldberg RE (1980): Congenital pits of the optic nerve head. II. Clinical studies in humans. *Ophthalmology* **87**: 51–65.

Christoforidis JB, Terrell W & Davidorf FH (2012): Histopathology of optic nerve pit-associated maculopathy. *Clin Ophthalmol* **6**: 1169–1174.

Gass JD (1969): Serous detachment of the macula. Secondary to congenital pit of the optic nervehead. *Am J Ophthalmol* **67**: 821–841.

Georgalas I, Ladas I, Georgopoulos G & Petrou P (2011): Optic disc pit: a review. *Graefes Arch Clin Exp Ophthalmol* **249**: 1113–1122.

Hirakata A, Okada AA & Hida T (2005): Long-term results of vitrectomy without laser treatment for macular detachment associated with an optic disc pit. *Ophthalmology* **112**: 1430–1435.

Hirakata A, Inoue M, Hiraoka T, & McCuen BW 2nd. (2012): Vitrectomy without laser treatment or gas tamponade for macular detachment associated with an optic disc pit. *Ophthalmology* **119**: 810–818.

Imamura Y, Zweifel SA, Fujiwara T, Freund KB & Spaide RF (2010): High-resolution optical coherence tomography findings in optic pit maculopathy. *Retina* **30**: 1104–1112.

Jain N & Johnson MW (2014): Pathogenesis and treatment of maculopathy associated with cavitory optic disc anomalies. *Am J Ophthalmol* **158**: 423–435.

Johnson TM & Johnson MW (2004): Pathogenic implications of subretinal gas migration through pits and atypical colobomas of the optic nerve. *Arch Ophthalmol* **122**: 1793–1800.

Lalwani GA, Punjabi OS, Flynn HW Jr, Knighton RW & Puliafito CA (2007): Documentation of optic nerve pit with macular schisis-like cavity by spectral domain OCT. *Ophthalmic Surg Lasers Imaging* **38**: 262–264.

Lincoff H, Lopez R, Kreissig I, Yannuzzi L, Cox M & Burton T (1988): Retinoschisis associated with optic nerve pits. *Arch Ophthalmol* **106**: 61–67.

Mase M, Yamada K, Shimazu N et al. (2003): Lipocalin-type prostaglandin D synthase (beta-trace) in cerebrospinal fluid: a useful marker for the diagnosis of normal pressure hydrocephalus. *Neurosci Res* **47**: 455–459.

Melegos DN, Diamandis EP, Oda H, Urade Y & Hayaishi O (1996): Immunofluorometric assay of prostaglandin D synthase in human tissue extracts and fluids. *Clin Chem* **42**: 1984–1991.

Ooto S, Mitra RA, Ridley ME & Spaide RF (2014): Vitrectomy with inner retinal fenestration for optic disc pit maculopathy. *Ophthalmology* **121**: 1727–1733.

Reiber H, Walther K & Althaus H (2003): Beta-trace protein as sensitive marker for CSF rhinorrhea and CSF otorrhea. *Acta Neurol Scand* **108**: 359–362.

Rizzo S, Belting C, Genovesi-Ebert F, Di BE, Cresti F, Cinelli L & Allegrini L (2012): Optic disc pit maculopathy: the value of small-gauge vitrectomy, peeling, laser treatment, and gas tamponade. *Eur J Ophthalmol* **22**: 620–625.

Sobol WM, Blodi CF, Folk JC & Weingeist TA (1990): Long-term visual outcome in patients with optic nerve pit and serous retinal detachment of the macula. *Ophthalmology* **97**: 1539–1542.

Theodossiadis GP & Theodossiadis PG (2000): The macular buckling technique in the treatment of optic disk pit maculopathy. *Semin Ophthalmol* **15**: 108–115.

Theodossiadis PG, Grigoropoulos VG, Emfietzoglou J & Theodossiadis GP (2007): Vitreous findings in optic disc pit maculopathy based on optical coherence tomography. *Graefes Arch Clin Exp Ophthalmol* **245**: 1311–1318.

Trichonas G & Kaiser PK (2014): Optical coherence tomography imaging of macular oedema. *Br J Ophthalmol* **98** (Suppl 2): ii24–ii29.

Tumani H, Nau R & Felgenhauer K (1998): Beta-trace protein in cerebrospinal fluid: a blood-CSF barrier-related evaluation in neurological diseases. *Ann Neurol* **44**: 882–889.

Received on February 10th, 2017.  
Accepted on June 7th, 2017.

*Correspondence:*  
Karim Makdoui, MD, PhD  
Department of Ophthalmology  
Örebro University Hospital  
SE-701 85 Örebro  
Sweden  
Tel: +46 602 10 00  
Fax: +46 19 602 10 52  
Email: karim.makdoui@regionorebrolan.se