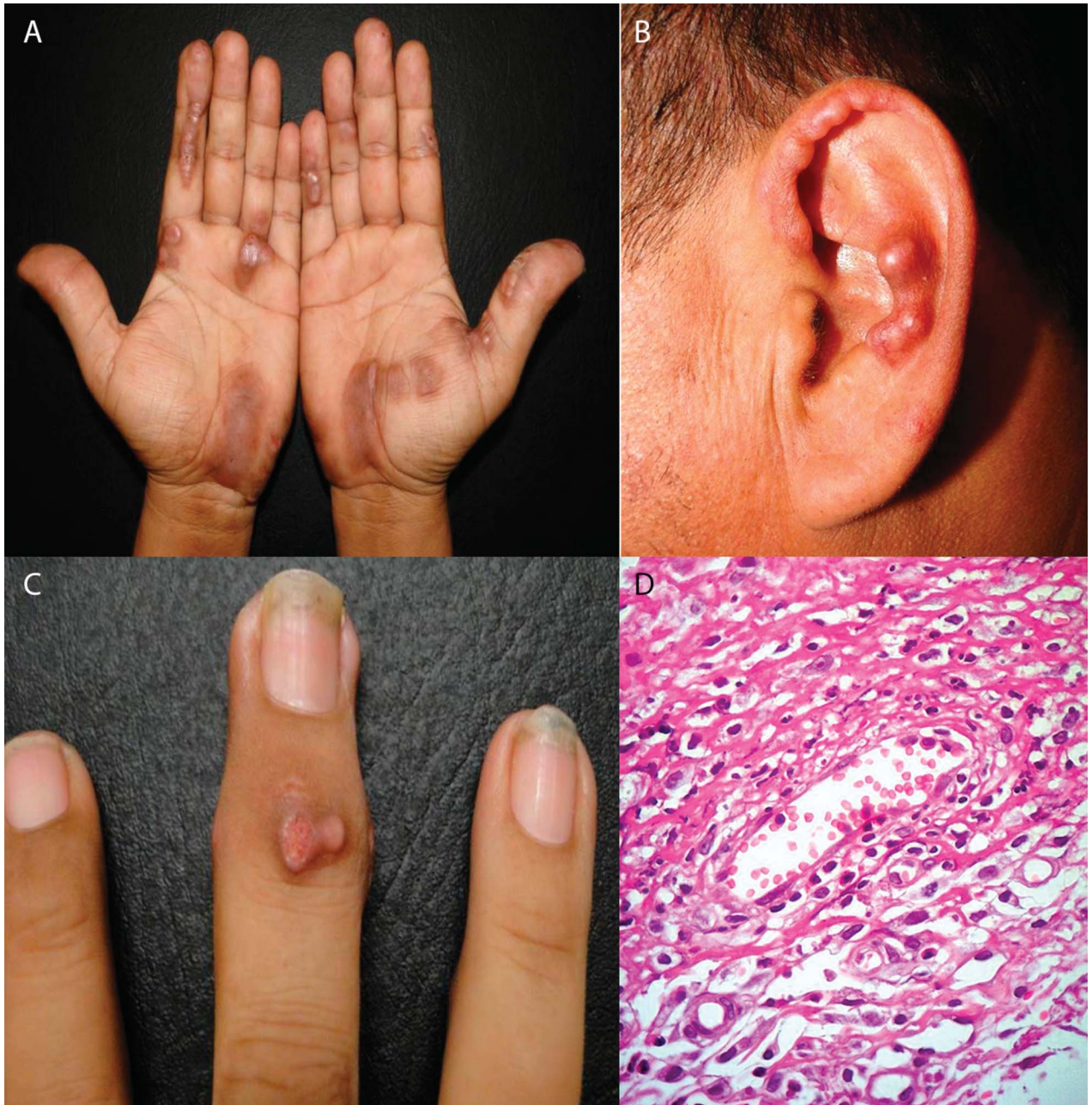


OPEN

## Erythema Elevatum Diutinum: An Atypical Presentation

**E**rythema elevatum diutinum (EED) is classified within the small vessel vasculitis. It is a rare, chronic and progressive disease affecting mostly extensor surfaces and skin overlying

the joints.<sup>1</sup> Clinically, it presents as multiple erythematous and violaceous papules with a symmetrical and bilateral distribution. Associations with underlying diseases are common, including autoimmune disease, malignancies and infections; although drug-induced cases have been reported. Treatment varies greatly among the literature, with dapsone being the most effective and most frequently used drug.<sup>2</sup> EED is an important differential diagnosis of rheumatic disease, especially when treating patients with chronic arthralgias and nonspecific cutaneous lesions, in whom associated diseases must be ruled out.<sup>3</sup>



**FIGURE 1.** (A) Atypical brown rope-like plaques and papules and postinflammatory macules on the patient's palms. (B) Erythematous and brownish papules over the helix and antihelix of the patient's left ear. (C) Typical erythematous papules over the distal interphalangeal joint of the patient's right middle finger. (D) Skin biopsy from a palmar lesion (40× stained with hematoxylin and eosin). Leukocytoclastic vasculitis with neutrophils, leukocytoclastic debris, lymphocytes and scant eosinophils surrounding the blood vessels.

We describe a 45-year-old man with chronic joint pain and atypical hyperpigmented macules in palms, as well as euchromatic papules over the ears.

The patient presented with a 2-year history of multiple papular lesions on the palms and dorsal aspect of hands, knees, elbows and ears. Some lesions progressed in number and size over the years, whereas others resolved spontaneously leaving residual hyperpigmentation. One year later, he developed arthralgias on elbows, knees, ankles and proximal interphalangeal joints. He was treated with nonsteroidal anti-inflammatory drugs without improvement.

On physical examination, he presented with firm erythematous, red-brown and violaceous papules and nodules of 0.5 to 2.0 cm in diameter, symmetrically distributed over the extensor surfaces of elbows, knees and proximal interphalangeal joints, as well as over the helixes. Linear rope-like papules and hyperpigmented macules were also noted on his palms (Fig. 1A–C). The patient referred arthralgias of affected and nonaffected joints, but no signs of arthritis were documented. An excisional biopsy from a lesion of his right palm was performed. Histopathology revealed the presence of leukocytoclastic vasculitis with neutrophils, leukocytoclastic debris, lymphocytes and scant eosinophils surrounding the blood vessels. The dermis showed a proliferation of spindle cells combined with a granulomatous response (Fig. 1D). Laboratory findings were negative or within normal limits.

EED is a rare form of chronic cutaneous vasculitis. The first descriptions of the disease were made by Hutchinson in 1878, and the disease was later named by Radcliff-Crocker and Williams in 1892.<sup>2</sup> It usually presents with persistent bilateral brown to erythematous or violaceous papules, nodules and plaques typically located over the extensor surfaces of the extremities,<sup>3</sup> particularly over joints of the hands, elbows and knees and occasionally on the face and ears. Lesions are mostly asymptomatic, although some patients can experience pruritus, tenderness and a burning sensation after the onset of new lesions. At the time when lesions appear, they are soft because of dermal edema and tissue destruction, but as they progress over time, they become fibrotic and hard on palpation. Differential diagnoses include granuloma annulare, sarcoidosis, Sweet's syndrome, pseudolymphoma, xanthomas and dermatofibroma.<sup>4</sup> EED has a slight male predominance and is seen in patients between the fourth and sixth decades. The cause of EED is still unknown, and it is believed to be a small vessel vasculitis mediated by immune complexes and has been associated with multiple underlying diseases: autoimmune (rheumatoid arthritis, diabetes mellitus, Crohn's disease and celiac disease), infections (HIV, streptococcus), malignancies (B-cell lymphoma, multiple myeloma, breast cancer), and there are case reports of EED after the use of antituberculosis drugs, cisplatin and erythropoietin. Histopathological changes vary according to the evolution of the lesions and time when the skin biopsy is taken. Early lesions may mimic features of neutrophilic dermatoses with polymorphonuclear cells, macrophages and histiocytes, but the presence of leukocytoclastic vasculitis helps to distinguish EED. In later stages of the disease, a dermal spindle cell proliferation is observed and lesions can resemble a dermatofibroma, and blood vessels show hypertrophic endothelial cells.<sup>2</sup> EED shows a chronic, progressive and relapsing course, which further complicates the treatment, although spontaneous resolution has been reported after 5 to 10 years. Treatment modalities include the use of anti-inflammatory drugs such as glucocorticoids, tetracyclines, nicotinamide, chloroquine, dapsone and

colchicine with variable results. Dapsone is a sulfonamide antibiotic that impairs neutrophil function; it is the most effective agent and remains the mainstay of treatment,<sup>5</sup> although recurrences are common on discontinuation.<sup>6</sup> Newer therapies include the use of topical 5% dapsone preparations<sup>7</sup> and plasmapheresis. Because EED can be associated with a long list of diseases, patients should be evaluated for related disorders to make prompt and proper referrals.

The patient presented in this case is of clinical interest because of the atypical distribution of the lesions, which usually affect the extensor surfaces. In this case, the main localization was the palmar region, and instead of papules, the lesions were more of plaques with a linear rope-like morphology. Other skin diseases that may present with palmar rope-like lesions include sarcoidosis, granuloma annulare, necrobiosis lipoidica, leprosy and multicentric reticulohistiocytosis. Our patient was initially evaluated for an underlying autoimmune disease, but clinical and radiological as well as laboratory examinations were within the normal range. Malignancies were also excluded. He was started on oral dapsone 50 mg/d but eventually denied any medical treatment and was lost to follow-up.

**\*Martha Elena García-Meléndez, MD**  
**Sylvia A. Martínez-Cabriales, MD**  
**Kristian Eichelmann, MD**  
**Minerva Gómez-Flores, MD**  
**Jorge Ocampo-Candiani, MD**

Department of Dermatology  
 University Hospital "José Eleuterio González,"  
 Universidad Autónoma de Nuevo León (UANL)  
 Monterrey, Mexico

\*E-mail: megmelendez@gmail.com

The authors have no financial or other conflicts of interest to disclose.

This is an open-access article distributed under the terms of the Creative Commons Attribution-NonCommercial-NoDerivatives 3.0 License, where it is permissible to download and share the work provided it is properly cited. The work cannot be changed in any way or used commercially.

## REFERENCES

1. **Takahashi H, Fukami Y, Honma M, et al.** Successful combination therapy with dapsone and cyclosporine for erythema elevatum diutinum with unusual appearance. *J Dermatol* 2011;39:486–7.
2. **Sharma V, Mahajan VK, Mehta KS, et al.** Erythema elevatum diutinum. *Indian J Dermatol Venereol Leprol* 2013;79:238–9.
3. **Rosa DJ, Machado RF, Fraga Rde O, et al.** Eritema elevatum diutinum as a differential diagnosis of rheumatic disease: case report [in English, Portuguese]. *Rev Bras Reumatol* 2012;52:291–4.
4. **High WA, Hoang MP, Stevens K, et al.** Late-stage nodular erythema elevatum diutinum. *J Am Acad Dermatol* 2003;49:764–7.
5. **Grabbe J, Haas N, Möller A, et al.** Erythema elevatum diutinum—evidence for disease-dependent leucocyte alterations and response to dapsone. *Br J Dermatol* 2000;143:415–20.
6. **Gibson LE, El-Azhary RA.** Erythema elevatum diutinum. *Clin Dermatol* 2000;18:295–9.
7. **Frieling GW, Williams NL, Scott JM, et al.** Novel use of topical dapsone 5% Gel for erythema elevatum diutinum: safer and effective. *J Drugs Dermatol* 2013;12:481–4.