

## Adenoid cystic carcinoma: A review of recent advances, molecular targets, and clinical trials

Patrick M. Dillon, MD,<sup>1\*</sup> Samhita Chakraborty, MD,<sup>2</sup> Christopher A. Moskaluk, MD, PhD,<sup>3</sup> Prashant J. Joshi, MD,<sup>4</sup> Christopher Y. Thomas, MD<sup>5</sup>

<sup>1</sup>Division of Hematology/Oncology, University of Virginia, Charlottesville, Virginia, <sup>2</sup>Division of Hematology/Oncology, New Jersey Medical School, Newark, New Jersey, <sup>3</sup>Department of Pathology, University of Virginia, Charlottesville, Virginia, <sup>4</sup>Department of Internal Medicine, University of Virginia, Charlottesville, Virginia, <sup>5</sup>Division of Hematology/Oncology, Wake Forest University, Winston-Salem, North Carolina.

Accepted 3 December 2014

Published online 16 June 2015 in Wiley Online Library (wileyonlinelibrary.com). DOI 10.1002/hed.23925

**ABSTRACT:** *Background.* Adenoid cystic carcinoma (ACC) is a rare tumor of secretory glands. In this study, recent advances in molecular characterization and in therapeutics are reviewed.

*Methods.* A search of articles in PubMed and of abstracts from national meetings was performed regarding ACC.

*Results.* Recent genetic analyses found that recurrent chromosome 6:9 translocations in ACC generate a MYB:NFIB gene fusion resulting in overexpression of the MYB oncoprotein. Several other frequent mutations are recently published that may be relevant for drug development. Several trials of targeted drugs are reviewed. Some agents delay tumor progression, but tumor responses remain rare.

*Conclusion.* ACCs have a characteristic chromosomal translocation, but also frequently pick up additional mutations. Clinical research is limited by the rarity and slow growth of ACC. Several ongoing trials are testing agents that inhibit fibroblast growth factor receptor signaling or other signaling pathways. Novel treatments based on the recently sequenced tumor genome are under development. © 2015 The Authors *Head & Neck* Published by Wiley Periodicals, Inc. **38:** 620–627, 2016

**KEY WORDS:** adenoid cystic carcinoma, salivary gland, tyrosine kinase inhibitor, MYB gene, NFIB gene, nuclear factor I/B

### INTRODUCTION

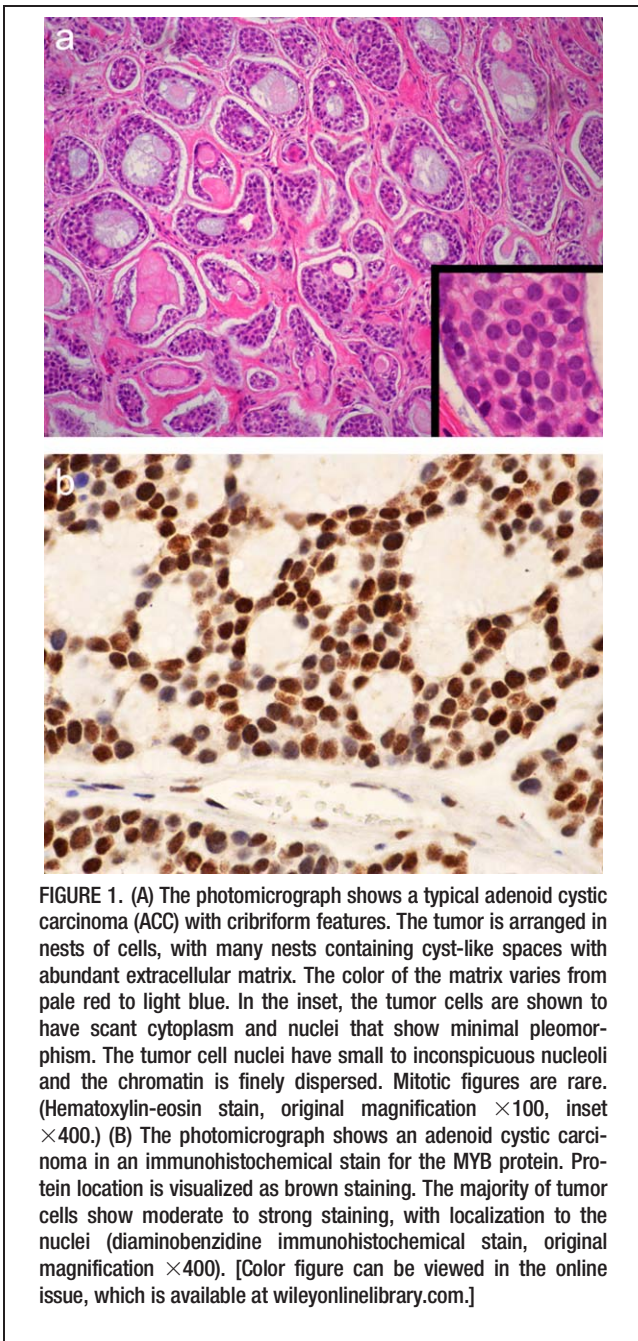
Adenoid cystic carcinoma (ACC) is an uncommon malignancy of secretory glands, which is characterized by slow growth kinetics and perineural invasion, and is among the rarer tumors for which little research has been performed and for which there are few treatment options for patients with advanced disease. Owing to its slow growth, clinical trials looking for classic response by solid tumor measurement criteria have been mostly negative. New treatments are desperately needed. Several recent advances in the understanding of the pathogenesis and molecular phenotype of this disease have been made. Given the new understanding of ACC, a thorough review of the therapeutic considerations and current management of ACC is needed. This clinical, molecular, and therapeutic review includes a search of all articles in PubMed containing ACC and a review of abstracts for the last 5 years.

The salivary glands are the most common site of origin for ACC. As an uncommon tumor type, ACC

accounts for only 1% of all malignant tumors of the head and neck region and 10% of all salivary gland neoplasms.<sup>1–3</sup> In the latter case, ACC occurs more frequently in minor as compared with major salivary glands. Other sites of origin in the head and neck are the tongue, paranasal sinuses, palate, nasopharynx, lacrimal glands, and external auditory canal. ACC may also arise in secretory glands located in other tissues, such as in the tracheobronchial tree, esophagus, breast, lungs, prostate, uterine cervix, Bartholin's glands, and vulva.<sup>4,5</sup> The disease is seen most commonly in the fifth and sixth decades of life but may appear at almost any age.<sup>1,6</sup> In a recent population study, ACC occurred more commonly in women than men (60:40 ratio).<sup>7</sup> Owing to the rarity of these tumors, there is little data on whether specific ethnic, geographic, exposure, or other factors predispose to the development of the disease.

ACCs typically grow more slowly compared with other carcinomas, and tend to have a low incidence of spread to local and regional lymph nodes. Nonetheless, after resection of the primary tumor, local and distant recurrences are quite common. This high recurrence rate likely reflects the known tendency for perineural invasion with occult extension beyond surgical margins and a tendency for hematogenous dissemination at early stages of tumor development.<sup>6,8</sup> The most common sites for metastatic disease are the lungs followed by bone and liver. Late relapses (>5 years postoperatively) are

\*Corresponding author: P. Dillon, Division of Hematology/Oncology, University of Virginia, Box 800716, Charlottesville, VA 22908. E-mail: Pmd5b@virginia.edu  
Contract grant sponsor: Dr. Dillon is supported by University of Virginia Cancer Center Support Grant. Dr. Thomas is supported by Wake Forest Cancer Center Support Grant  
This is an open access article under the terms of the Creative Commons Attribution-NonCommercial-NoDerivs License, which permits use and distribution in any medium, provided the original work is properly cited, the use is non-commercial and no modifications or adaptations are made.  
The copyright line for this article was changed on 24 September 2018 after original online publication



**FIGURE 1.** (A) The photomicrograph shows a typical adenoid cystic carcinoma (ACC) with cribriform features. The tumor is arranged in nests of cells, with many nests containing cyst-like spaces with abundant extracellular matrix. The color of the matrix varies from pale red to light blue. In the inset, the tumor cells are shown to have scant cytoplasm and nuclei that show minimal pleomorphism. The tumor cell nuclei have small to inconspicuous nucleoli and the chromatin is finely dispersed. Mitotic figures are rare. (Hematoxylin-eosin stain, original magnification  $\times 100$ , inset  $\times 400$ .) (B) The photomicrograph shows an adenoid cystic carcinoma in an immunohistochemical stain for the MYB protein. Protein location is visualized as brown staining. The majority of tumor cells show moderate to strong staining, with localization to the nuclei (diaminobenzidine immunohistochemical stain, original magnification  $\times 400$ ). [Color figure can be viewed in the online issue, which is available at [wileyonlinelibrary.com](http://wileyonlinelibrary.com).]

well documented as are reports of rapid tumor progression after an extended period of indolent disease.

### Histopathology

The original histopathologic term for ACC of the salivary gland was “cylindroma” based on the histologic appearance of cylinders of epithelial/secretory cells and a hyaline stroma.<sup>8,9</sup> The tumor cells have angulated hyperchromatic nuclei and minimal cytoplasm, which is usually clear or eosinophilic. Electron microscopic and immunohistochemical studies have shown ACC to have biphasic differentiation with both myoepithelial and secretory glandular elements, although myoepithelial differentiation predominates.<sup>10–12</sup>

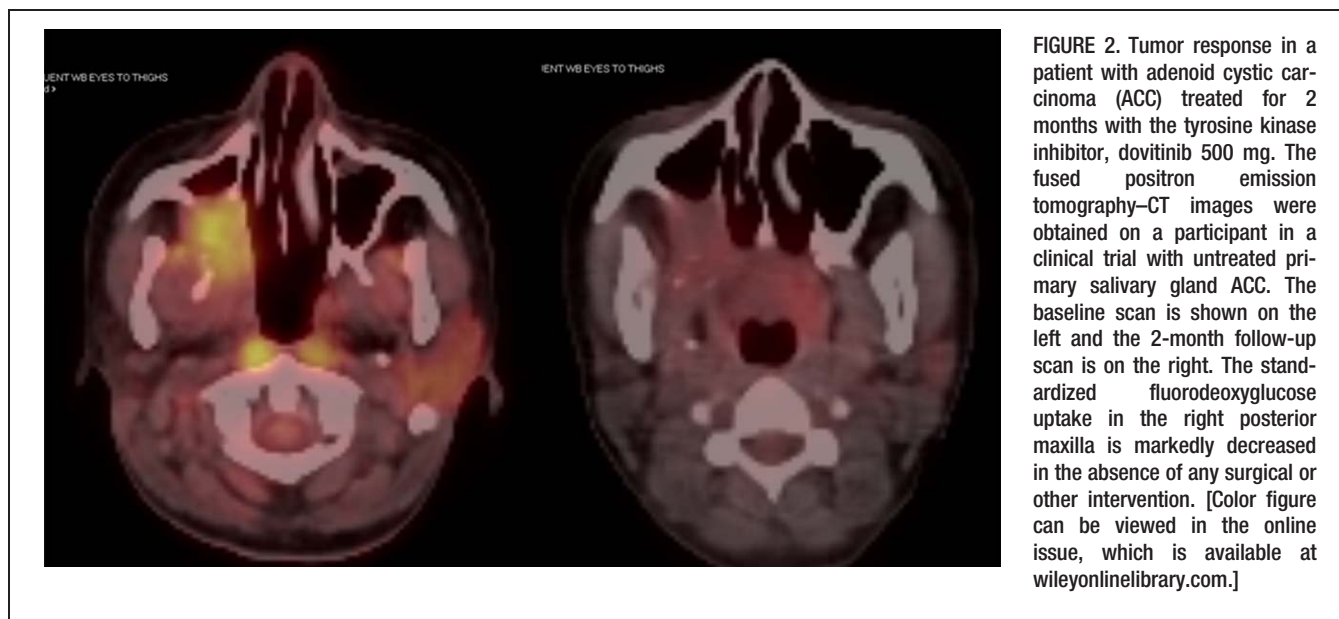ACCs exhibit varying proportions of 3 distinct growth patterns that are referred to as cribriform, tubular, and solid.<sup>8</sup> The cribriform subtype is the most frequent and shows islands of basaloid cells surrounded by variably sized cyst-like spaces that form a “Swiss cheese” pattern (see Figure 1). The cyst-like spaces do not represent true glandular lumina and are contiguous with the surrounding stroma. True glandular lumina with cuboidal cells are typically scattered throughout the tumor. The tubular pattern has a similar cytologic appearance but with the tumor cells arranged in nests surrounded by variable amounts of eosinophilic, often hyalinized stroma. The solid histologic subtype shows aggregates of basaloid cells without tubule nor pseudocystic formations.<sup>8,13</sup>

Immunohistochemistry is often necessary to firmly diagnose ACC. By immunohistochemistry, the myoepithelial tumor cells that surround the pseudocysts stain positively for smooth muscle actin, S100, vimentin, and smooth muscle myosin heavy chain.<sup>8</sup> Also, ACC cells are strongly positive for the receptor tyrosine kinase c-KIT (CD117) and MYB (Figure 1B) regardless of grade.<sup>8,14,15</sup> Biomarkers, such as c-KIT, vascular endothelial growth factor receptor (VEGFR)–3, Ki-67, and p53, have been linked to biologic aggressiveness and poor prognosis.<sup>8</sup> Other genes, such as *Beclin-1*,<sup>16</sup> may interact with p53 and Bcl-2 and may have a role in the pathogenesis as well. However, validation that these markers provide independent prognostic or predictive information is still needed before these can be applied in the clinic.

### Molecular pathogenesis

Investigation of the pathogenesis of ACC has been hampered by lack of validated cell lines. Nevertheless, studies of tumor tissues and, more recently, primary xenografts have provided important insights.<sup>17</sup> Analysis of tumor RNA by microarray revealed that ACCs express genes associated with myoepithelial differentiation along with high levels of the transcription factor Sox4.<sup>18</sup> The latter normally regulates embryonic development and is also a candidate human oncogene.<sup>19</sup> Other overexpressed genes include *casein kinase 1-epsilon* and *frizzled-7*, which are implicated in the Wnt/ $\beta$ -catenin signaling pathway and in tumorigenesis. This would be consistent with a separate report showing that ACCs contain activating mutations in components of the Wnt/ $\beta$ -catenin pathway.<sup>20</sup> Another finding is that ACC tumors frequently produce high levels of the receptor tyrosine kinase c-KIT (Figure 2) and variably overexpress other growth factor receptors, including fibroblast growth factor receptor 1 (FGFR1), epidermal growth factor receptor (EGFR), and/or human epidermal receptor-2 (HER-2).<sup>2,21–23</sup> Although each of these receptors has the potential to generate oncogenic growth factor signals, mutational activation or overexpression because of gene amplification of the cognate genes is rare.<sup>24,25</sup> Thus, autocrine stimulation of these receptors is believed to lead to constitutive signaling.

A careful chromosomal analysis and a recent sequencing of over 80 ACC genomes provide the most compelling clues to the pathogenesis of this tumor. Not surprisingly, ACC tumors demonstrate the acquisition of somatic gene mutations.<sup>24–26</sup> ACC tumors exhibit nonrandom gains or losses of specific chromosome regions,



**FIGURE 2.** Tumor response in a patient with adenoid cystic carcinoma (ACC) treated for 2 months with the tyrosine kinase inhibitor, dovitinib 500 mg. The fused positron emission tomography–CT images were obtained on a participant in a clinical trial with untreated primary salivary gland ACC. The baseline scan is shown on the left and the 2-month follow-up scan is on the right. The standardized fluorodeoxyglucose uptake in the right posterior maxilla is markedly decreased in the absence of any surgical or other intervention. [Color figure can be viewed in the online issue, which is available at [wileyonlinelibrary.com](http://wileyonlinelibrary.com).]

including what may be an ACC-specific deletion of chromosome 1p35–36. Other frequent deletions are located at 6q24, 12q, and 14q.<sup>23–25</sup> However, the most intriguing alteration is a translocation between chromosomes 6q and 9p [(6;9)(q22–23;p23–24)]. Persson et al<sup>27,28</sup> were the first to report that this rearrangement juxtaposes the genes for the MYB and nuclear factor I/B (NFIB) transcription factors. This translocation seems to be specific for ACC, found in up to 86% of these tumors,<sup>24,27,28</sup> and may be helpful in differentiating these tumors from other forms of carcinoma, such as pleomorphic adenoma.<sup>29,30</sup> One consequence of the rearrangement is the overexpression of a fusion transcript (perhaps related to absence of a 3' negative regulatory element found in the normal MYB mRNA) as well as a largely intact MYB oncoprotein. This leads to deregulation of expression of the MYB target genes, which, in turn, promotes tumorigenesis.<sup>28,31–33</sup> Alterations of NFIB may also be of significance because mutations that seem to target this gene have been described in some ACCs.<sup>24</sup>

The detailed analyses of ACC tumor genomes revealed fewer overall genetic alterations than are found in most other carcinomas.<sup>24,25,34</sup> In fact, MYB translocations were the only detectable mutations in a subset of tumors. This is consistent with the theory that deregulated MYB plays a central role in the pathogenesis of these tumors. In those tumors that had acquired non-MYB gene alterations, each exhibited a distinct mutational profile and only a few of the mutations were shared. Interestingly, tumor suppressor genes and oncogenes that are frequently mutated in other cancers were uncommon. For example, the p53 tumor suppressor gene was mutated in only 3 of the 84 tumors in the 2 studies, whereas RAS or phosphatidylinositol-3-kinase (PI3K) growth factor signaling proteins were mutated in only 7.<sup>24,25</sup> Although a number of mutations were unique or only in a small fraction of the tumors, the altered genes could be grouped together by their potential to disrupt specific cellular functions or biochemical pathways. This included those that interact

with the MYB transcription network, but also genes that influence chromatin remodeling, DNA damage/checkpoint responses, signaling pathways regulated by fibroblast growth factor (FGF)-insulin-like growth factor-PI3K, protein kinase A pathway, or Notch.<sup>24,25,35,36</sup> Understanding the specific contribution of each mutation to tumorigenesis might lead to novel pathways for targeted therapy.

### Clinical features

The most common presentation of ACC is an asymptomatic slowly enlarging mass, often in the head and neck area.<sup>3</sup> ACCs have been rarely noted to present as primary intraosseous lesions as well.<sup>37</sup> Pain or paresthesia may also be reported and likely reflect the tumor's propensity for perineural infiltration.<sup>4,38</sup>

Most ACC primary tumors are treated with adequate surgical resection, yet local and repeated recurrences are common. Recurrence may relate to perineural or perivascular invasion with occult cells beyond negative resection margins<sup>12,39</sup> or ACC may seed distally very early in tumorigenesis. Perineural involvement is common, it increases chances of recurrence, and could account for the 14% to 22% of patients with head and neck ACCs who develop intracranial tumor extension.<sup>40</sup> Recent data also suggests intraneural, rather than perineural, invasion has a larger impact on survival in head and neck ACC.<sup>41</sup> Other parameters that correlate with local recurrence after surgery are age, nonsalivary or minor salivary gland primary, T classification, tumor grade, lymphovascular invasion, and positive surgical margins.<sup>5,11,38,42,43</sup>

About 40% of patients with ACC develop metastatic disease.<sup>38</sup> Risk factors for the development of distant metastases are similar to the local recurrence risk factors above, with the additions of solid histology, size over 3 cm, and involvement of regional lymph nodes.<sup>1,5,38,44,45</sup> The most common sites of metastases are the lungs followed by bone, liver, skin, breast, and rarely the brain.<sup>44</sup> Intracranial disease, while rare, usually results from direct

TABLE 1. Targeted agents in adenoid cystic carcinoma.

Agent	Molecular target	Authors	Size	CR	PR	Overall response	Stable disease
Imatinib	c-KIT CD117	Hotte et al <sup>69</sup>	10	0	0	0	2 (20%)
Imatinib, cisplatin	c-KIT	Ghosal et al <sup>67</sup>	12	0	1 (8%)	1 (8%)	5 (42%)
Gefitinib	EGFR TKI	Jakob et al <sup>70</sup>	19	0	0	0	13 (68%)
Bortezomib	Proteasome inhibitor	Argiris et al <sup>78</sup>	25	0	0	0	16 (64%)
Lapatinib	HER-2, EGFR	Agulnik et al <sup>73</sup>	19	0	0	0	15 (79%)
Cetuximab (antibody)	EGFR	Locati et al <sup>71</sup>	23	0	0	0	20 (87%)
Sunitinib	VEGFR, c-KIT, PDGFR	Chau et al <sup>75</sup>	13	0	0	0	11 (62%)
Vorinostat	Histone deacetylase	Goncalves et al <sup>81</sup>	30	0	1	1	25 (83%)

Abbreviations: CR, complete response; PR, partial response; EGFR, epidermal growth factor receptor; TKI, tyrosine kinase inhibitor; HER-2, human epidermal receptor-2; VEGFR, vascular endothelial growth factor receptor; PDGFR, platelet-derived growth factor receptor.

tumor extension or invasion along cranial nerves rather than hematogenous spread.<sup>40,46</sup> Patients who develop metastatic ACC are considered incurable, except in the rare case in which single or oligometastatic disease is resectable.<sup>38</sup> Of those with disseminated disease, patients who have metastases limited to the lung survive longer than those with bone or other visceral metastases.<sup>47</sup> It is also important to note that although ACC in the breast can seem initially like invasive ductal carcinoma and is typically triple negative (estrogen receptor, progesterone receptor, and HER-2) it has a generally more favorable prognosis than conventional triple negative breast carcinomas and ACCs arising at other sites. The c-KIT, EGFR expression, and Ki-67 activity is typically low in these cases.<sup>48</sup> Clearly, a large proportion of patients harbor indolent tumors and may survive 5 to 10 years even with little or no therapy, yet others have tumors that grow more rapidly and some have tumors that grow rapidly only after a period of relative stability. A recent analysis of more than 2600 European patients with metastatic ACC confirmed that degree of variability in the clinical course, but overall observed that nearly two thirds of the patients had died after 5 years.<sup>49</sup>

## Surgery and radiotherapy

The preferred treatment for localized ACC is surgery that results in a complete resection and negative surgical margins while maintaining the function of the affected organs.<sup>4,6</sup> In the case of primary tumors of the head and neck, modified radical neck dissection is reserved for those with clinically positive cervical lymph nodes.<sup>4</sup> Despite adherence to good surgical technique, the 5 to 10 year recurrence rates range from 30% to 75%.<sup>50</sup>

One strategy to reduce local relapses is to administer postoperative radiotherapy. Although data from randomized trials is lacking, most practitioners consider such treatment to be beneficial.<sup>42,51,52</sup> In 1 retrospective study, the 5-year local control rate for patients treated with surgery followed by radiation therapy was 78% compared to 44% for those treated with surgery alone.<sup>53</sup> In another report, 10-year local control rates were 83% and 25% for patients who had surgery with or without postoperative radiation, respectively.<sup>54</sup> In yet another retrospective analysis of patients with submandibular ACCs, the benefit of postoperative radiation seemed more modest with local relapse-free survival at 67 months of 82% compared to 70% for those having only surgery.<sup>9</sup>

Although postoperative radiation seems to improve local control rates, the impact on ACC-specific survival is not clear.<sup>43,50,51</sup> Evaluation of survival is confounded by the requirement for long-term follow-up as one half of recurrences manifest after 5 years. Moreover, patients who experience local control may nonetheless develop recurrences outside the radiation field or at distant sites. Despite its limitations, postoperative radiation to 60 Gy or more is recommended after resection of intermediate or high-grade ACC or tumors of any grade with close or positive surgical margins.<sup>55</sup> Radiation is optional for patients with small tumors (T1N0), but should be considered for those who have low-grade tumors with perineural invasion or evidence of tumor spillage during surgery. Elective radiation of clinically negative regional nodes to a lesser dose has also been proposed for patients whose tumors are located in lymphatic-rich areas.<sup>51</sup>

Primary treatment with radiation should be considered when surgery is not feasible. In a series of 44 patients treated with definitive radiation alone, Balamucki et al<sup>51</sup> reported that 36% were free of local relapse at 10 years with an ACC cause-specific survival of 46%. For those patients who relapse after surgery, 1 older study indicated that the response rate to salvage radiation may be as high as 94%, but long-term control was achieved in only 10% of the patients.<sup>56</sup> Also, radiation is a standard treatment for palliation of brain and bone metastases.<sup>31</sup> Of note, modern radiation techniques, such as intensity-modulated radiation therapy, proton beam, and neutron beam therapies seem to be at least equally effective against ACC.<sup>57–59</sup>

## Chemotherapy

Many ACC tumors have slow growth kinetics and do not benefit from systemic chemotherapy. Nevertheless, several chemotherapy studies have been performed over the years. The results show consistently low response rates to cytotoxic chemotherapy for metastatic disease. Thus, there is no accepted standard systemic chemotherapy for patients with ACC tumors.

The complete listing of clinical trials of single agents and combination chemotherapies were recently reviewed by Laurie et al<sup>60</sup> and no new chemotherapy studies have been performed recently. The studies of chemotherapy for ACC range in size from 10 to 32 patients. The objective tumor response rate to single or multiple drug regimens ranges from 0% to 29%, with a single-institution outlier

TABLE 2. Ongoing or planned clinical trials of novel therapies for adenoid cystic carcinoma.

Agent	Target	Phase	Size	Institution
Axitinib	VEGF, PDGFR, c-KIT	II	32	Memorial Sloan–Kettering Hospital
Dasatinib	c-KIT, SRC family, PDGFR $\beta$ , EPHA2	II	65	University of Chicago, NCI consortium
Dovitinib	FGFR, VEGFR, PDGFR, c-KIT	II	35	University of Virginia
Dovitinib	FGF, VEGF, PDGFR, c-KIT	II	33	Seoul National University, South Korea
Dovitinib	FGF, VEGF, PDGFR, c-KIT	II	20	Ontario Clinical Oncology Group
Bortezomib + doxorubicin	Proteasome, NF- $\kappa$ B	II	35	University of Pittsburg
Cetuximab, IMRT	EGFR	I,II	49	University of Heidelberg, Germany
MK-2206	AKT	II	41	CALGB
Nelfinavir	AKT and MAPK pathways	II	35	University of Iowa
Everolimus	mTOR	II	33	Seoul National University, South Korea

Abbreviations: VEGF, vascular endothelial growth factor; PDGFR, platelet-derived growth factor receptor; NCI, National Cancer Institute; EPHA2, ephrin type-A receptor 2; FGFR, fibroblast growth factor receptor; VEGFR, vascular endothelial growth factor receptor; FGF, fibroblast growth factor; NF- $\kappa$ B, nuclear factor-kappa B; IMRT, intensity-modulated radiation therapy; EGFR, epidermal growth factor receptor; CALGB, Cancer and Leukemia Group B; MAPK, mitogen-activated protein kinase; mTOR, mammalian target of rapamycin.

that reported 7 responses to cisplatin in 10 patients.<sup>61</sup> Other studies found 0% response rates to cisplatin,<sup>62,63</sup> and thus the role of cisplatin for metastatic disease remains unclear. The variation in response rates is likely because of the small number of patients in each study and risk for single institution bias. Overall, the antitumor activity across a variety of chemotherapy classes is poor. A French literature review examining various chemotherapy regimens for ACC based on studies published after 2000 suggested that the strongest rationale remains in favor of cisplatin,<sup>64</sup> but prospective data is lacking. In addition, a meta-analysis of published trials concluded that combination chemotherapy offered no advantage over single-agent therapy.<sup>60</sup> In view of these observations, the role of single-agent or combination chemotherapy for palliation of ACC remains controversial. A consensus is to reserve chemotherapy for palliation of patients with symptomatic metastases or rapidly progressing disease who are not candidates for other treatment modalities or clinical trials.

### Targeted and novel agents

Given the ineffectiveness of cytotoxic chemotherapy in advanced ACC, investigators have focused on targeted therapies. Most of the drugs currently in trials were selected based on observations from preclinical studies initiated before the elucidation of ACC genome (Table 1). For example, the finding that 65% to 90% of ACCs overexpress c-KIT (CD117), a known oncoprotein, suggested that this receptor would be an appropriate therapeutic target.<sup>21,65,66</sup> Imatinib, a c-KIT inhibitor, produces high rates of responses in gastrointestinal stromal tumors with mutant forms of c-KIT. However, in 4 phase II clinical trials, only 2 of 42 patients with ACC treated with imatinib experienced objective tumor responses. The addition of cisplatin to imatinib also did not improve outcome as only 3 tumor responses were seen in 28 patients.<sup>67</sup> These disappointing results suggest that the overexpressed c-KIT receptors are not actively signaling in ACC cells or are not the major drivers of the malignant phenotype. Additionally, it is now clear from sequencing data that ACC tumors express wild-type c-KIT.<sup>24,25,66,68,69</sup>

The potential benefit of targeting the EGFR family members in ACC has also been tested. Jakob et al<sup>70</sup>

treated 18 patients with ACC with gefitinib, a small molecule inhibitor of EGFR kinase. None of the patients had an objective tumor response, although stable disease was seen in 13 (68%). In another trial, 20 patients received cetuximab, a chimeric monoclonal antibody to the EGFR.<sup>71</sup> Once again, no objective responses were observed, although 20 of 23 (87%) had stable disease. Cetuximab was also tested in conjunction with chemotherapy (radiation and cisplatin for local disease, cisplatin +5-fluorouracil for metastatic disease), which reported a >40% objective response rate. The median progression-free survival (PFS) was 64 months and the overall survival rate was 100% for localized disease, whereas median PFS was 13 months and the overall survival was 24 months.<sup>72</sup> Agulnik et al<sup>73</sup> conducted a phase II trial for patients whose tumors expressed EGFR and/or HER-2. Those patients were given lapatinib, an agent that blocks signaling by both receptors. No objective tumor responses were observed. Taken together, these trials suggest that signaling by the EGFR and/or HER-2 signaling is a minor contributor to the malignant phenotype.

Tumor angiogenesis by the VEGFR is hypothesized to play a role in the pathogenesis of ACC. The expression of the receptor ligand, vascular endothelial growth factor (VEGF) by tumor cells correlates with tumor size and stage, vascular invasion, and increased risk of recurrence and metastasis.<sup>74</sup> Moreover, VEGF-A is a candidate downstream effector of deregulated MYB expression.<sup>33</sup> Thus, inhibition of VEGFR signaling in the endothelial cells of the tumor vasculature may suppress tumor blood flow and tumor growth. However, a phase II trial of sunitinib, a small-molecule inhibitor of the VEGFR kinases (as well as well as c-KIT, platelet-derived growth factor receptor [PDGFR]  $\alpha/\beta$ , and rearranged during transfection), failed to induce objective tumor responses in any of 13 patients with ACC. On the other hand, the drug proved to be well tolerated and 11 patients had radiological stable disease after 2 months and 8 had stability for  $\geq$ 6 months.<sup>75</sup> The median time to progression was 7.2 months and median overall survival was 18.7 months. A trial testing another multikinase and VEGFR inhibitor, axitinib, is currently underway (Table 2); 1 patient treated with this agent reportedly achieved a partial response that lasted 4 months.<sup>76</sup>

Another receptor kinase that is a potential therapeutic target is the FGFR. Preclinical studies by Moskaluk et al<sup>17</sup> of low-passage primary ACC xenografts expressed spontaneously activated FGFR-1 receptors. This could be explained by autocrine activation of the receptor driven by concomitant expression of one its ligands, FGF2. This growth factor is upregulated in ACC cells with MYB overexpression and therefore is a candidate downstream effector of this oncoprotein.<sup>33,77</sup> The relevance of FGF signaling to ACC tumorigenesis is further supported by the description of mutations in the *FGF14*, *FGFR4*, or *FGFR2* genes in 4 different tumors.<sup>24,25</sup> These observations provide a rationale for testing FGFR inhibitors in ACC. One such inhibitor is dovitinib, which is a small molecule inhibitor of the FGFR 1 to 3 kinases that also blocks signaling by the VEGFR, PDGFR $\beta$ , colony stimulating factor 1 receptor, c-KIT, rearranged during transfection, TrkA, and FMS-like tyrosine kinase 3 (FLT-3).<sup>78,79</sup> The drug demonstrates activity against a variety of tumor types both in vitro and in vivo with effects on cell proliferation, angiogenesis, and/or stromal elements that promote tumor growth. Of note, dovitinib suppressed tumor growth in the ACC xenograft model.<sup>17</sup>

Dovitinib is being evaluated for antitumor activity in 3 phase II trials (Table 2). In the University of Virginia study, 2 participants experienced metabolic responses with reductions of 18F-fluorodeoxyglucose uptake in tumor tissues as measured by positron emission tomography (Figure 2). Two objective tumor responses and several stable diseases were also reported in 2013.<sup>80</sup> Because dovitinib is a multikinase inhibitor, it is not yet clear if these promising early results are related to inhibition of FGFR, the other targeted kinases, or a combination of these.

Other ongoing studies are testing agents that target components downstream of activated FGFR and other growth factors such as AKT, mitogen-activated protein kinase, and mammalian target of rapamycin (Table 2). In an early report, the histone deacetylase inhibitor, vorinostat, achieved stable disease in 25 of 30 patients and had 1 partial response.<sup>81</sup> Hoover et al<sup>82</sup> conducted a phase II clinical trial with nelfinavir, which targets AKT signaling in patients with advanced ACC and did not note a significant clinical response with nelfinavir as a monotherapy. In most of the targeted trials, including the 3 mentioned above, patients are required to have evidence of disease progression by Response Evaluation Criteria in Solid Tumors within 6 months of study participation in order to avoid falsely assessing disease stabilization.

In summary, trials of targeted therapy to date have not yet identified an agent with sufficient activity to be deemed standard in the treatment of advanced ACC. However, sunitinib may extend PFS and the agents dovitinib and vorinostat seem to produce responses in a small proportion of patients. There is hope that current or future studies of these and related targeted agents may reveal clinically relevant antitumor activity.

## CONCLUSIONS

The elucidation of the genetic basis of ACCs has identified novel candidate therapeutic targets. Perhaps the most appealing is the MYB oncoprotein, given the high

frequency of translocation of the cognate gene. However, finding a compound that specifically inhibits the MYB transcriptional function presents a formidable challenge. On the other hand, some of the proposed downstream effectors of MYB may be more “druggable.” These include cell proliferation proteins (*MYC*, *CD53*, *FGF2*, *VEGFA*, and *KIT*), cell cycle proteins (*CCNB1*, *CDC2*, and *MAD1L1*), apoptosis-related markers (*API5*, *BCL2*, *BIRC3*, *HSPA8*, and *SET*), and cellular adhesion molecules (*CD34*).<sup>28</sup> In addition, the tumor DNA studies suggest that agents that inhibit signaling through the Notch, protein kinase A, or FGF-insulin-like growth factor-PI3K pathways or block the epigenetic effects of chromatin remodeling may also be active in ACC.<sup>24,25</sup>

In regard to treatment, surgery with adjuvant radiotherapy is favored for primary disease. For systemic disease, local therapies are preferred when possible. Otherwise, clinical trial participation is preferred. For indolent cases of metastatic disease, observation is standard and may be superior to systemic therapy. In rapidly progressive systemic disease, chemotherapy may offer modest control in a minority of patients. Targeted agents are early in development for ACC and care should be taken if using them off-trial.

As with other tumors, future trials of pathway-targeting agents are expected to be limited to patients whose tumors carry the relevant targets. In addition, the discovery of new effective therapies for ACC could be accelerated by modifications in clinical trial designs that detect clinically relevant stable responses or incorporate early novel endpoints that predict for subsequent improvements in overall survival.

## REFERENCES

- Chummun S, McLean NR, Kelly CG, et al. Adenoid cystic carcinoma of the head and neck. *Br J Plast Surg* 2001;54:476–480.
- Spiro RH, Huvos AG, Strong EW. Adenoid cystic carcinoma of salivary origin. A clinicopathologic study of 242 cases. *Am J Surg* 1974;128:512–520.
- Papaspyrou G, Hoch S, Rinaldo A, et al. Chemotherapy and targeted therapy in adenoid cystic carcinoma of the head and neck: a review. *Head Neck* 2011;33:905–911.
- Spiro RH, Huvos AG. Stage means more than grade in adenoid cystic carcinoma. *Am J Surg* 1992;164:623–628.
- Khan AJ, DiGiovanna MP, Ross DA, et al. Adenoid cystic carcinoma: a retrospective clinical review. *Int J Cancer* 2001;96:149–158.
- Li N, Xu L, Zhao H, El-Naggar AK, Sturgis EM. A comparison of the demographics, clinical features, and survival of patients with adenoid cystic carcinoma of major and minor salivary glands versus less common sites within the Surveillance, Epidemiology, and End Results registry. *Cancer* 2012;118:3945–3953.
- Jaso J, Malhotra R. Adenoid cystic carcinoma. *Arch Pathol Lab Med* 2011;135:511–515.
- Azumi N, Battifora H. The cellular composition of adenoid cystic carcinoma. An immunohistochemical study. *Cancer* 1987;60:1589–1598.
- Caselitz J, Schulze I, Seifert G. Adenoid cystic carcinoma of the salivary glands: an immunohistochemical study. *J Oral Pathol* 1986;15:308–318.
- Chen W, Dong S, Zhou J, Sun M. Investigation of myoepithelial cell differentiation into Schwann-like cells in salivary adenoid cystic carcinoma associated with perineural invasion. *Mol Med Rep* 2012;6:755–759.
- Prasad AR, Savera AT, Gown AM, Zarbo RJ. The myoepithelial immunophenotype in 135 benign and malignant salivary gland tumors other than pleomorphic adenoma. *Arch Pathol Lab Med* 1999;123:801–806.
- Moskaluk CA. Adenoid cystic carcinoma: clinical and molecular features. *Head Neck Pathol* 2013;7:17–22.
- Andreadis D, Epivatianos A, Pouloupoulos A, et al. Detection of C-KIT (CD117) molecule in benign and malignant salivary gland tumours. *Oral Oncol* 2006;42:57–65.
- Vila L, Liu H, Al-Quran SZ, Coco DP, Dong HJ, Liu C. Identification of c-kit gene mutations in primary adenoid cystic carcinoma of the salivary gland. *Mod Pathol* 2009;22:1296–1302.

15. Jiang LC, Huang SY, Zhang DS, et al. Expression of beclin 1 in primary salivary adenoid cystic carcinoma and its relation to Bcl-2 and p53 and prognosis. *Braz J Med Biol Res* 2014;47:252–258.
16. Moskaluk CA, Baras AS, Mancuso SA, et al. Development and characterization of xenograft model systems for adenoid cystic carcinoma. *Lab Invest* 2011;91:1480–1490.
17. Frierson HF Jr, El-Naggar AK, Welsh JB, et al. Large scale molecular analysis identifies genes with altered expression in salivary adenoid cystic carcinoma. *Am J Pathol* 2002;161:1315–1323.
18. Dong C, Wilhelm D, Koopman P. Sox genes and cancer. *Cytogenet Genome Res* 2004;105:442–447.
19. Daa T, Kashima K, Kaku N, Suzuki M, Yokoyama S. Mutations in components of the Wnt signaling pathway in adenoid cystic carcinoma. *Mod Pathol* 2004;17:1475–1482.
20. Edwards PC, Bhuiya T, Kelsch RD. C-kit expression in the salivary gland neoplasms adenoid cystic carcinoma, polymorphous low-grade adenocarcinoma, and monomorphic adenoma. *Oral Surg Oral Med Oral Pathol Oral Radiol Endod* 2003;95:586–593.
21. Ito FA, Ito K, Coletta RD, Graner E, de Almeida OP, Lopes MA. Salivary gland tumors: immunohistochemical study of EGF, EGFR, ErbB-2, FAS and Ki-67. *Anal Quant Cytol Histol* 2009;31:280–287.
22. Myoken Y, Myoken Y, Okamoto T, et al. Immunohistochemical study of overexpression of fibroblast growth factor-1 (FGF-1), FGF-2, and FGF receptor-1 in human malignant salivary gland tumours. *J Pathol* 1996;178:429–436.
23. Rao PH, Roberts D, Zhao YJ, et al. Deletion of 1p32-p36 is the most frequent genetic change and poor prognostic marker in adenoid cystic carcinoma of the salivary glands. *Clin Cancer Res* 2008;14:5181–5187.
24. Ho AS, Kannan K, Roy DM, et al. The mutational landscape of adenoid cystic carcinoma. *Nat Genet* 2013;45:791–798.
25. Stephens R, Mythen M, Kallis P, Davies DW, Egner W, Rickards A. Two episodes of life-threatening anaphylaxis in the same patient to a chlorhexidine-sulphadiazine-coated central venous catheter. *Br J Anaesth* 2001;87:306–308.
26. Zhang J, Peng B, Chen X. Expressions of nuclear factor kappaB, inducible nitric oxide synthase, and vascular endothelial growth factor in adenoid cystic carcinoma of salivary glands: correlations with the angiogenesis and clinical outcome. *Clin Cancer Res* 2005;11:7334–7343.
27. Persson F, Fehr A, Sundelin K, Schulte B, Löning T, Stenman G. Studies of genomic imbalances and the MYB-NFIB gene fusion in polymorphous low-grade adenocarcinoma of the head and neck. *Int J Oncol* 2012;40:80–84.
28. Persson M, Andrén Y, Moskaluk CA, et al. Clinically significant copy number alterations and complex rearrangements of MYB and NFIB in head and neck adenoid cystic carcinoma. *Genes Chromosomes Cancer* 2012;51:805–817.
29. Hudson JB, Collins BT. MYB gene abnormalities t(6;9) in adenoid cystic carcinoma fine-needle aspiration biopsy using fluorescence in situ hybridization. *Arch Pathol Lab Med* 2014;138:403–409.
30. Pusztaszeri MP, Sadow PM, Ushiku A, Bordignon P, McKee TA, Faquin WC. MYB immunostaining is a useful ancillary test for distinguishing adenoid cystic carcinoma from pleomorphic adenoma in fine-needle aspiration biopsy specimens. *Cancer Cytopathol* 2014;122:257–265.
31. Brill LB II, Kanner WA, Fehr A, et al. Analysis of MYB expression and MYB-NFIB gene fusions in adenoid cystic carcinoma and other salivary neoplasms. *Mod Pathol* 2011;24:1169–1176.
32. Mitani Y, Li J, Rao PH, et al. Comprehensive analysis of the MYB-NFIB gene fusion in salivary adenoid cystic carcinoma: incidence, variability, and clinicopathologic significance. *Clin Cancer Res* 2010;16:4722–4731.
33. Stenman G, Andersson MK, Andrén Y. New tricks from an old oncogene: gene fusion and copy number alterations of MYB in human cancer. *Cell Cycle* 2010;9:2986–2995.
34. Frierson HF Jr, Moskaluk CA. Mutation signature of adenoid cystic carcinoma: evidence for transcriptional and epigenetic reprogramming. *J Clin Invest* 2013;123:2783–2785.
35. Ross JS, Ali SM, Wang K, et al. Comprehensive genomic profiling of epithelial ovarian cancer by next generation sequencing-based diagnostic assay reveals new routes to targeted therapies. *Gynecol Oncol* 2013;130:554–559.
36. Bell D, Hanna EY, Miele L, Roberts D, Weber RS, El-Naggar AK. Expression and significance of notch signaling pathway in salivary adenoid cystic carcinoma. *Ann Diagn Pathol* 2014;18:10–13.
37. Bouaichi A, Aimad-Eddine S, Mommers XA, Ella B, Zwetyenga N. Intra-mandibular adenoid cystic carcinoma. *Rev Stomatol Chir Maxillofac Chir Orale* 2014;115:100–104.
38. Dodd RL, Slevin NJ. Salivary gland adenoid cystic carcinoma: a review of chemotherapy and molecular therapies. *Oral Oncol* 2006;42:759–769.
39. Bradley PJ. Adenoid cystic carcinoma of the head and neck: a review. *Curr Opin Otolaryngol Head Neck Surg* 2004;12:127–132.
40. Kazumoto K, Hayase N, Kurosumi M, Kishi K, Uki J, Takeda F. Multiple brain metastases from adenoid cystic carcinoma of the parotid gland. Case report and review of the literature. *Surg Neurol* 1998;50:475–479.
41. Amit M, Binenbaum Y, Trejo-Leider L, et al. International collaborative validation of intraneural invasion as a prognostic marker in adenoid cystic carcinoma of the head and neck. *Head Neck* 2014. [Epub ahead of print].
42. Garden AS, Weber RS, Morrison WH, Ang KK, Peters LJ. The influence of positive margins and nerve invasion in adenoid cystic carcinoma of the head and neck treated with surgery and radiation. *Int J Radiat Oncol Biol Phys* 1995;32:619–626.
43. Oplatek A, Ozer E, Agrawal A, Bapna S, Schuller DE. Patterns of recurrence and survival of head and neck adenoid cystic carcinoma after definitive resection. *Laryngoscope* 2010;120:65–70.
44. Spiro RH. Distant metastasis in adenoid cystic carcinoma of salivary origin. *Am J Surg* 1997;174:495–498.
45. Fordice J, Kershaw C, El-Naggar A, Goepfert H. Adenoid cystic carcinoma of the head and neck: predictors of morbidity and mortality. *Arch Otolaryngol Head Neck Surg* 1999;125:149–152.
46. Hammoud MA, Hassenbusch SJ, Fuller GN, Shi W, Leeds NE. Multiple brain metastases: a rare manifestation of adenoid cystic carcinoma of the parotid gland. *J Neurooncol* 1996;27:61–64.
47. Sur RK, Donde B, Levin V, et al. Adenoid cystic carcinoma of the salivary glands: a review of 10 years. *Laryngoscope* 1997;107:1276–1280.
48. Kim M, Lee DW, Im J, et al. Adenoid cystic carcinoma of the breast: a case series of six patients and literature review. *Cancer Res Treat* 2014;46:93–97.
49. Ciccolallo L, Licita L, Cantú G, Gatta G; EUROCARE Working Group. Survival from salivary glands adenoid cystic carcinoma in European populations. *Oral Oncol* 2009;45:669–674.
50. Chen AM, Bucci MK, Weinberg V, et al. Adenoid cystic carcinoma of the head and neck treated by surgery with or without postoperative radiation therapy: prognostic features of recurrence. *Int J Radiat Oncol Biol Phys* 2006;66:152–159.
51. Balamucki CJ, Amdur RJ, Werning JW, et al. Adenoid cystic carcinoma of the head and neck. *Am J Otolaryngol* 2012;33:510–518.
52. Gomez DR, Hoppe BS, Wolden SL, et al. Outcomes and prognostic variables in adenoid cystic carcinoma of the head and neck: a recent experience. *Int J Radiat Oncol Biol Phys* 2008;70:1365–1372.
53. Miglianico L, Eschwege F, Marandas P, Wibault P. Cervico-facial adenoid cystic carcinoma: study of 102 cases. Influence of radiation therapy. *Int J Radiat Oncol Biol Phys* 1987;13:673–678.
54. Simpson JR, Thawley SE, Matsuba HM. Adenoid cystic salivary gland carcinoma: treatment with irradiation and surgery. *Radiology* 1984;151:509–512.
55. National Comprehensive Cancer Network. Head and neck cancer (version 2.2014). 2014. Available at: www.nccn.org. Accessed June 30, 2014.
56. Vikram B, Strong EW, Shah JP, Spiro RH. Radiation therapy in adenoid-cystic carcinoma. *Int J Radiat Oncol Biol Phys* 1984;10:221–223.
57. Huber PE, Debus J, Latz D, et al. Radiotherapy for advanced adenoid cystic carcinoma: neutrons, photons or mixed beam? *Radiother Oncol* 2001;59:161–167.
58. Münter MW, Schulz-Ertner D, Hof H, et al. Inverse planned stereotactic intensity modulated radiotherapy (IMRT) in the treatment of incompletely and completely resected adenoid cystic carcinomas of the head and neck: initial clinical results and toxicity of treatment. *Radiat Oncol* 2006;1:17.
59. Stannard C, Vermimmen F, Carrara H, et al. Malignant salivary gland tumours: can fast neutron therapy results point the way to carbon ion therapy? *Radiother Oncol* 2013;109:262–268.
60. Laurie SA, Ho AL, Fury MG, Sherman E, Pfister DG. Systemic therapy in the management of metastatic or locally recurrent adenoid cystic carcinoma of the salivary glands: a systematic review. *Lancet Oncol* 2011;12:815–824.
61. Schramm VL Jr, Srodes C, Myers EN. Cisplatin therapy for adenoid cystic carcinoma. *Arch Otolaryngol* 1981;107:739–741.
62. de Haan LD, De Mulder PH, Vermorken JB, Schornagel JH, Vermey A, Verweij J. Cisplatin-based chemotherapy in advanced adenoid cystic carcinoma of the head and neck. *Head Neck* 1992;14:273–277.
63. Licitra L, Marchini S, Spinazzè S, et al. Cisplatin in advanced salivary gland carcinoma. A phase II study of 25 patients. *Cancer* 1991;68:1874–1877.
64. Cerda T, Sun XS, Vignot S, et al. A rationale for chemoradiation (vs radiotherapy) in salivary gland cancers? On behalf of the REFCOR (French rare head and neck cancer network). *Crit Rev Oncol Hematol* 2014;91:142–158.
65. Locati LD, Perrone F, Losa M, et al. Treatment relevant target immunophenotyping of 139 salivary gland carcinomas (SGCs). *Oral Oncol* 2009;45:986–990.
66. Holst VA, Marshall CE, Moskaluk CA, Frierson HF Jr. KIT protein expression and analysis of c-kit gene mutation in adenoid cystic carcinoma. *Mod Pathol* 1999;12:956–960.
67. Ghosal N, Mais K, Shenjere P, et al. Phase II study of cisplatin and imatinib in advanced salivary adenoid cystic carcinoma. *Br J Oral Maxillofac Surg* 2011;49:510–515.
68. Duffaud F, Le Cesne A. Imatinib in the treatment of solid tumours. *Target Oncol* 2009;4:45–56.
69. Hotte SJ, Winquist EW, Lamont E, et al. Imatinib mesylate in patients with adenoid cystic cancers of the salivary glands expressing c-kit: a Princess Margaret Hospital phase II consortium study. *J Clin Oncol* 2005;23:585–590.
70. Jakob JA, Kies MS, Glisson BS, et al. A phase II study of gefitinib in patients with advanced salivary gland cancers. *Head Neck* 2014. [Epub ahead of print].

71. Locati LD, Bossi P, Perrone F, et al. Cetuximab in recurrent and/or metastatic salivary gland carcinomas: a phase II study. *Oral Oncol* 2009;45:574–578.
72. Hitre E, Budai B, Takácsi-Nagy Z, et al. Cetuximab and platinum-based chemoradio- or chemotherapy of patients with epidermal growth factor receptor expressing adenoid cystic carcinoma: a phase II trial. *Br J Cancer* 2013;109:1117–1122.
73. Agulnik M, Cohen EW, Cohen RB, et al. Phase II study of lapatinib in recurrent or metastatic epidermal growth factor receptor and/or erbB2 expressing adenoid cystic carcinoma and non adenoid cystic carcinoma malignant tumors of the salivary glands. *J Clin Oncol* 2007;25:3978–3984.
74. Hao L, Xiao-lin N, Qi C, Yi-ping Y, Jia-quan L, Yan-ning L. Nerve growth factor and vascular endothelial growth factor: retrospective analysis of 63 patients with salivary adenoid cystic carcinoma. *Int J Oral Sci* 2010;2:35–44.
75. Chau NG, Hotte SJ, Chen EX, et al. A phase II study of sunitinib in recurrent and/or metastatic adenoid cystic carcinoma (ACC) of the salivary glands: current progress and challenges in evaluating molecularly targeted agents in ACC. *Ann Oncol* 2012;23:1562–1570.
76. Rugo HS, Herbst RS, Liu G, et al. Phase I trial of the oral antiangiogenesis agent AG-013736 in patients with advanced solid tumors: pharmacokinetic and clinical results. *J Clin Oncol* 2005;23:5474–5483.
77. Persson M, Andrén Y, Mark J, Horlings HM, Persson F, Stenman G. Recurrent fusion of MYB and NFIB transcription factor genes in carcinomas of the breast and head and neck. *Proc Natl Acad Sci U S A* 2009;106:18740–18744.
78. Argiris A, Burtneß B, Axelrod RS, Deconti RC, Forastiere AA. A phase 2 trial of bortezomib followed by the addition of doxorubicin at progression in patients with recurrent or metastatic adenoid cystic carcinoma of the head and neck: a trial of the Eastern Cooperative Oncology Group (E1303). *Cancer*. 2011;117:3374–3382.
79. Dubbelman AC, Uthagrove A, Beijnen JH, et al. Disposition and metabolism of 14C-dovitinib (TKI258), an inhibitor of FGFR and VEGFR, after oral administration in patients with advanced solid tumors. *Cancer Chemother Pharmacol* 2012;70:653–663.
80. Dillon P, Moskaluk CA, Petroni G, et al. Phase II study of dovitinib (TKI258) in patients with progressive metastatic adenoid cystic carcinoma. *J Clin Oncol* 2013;31(suppl):abstract 6021.
81. Goncalves P, Kummar S, Siu LL, et al. A phase II study of suberoylanilide hydroxamic acid (SAHA) in subjects with locally advanced, recurrent, or metastatic adenoid cystic carcinoma (ACC). *J Clin Oncol* 2013;31(suppl): abstract 6045.
82. Hoover AC, Milhem MM, Anderson CM, et al. Efficacy of nelfinavir as monotherapy in refractory adenoid cystic carcinoma: results of a phase II clinical trial. *Head Neck* 2014. [Epub ahead of print].