

# Ocular Manifestations of Emerging Arthropod-Borne Infectious Diseases

Nesrine Abroug<sup>1,2</sup>, Molka Khairallah<sup>1,2</sup>, Sourour Zina<sup>1,2</sup>, Imen Ksiao<sup>1,2</sup>, Hager Ben Amor<sup>1,2</sup>, Sonia Attia<sup>1,2</sup>, Bechir Jelliti<sup>1,2</sup>, Sana Khochtali<sup>1,2</sup>, Moncef Khairallah<sup>1,2</sup>

<sup>1</sup>Department of Ophthalmology, Fattouma Bourguiba University Hospital, Monastir, Tunisia, <sup>2</sup>Departement of Ophthalmology, Faculty of Medicine, University of Monastir, Monastir, Tunisia

## Abstract

**Purpose:** To review the clinical features, diagnosis, treatment modalities, and prognosis of arthropod-borne infectious diseases.

**Methods:** This is a narrative review on arthropod-borne infectious diseases including general and ophthalmological aspects of these infectious diseases. A comprehensive literature review between January 1983 and September 2020 was conducted in PubMed database. Epidemiology, clinical features, diagnosis, treatment, and prognosis of arthropod-borne infectious diseases were reviewed.

**Results:** Emergent and resurgent arthropod-borne infectious diseases are major causes of systemic morbidity and death that are expanding worldwide. Among them, bacterial and viral agents including rickettsial disease, West Nile virus, Dengue fever, Chikungunya, Rift valley fever, and Zika virus have been associated with an array of ocular manifestations. These include anterior uveitis, retinitis, chorioretinitis, retinal vasculitis, and optic nerve involvement. Proper clinical diagnosis of any of these infectious diseases is primarily based on epidemiological data, history, systemic symptoms and signs, and the pattern of ocular involvement. The diagnosis is confirmed by laboratory tests. Ocular involvement usually has a self-limited course, but it can result in persistent visual impairment. Doxycycline is the treatment of choice for rickettsial disease. There is currently no proven specific treatment for arboviral diseases. Prevention remains the mainstay for arthropod vector and zoonotic disease control.

**Conclusions:** Emerging arthropod vector-borne diseases should be considered in the differential diagnosis of uveitis, especially in patient living or with recent travel to endemic countries. Early clinical diagnosis, while laboratory testing is pending, is essential for proper management to prevent systemic and ocular morbidity.

**Keywords:** Arthropod-borne diseases, Chikungunya, Chorioretinitis, Infection, Posterior Uveitis, Retinitis, Rickettsial, Rift valley fever, Vasculitis, West Nile virus, Zika

**Address for correspondence:** Moncef Khairallah, Department of Ophthalmology, Fattouma Bourguiba University Hospital, 5000 Monastir, Tunisia.

E-mail: moncef.khairallah@rns.tn

**Submitted:** 17-Jan-2021; **Revised:** 25-Apr-2021; **Accepted:** 25-Apr-2021; **Published:** 22-Oct-2021

## INTRODUCTION

Vector-borne diseases are among the most important emergent and resurgent infections that are mostly prevalent in tropical and subtropical areas, tending to expand worldwide, mainly due to climate changes and globalization.<sup>1</sup> They are caused by bacteria, viruses, and parasites transmitted by the bite of hematophagous arthropods, mainly ticks and mosquitoes.

Most vector-borne diseases are subclinical or manifest as a mild febrile illness, but a severe, potentially lethal systemic involvement can occur. Specific bacterial and viral arthropod vector-borne diseases including rickettsioses, West Nile virus (WNV) infection, rift valley fever (RVF), Dengue fever (DF), Chikungunya, and Zika have been recently associated with uveitis and other ocular manifestations.<sup>1-5</sup> The

### Access this article online

Quick Response Code:



**Website:**  
www.jcurrophthalmol.org

**DOI:**  
10.4103/joco.joco\_134\_21

This is an open access journal, and articles are distributed under the terms of the Creative Commons Attribution-NonCommercial-ShareAlike 4.0 License, which allows others to remix, tweak, and build upon the work non-commercially, as long as appropriate credit is given and the new creations are licensed under the identical terms.

**For reprints contact:** WKHLRPMedknow\_reprints@wolterskluwer.com

**How to cite this article:** Abroug N, Khairallah M, Zina S, Ksiao I, Ben Amor H, Attia S, *et al.* Ocular manifestations of emerging arthropod-borne infectious diseases. *J Curr Ophthalmol* 2021;33:227-35.

purpose of this manuscript is to describe systemic and ocular features of these emerging arthropod-borne infections.

## METHODS

The literature review for this study was based on a search in PubMed/Medline and Scopus databases to identify original articles, reviews, and case reports between January 1983 and September 2020 in the English language regarding arthropod-borne infectious diseases. The following keywords were used (“Arthropod-Borne Diseases” OR “Vector-Borne Diseases” OR “Zoonotic Diseases” OR “Emerging Infections” OR “Resurgent Infections”) AND (“Eye” OR “Uveitis” OR “Retinitis” OR “Chorioretinitis” OR “Retinal Vasculitis”). All selected articles were reviewed thoroughly by the authors to review epidemiology, pathogenesis, clinical features, diagnosis, treatment, and prognosis of arthropod-borne diseases.

## RESULTS

### *Rickettsioses*

Rickettsioses are worldwide distributed zoonoses due to obligate intracellular small gram-negative bacteria. Most of them are transmitted to humans by the bite of contaminated arthropods such as ticks.<sup>1-3</sup> Rickettsial agents are classified into three major categories: the spotted fever group, the typhus group, and the scrub typhus.<sup>1-3</sup>

### *Systemic disease*

The incubation period for rickettsial disease varies between 2 and 21 days. The initial presentation typically includes high fever with abrupt onset, headache, and myalgia. A maculopapular skin rash usually appears 3–5 days after the onset of fever.<sup>1-3</sup> The skin rash, involving also the palms of the hands and the soles of the feet, is a hallmark of rickettsial infection. However, its absence should not rule out a possible rickettsial infection, especially during the first week of illness. A local skin lesion, termed tache noire (black spot), at the inoculating site may be seen in several rickettsial infections including Mediterranean spotted fever, caused by rickettsia conorii infection. Severe systemic complications may occur including interstitial pneumonitis, meningoencephalitic syndrome, acute renal failure, and disseminated intravascular coagulation.

### *Ocular disease*

Ocular involvement is common in patients with rickettsiosis, but since it is frequently asymptomatic and self-limited, it may be easily overlooked.<sup>1-3,6-8</sup> However, patients may present with ocular symptoms such as decreased vision, scotomas, floaters, or redness.

Bilateral or rarely unilateral nonnecrotizing retinitis, with or without associated mild vitritis, is the most common ocular finding. It typically presents in the form of white retinal lesions infiltrating the inner retinal layers, located adjacent to retinal vessels, and varying in number, size, and location [Figure 1a and b]. Small

retinal lesions in the posterior fundus may resemble cotton-wool spots, and large retinal lesions are usually associated with macular edema and serous retinal detachment (SRD). Fluorescein angiography (FA) shows early hypofluorescence and late staining of large retinal lesions [Figure 1c and d] and slight hypofluorescence or isofluorescence of small retinal lesions.<sup>6,8</sup> Optical coherence tomography (OCT) demonstrates focal area of retinal thickening with hyperreflectivity extending from the retinal nerve fiber layer to the outer nuclear layer, and sparing the retinal pigment epithelium (RPE) and the choroid [Figure 1e and f].<sup>9</sup> OCT is also useful in the detection of associated macular edema and SRD. Retinal vascular lesions are a prominent feature of rickettsial disease.<sup>6,8</sup> They may include focal or diffuse vascular sheathing, vascular leakage on FA [Figure 1c and d], retinal hemorrhages, and retinal vascular occlusions, which mainly involve small branch retinal arteries.

OCT angiography (OCTA) [Figure 1g] allows detection and evaluation of occlusive complications associated with rickettsial retinitis.<sup>10</sup> A subclinical choroidal involvement only detectable by FA or indocyanine green angiography (ICGA) is also common.<sup>8</sup> Other reported ocular manifestations of rickettsiosis include conjunctivitis, keratitis, nongranulomatous anterior uveitis, panuveitis, optic disc edema, optic disc staining, optic neuritis, neuroretinitis, anterior ischemic optic neuropathy, and endophthalmitis.<sup>1-3,6-8,11</sup>

### *Laboratory diagnosis*

Diagnosis of rickettsial infection is usually suspected on the basis of clinical features (ocular and systemic) and epidemiologic data. It is confirmed by positive indirect immunofluorescent antibody test results. Positive serologic criteria usually include either initial high antibody titer or a fourfold rise of the titer in the convalescent serum. Case confirmation with serology might take 2–3 weeks. Other laboratory tests, such as serologic testing using Western blot or detection of rickettsiae in blood or tissue using polymerase chain reaction (PCR) may be useful in selected cases.<sup>12</sup>

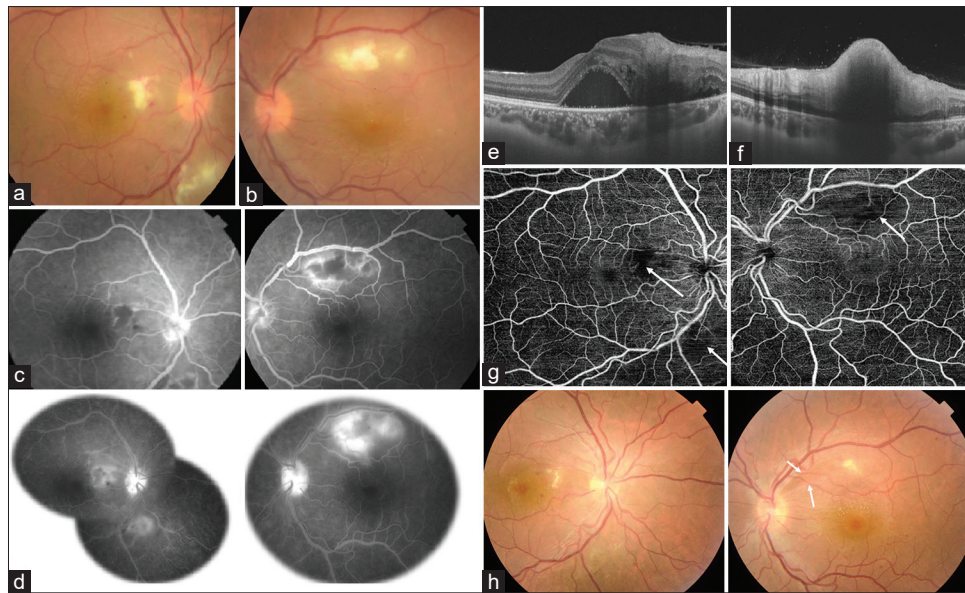
Ocular examination, revealing frequently abnormal, fairly typical findings is helpful in diagnosing a rickettsial disease, particularly in incomplete and atypical systemic presentation, while serologic testing is pending.<sup>12</sup>

### *Treatment*

Early treatment is required for a better outcome. Oral tetracyclines, particularly doxycycline (100 mg, twice a day for 7–10 days), are effective in the treatment of systemic rickettsial disease.<sup>1,12,13</sup> Fluoroquinolones are also effective. Macrolides, including clarithromycin, azithromycin, and particularly josamycin, can be used as alternative therapy in children and pregnant women. Corticosteroids may be required for severe ophthalmic involvement such as optic neuritis or retinal vasculitis.<sup>1-3,12-16</sup>

### *Visual prognosis*

Ophthalmic involvement in rickettsioses often has a self-limited course. Foci of retinitis usually disappear without causing



**Figure 1:** (a and b) Color fundus photograph of a patient with rickettsial disease shows large and small superficial white retinal lesions in both eyes. (c) Fluorescein angiography shows early hypofluorescence (d) and late staining of the retinal lesions with associated contiguous retinal vascular leakage and optic disc hyperfluorescence. (e) Swept source optical coherence tomography (OCT) section passing through the macula and the retinal lesion of the right eye demonstrates serous retinal detachment with retinal thickening and increased inner retinal reflectivity. (f) Swept source OCT section acquired through the retinal lesion of the left eye shows increased inner retinal reflectivity and retinal thickening with posterior shadowing and associated thickened posterior hyaloid and hyperreflective vitreous dots. (g) 9 mm × 9 mm swept source OCT angiography reveals well-delineated areas of flow deficit in the superficial capillary plexus corresponding to the retinal lesions (white arrows). (h) Color fundus photograph of the same patient 1 month after initial presentation showing a near complete resolution of the retinal lesions in both eyes with residual retinal nerve fiber layer defect demarcated by the white arrows. Small macular hard exudates become evident, mainly in the left eye

scarring in 3–10 weeks [Figure 1h]. Persistent decreased vision may occur in case of retinal changes secondary to macular edema or SRD, retinal artery or vein occlusion, foveal chorioretinal scar, or optic neuropathy.<sup>1-3,12-14,17,18</sup>

### West Nile virus infection

WNV infection is a zoonotic disease caused by a single-stranded ribonucleic acid (RNA) Flavivirus and transmitted to humans by a mosquito vector (type *Culex*), with wild birds serving as its reservoir.<sup>1-3</sup> The virus is the most widespread globally, first isolated in Africa, then, Europe, Australia, and Asia, and since 1999, it has spread rapidly throughout the Western hemisphere, including the United States, Canada, Mexico, and the Caribbean and into parts of Central and South America.<sup>19</sup> Recently, a co-circulation with Usutu virus, a neurotropic mosquito-borne Flavivirus, was noticed in Europe, giving WNV the potential of more spread to areas where only Usutu virus has been observed to date and conversely.<sup>20</sup>

### Systemic disease

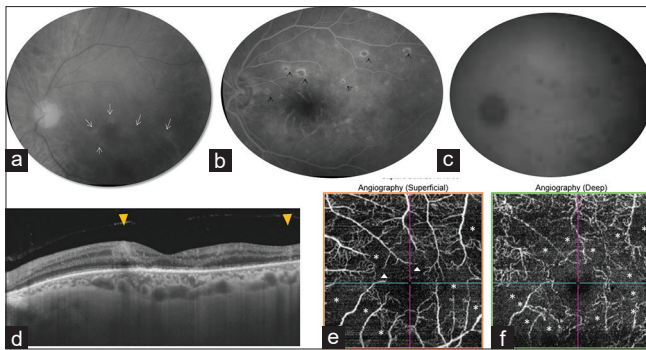
The incubation period for WNV infection ranges from 3 to 14 days. Human infections are often asymptomatic. Only approximately 20% of infected persons develop symptoms, with a self-limiting flu-like syndrome in most cases.<sup>6,7</sup> Severe neurologic disease may develop in <1% of cases.<sup>8</sup> WNV infection neurologic manifestations mainly include meningitis, encephalitis, and poliomyelitis-like disease. Findings in encephalitis and/or meningitis typically include a headache of rapid onset, photophobia, back pain, confusion,

and continued fever. Asymmetric paralysis of acute onset and absence of reflexes without pain are characteristic of WNV poliomyelitis-like syndrome.<sup>8</sup> Neuroinvasive disease is associated with high rates of morbidity and mortality, especially in patients with advanced age or diabetes.<sup>8</sup>

### Ocular disease

A typical bilateral or rarely unilateral multifocal chorioretinitis is the most common ocular manifestation of WNV infection, occurring in almost 80% of patients with acute WNV infection associated with neurologic illness.<sup>21,22</sup> Most patients have no ocular symptoms or present with mildly reduced vision or floaters. Active chorioretinal lesions present as circular, deep, yellowish lesions on ophthalmoscopy, with early hypofluorescence and late staining on FA.<sup>21</sup> Inactive chorioretinal lesions appear as round, atrophic lesions with or without central pigmentation [Figure 2], and they usually exhibit a typical “target-like appearance” on FA [Figure 2] with central hypofluorescence and peripheral hyperfluorescence.<sup>21</sup> Chorioretinal lesions vary in number and size, involving the midperiphery, with or without associated posterior pole involvement.<sup>21</sup> They are typically oriented radially in the nasal and peripheral fundus or arranged in a curvilinear pattern in the temporal posterior fundus.<sup>21</sup> The linear pattern of chorioretinitis appears to be related to the course of retinal nerve fibers.<sup>23</sup> OCT through lesions shows deep retinal location with focal disruption of the outer nuclear layer and RPE.<sup>24</sup>





**Figure 2:** Red free fundus photograph (a) of the left eye of a diabetic patient with West Nile virus infection shows patchy areas of ischemic retinal whitening with arteriolar narrowing and sheathing (arrows). Midphase fluorescein angiogram (b) of the left eye shows inactive multifocal chorioretinitis with a target-like appearance (arrowheads) and marked disruption of the perifoveal capillary arcade with enlarged and irregular foveal avascular zone and diffuse staining and leakage of perifoveal arterioles and venules. Late-phase indocyanine green angiograms (c) show multiple hypofluorescent choroidal spots. Macular section of swept-source optical coherence tomography (OCT) (d) shows paracentral focal hyperreflective lesions extending from the inner limiting membrane to the outer plexiform layer corresponding to the patchy areas of ischemic retinal whitening seen clinically (yellow triangle) and focal alterations of the outer retina. OCT angiograms show extensive well-delineated hypointense grayish areas of retinal capillary hypoperfusion (asterisks) and perifoveal capillary arcade disruption (white triangles) in the superficial capillary plexus (e) and larger grayish areas of capillary hypoperfusion (asterisks), capillary rarefaction, and diffuse capillary network attenuation and disorganization in the deep retinal capillary plexus, with a significant degree of projection artifact from the superficial vascular plexus (f)

ICGA shows well-delineated hypofluorescent choroidal spots with more lesions than those appreciated clinically or on FA.<sup>25</sup> Most patients with chorioretinitis are above 50 years in age and have diabetes mellitus, with a substantial proportion of them exhibiting associated diabetic retinopathy.<sup>26</sup>

Although multifocal chorioretinitis is the most common ocular manifestation of WNV infection, other manifestations have been described including nongranulomatous anterior uveitis, retinal hemorrhages, focal or diffuse retinal vascular sheathing, vascular leakage, occlusive vasculitis, zones of atrophy and mottling of RPE, macular edema, optic neuritis, and papilledema.<sup>1-3,21,22,27</sup>

OCTA allows the detection and precise delineation of areas of retinal capillary nonperfusion in both the superficial and deep capillary plexuses in case of associated occlusive retinal vasculitis.<sup>28</sup>

### Laboratory diagnosis

The diagnosis is confirmed by detection of IgM antibody in serum or cerebrospinal fluid.<sup>29</sup> Serological tests, however, can lead to cross reactivity with other Flavivirus or give false-negative results.<sup>30</sup> Thus, virus detection by PCR is becoming the gold standard for the diagnosis of WNV infection.<sup>29</sup>

### Treatment

There is, at present, no proven treatment for WNV infection. In cases of severe systemic disease, intensive supportive therapy is indicated.<sup>1-3,31</sup> Antiviral agents, such as ribavirin and interferon, were found to be active only *in vitro*.<sup>2</sup> Several clinical trials of interferon alpha-2b, interferon beta, and high-titer intravenous immunoglobulin will allow new and more effective therapeutic approaches to emerge in future.<sup>31,32</sup>

Specific ophthalmic treatments that may be required include topical steroids for anterior uveitis, peripheral retinal photocoagulation for neovascularization owing to occlusive vasculitis, pars plana vitrectomy for nonclearing vitreous hemorrhage or tractional retinal detachment, and intravitreal injection of antivascular endothelial growth factor agent for choroidal neovascularization or macular edema.<sup>33,34</sup>

No vaccination is available for WNV. However, research on mice and wild type mice showed a possible immunization against WNV nonstructural protein 1 which may reduce brain inflammation in a context of Toll-like receptor 3 signaling deficiency.<sup>5</sup>

### Visual prognosis

Ocular disease associated with WNV infection usually has a self-limited course, and visual acuity returns to baseline in most patients.<sup>21</sup> However, persistent visual loss may occur due to foveal chorioretinal scar, choroidal neovascularization, vitreous hemorrhage, tractional retinal detachment, severe ischemic maculopathy, optic atrophy, and retrogeniculate damage.<sup>1-3,21,22,26,35</sup> One case of reactivation of WNV infection-related chorioretinitis has been reported.<sup>36</sup>

### Dengue fever

DF is caused by any of four immunologically related serotypes of the Dengue virus, which belong to the genus *Flavivirus* of the family *Flaviviridae*. It is transmitted through the bite of an infected female *Aedes aegypti/albopictus* mosquito. *Aedes albopictus* vector seems to produce a slow-moving outbreak by contrast to the sharp epidemics associated with *Aedes aegypti*.<sup>37</sup>

DF is considered to be one of the most important arthropod-borne diseases in the tropical and subtropical regions, being endemic in more than 100 countries, including America, Southeast Asia, Western pacific, Africa, and The Eastern Mediterranean.<sup>38</sup>

### Systemic disease

The incubation period for DF varies from 3 to 14 days. The initial infection may be asymptomatic, may result in a nonspecific febrile illness, or may produce features of classic DF including sudden onset of high fever, severe headache, myalgias, arthralgias, nausea, vomiting, and a maculopapular rash. The majority of DF cases are self-limiting. A small proportion of affected patients may develop life-threatening Dengue hemorrhagic fever syndrome, which is characterized by increased capillary permeability and hemostatic disturbances, or Dengue shock syndrome, which is characterized by severe

systemic hypotension. DF is often associated with a bleeding tendency secondary to thrombocytopenia.<sup>37,39</sup>

### Ocular disease

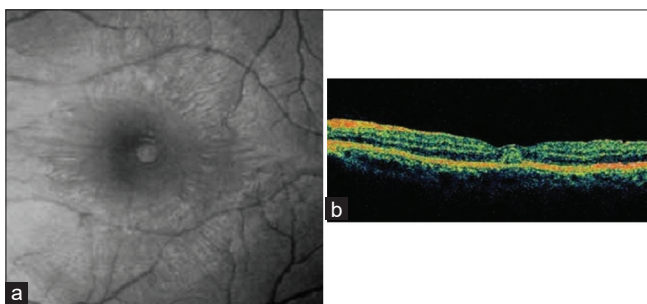
Ocular involvement, usually bilateral, is common in patients with DF<sup>1-3</sup> and results of thrombocytopenia, inflammatory, and ischemic mechanisms.<sup>40</sup> The patients may complain of a sudden decrease in vision, a central scotoma, or floaters. A subconjunctival hemorrhage, petechial in type and associated with a platelet count of  $<50,000/\mu\text{l}$  is common.<sup>2</sup> Numerous posterior segment changes can occur in association with DF including vitreous cells, retinal hemorrhages, retinal vascular sheathing, yellow subretinal dots, RPE mottling, foveolitis seen clinically as a round yellowish lesion at the fovea [Figure 3], choroidal changes, optic disc swelling, optic neuritis, and neuroretinitis.<sup>1-3,27,40,41</sup> Panophthalmitis and anterior segment manifestations including anterior uveitis and stromal keratitis are less common.<sup>42,43</sup>

The most common fluorescein angiographic findings include retinal vascular leakage and occlusion. ICGA shows hypofluorescent spots corresponding to the subretinal lesions seen clinically and additional spots in areas without clinically evident dots.<sup>40</sup> Large choroidal vasculopathy with hyperfluorescence and leakage is also common. OCT is useful in detecting and monitoring the dengue-induced inflammatory ischemic foveolitis and outer maculopathy (DIII-FOM).<sup>44,45</sup> OCT findings include the disruption of outer retinal layers and conical foveal elevation and focal outer neurosensory retina-RPE thickening corresponding to the round foveal yellowish lesion seen clinically. OCTA demonstrates ischemia of deep retinal capillary plexus (DCP).<sup>40</sup>

OCT is also useful in the detection and evaluation of SRD and macular edema. Although the visual prognosis is good in most patients, dengue-associated maculopathy and neuropathy may result in permanent visual impairment.<sup>44</sup>

### Laboratory diagnosis

The diagnosis of DF is based on the typical clinical presentation of and a positive serology for Dengue virus.<sup>1-3</sup> Serological tests include detection of Dengue virus nonstructural protein 1 and IgM/IgG antibodies.<sup>46</sup>



**Figure 3:** Red-free fundus photograph of the left eye (a) of a patient with Dengue fever shows a subretinal round, yellowish lesion at the fovea. Optical coherence tomography (b) through the lesion demonstrates conical foveal elevation with focal outer neurosensory retina-retinal pigment epithelium thickening (Courtesy, Soon Phaik Chee)

All available commercial tests have variable sensitivities for IgM and IgG screening with potential false positivity with IgG antibody. However, for the majority of the tests, nonstructural protein 1 screening had good agreement, especially tests for combined IgM antibody and nonstructural protein 1 detection.<sup>46</sup>

### Treatment

Treatment with topical, periocular, oral, intravenous steroids, and immune globulins has been attempted with variable success.<sup>47,48</sup> Deoxyribonucleic acid vaccine for DF is still in the research Phase I.<sup>49</sup>

### Visual prognosis

Ocular involvement in DF may be self-limiting.<sup>1-3</sup> However, vision-threatening ocular manifestations may occur including vasculitis, dengue maculopathy, and optic neuropathy. There have been no prospective randomized trials on therapy to date.

### Chikungunya

Chikungunya virus is a single-stranded RNA virus of the genus *Alphavirus* in the family *Togaviridae* transmitted to humans the bite of infected *Aedes aegypti* mosquito.<sup>1-3</sup> The virus has been associated with a massive pandemic that began in East Africa in 2004 and subsequently spread to India, Southeast Asia, and South America.<sup>1-3</sup>

### Systemic disease

The incubation period ranges from 1 day to 12 days, with an average of 2–4 days. Onset of the disease is abrupt and is characterized by high fever, severe arthralgia, and myalgia, along with headache and skin rash. Asymptomatic infections are rare (3%–25% of serologically proven infections).<sup>50</sup> The debilitating polyarthralgia is very characteristic of Chikungunya. Joint pain often disappears in few weeks but may persist for months or years in some patients.<sup>51,52</sup> Skin lesions may be seen in almost one half of the patients. A pruriginous maculopapular rash, lasting for 2–3 days, is the most common feature.<sup>51-53</sup> Rarely, severe infection associated with multiorgan failure, central neurological involvement, neonatal infection, and death occurs.<sup>51,52,54</sup>

### Ocular disease

Ocular symptoms usually occur after a latent period of a month to year; however, a few concurrent presentations have also been reported. Ocular involvement in Chikungunya is either unilateral or bilateral, affecting both the genders in all age groups, with anterior uveitis and retinitis being the most common ocular manifestations.<sup>1-3,55</sup>

Chikungunya retinitis or retinochoroiditis is usually accompanied by mild vitritis and present in the form of areas of retinal whitening in the posterior pole with surrounding retinal and macular edema. An associated occlusive vasculitis, accurately detected by FA, is also common.<sup>1-3,27,55,56</sup> OCT through retinal lesions demonstrates outer retinal disruption, mild RPE elevation, and thickening.<sup>57</sup> OCTA shows decrease in the superficial capillary plexus, DCP, and the choriocapillaris hyporeflective areas suggestive of flow deficit.<sup>57</sup>

Other posterior segment involvements include optic neuritis, neuroretinitis, central retinal artery occlusion, and exudative retinal detachment.<sup>41,42,48,58,59</sup> Although ocular manifestations typically have a benign clinical course, optic neuritis may result in permanent visual loss. Recently, recurrence in Chikungunya retinitis has been reported.<sup>60</sup>

### Laboratory diagnosis

The diagnosis is confirmed by the detection of IgM antibody in serum and/or by PCR.<sup>61,62</sup>

### Treatment

Some investigators treat confluent retinitis with intravenous/oral acyclovir and oral prednisolone, although there is no evidence in the literature to support the efficacy of acyclovir or other antiviral agents against Chikungunya.<sup>1-3</sup> Vaccines are still in the early developing stage.<sup>63</sup>

### Visual prognosis

Most patients recover well over a 10–12-week period, with a good visual outcome. Chronic arthralgia may indicate recurrence of the eye disease.<sup>60</sup>

### Rift valley fever

RVF is an arthropod-borne viral disease caused by *Bunyaviridae*. It is transmitted to humans through a bite by infected mosquitoes or through direct contact with infected animals. Several outbreaks have been reported in sub-Saharan and North Africa and more recently in the Arabian Peninsula.<sup>1-3</sup>

### Systemic disease

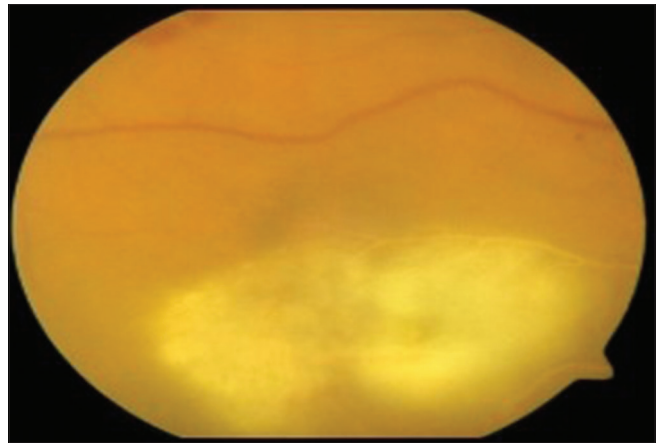
After an incubation period of 3–6 days, RVF virus is often responsible for influenza-like symptoms including fever, headache, arthralgias, myalgias, and gastrointestinal disturbances. The temperature curve usually shows a biphasic pattern, with an initial elevation lasting 2–3 days, followed by a remission and then a second febrile episode. Convalescence is typically rapid. Major life-threatening complications such as hepatic syndromes, hemorrhagic manifestations, or meningoencephalitis may rarely occur.<sup>64</sup>

### Ocular disease

Ocular involvement has been reported to occur in 1%–20% of RVF infections.<sup>1-3,65</sup> The mean interval between the onset of RVF and visual symptoms ranges from 4 to 15 days. Macular or paramacular retinitis is the most common finding [Figure 4]. Foci of retinitis show early hypofluorescence with late staining of retinal lesions and retinal vascular leakage on FA. Other posterior segment lesions include retinal hemorrhages, vitritis, optic disc edema, and retinal vasculitis.<sup>1,2,27,65</sup> Symptoms resolve spontaneously within 2–3 weeks from the onset of systemic symptoms, but permanent visual loss is common, resulting from macular and paramacular scarring, vascular occlusion, or optic atrophy.<sup>1-3,65</sup>

### Laboratory diagnosis

The diagnosis is confirmed by detection of IgM antibody in serum and/or by PCR.<sup>62,65</sup>



**Figure 4:** Fundus photograph of the right eye of a patient with Rift Valley fever shows an extensive necrotizing retinitis involving the macula associated with diffuse retinal vascular sheathing (Courtesy, Emad Abboud)

### Treatment

Treatment is entirely supportive. For mild-to-moderate cases of RVF, simple analgesia and fluids can be administered.<sup>1-3</sup> For patients who develop severe disease aggressive critical care including assisted ventilation and blood product transfusion is essential.<sup>1-3</sup> Vaccines are still in the early developing stage.<sup>66</sup>

### Visual prognosis

Previous studies showed that 40%–50% of patients have permanent vision loss and 70% of patients are legally blind. The most common cause of vision loss is foveal involvement.<sup>65</sup>

### Zika virus

Zika virus is an arbovirus in the Flavivirus family, transmitted by *Aedes aegypti* mosquito. It was first identified in Uganda in 1947. Then, the virus spread to Asian and Pacific countries. It has regained interest since 2015 as it was introduced in Brazil, reaching epidemic states with increased virulence and rapid dissemination.<sup>67,68</sup>

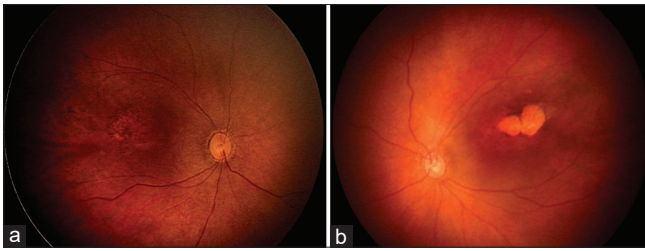
### Systemic disease

Acquired Zika virus infection is often asymptomatic or accompanied by mild flu-like symptoms. However, a few cases of neurological complications such as Guillain–Barre syndrome have been reported. Pregnant women who become infected with Zika virus may transmit the virus to their fetus. Congenital Zika virus infection can cause microcephaly, damage to the brain and/or eye, and central nervous system dysfunction.

### Ocular disease

Commonly, eye involvement includes among fetus and newborns chorioretinal atrophy, macular focal pigmentary, and optic nerve abnormalities [Figure 5]. The main OCT findings include discontinuation of the ellipsoid zone, hyperreflectivity underlying the RPE, retinal and choroidal thinning with colobomatous-like excavation involving the neurosensory retina, RPE, and choroid.<sup>69</sup> Ocular findings among adults are less frequent including conjunctivitis,





**Figure 5:** Fundus photographs of a newborn with congenital Zika virus syndrome show macular focal pigmentary alteration on the right eye (a) and macular chorioretinal atrophy on the left eye (b) (Courtesy, Rubens Belfort)

iridocyclitis, chorioretinitis, and unilateral acute idiopathic maculopathy.<sup>70</sup>

### Laboratory diagnosis

Several methods can be used for biological confirmation of the Zika virus infection.<sup>70</sup> The IgM and IgG antibodies identification has high rate of cross-reactivity with other Flaviviruses.<sup>57</sup> Besides, as the disease has a quick self-limited course, real-time PCR identifies the virus only in the first 7 days of infection.<sup>62,71</sup> The plaque reduction neutralization test for confirmation of positive IgM results is a more specific test.<sup>57</sup>

Subsequently, an accurate laboratory diagnosis, requires combining serologic data to molecular testing, as well as clinical and epidemiological criteria, especially for pregnant women and newborns.<sup>57</sup>

### Treatment

Zika virus infection runs self-limited course. There is still no approved specific antiviral drug for the treatment of Zika virus infections.<sup>72</sup>

### Visual prognosis

Zika virus infection may lead to severe visual impairment in newborns-related neurological involvement regardless of ocular damage.<sup>73</sup>

## DISCUSSION

In the present article, we reviewed the most recent available data in the literature, regarding ocular manifestations of arthropod vector-borne diseases that are relevant to ophthalmologist in every day clinical practice. Emerging arthropod vector-borne diseases may lead to significant morbidity, mortality, and visual threat of global dimensions.<sup>2</sup> They are caused by bacteria, viruses, and parasites transmitted by the bite of hematophagous arthropods, mainly ticks and mosquitoes. Most vector-borne diseases are subclinical or manifest as a mild febrile illness, but a severe, potentially lethal systemic involvement can occur. Among them, specific bacterial and viral arthropod vector-borne diseases including rickettsioses, WNV infection, RVF, DF, and Chikungunya have been associated with an array of ocular manifestations. These include anterior uveitis, retinitis, chorioretinitis, retinal vasculitis, and optic nerve involvement.<sup>1-5</sup> Congenital Zika infection has been

more recently associated with microcephaly and other central nervous system malformations and with cicatricial chorioretinal involvement that both may contribute to visual impairment.<sup>68,69</sup>

The pathogenesis of ocular involvement due to arthropod vector-borne diseases remains unclear, and it might result from direct effect of infectious agent and/or immune-mediated process. Arthropod vector-borne and zoonotic diseases should be considered in the differential diagnosis of intraocular inflammatory changes, especially in patients living or with recent travel to endemic countries.<sup>1,2</sup> Multimodal imaging was found to be useful in the detection and monitoring of posterior segment changes. It includes FA, OCT, autofluorescence, and OCTA. Although FA remains the gold standard in the evaluation of retinal vasculitis, OCTA was found to be a valuable tool for assessing occlusive retinal vasculitis associated with rickettsial disease or WNV infection.<sup>10,28</sup> The diagnosis is confirmed by the detection of specific antibody in serum or by PCR. Early clinical diagnosis, while laboratory testing is pending, is essential for proper management to prevent systemic and ocular morbidity.<sup>1-5</sup>

Ocular involvement associated with emergent infections usually has a self-limited course, but it can result in persistent severe visual impairment due to foveal retinitis or choroiditis, macular edema, SRD, retinal occlusive complications, optic neuropathy, or choroidal neovascularization.<sup>1-5</sup> Despite their health global burden, no proven antiviral treatment for the mainstay of these diseases is available. Nevertheless, supportive and symptomatic treatment should be conducted at early stages. Doxycycline is the drug of choice for the treatment of rickettsial diseases.<sup>2,5</sup> Topical corticosteroids can be used to treat anterior uveitis associated with arthropod vector-borne diseases.<sup>4</sup> However, the role of periocular, oral, or intravenous steroids in posterior segment involvement remains controversial.<sup>1-3,5</sup> Prevention remains the mainstay of infection control.<sup>2</sup> Public health measures including draining, standing water, and larvicides should be maintained to reduce the number of mosquitoes. Besides, personal protection against mosquito and tick bites including the use of repellants, window screens, and protective clothing is mandatory. Vaccination against the pathogen, a long-term solution, is still in the research phase.<sup>5</sup>

### Financial support and sponsorship

Nil.

### Conflicts of interest

There are no conflicts of interest.

## REFERENCES

1. Khairallah M, Jelliti B, Jenzeri S. Emergent infectious uveitis. Middle East Afr J Ophthalmol 2009;16:225-38.
2. Khairallah M, Yahia SB, Attia S. Arthropod vector-borne uveitis in the developing world. Int Ophthalmol Clin 2010;50:125-44.
3. Khairallah M, Chee SP, Rathinam SR, Attia S, Nadella V. Novel infectious agents causing uveitis. Int Ophthalmol 2010;30:465-83.
4. Khairallah M, Mahendradas P, Curi A, Khochtali S, Cunningham ET Jr. Emerging Viral Infections Causing Anterior Uveitis. Ocul Immunol Inflamm 2019;27:219-28.

5. Mahendradas P, Kawali A, Luthra S, Srinivasan S, Curi AL, Maheswari S, *et al.* Post-fever retinitis – Newer concepts. *Indian J Ophthalmol* 2020;68:1775-86.
6. Petersen LR, Marfin AA. West Nile virus: A primer for the clinician. *Ann Intern Med* 2002;137:173-9.
7. Garg S, Jampol LM. Systemic and intraocular manifestations of West Nile virus infection. *Surv Ophthalmol* 2005;50:3-13.
8. Gyure KA. West Nile virus infections. *J Neuropathol Exp Neurol* 2009;68:1053-60.
9. Bains HS, Jampol LM, Caughron MC, Parnell JR. Vitritis and chorioretinitis in a patient with West Nile virus infection. *Arch Ophthalmol* 2003;121:205-7.
10. Kahloun R, Jelliti B, Ksaa I, Ben Amor H, Zaouali S, Lupidi M, *et al.* Swept-source optical coherence tomography angiography in rickettsial retinitis. *Retin Cases Brief Rep* 2019;13:348-51.
11. Vandenbelt S, Shaikh S, Capone A Jr., Williams GA. Multifocal choroiditis associated with West Nile virus encephalitis. *Retina* 2003;23:97-9.
12. Khairallah M, Ladjimi A, Chakroun M, Messaoud R, Yahia SB, Zaouali S, *et al.* Posterior segment manifestations of Rickettsia conorii infection. *Ophthalmology* 2004;111:529-34.
13. Khairallah M, Ben Yahia S, Toumi A, Jelliti B, Loussaief C, Romdhane FB, *et al.* Ocular manifestations associated with murine typhus. *Br J Ophthalmol* 2009;93:938-42.
14. Khairallah M, Yahia SB, Jelliti B, Ben Romdhane F, Loussaief C, Attia S, *et al.* Diagnostic value of ocular examination in Mediterranean spotted fever. *Clin Microbiol Infect* 2009;15 Suppl 2:273-4.
15. de Groot-Mijnes JD, de Visser L, Zuurveen S, Martinus RA, Vrtin R, ten Dam-van Loon NH, *et al.* Identification of new pathogens in the intraocular fluid of patients with uveitis. *Am J Ophthalmol* 2010;150:628-36.
16. Visser N, Rothova A, de Groot-Mijnes JD, de Visser L. Searching for intraocular antibody production against Parvovirus B19, Mumps virus and Measles virus in patients with intermediate and posterior uveitis. *Br J Ophthalmol* 2009;93:841-2.
17. Agahan AL, Torres J, Fuentes-PPen G, Marttesm-Osorio H, Orduri A, Calonge M. Intraocular inflammation as the main manifestation of Rickettsia conorii infection. *Clin Ophthalmol* 2011;5:1401-7.
18. Kahloun R, Gargouri S, Abroug N, Sellami D, Ben Yahia S, Feki J, *et al.* Visual loss associated with rickettsial disease. *Ocul Immunol Inflamm* 2014;22:373-8.
19. Troupin A, Colpitts TM. Overview of West Nile virus transmission and epidemiology. *Methods Mol Biol* 2016;1435:15-8.
20. Zannoli S, Sambri V. West Nile virus and Usutu virus co-circulation in Europe: Epidemiology and implications. *Microorganisms* 2019;7:184.
21. Khairallah M, Ben Yahia S, Ladjimi A, Zeghidi H, Ben Romdhane F, Besbes L, *et al.* Chorioretinal involvement in patients with West Nile virus infection. *Ophthalmology* 2004;111:2065-70.
22. Chan CK, Limstrom SA, Tarasewicz DG, Lin SG. Ocular features of West Nile virus infection in North America: A study of 14 eyes. *Ophthalmology* 2006;113:1539-46.
23. Khairallah M, Ben Yahia S, Attia S, Zaouali S, Ladjimi A, Messaoud R. Linear pattern of West Nile virus-associated chorioretinitis is related to retinal nerve fibres organization. *Eye (Lond)* 2007;21:952-5.
24. Learned D, Nudleman E, Robinson J, Chang E, Stec L, Faia LJ, *et al.* Multimodal imaging of West Nile virus chorioretinitis. *Retina* 2014;34:2269-74.
25. Khairallah M, Ben Yahia S, Attia S, Zaouali S, Jelliti B, Jenzri S, *et al.* Indocyanine green angiographic features in multifocal chorioretinitis associated with West Nile virus infection. *Retina* 2006;26:358-9.
26. Khairallah M, Yahia SB, Letaief M, Attia S, Kahloun R, Jelliti B, *et al.* A prospective evaluation of factors associated with chorioretinitis in patients with West Nile virus infection. *Ocul Immunol Inflamm* 2007;15:435-9.
27. Khairallah M, Kahloun R. Ocular manifestations of emerging infectious diseases. *Curr Opin Ophthalmol* 2013;24:574-80.
28. Khairallah M, Kahloun R, Gargouri S, Jelliti B, Sellami D, Ben Yahia S, *et al.* Swept-source optical coherence tomography angiography in West Nile virus chorioretinitis and associated occlusive retinal vasculitis. *Ophthalmol Surg Lasers Imaging Retina* 2017;48:672-5.
29. Shukla J, Saxena D, Rathinam S, Lalitha P, Joseph CR, Sharma S, *et al.* Molecular detection and characterization of West Nile virus associated with multifocal retinitis in patients from southern India. *Int J Infect Dis* 2012;16:e53-9.
30. Kuno G. Serodiagnosis of flaviviral infections and vaccinations in humans. *Adv Virus Res* 2003;61:3-65.
31. Lazear HM, Pinto AK, Vogt MR, Gale M Jr., Diamond MS. Beta interferon controls West Nile virus infection and pathogenesis in mice. *J Virol* 2011;85:7186-94.
32. Ben-Nathan D, Gershoni-Yahalom O, Samina I, Khinich Y, Nur I, Laub O, *et al.* Using high titer West Nile intravenous immunoglobulin from selected Israeli donors for treatment of West Nile virus infection. *BMC Infect Dis* 2009;9:18.
33. Seth RK, Stoessel KM, Adelman RA. Choroidal neovascularization associated with West Nile virus chorioretinitis. *Semin Ophthalmol* 2007;22:81-4.
34. Afshar AR, Hariprasad SM, Jampol LM, Sheth VS. Use of intravitreal bevacizumab to treat macular edema in West Nile virus chorioretinitis. *Arch Ophthalmol* 2012;130:396-8.
35. Khairallah M, Ben Yahia S, Attia S, Jelliti B, Zaouali S, Ladjimi A. Severe ischemic maculopathy in a patient with West Nile virus infection. *Ophthalmic Surg Lasers Imaging* 2006;37:240-2.
36. Beardsley R, McCannel C. Reactivation West Nile virus infection-related chorioretinitis. *Semin Ophthalmol* 2012;27:43-5.
37. Halstead SB. Dengue. *Curr Opin Infect Dis* 2002;15:471-6.
38. World Health Organization. Dengue Haemorrhagic Fever: Diagnosis, Treatment, Prevention and Control. Geneva: World Health Organization; 1997.
39. Chan DP, Teoh SC, Tan C, Nah GK, Rajagopalan R, Prabhakaragupta MK, *et al.* Ophthalmic complications of dengue. *Emerg Infect Dis* 2006;12:285-9.
40. Loh BK, Bacsal K, Chee SP, Cheng BC, Wong D. Foveolitis associated with dengue Fever: A case series. *Ophthalmologica* 2008;222:317-20.
41. Tabbara K. Dengue retinochoroiditis. *Ann Saudi Med* 2012;32:530-3.
42. Bawankar P, Lahane T, Parekh R, Lahane S, Lahane S, Pathak P, *et al.* An unusual occurrence of stromal keratitis in dengue fever. *Indian J Ophthalmol* 2018;66:1631-3.
43. Kumar V, Deorari V, Swaroop S, Biswas A. Panophthalmitis in a patient with dengue fever. *BMJ Case Rep* 2019;12:e229588.
44. Teoh SC, Chee CK, Laude A, Goh KY, Barkham T, Ang BS, *et al.* Optical coherence tomography patterns as predictors of visual outcome in dengue-related maculopathy. *Retina* 2010;30:390-8.
45. Agarwal A, Aggarwal K, Dogra M, Kumar A, Akella M, Katoch D, *et al.* Dengue-induced inflammatory, ischemic foveolitis and outer maculopathy: A swept-source imaging evaluation. *Ophthalmol Retina* 2019;3:170-7.
46. Lee H, Ryu JH, Park HS, Park KH, Bae H, Yun S, *et al.* Comparison of six commercial diagnostic tests for the detection of dengue virus non-structural-1 antigen and IgM/IgG antibodies. *Ann Lab Med* 2019;39:566-71.
47. Bacsal KE, Chee SP, Cheng CL, Flores JV. Dengue-associated maculopathy. *Arch Ophthalmol* 2007;125:501-10.
48. Lim WK, Mathur R, Koh A, Yeoh R, Chee SP. Ocular manifestations of dengue fever. *Ophthalmology* 2004;111:2057-64.
49. Williams M, Ewing D, Blevins M, Sun P, Sundaram AK, Raviprakash KS, *et al.* Enhanced immunogenicity and protective efficacy of a tetravalent dengue DNA vaccine using electroporation and intradermal delivery. *Vaccine* 2019;37:4444-53.
50. Burt FJ, Rolph MS, Rulli NE, Mahalingam S, Heise MT. Chikungunya: A re-emerging virus. *Lancet* 2012;379:662-71.
51. Pialoux G, Gaaloux BA, Jauroux2mergi S, Strobel M. Chikungunya, an epidemic arbovirosis. *Lancet Infect Dis* 2007;7:319-27.
52. Chhabra M, Mittal V, Bhattacharya D, Rana U, Lal S. Chikungunya fever: A re-emerging viral infection. *Indian J Med Microbiol* 2008;26:5-12.
53. Brighton SW, Prozesky OW, de la Harpe AL. Chikungunya virus infection. A retrospective study of 107 cases. *S Afr Med J* 1983;63:313-5.
54. Sudeep AB, Parashar D. Chikungunya: An overview. *J Biosci* 2008;33:443-9.
55. Lalitha P, Rathinam S, Banushree K, Maheshkumar S, Vijayakumar R, Sathe P. Ocular involvement associated with an epidemic outbreak of



- Chikungunya virus infection. *Am J Ophthalmol* 2007;144:552-6.
56. Chanana B, Azad RV, Nair S. Bilateral macular choroiditis following Chikungunya virus infection. *Eye (Lond)* 2007;21:1020-1.
  57. Agarwal A, Choudhary T, Gupta V. Optical coherence tomography angiography features of bilateral retinopathy associated with Chikungunya fever. *Indian J Ophthalmol* 2018;66:142-5.
  58. Su DH, Bacsal K, Chee SP, Flores JV, Lim WK, Cheng BC, *et al.* Prevalence of dengue maculopathy in patients hospitalized for dengue fever. *Ophthalmology* 2007;114:1743-7.
  59. Arag: 1 RE, Barreira IM, Lima LN, Rabelo LP, Pereira FB. Bilateral optic neuritis after dengue viral infection: Case report. *Arq Bras Oftalmol* 2010;73:175-8.
  60. Salceanu SO, Raman V. Recurrent Chikungunya retinitis. *BMJ Case Rep* 2018;2018:bcr2017222864.
  61. Mahendradas P, Ranganna SK, Shetty R, Balu R, Narayana KM, Babu RB, *et al.* Ocular manifestations associated with Chikungunya. *Ophthalmology* 2008;115:287-91.
  62. Boga JA, Alvarez-Arguelles ME, Rojo-Alba S, RodraAlba M, de Oña M, Mel M S. Simultaneous detection of Dengue virus, Chikungunya virus, Zika virus, Yellow fever virus and West Nile virus. *J Virol Methods* 2019;268:53-5.
  63. Carrau L, Rezelj VV, Noval MG, Levi LI, Megrian D, Blanc H, *et al.* Chikungunya virus vaccine candidates with decreased mutational robustness are attenuated *in vivo* and have compromised transmissibility. *J Virol* 2019;93:e00775-19.
  64. Balkhy HH, Memish ZA. Rift Valley fever: An uninvited zoonosis in the Arabian peninsula. *Int J Antimicrob Agents* 2003;21:153-7.
  65. Al-Hazmi A, Al-Rajhi AA, Abboud EB, Ayoola EA, Al-Hazmi M, Saadi R, *et al.* Ocular complications of Rift Valley fever outbreak in Saudi Arabia. *Ophthalmology* 2005;112:313-8.
  66. Ma J, Chen R, Huang W, Nie J, Liu Q, Wang Y, *et al.* *In vitro* and *in vivo* efficacy of a Rift Valley fever virus vaccine based on pseudovirus. *Hum Vaccin Immunother* 2019;15:2286-94.
  67. Freitas AR, Angerami RN, von Zuben AP, Donalisio MR. Introduction and transmission of Zika virus in Brazil: New challenges for the Americas. *Rev Inst Med Trop Sao Paulo* 2016;58:24.
  68. Sikka V, Chattu VK, Popli RK, Galwankar SC, Kelkar D, Sawicki SG, *et al.* The emergence of Zika virus as a global health security threat: A review and a consensus statement of the INDUSEM Joint working Group (JWG). *J Glob Infect Dis* 2016;8:3-15.
  69. Ventura CV, Ventura LO, Bravo-Filho V, Martins TT, Berrocal AM, Gois AL, *et al.* Optical coherence tomography of retinal lesions in infants with congenital Zika syndrome. *JAMA Ophthalmol* 2016;134:1420-7.
  70. Parke DW 3<sup>rd</sup>, Almeida DR, Albini TA, Ventura CV, Berrocal AM, Mittra RA. Serologically confirmed Zika-related unilateral acute maculopathy in an adult. *Ophthalmology* 2016;123:2432-3.
  71. Cordeiro MT. Laboratory diagnosis of Zika virus. *Top Magn Reson Imaging* 2019;28:15-7.
  72. Baz M, Boivin G. Antiviral agents in development for Zika virus infections. *Pharmaceuticals (Basel)* 2019;12:101.
  73. Ventura CV, Ventura Filho MC, Ventura LO. Ocular manifestations and visual outcome in children with congenital Zika syndrome. *Top Magn Reson Imaging* 2019;28:23-7.