

## CASE REPORT

## Toxicology

# Potentially fatal ingestion of heat-not-burn cigarettes successfully treated by gastric lavage

Tetsuya Yumoto MD, PhD<sup>1,2</sup>  | Hisashi Hamaguchi MD<sup>1,3</sup> | Souichiro Mae MD<sup>1,4</sup> | Atsunori Nakao MD, PhD<sup>2</sup>

<sup>1</sup> Department of Emergency Medicine, Kasaoka Daiichi Hospital, Kasaoka, Okayama, Japan

<sup>2</sup> Department of Emergency, Critical Care, and Disaster Medicine, Okayama University Graduate School of Medicine, Dentistry, and Pharmaceutical Sciences, Kita, Okayama, Japan

<sup>3</sup> Department of Medical Education, Kurashiki Central Hospital, Kurashiki, Okayama, Japan

<sup>4</sup> Emergency and Critical Care Center, Kurashiki Central Hospital, Kurashiki, Okayama, Japan

**Correspondence**

Tetsuya Yumoto, MD, PhD, Department of Emergency, Critical Care, and Disaster Medicine, Okayama University Graduate School of Medicine, Dentistry, and Pharmaceutical Sciences, 2-5-1, Shikata-cho, Kita-ku, Okayama, 700-8558, Japan.

Email: [tyumoto@cc.okayama-u.ac.jp](mailto:tyumoto@cc.okayama-u.ac.jp)

**Funding and support:** By *JACEP Open* policy, all authors are required to disclose any and all commercial, financial, and other relationships in any way related to the subject of this article as per ICMJE conflict of interest guidelines (see [www.icmje.org](http://www.icmje.org)). The authors have stated that no such relationships exist.

**Abstract**

Newly introduced heat-not-burn or electronic cigarettes can cause lethal nicotine intoxication if ingested at higher doses. Although routine gastric lavage is not recommended, it should be considered if the amount of intoxicant is lethal. A 59-year-old man with a history of depression was brought to our emergency department after intentional ingestion of 8 heat-not-burn cigarettes, which were estimated to contain a total of 100 mg of nicotine. Abdominal computed tomography confirmed the gastric contents, detecting multiple stick-like and rod-shaped high-density structures. Gastric lavage was performed to minimize absorption of the potentially lethal nicotine dose. The patient exhibited only mild gastrointestinal symptoms. Emergency physicians should be aware of this novel heat-not-burn cigarette and its toxicity.

**KEYWORDS**

cigarette, computed tomography, gastric lavage, nicotine, suicide attempt, tobacco, toxicity

## 1 | INTRODUCTION

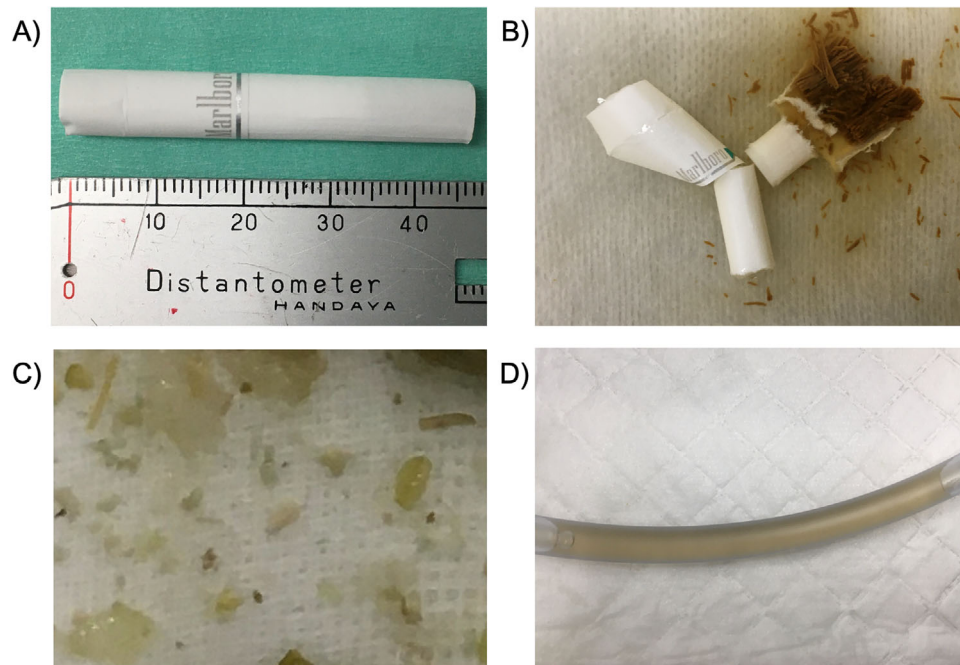
Heat-not-burn (HNB) cigarettes and electronic cigarettes or e-cigarettes have become widespread across the world as “safer” substitutes for conventional combustible cigarettes. Because these new heated cigarettes contain potentially harmful chemicals including nicotine, which can be life-threatening when ingested in high amounts, deliberate ingestion of e-cigarette products is sometimes seen in patients who attempt suicide or unintentional pediatric ingestion of

highly concentrated liquid nicotine.<sup>1</sup> Currently, gastric lavage is not routinely recommended<sup>2</sup>; however, it may be beneficial in specific circumstances to avoid absorption of toxic substances, including nicotine, from the gastrointestinal tract.<sup>3</sup> To date, clinical presentation and treatment regarding intentional ingestion of potentially fatal amounts of HNB cigarettes are lacking. Herein we describe a case of intentional ingestion of HNB cigarettes in which immediate computed tomography (CT) imaging guided us to perform gastric lavage, preventing potentially lethal nicotine intoxication. We believe our case provides additional valuable information concerning the management of nicotine intoxication after the intentional ingestion of novel HNB cigarettes.

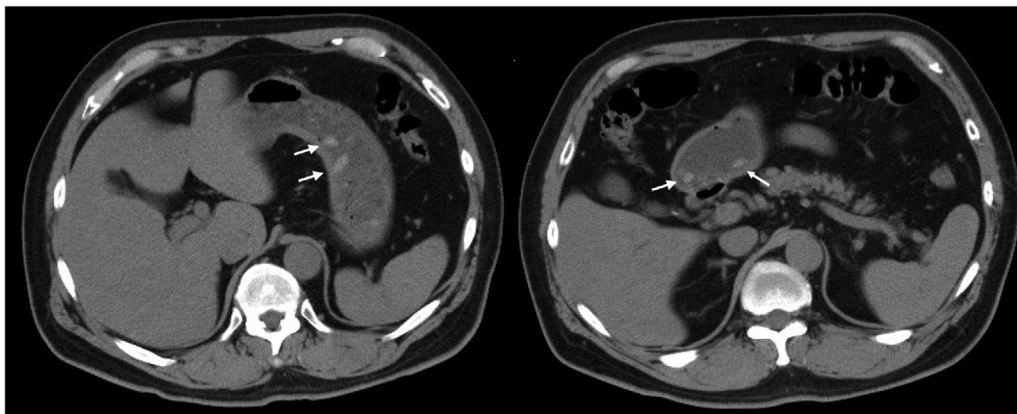
Supervising Editor: Sing-Yi Feng, MD.

This is an open access article under the terms of the [Creative Commons Attribution-NonCommercial-NoDerivs](https://creativecommons.org/licenses/by-nc-nd/4.0/) License, which permits use and distribution in any medium, provided the original work is properly cited, the use is non-commercial and no modifications or adaptations are made.

© 2020 The Authors. *JACEP Open* published by Wiley Periodicals LLC on behalf of the American College of Emergency Physicians.



**FIGURE 1** (A) The heat-not-burn cigarette the patient ingested. The unit of the ruler is centimeters. (B) Appearance of the heat-not-burn cigarette soaked in regular water for 10 minutes. Paper-wrapped tobacco leaves are exposed dissolving in the water. (C and D) Discharge mixed with leaf fragments and possible soggy outer layer of the cigarettes from the nasogastric tube



**FIGURE 2** Abdominal computed tomography demonstrating multiple stick-like and rod-shaped high-density structures in the stomach, which presumably represented heat-not-burn cigarette fragments (arrow). Mean Hounsfield units of the 4 structures marked were 65.5

## 2 | CASE PRESENTATION

A 59-year-old man with a 4-year history of depression was brought to our emergency department by an ambulance half an hour after deliberate ingestion of HNB cigarettes. The patient took several benzodiazepine pills at the same time. On hospital arrival, he was oriented but appeared lethargic. His vital signs were as follows: Glasgow Coma Scale score, 14 (E3V5M6); respiratory rate, 20 breaths/min; pulse rate, 67 beats/min; blood pressure, 139/79 mmHg; oxygen saturation, 97%; and temperature, 36.3°C. He denied any symptoms of nausea, vomiting, abdominal pain, or headache. The patient reported that he had swallowed 8 HNB cigarette sticks (Marlboro IQOS Heatstick Men-

thol) all at once (Figure 1A and 1B); however, the actual amounts were uncertain. We decided to perform abdominal CT to evaluate his gastric contents. Multiple stick-like and rod-shaped high-density structures, which were considered cigarette fragments, were detected in the stomach (Figure 2). Based on the lethal amount of nicotine that was potentially absorbable from the gut, gastric lavage was performed an hour after the ingestion. The patient was cooperative, and his airway was secured without warranting intubation during the procedure. A total of 2 L of water was administered through the nasogastric tube until tobacco leaves mixed with undigested food materials and the effluent had become clear (Figure 1C and 1D). We did not administer activated charcoal because of the absence of symptoms during the

initial management. The patient was carefully observed for 24 hours, during which he temporarily complained of nausea and vomiting. The gastrointestinal symptoms relieved within several hours, and he was otherwise asymptomatic. The patient was discharged the following day and referred to the psychiatric hospital, where he had been treated for depression.

### 3 | DISCUSSION

Our case report describes a successfully treated case of potentially lethal nicotine intoxication by gastric lavage after intentional ingestion of novel HNB cigarettes.

HNB cigarettes and e-cigarettes have been popular around the world because they are largely believed to be safer relative to traditional cigarettes. However, there is insufficient evidence to demonstrate that these cigarettes are less harmful than conventional cigarettes.<sup>4</sup> Surprisingly, acute intoxication attributed to nicotine overdose related to these products has been reported.<sup>5</sup> Generally, highly concentrated liquid nicotine or “e-liquid” that e-cigarettes aerosolize is much more hazardous because of its quick absorption.<sup>1</sup> However, ingestion of large amounts of HNB cigarettes can also be life-threatening because they contain as much nicotine as regular tobacco.<sup>6</sup> The total amount of nicotine our patient consumed was estimated as  $\approx 100$  mg (12.5 mg of nicotine per stick) according to data measured by an independent reviewers via the World Health Organization official method.<sup>7</sup> Although an HNB cigarette is almost half in length compared with conventional combustible cigarettes, it contains as much nicotine as the traditional cigarette. The fact that menthol, which is a commonly used flavoring agent in HNB cigarettes as in this case, inhibits the metabolism of nicotine might further increase the risk of lethal nicotine intoxication.<sup>8</sup> Currently, there is no accepted lethal dose of nicotine in adult humans. Traditionally, intake of 40 to 60 mg of oral nicotine or 5 cigarettes has been shown to be lethal; however, the actual lethal dose is implied to be much greater based on previous reports showing that the majority of patients who were potentially harmed were asymptomatic or presented with only mild symptoms.<sup>5</sup> Possible explanations include decrease of actual intake as a result of vomiting, difference in absorption rates between cigarette sticks and nicotine liquid, and the rapid metabolism of nicotine in the liver.<sup>1,9</sup> Nevertheless, the present case could have been fatal given a previously reported case of lethal acute nicotine intoxication attributed to the intentional ingestion of 9 regular cigarettes.<sup>9</sup>

Interestingly, abdominal CT imaging has been reported as a diagnostic modality to confirm recent overdose in comatose patients who had no exact evidence of overdose.<sup>10</sup> To the best of our knowledge, this is the first case where abdominal CT was performed soon after deliberate ingestion of a potentially lethal dose of HNB cigarettes, which was helpful to determine if gastric lavage was preferable. Presently, gastric lavage should be provided by experts to avoid complications and would be beneficial in cases of lethal ingestion and recent exposure to toxic substances to minimize absorption.<sup>2</sup> Based on abdominal CT imaging that had identified multiple cigarettes fragments, we performed gastric

lavage in the present case, which could have contributed to mild symptoms, including nausea and vomiting.

### 4 | CONCLUSIONS

Given the recent widespread use of HNB cigarettes, emergency physicians may encounter potentially fatal nicotine intoxication. Recognition of this novel cigarette and its toxicity should be warranted. Gastric lavage may be beneficial if performed promptly after ingestion.

### CONFLICTS OF INTEREST

The authors declare no conflict of interest.

### ORCID

Tetsuya Yumoto MD, PhD  <https://orcid.org/0000-0003-1766-8026>

### REFERENCES

1. Maessen GC, Wijnhoven AM, Neijzen RL, et al. Nicotine intoxication by e-cigarette liquids: a study of case reports and pathophysiology. *Clin Toxicol*. 2020;58(1):1-8.
2. Benson BE, Hoppu K, Troutman WG, et al. Position paper update: gastric lavage for gastrointestinal decontamination. *Clin Toxicol*. 2013;51(3):140-146.
3. Miyauchi M, Hayashida M, Hirata K, Hirata K, Yokota H. Gastric lavage guided by ultrathin transnasal esophagogastroduodenoscopy in a life-threatening case of tobacco extract poisoning: a case report. *J Nippon Med Sch*. 2013;80(4):307-311.
4. Centers for Disease Control. Heated tobacco products. [https://www.cdc.gov/tobacco/basic\\_information/heated-tobacco-products/index.html](https://www.cdc.gov/tobacco/basic_information/heated-tobacco-products/index.html). Published 2020. Accessed July 1, 2020.
5. Obertova N, Navratil T, Zak I, Zakharov S. Acute exposures to e-cigarettes and heat-not-burn products reported to the czech toxicological information centre over a 7-year period (2012-2018). *Basic Clin Pharmacol Toxicol*. 2020;127(1):39-46.
6. Simonavicius E, McNeill A, Shahab L, Brose LS. Heat-not-burn tobacco products: a systematic literature review. *Tob Control*. 2019;28(5):582-594.
7. Farsalinos KE, Yannovits N, Sarri T, Voudris V, Poulas K. Nicotine delivery to the aerosol of a heat-not-burn tobacco product: comparison with a tobacco cigarette and e-cigarettes. *Nicotine Tob Res*. 2018;20(8):1004-1009.
8. Kaur G, Muthumalage T, Rahman I. Mechanisms of toxicity and biomarkers of flavoring and flavor enhancing chemicals in emerging tobacco and non-tobacco products. *Toxicol Lett*. 2018;288:143-155.
9. Yamamoto H, Takayasu T, Ishida Y, et al. A case of complex suicide due to acute nicotine intoxication caused by cigarette ingestion. *Int J Legal Med*. 2020;134(3):997-1002.
10. Yanagawa Y, Nishi K, Imamura T, Sakamoto T. Sefulness of computed tomography in the diagnosis of an overdose. *Acta Med Okayama*. 2011;65(1):33-40.

**How to cite this article:** Yumoto T, Hamaguchi H, Mae S, Nakao A, Potentially fatal ingestion of heat-not-burn cigarettes successfully treated by gastric lavage. *JACEP Open*. 2020;1:1709-1711. <https://doi.org/10.1002/emp2.12283>