



Since January 2020 Elsevier has created a COVID-19 resource centre with free information in English and Mandarin on the novel coronavirus COVID-19. The COVID-19 resource centre is hosted on Elsevier Connect, the company's public news and information website.

Elsevier hereby grants permission to make all its COVID-19-related research that is available on the COVID-19 resource centre - including this research content - immediately available in PubMed Central and other publicly funded repositories, such as the WHO COVID database with rights for unrestricted research re-use and analyses in any form or by any means with acknowledgement of the original source. These permissions are granted for free by Elsevier for as long as the COVID-19 resource centre remains active.

Occupational dermatitis to facial personal protective equipment in health care workers: A systematic review



Jiade Yu, MD,^a Jennifer K. Chen, MD,^b Christen M. Mowad, MD,^c Margo Reeder, MD,^d Sara Hylwa, MD,^e Sarah Chisolm, MD,^f Cory A. Dunnick, MD,^{g,h} Ari M. Goldminz, MD,ⁱ Sharon E. Jacob, MD,^{j,k} Peggy A. Wu, MD, MPH,^l Jonathan Zippin, MD,^m and Amber Reck Atwater, MDⁿ
Boston, Massachusetts; Redwood City, Loma Linda, Riverside, and Sacramento, California; Danville, Pennsylvania; Madison, Wisconsin; Minneapolis, Minnesota; Decatur, Georgia; Aurora, Colorado; New York, New York; and Durham, North Carolina

Background: Prolonged wear of facial protective equipment can lead to occupational dermatoses.

Objective: To identify important causes of occupational dermatoses from facial protective equipment.

Methods: A systematic review following Preferred Reporting Items for Systematic Reviews and Meta-Analyses guidelines was performed using PubMed and Embase databases. Articles were included if they reported occupational dermatoses caused by surgical/procedure masks or N95 respirators, or both.

Results: We identified 344 articles, and 16 were suitable for inclusion in this review. Selected articles focused on facial occupational dermatoses in health care workers. Allergic contact dermatitis to the elastic straps, glue, and formaldehyde released from the mask fabric was reported. Irritant contact dermatitis was common on the cheeks and nasal bridge due to pressure and friction. Irritant dermatitis was associated with personal history of atopic dermatitis and prolonged mask wear (>6 hours). Acneiform eruption was reported due to prolonged wear and occlusion. Contact urticaria was rare.

Limitations: Only publications listed in PubMed or Embase were included. Most publications were case reports and retrospective studies.

Conclusion: This systematic review from members of the American Contact Dermatitis Society highlights cases of occupational dermatitis to facial protective equipment, including potential offending allergens. This work may help in the diagnosis and treatment of health care workers with facial occupational dermatitis. (J Am Acad Dermatol 2021;84:486-94.)

From the Department of Dermatology, Massachusetts General Hospital, Harvard Medical School, Boston^a; the Department of Dermatology, Stanford University School of Medicine, Redwood City^b; the Division of Dermatology, Geisinger Medical Center, Danville^c; the University of Wisconsin School of Medicine and Public Health, Madison^d; Departments of Dermatology, HealthPartners Institute, Hennepin Healthcare, and University of Minnesota, Minneapolis^e; the Department of Dermatology, Emory University, Grady Memorial Hospital, Regional Telehealth Service, and Veterans Affairs Veterans Integrated Service Network 7 Southeast Network, Decatur^f; the Department of Dermatology, University of Colorado Anschutz Medical Campus, Aurora^g; the Dermatology Service, Rocky Mountain Regional Veterans Affairs Medical Center, Aurora^h; the Department of Dermatology, Brigham and Women's Hospital, Harvard Medical School, Bostonⁱ; the Department of Dermatology, Loma Linda University^j; the Department of Medicine and Pediatrics, University of California, Riverside^k; the Department of Dermatology, University of California, Davis, Sacramento^l; the Department of Dermatology, Weill Cornell Medicine, New York^m; and Duke Dermatology, Duke University Medical Center, Durham.ⁿ

Funding sources: None.

Conflicts of interest: Dr Chisolm serves as a consultant for Kimberly-Clark. Dr Jacob is the founder and chief executive officer of the Dermatitis Academy and has consulted for L'Oréal and Johnson & Johnson. Drs Yu, Chen, Mowad, Reeder, Hylwa, Dunnick, Goldminz, Wu, Zippin, and Atwater have no conflicts of interest to declare.

IRB approval status: Reviewed and determined exempt by the Duke University Health System Institutional Review Board.

Accepted for publication September 23, 2020.

Reprints not available from the authors.

Correspondence to: Amber Reck Atwater, MD, Duke Contact Dermatitis and Patch Testing Center, 5324 McFarland Dr, #210, Durham, NC 27707. E-mail: atwat012@gmail.com.

Published online October 1, 2020.

0190-9622

© 2020 Published by Elsevier on behalf of the American Academy of Dermatology, Inc.

<https://doi.org/10.1016/j.jaad.2020.09.074>

Key words: acne; allergic contact dermatitis; contact dermatitis; contact urticaria; face mask; irritant contact dermatitis; mask; medical face mask; N95; N95 mask; N95 respirator; occupational dermatitis; occupational dermatoses; personal protective equipment; procedure mask; respirator; surgical mask; systematic review.

Personal protective equipment (PPE), including medical face masks, is essential to the safety of health care workers (HCWs). The 2 primary types of face masks are surgical/procedure masks and N95 respirators. Surgical/procedure masks (also referred to as medical face masks) are designed to block large-particle droplets and provide varying levels of protection based on the masks' materials. N95 respirators block at least 95% of 0.3- μ m test particles.

Prolonged PPE use has been shown to increase the risk of occupational dermatoses.¹ Occupational dermatitis consists of both irritant contact dermatitis (ICD) and allergic contact dermatitis (ACD), with 80% of cases due to ICD.² The objective of this study was to complete a systematic review of occupational dermatoses from medical face masks and N95 respirators in HCWs.

METHODS AND LITERATURE SEARCH

This systematic review was determined exempt by the Duke University Health System Institutional Review Board. We completed a review of occupational dermatoses from protective face masks adhering to Preferred Reporting Items for Systematic Reviews and Meta-Analyses guidelines.³ Articles were identified via both PubMed and Embase databases. PubMed was searched on April 9, 2020, with search terms: 1) contact dermatitis *and* face mask, surgical mask, respirator, N95, mask and 2) occupational dermatitis *and* face mask, surgical mask, respirator, N95, mask. A similar search was conducted in Embase on April 10, 2020, where we additionally used the Emtree term occupational eczema.

We identified 344 articles. After duplicates and those that did not meet inclusion criteria (Table 1) were removed, 29 publications were examined. Review of references identified 8 additional articles. Of 37 articles that were analyzed, 16 qualified for inclusion (Fig 1).

RESULTS

We identified 16 unique publications, categorized by publication type, level of evidence, type of

CAPSULE SUMMARY

- Personal facial protective equipment can lead to various dermatoses, especially during periods of increased and prolonged use.
- A systematic review of facial occupational dermatoses due to personal protective equipment revealed that allergic and irritant contact dermatitis are most common, followed by acneiform eruptions and contact urticaria.

facial PPE, and clinical characteristics (Table II).^{1,4-19}

DISCUSSION

This review of occupational dermatitis from medical face masks in HCWs identified several common skin concerns: adverse cutaneous reactions, ACD, ICD, acneiform eruptions, and contact urticaria. Our opinion is that skin reactions from facial PPE are most commonly due to ICD.

Adverse cutaneous reactions

Large studies of medical face mask-related cutaneous reactions are limited. We identified 3 studies that focused on facial PPE worn during coronavirus infections (severe acute respiratory syndrome and coronavirus disease 2019 [COVID-19]), although specific diagnoses were not provided.^{1,6,7} It is unusual for dermatology publications to include the terms "adverse cutaneous reaction" and "skin damage," but the surveys were likely administered to nondermatologists without a formal diagnosis. This may be unique to epidemic/pandemic populations.

Ascertaining diagnoses is difficult based on the description of papules, erythema, maceration, scale, desquamation, rash, and fissures; these terms suggest eczematous skin lesions, which include ACD and ICD. Symptoms of dryness, tightness, tenderness, pruritus, and burning/pain can also represent other potential diagnoses.

Mask-related areas of involvement in these studies included cheeks, nasal bridge, and forehead, and these could be potential areas of focus for preventative workplace strategies. HCWs at greater risk for adverse reactions during COVID-19 wore PPE >6 hours daily.^{6,7} Length of wear could be a potential workplace modification to assist HCWs experiencing mask-related adverse cutaneous reactions. Two studies of HCWs not in epidemics or pandemics described facial contact dermatitis⁹ and facial skin concerns, some of which may have been related to masks.¹² Whereas facial contact dermatitis typically refers to ACD or ICD, conceptualizing a diagnosis with the term "skin concern" is difficult. It would be

Abbreviations used:

ICD:	irritant contact dermatitis
ACD:	allergic contact dermatitis
HCWs:	health care workers
PPE:	personal protective equipment

advantageous if future studies on cutaneous face mask reactions included specific descriptive symptoms and signs.

Allergic contact dermatitis

ACD is a delayed type IV hypersensitivity reaction that can develop in response to allergens in the environment. Prolonged wear and exposure to PPE are risk factors for the development of ACD. We identified several sources of mask-associated ACD. The incomplete and sometimes absent disclosure of chemicals used in the manufacture of PPE makes identification and avoidance of relevant allergens difficult.

Rubber accelerators are used to accelerate the vulcanization of rubber and have been identified as allergens in mask elastic bands.^{10,15,19} Rubber antioxidants, such as N-isopropyl-N'-phenyl paraphenylenediamine, are also added during the vulcanization process and have been reported in mask-associated ACD.

Metal wires or rims are used in masks to mold the mask to the face. Nickel ACD has been described in mask-associated ACD, and nickel and cobalt have

Table I. Inclusion criteria

Inclusion criteria
English language
Surgical/procedure mask use
N95 respirator use
Occupational dermatitis in a health care worker

both been reported as suspected causes of ACD to protective equipment, including masks.^{5,10} Although metal wires are not likely to be in direct contact with the skin, prolonged or repeated wear, rubbing, and sweating can result in the release and transfer of the metal ions to the skin.

Adhesive chemicals are used in the construction of medical face masks and N95 respirators. A case report described ACD to methyl dibromo glutaronitrile in the adhesive material beneath the mask polyester foam strip.¹⁶ Methyl dibromo glutaronitrile is a preservative that is used in some adhesives.

Formaldehyde has been described as an allergen in N95 respirators.^{8,14} Formaldehyde is a preservative used in the production of resins, plastics, plywood, and paper products. In 1 case report, chemical evaluation of an N95 respirator identified formaldehyde, possibly a byproduct of polypropylene degradation during production of the mask.^{14,20-22} Other potential sources of undisclosed formaldehyde include its presence in raw materials or as a contaminant released from product packaging.^{23,24} Aside from the possible risk of

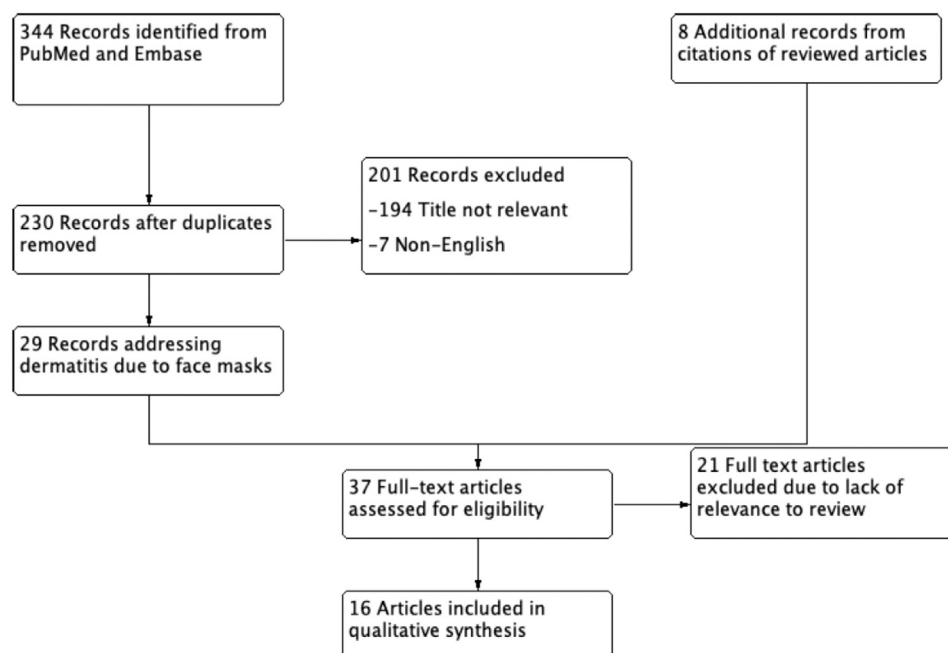


Fig 1. Review of process for inclusion of articles relevant to occupational dermatitis due to facial personal protective equipment in health care workers.

Table II. Unique publications identified

Publication	Study type	Level of evidence ^a	Exposure	Clinical description	Patch test results	Final diagnosis
A review of nonglove PPE-related occupational dermatoses reported to EPIDERM between 1993 and 2013 ⁵	Retrospective cohort	3	Face masks, safety glasses	13 cases of work-related dermatoses reported to EPIDERM in the United Kingdom were from face masks/safety glasses. 4-ACD, 1-ICD, 2-friction, 2-occlusion, 4-acne	Of the 4 cases of ACD to face masks: 2 caused by <i>N</i> -isopropyl- <i>N'</i> -phenyl paraphenylenediamine 1 caused by nickel 1 unknown (details NR)	Allergic contact dermatitis Irritant contact dermatitis Acne
Adverse skin reactions among HCWs during the COVID-2019 outbreak: a survey in Wuhan and its surrounding regions ⁶	Cross-sectional survey	4	N95 respirator, surgical masks, double gloves	280/376 (74.5%) of HCW in Wuhan, China, and surrounding regions during COVID-19 had adverse skin reaction: hands > cheeks > nasal bridge. Most common reactions dryness or scale > papules or erythema > maceration. More severely affected regions/hospitals had more cases likely due to longer hours and stringent PPE requirements. >6 hours of PPE had statistically significant increase in adverse skin reactions.	None	Adverse skin reactions were common. Dermatologic diagnoses were not specified.
Skin damage among HCW managing COVID-19 ⁷	Cross-sectional survey	4	Goggles, N95 respirator	526/542 (97%) HCWs in COVID-19 pandemic in Hubei, China, reported skin damage. Nasal bridge was most commonly affected area (83.1%); also hands, cheeks, forehead. 70.3% reported dryness and tightness; 61.6% desquamation. >6 hours of PPE wear increased risk of skin damage.	None	Skin damage. Specific dermatologic diagnosis was not discussed.

Continued

Table II. Cont'd

Publication	Study type	Level of evidence ^a	Exposure	Clinical description	Patch test results	Final diagnosis
Adverse skin reactions to PPE against SARS—a descriptive study in Singapore ¹	Cross-sectional survey	4	N95 respirator, surgical & paper masks; gloves; gowns	340 HCWs in 2003 SARS epidemic, Singapore. N95 worn on average 8 h/d. N95 respirators: 109/307 (35.5%) had adverse skin reactions: acne (59.6%), facial itch (51.4%), rash (35.8%). Surgical and paper masks: no skin reactions.	None	Adverse skin reaction to N95 respirator in 35.5%: acne, facial itch, rash.
Skin reactions after use of N95 facial masks ⁸	Case series (abstract)	4	N95 respirator	13 referrals for possible N95 face mask allergy during 2002 SARS epidemic. 5 patients with facial dermatitis, 3 patients with facial urticaria, 2 patients with acute respiratory complaints and no skin changes.	8 patients completed patch testing, 6 were negative. 2 patients had positive patch test reactions to quaternium-15 and ethylene urea melamine. One of those 2 patients also tested positive for formaldehyde [†]	Majority of N95 respirator reactions are ICD. 3 cases of contact urticaria. 2 cases of ACD.
Self-report of occupational-related contact dermatitis: prevalence and risk factors among HCWs in Gondar town, Northwest Ethiopia, 2018, a cross-sectional study ⁹	Cross sectional survey	4	Gloves, "PPE," not otherwise described	133/422 (31.5%) of HCWs self-reported work-related contact dermatitis in the previous 12 months. 19/422 (5%) reported facial contact dermatitis.	None	Occupational contact dermatitis, type not specified.
Safety equipment: when protection becomes a problem ¹⁰	Cross-sectional study	4	Safety equipment (masks and respirators)	88/38533 (0.2%) NACDG patients (2001-2017) had ACD or ICD to safety equipment. 30% were HCWs. Common sites of skin disease were face (28%), hands (17%), arms (13%).	Most common positive patch test reactions: carba mix, 25.3%; thiuram mix, 22.9%; mixed dialkyl thioureas, 10.8%; nickel sulfate, 8.4%; <i>p</i> -phenylenediamine, 4.8%.	Safety equipment (eg, masks and respirators) is associated with ACD (77%), ICD (28.7%), or both (11.3%). Unknown whether facial dermatitis cases were due to masks.

Occupational skin diseases among dental nurses ¹¹	Cross-sectional survey	4	Gloves, paper mask	56/799 (7%) female dental nurses in Finland had facial dermatitis related to dental occupation. History of atopy was significantly associated with facial dermatitis ($P < .001$)	Patch testing completed; no ACD identified in patients with facial dermatitis.	Paper face mask was the most commonly reported source of facial dermatitis and caused "slight skin irritation."
Occupational health problems among dental hygienists ¹²	Cross-sectional survey	4	Dental mask	70/189 (37%) of occupational dermatoses in dental hygienists were skin related. 5/70 had skin-related occupational dermatitis due to face masks	None	Facial dermatitis. Mentions residual formaldehyde causing problems. Some reactions were general allergy or atopy or were not specified
The dental face mask—the most common cause of work-related face dermatitis in dental nurses ¹³	Case report	5	Dental mask	28-year-old female dental nurse with facial & hand dermatitis.	1+ nickel and cobalt. Mask contained only aluminum via analysis.	ICD from dental mask in setting of atopic diathesis.
Allergic contact dermatitis from formaldehyde textile resins in surgical uniforms and nonwoven textile masks ¹⁴	Case report	5	N95 respirator, scrubs, disposable paper gown	49-year-old female physician with recurrent generalized dermatitis during 2003 SARS epidemic. Pruritic eruption of face, neck, flexures, trunk, legs.	2+ melamine formaldehyde; 1+ urea formaldehyde; 1+ ethyleneurea melamine/formaldehyde mix; 2+ quaternium-15; 1+ toluene sulfonamide formaldehyde resin; 1+ imidazolidinyl urea; 1+ formaldehyde 1%; 1+ MCI/MI Negative patch test to N95 respirator, scrubs, paper gown, but chemical analysis revealed presence of formaldehyde in N95 respirator and scrubs.	ACD to formaldehyde in N95 respirator and scrubs.
Occupational allergic contact dermatitis in an obstetrics and gynecology resident ¹⁵	Case report	5	Surgical mask, surgical cap	30-year-old female resident physician with intermittent pruritic eruption on cheeks, eyelids, forehead.	2+ thiuram; 3+ nickel sulfate; 3+ cobalt; 3+ gold sodium thiosulfate.	ACD to thiuram in elastic of surgical mask and surgical cap.

Continued

Table II. Cont'd

Publication	Study type	Level of evidence ^a	Exposure	Clinical description	Patch test results	Final diagnosis
Surgical mask contact dermatitis and epidemiology of contact dermatitis in HCW ¹⁶	Case report and review	5	Surgical mask	32-year-old male scrub nurse with intermittent erythematous scaly pruritic rash on face and eyelids.	1+ carba mix; 2+ dibromodicyanobutane (methyl dibromoglutaronitrile); 2+ foam strip from mask.	ACD to dibromodicyanobutane in adhesive used to attach foam strip to textile of surgical mask.
N95 acne ¹⁷	Case report	5	N95 respirator	2 cases of female health assistants (ages 27 and 45) in Singapore during 2003 SARS epidemic; acneiform eruptions on areas of face covered by N95 respirator. 3 months of N95 wear in hospital.	None	Acneiform eruptions from N95 respirators. Eruptions cleared with topical retinoid and systemic antimicrobials.
Allergic contact dermatitis to face masks in dental clinic: case reports ¹⁸	Case reports (abstract)	5	Dental face mask	45-year-old female dentist with erythema, pruritus, edema on perioral face & anterior neck	"Standard patch test" negative (type NR).	Facial contact dermatitis from dental face mask.
			Dental face mask	28-year-old female dental resident with burning, edema, erythema & vesicles lips & chin	"Standard patch test" negative (type NR).	Facial contact dermatitis from dental face mask
Allergic contact dermatitis in dental professionals: effective diagnosis and treatment ¹⁹	Case report	5	Dental mask	48-year-old female orthodontic assistant with hand dermatitis and red itchy areas on face.	1+ carba mix; 1+ quaternium-15; 1+ thiuram mix; 1+ glutaraldehyde; 1+ thimerosal; 1+ MCI/MI	ACD to rubber accelerators (carba mix, thiuram mix) present in dental mask strap, rubber gloves.

ACD, Allergic contact dermatitis; *carba mix*, diphenylguanidine, zinc dibutylthiocarbamate, and zinc diethylthiocarbamate; COVID, coronavirus disease 2019; HCW, health care worker; ICD, irritant contact dermatitis; MCI, methylchloroisothiazolinone; NR, not reported; MI, methylisothiazolinone; PPE, personal protective equipment; SARS, severe acute respiratory syndrome; *thiuram mix*, tetramethylthiuram monosulfide, tetraethylthiuram disulfide, tetramethylthiuram disulfide, and dipentamethylenethiuram disulfide.

*Key for determination of level of evidence⁴: 1 = properly powered and conducted randomized clinical trial; systematic review with meta-analysis. 2 = well-designed controlled trial without randomization; prospective comparative cohort trial. 3 = case-control studies; retrospective cohort study. 4 = case series with or without intervention; cross-sectional study. 5 = opinion of respected authorities; case reports.

[†]One patient was likely duplicate of this case report: Allergic contact dermatitis from formaldehyde textile resins in surgical uniforms and nonwoven textile masks.

formaldehyde release from polypropylene degradation, polypropylene itself poses a low risk of ACD.

Irritant contact dermatitis

ICD, the most common form of occupational skin disease, results from cytotoxic injury due to direct contact with chemicals or physical irritants. ICD severity is dependent on the irritant and chronicity of the exposure and presents clinically as erythema, scaling, edema, and vesicles along with ulcerations and fissures at the area of contact. Reported symptoms often include stinging or burning rather than pruritus. Those with a history of atopy are more susceptible to irritants because they have skin barrier defects.²⁵ Because ICD is commonly a diagnosis of exclusion and the clinical features of ICD and ACD can overlap, patch testing is needed to differentiate between them.

The hands are the most commonly reported site of occupationally related ICD in HCWs. The reports of cutaneous reactions during pandemics highlight involvement of the cheeks and nasal bridge, which is mainly due to face mask exposure. The studies in our review cite prolonged use of the mask as an added risk factor.^{6,7}

Acneiform eruption and contact urticaria

Acne has been reported in HCWs wearing face masks for prolonged periods of time, likely due to rubbing (acne mechanica) or occlusion. Patients with acne had a history of acne in 1 case series. Contact urticaria is rarely reported, and case details were not available in the literature.

Limitations

Our review has some inherent limitations. Our search was limited to 2 major databases, PubMed and Embase. The published literature included mostly case reports and case series, with few cross-sectional surveys and only 1 retrospective cohort study. This limits the generalizability of our conclusions.

CONCLUSIONS

This review describes causes of occupational dermatitis from protective face masks. Given the large numbers of HCWs wearing protective face masks, we predict that there will be an increasing incidence of face mask-related occupational dermatitis. Well-designed studies are necessary to better understand incidence and opportunities for management of mask-related occupational dermatitis.

REFERENCES

1. Foo CCI, Goon ATJ, Leow Y-H, Goh C-L. Adverse skin reactions to personal protective equipment against severe acute

- respiratory syndrome—a descriptive study in Singapore. *Contact Dermatitis*. 2006;55(5):291-294.
2. Sasseville D. Occupational contact dermatitis. *Allergy Asthma Clin Immunol*. 2008;4(2):59-65.
3. Moher D, Liberati A, Tetzlaff J, Altman D, PRISMA Group. Preferred reporting items for systematic reviews and meta-analyses: the PRISMA statement. *Ann Intern Med*. 2009;151(4):264-269.
4. Instructions for Authors. *JAMA Dermatology*. <https://jamanetwork.com/journals/jamadermatology/pages/instructions-for-authors>. Accessed April 16, 2020.
5. Bhojru B, Lecamwasam K, Wilkinson M, et al. A review of non-glove personal protective equipment-related occupational dermatoses reported to EPIDERM between 1993 and 2013. *Contact Dermatitis*. 2019;80(4):217-221.
6. Lin P, Zhu S, Huang Y, et al. Adverse skin reactions among healthcare workers during the coronavirus disease 2019 outbreak: a survey in Wuhan and its surrounding regions. *Br J Dermatol*. 2020;183(1):190-192.
7. Lan J, Song Z, Miao X, et al. Skin damage among health care workers managing coronavirus disease-2019. *J Am Acad Dermatol*. 2020;82(5):1215-1216.
8. Donovan J, Kudla I, Holness LD, Skotnicki-Grant S, Nethercott JR. Skin reactions following use of N95 facial masks. *Dermatitis*. 2007;18(2):104.
9. Mekonnen TH, Yenealem DG, Tolosa BM. Self-report occupational-related contact dermatitis: prevalence and risk factors among healthcare workers in Gondar town, Northwest Ethiopia, 2018—a cross-sectional study. *Environ Health Prev Med*. 2019;24(1):11.
10. Warshaw EM, Schlarbaum JP, Silverberg JI, et al. Safety equipment: when protection becomes a problem. *Contact Dermatitis*. 2019;81(2):130-132.
11. Alanko K, Susitaival P, Jolanki R, Kanerva L. Occupational skin diseases among dental nurses. *Contact Dermatitis*. 2004;50(2):77-82.
12. Jacobsen N, Hensten-Pettersen A. Occupational health problems among dental hygienists. *Community Dent Oral Epidemiol*. 1995;23(3):177-181.
13. Kanerva L, Alanko K, Jolanki R, Kanervo K, Susitaival P, Estlander T. The dental face mask—the most common cause of work-related face dermatitis in dental nurses. *Contact Dermatitis*. 2001;44(4):261-262.
14. Donovan J, Skotnicki-Grant S. Allergic contact dermatitis from formaldehyde textile resins in surgical uniforms and nonwoven textile masks. *Dermatitis*. 2007;18(1):40-44.
15. Kosann M, Brancaccio R, Cohen D. Occupational allergic contact dermatitis in an obstetrics and gynecology resident. *Am J Contact Dermat*. 2003;14(4):217-218.
16. Al Badri F. Surgical mask contact dermatitis and epidemiology of contact dermatitis. *Curr Allergy Clin Immunol*. 2017;30(3):183-188.
17. Tan KT, Greaves MW. N95 acne. *Int J Dermatol*. 2004;43(7):522-523.
18. Stroici C, Brzezinski P, Chiriac A, Bujor A. Allergic contact dermatitis to face masks in dental clinic: case reports. *Eur J Allergy Clin Immunol*. 2014;69(99):426.
19. Hamann CP, Rodgers PA, Sullivan K. Allergic contact dermatitis in dental professionals: effective diagnosis and treatment. *J Am Dent Assoc*. 2003;134(2):185-194.
20. Hamburger R, Azaz E, Donbrow M. Autoxidation of polyoxyethylene non-ionic surfactants and of polyethylene glycols. *Pharm Acta Helv*. 1975;50(1-2):10-17.
21. Rieger M. Peroxides in polyethylene glycols and polyethylene glycol derivatives. *Cosmet Perfum*. 1975;90:12-16.

22. Bergh M, Magnusson K, Nilsson JL, Karlberg AT. Contact allergenic activity of Tween 80 before and after air exposure. *Contact Dermatitis*. 1997;37(1):9-18.
23. Nikle AB, Liou YL, Ericson ME, Warshaw EM. Formaldehyde release from clothing and upholstery fabrics using the chromotropic acid method. *Dermatitis*. 2019;30(4):255-258.
24. Fregert S. Contamination of chemico-technical preparations with formaldehyde from packages. *Contact Dermatitis*. 1977;3(2):109-110.
25. Visser M, Landeck L, Campbell L, et al. Impact of atopic dermatitis and loss-of-function mutations in the filaggrin gene on the development of occupational irritant contact dermatitis. *Br J Dermatol*. 2013;168(2):326-332.