

Use of selexipag in a teenage patient with pulmonary arterial hypertension

Nathalie Jeanne Magioli Bravo-Valenzuela^{1,2}, Flavia Navarro³, Socrates Pereira Silva²

¹Department of Pediatrics, Federal University of Rio de Janeiro, Rio de Janeiro, RJ, Brazil, ²PEDICOR-Pediatric and Perinatal Cardiology Center, Sao José dos Campos, SP, Brazil, ³Pulmonary Hypertension Center, Faculty of Medical Sciences, Santa Casa de Sao Paulo, Sao Paulo, SP, Brazil,

ABSTRACT

Pulmonary arterial hypertension (PAH) is a chronic, progressive, multifactorial disease. Currently, combination therapy is an attractive option for PAH management because three pathways (endothelin, nitric oxide, and prostacyclin) are involved in this disease. Selexipag is a novel oral prostacyclin pathway drug and is a highly selective IP prostacyclin receptor agonist with vasodilatory and antiproliferative effects. We report the case of a teenage patient with idiopathic PAH who presented in World Health Organization functional Class IV and showed no clinical improvement with dual therapy. We added oral selexipag to the treatment regimen and observed substantial improvement in her quality of life at the short-time follow-up. Despite the lack of childhood data regarding the use of selexipag in pediatric patients with PAH, the use of this drug in the current teenage patient improved her quality of life and exercise capacity.

Keywords: Children, prostacyclin, pulmonary arterial hypertension, selexipag

INTRODUCTION

Pulmonary arterial hypertension (PAH) is a chronic and progressive disease. In Europe, the estimated annual incidence of PAH is 5–10 cases per million adults.^[1,2] PAH may be underdiagnosed and underreported because of the nonspecific presentation that makes accurate diagnosis challenging.^[3]

Moreover, as knowledge of PAH increases, there is a better understanding of what treatment goals or outcomes are associated with improvement in survival, and how these might be achieved through combination therapy.^[3] The endothelin, nitric oxide (NO), and prostacyclin pathways are involved in PAH, and current recommendations support the use of combined therapies that target each of these pathways. Consequently, the use of drugs with different mechanisms of action, preferably oral drugs that are more convenient for the patient, is believed

to be the optimal approach. The European Society of Cardiology and the European Respiratory Society guidelines recommend that low- or intermediate-risk PAH patients with World Health Organization (WHO) functional Class (FC) II–III can be treated with either initial monotherapy or initial oral combination therapy. High-risk patients (WHO FC IV) should begin initial combination therapy including medications action on the prostacyclin pathway.^[4]

Although prostacyclin therapy is recommended in patients with severe PAH, >30% of the patients with WHO FC IV are not prescribed the same. Furthermore, 44.1% of the patients who died because of PAH were not using prostacyclin therapy. Moreover, parenteral and inhaled prostacyclins present limitations in terms of the quality of life as well as risks concerning catheters or

This is an open access journal, and articles are distributed under the terms of the Creative Commons Attribution-NonCommercial-ShareAlike 4.0 License, which allows others to remix, tweak, and build upon the work non-commercially, as long as appropriate credit is given and the new creations are licensed under the identical terms.

For reprints contact: WKHLRPMedknow_reprints@wolterskluwer.com

How to cite this article: Bravo-Valenzuela NJ, Navarro F, Silva SP. Use of selexipag in a teenage patient with pulmonary arterial hypertension. *Ann Pediatr Card* 2021;14:75-8.

Access this article online

Quick Response Code:



Website:

www.annalspc.com

DOI:

10.4103/apc.APC_63_19

Address for correspondence: Prof. Nathalie Jeanne Magioli Bravo-Valenzuela, Av. Andromeda, 693, s. 601-603, Zip Code: 12230-000, São José dos Campos- SP, Brazil. E-mail: njmbravo@cardiol.br

Submitted: 29-Apr-2019 Revised: 24-Oct-2019 Accepted: 08-Jul-2020 Published: 23-Sep-2020

infusion pump. Selexipag is an orally bioavailable form of prostacyclin therapy. This drug is a highly selective IP prostacyclin receptor agonist that exerts vasodilatory and antiproliferative effects.^[5,6]

Here, we report the use of selexipag in a 15-year-old girl with idiopathic PAH; the treatment resulted in substantial improvement in her quality of life and exercise capacity.

CASE REPORT

A 15-year-old girl (weight 50 kg; body surface area 1.45 m²) was diagnosed with idiopathic PAH with clinical deterioration and signs of disease progression. Initial right cardiac catheterization demonstrated a mean pulmonary artery pressure of 60 mmHg and pulmonary artery systolic pressure (PASP) of 80 mmHg, with a systolic aortic pressure of 68 mmHg. The pulmonary vascular resistance index (PVRI) to body surface area was 15.9 Wood units.m², the cardiac index was 385 l/m/m², and the right atrial pressure was 11 mmHg with no response to NO. Initially, a drug combination of sildenafil 60 mg/day, bosentan 125 mg/day (bid), and anticoagulant (warfarin) was used and achieved a good response. The patient’s WHO FC improved from class III to II, the six-minute walk test (6-MWT) distance increased from 266 m to 358 m, echo parameteres showed a decrease in the PASP from 88 mmHg to 54 mmHg and the B-type natriuretic peptide decreased from 150 to 100 ng/L. Cardiac catheterization was not performed. Six years thereafter, the 6-MW and echocardiographic parameters gradually worsened. The 6-MW distance decreased from 358 m to 165 m (i.e., reduced by >15%, as confirmed by two tests performed on different days in a period of 2 weeks). Transthoracic echocardiography showed the following results: PASP = 104.8 mmHg (estimated with the tricuspid regurgitation plus right atrial pressure of 10 mmHg), right atrial area = 19 cm², main pulmonary artery diameter = 3.3 cm, crescent-shaped left ventricle (LV), tricuspid annular plane systolic excursion (TAPSE) = 1.5 cm, and no pericardial effusion. Cardiac catheterization was repeated and demonstrated a PVRI value of 17 wood units/m² and a cardiac index of 2.4 l min/m². The bosentan was switched to macitentan (10 mg/d) with no significant clinical improvement. As the clinical presentation

progressively worsened with fatigue, syncope, WHO FC IV (the patient was unable to perform the 6-MWT), and higher serum B-type natriuretic peptide (from 100 to 250 ng/L), the patient was classified as being at high risk, and prostacyclin target therapy was recommended.

We discussed the use of inhaled or even parenteral prostacyclin (subcutaneous pump or central catheter). Considering the risks of IV or subcutaneous prostacyclin administration and the need for frequent administration when aerosolized prostacyclins are used, we discussed the use of an oral route. Therefore, owing to the adverse events associated with the use of prostacyclin analogs, we decided to administer add-on therapy with an oral agonist of IP receptor (selexipag). Concomitant therapy (macitentan and sildenafil) and warfarin were maintained. The international normalized ratio was measured once each month because the therapeutic levels were stable (ranging from 2.2 to 2.5).

Selexipag was started in the evening at 200 mcg bid; during the first 2 weeks, the dose was raised in steps of 200 mcg once daily. After this initial period, the dose was uptitrated in steps of 400 mcg/d to reach a final dose of 1600 mcg/d (highest tolerated dose). Three weeks after starting selexipag add-on drug therapy, the patient’s WHO FC improved to III and her vital signs were as follows: heart rate 82 bpm, blood pressure 100/60 mmHg, and peripheral oxygen saturation 94%. No cardiac catheterization was performed after starting selexipag. At the final week of uptitrated dose (final dose: 1600 mcg/d), an improvement in the WHO FC, SF-36 clinical self-assessment score, and 6-MWT was observed [Figure 1a and b]. After 3 months of follow-up, the patient was classified as WHO FC II, and the PASP estimated on echocardiography decreased from 104.8 mmHg to 78 mmHg [Figure 2a-c]. Echocardiographic parameters are described as follows: PASP = 78 mmHg estimated on the basis of tricuspid regurgitation plus right atrial pressure of 10 mmHg, right atrial area = 18 cm², main pulmonary artery diameter = 2.7 cm, D-shaped LV, TAPSE = 1.8 cm, and no pericardial effusion. The use of supplemental oxygen was reduced to nocturnal oxygen therapy because her peripheral oxygen saturation showed improvement. In fact, she showed an important improvement in terms of

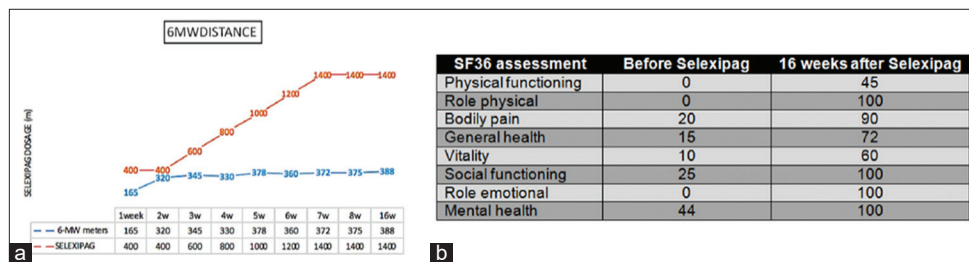


Figure 1: Clinical effects of selexipag in a teenage patient within the first 26 weeks: (a) Increase in the 6-min walking test distance with the titration dose and 3 months after starting this novel therapy and (b) improvement in the SF-36 clinical self-assessment score

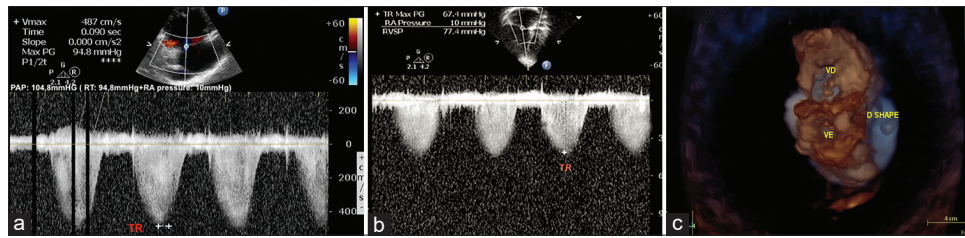


Figure 2: Echocardiography showing a decrease in the pulmonary artery systolic pressure from 104.8 mmHg before the initiation of selexipag (a) to 78 mmHg after 3 months (b). Pulmonary artery systolic pressure was calculated using the following formula: PAP = tricuspid regurgitation gradient (TR) + RA pressure (RAP) = 10 mmHg. PAP: Pulmonary artery systolic pressure; TR: Tricuspid regurgitation gradient; RAP: Right atrial pressure (c) 3D echocardiography showing the crescent-shaped LV (“D-shaped” LV) before selexipag initiation. 3D: Three dimensional; RV: Right ventricle; LV: Left ventricle

quality of life and could return to the performance of routine activities, including school activities.

DISCUSSION

The last consensus for pediatric PAH treatment by the American Heart Association and the American Thoracic Society recommends the use of prostacyclin analogs in high-risk patients and consideration of early combination with phosphodiesterase inhibitor and/or endothelin receptor antagonist.^[7] In the pediatric population, current treatment with drugs that act on the prostacyclin pathway include inhaled (iloprost and epoprostenol) and IV prostacyclin analogs (iloprost, treprostinil, and epoprostenol). Various studies have reported that the continuous IV infusion of prostacyclin improves patient survival; however, complications due to central venous catheter administration (sepsis, local infection, and catheter dislodgement) may occur.^[8,9] Currently, the risk of infection may be mitigated with the use of closed-hub systems, and IV prostacyclin is indicated in the critical care setting. One randomized control trial demonstrated improvements in the hemodynamic parameters and symptoms with continuous subcutaneous infusion of treprostinil.^[10] In fact, treatment with subcutaneous prostacyclins is well tolerated (79%), and site pain can be managed with simple analgesics in most pediatric patients.^[11] In addition, IV, subcutaneous, and inhaled prostacyclins are drugs with a short half-life and poor compliance.^[12-14] Consequently, considering the risks of parenteral use and with a focus on better compliance, we decided to use the oral route of administration.^[15]

Selexipag is an oral nonprostanoid and a highly selective IP prostacyclin receptor agonist that enables vasodilatation and inhibits cell proliferation.^[16] However, prostacyclin analogs stimulate other receptors, such as EP3 and TP, that are inhibitory receptors.^[17] The simultaneous activation of all receptors leads to opposing effects, weakening the IP receptor-mediated vasodilator effects, and inducing pulmonary vasoconstriction and cell proliferation. Therefore, this fact is related to the limited long-term efficacy and more intense adverse events observed in prostacyclin analogs therapy.^[5]

The GRIPHON study was a randomized, double-blind, placebo-controlled study that showed the safety (Phase 2) and efficacy (Phase 3) of this drug. In this study, the risk of death and complications due to PAH (primary endpoint) was significantly lower among patients who used selexipag than among those in the placebo group.^[18] Similarly, in this case, no hospitalization or other complications related to PAH were observed within 7 days after the last intake of selexipag. However, during the first 2 weeks (400 mcg/d–600 mcg/d), headache, diarrhea, and nausea persisted with symptomatic medications and food intake, requiring a 50% decrease in the weekly titration dose. Precocious adverse events constituted a challenge because they were used to define the maximum tolerated dose. The final tolerated dose in this teenage patient was 1600 mcg at which the adverse events became unmanageable.

In the reported case, no cardiac catheterization was performed after starting selexipag, and clinical parameters were used to guide therapy. The European Society of Cardiology and the European Respiratory Society guidelines do not mention compulsory cardiac catheterization for therapeutic change in pediatric patients.^[3] Furthermore, the indications for repeat cardiac catheterization in pediatric patients with pulmonary hypertension are not well defined.^[19]

Our subject was a high-risk patient; therefore, we started add-on selexipag despite the lack of data on the pediatric population. In a recent multicenter study on 15 patients,^[20] the add-on selexipag therapy was well tolerated with better right ventricular systolic function and FC.^[20] Furthermore, a single-center study on a small number of patients and a case report have shown similar results.^[21,22] Thus, selexipag may be a promising drug for targeting the prostacyclin pathway in pediatric patients with PAH. However, experimental studies conducted in rat pups demonstrated that selexipag causes gastrointestinal disturbances, such as intestinal intussusception.^[23] Therefore, to prevent the deleterious effects of selexipag in infants, additional studies on a larger population of pediatric patients are warranted.

Acknowledgment

The authors acknowledge Dr. Paloma Di Napoli for medical assistance to the case reported.

Declaration of patient consent

The authors certify that they have obtained all appropriate patient consent forms. In the form the parents have given their consent for the patient's images and other clinical information to be reported in the journal. They understand that their daughter's name and initials will not be published and due efforts will be made to conceal their identity, but anonymity cannot be guaranteed.

Financial support and sponsorship

Nil.

Conflicts of interest

There are no conflicts of interest.

REFERENCES

1. Peacock AJ, Murphy NF, McMurray JJ, Caballero L, Stewart S. An epidemiological study of pulmonary arterial hypertension. *Eur Respir J* 2007;30:104-9.
2. McGoon M, Gutterman D, Steen V, Barst R, McCrory DC, Fortin TA, *et al.* Screening, early detection, and diagnosis of pulmonary arterial hypertension: ACCP evidence-based clinical practice guidelines. *Chest* 2004;126 Suppl 1:14S-34S.
3. Galiè N, Humbert M, Vachiery JL, Gibbs S, Lang I, Torbicki A, *et al.* ESC/ERS Guidelines for the diagnosis and treatment of pulmonary arterial hypertension: The joint task force for the diagnosis and treatment of pulmonary arterial hypertension of the European society of cardiology (ESC) and the European Respiratory Society (ERS): Endorsed by: Association for European Paediatric and Congenital Cardiology (AEPC), International Society for Heart and Lung Transplantation (ISHLT). *Eur Heart J* 2015;37:67-119.
4. Sitbon O, Humbert M, Nunes H, Parent F, Garcia G, Hervé P, *et al.* Long-term intravenous epoprostenol infusion in primary pulmonary arterial hypertension: Prognostic factors and survival. *J Am Coll Cardiol* 2002;40:780-88.
5. Kuwano K, Hashino A, Asaki T, Hamamoto T, Yamada T, Okubo K, *et al.* 2-[4-[(5,6-diPULMONARY ARTERIAL HYPERTENSION enylpyrazin-2-yl)(isopropyl amino) butoxy]-N-(methylsulfonyl) acetamide (NS-304), an orally available and long-acting prostacyclin receptor agonist prodrug. *J Pharmacol Exp Ther* 2007;322:1181-8.
6. Morrison K, Studer R, Ernst R, Haag F, Kauser K, Clozel M. Differential effects of selexipag and prostacyclin analogs in rat pulmonary artery. *J Pharmacol Exper Ther* 2002;343:547-55.
7. Abman SH, Hansmann G, Archer SL, Ivy DD, Adatia I, Chung WK, *et al.* Pediatric Pulmonary arterial hypertension. *Circulation* 2015;132:2037-99.
8. Barst RJ, Maislin G, Fishman AP. Vasodilator therapy for primary pulmonary arterial hypertension in children. *Circulation* 1999;99:1197-208.
9. Yung D, Widlitz AC, Rosenzweig EB, Kerstein D, Maislin G, Barst RJ. Outcomes in children with idiopathic pulmonary arterial hypertension. *Circulation* 2004;110:660-5.
10. Simonneau G, Barst RJ, Galie N, Naeije R, Rich S, Bourge RC, *et al.* Continuous subcutaneous infusion of treprostinil, a prostacyclin analogue, in patients with pulmonary arterial hypertension: A double-blind, randomized, placebo-controlled trial. *Am J Respir Crit Care Med* 2002;165:800-4.
11. Levy M, Del Cerro MJ, Nadaud S, Vadlamudi K, Colgazier E. Fineman safety, efficacy and management of subcutaneous treprostinil infusions in the treatment of severe pediatric pulmonary hypertension. *Int J Cardiol* 2018;264:153-7.
12. Barst RJ, Rubin LJ, McGoon MD, Caldwell EJ, Long WA, Levy PS. Survival in primary pulmonary arterial hypertension with long-term continuous intravenous prostacyclin. *Ann Intern Med* 1994;121:409-515.
13. Ivy DD, Doran AK, Smith KJ, Mallory GB Jr., Beghetti M, Barst RJ, *et al.* Short- and long-term effects of inhaled iloprost therapy in children with pulmonary arterial hypertension. *J Am Coll Cardiol* 2008;51:161-9.
14. Mubarak KK. A review of prostaglandin analogs in the management of patients with pulmonary arterial hypertension. *Respir Med* 2010;104:9-21.
15. Morrison K, Ernst R, Hess P, Studer R, Clozel M. Selexipag: A selective prostacyclin receptor agonist that does not affect rat gastric function. *J Pharmacol Exp Ther* 2010;335:249-55.
16. Kaufmann P, Okubo K, Bruderer S, Mant T, Yamada T, Dingemans J, *et al.* Pharmacokinetics and tolerability of the novel oral prostacyclin IP receptor agonist selexipag. *Am J Cardiovasc Drugs* 2015;15:195-203.
17. Whittle BJ, Silverstein AM, Mottola DM, Clapp LH. Binding and activity of the prostacyclin receptor (IP) agonists, treprostinil and iloprost, at human prostanoid receptors: Treprostinil is a potent DP1 and EP2 agonist. *Biochem Pulm Arterial Hypertens Farmacol* 2012;84:68-75.
18. Sitbon O, Channick R, Chin KM, Frey A, Gaine S, Galie N, *et al.* Selexipag for the treatment of pulmonary arterial hypertension. *N Engl J Med* 2015;373:2522-33.
19. Rosenzweig EB, Abman SH, Adatia I, Beghetti M, Bonnet D, Haworth S, *et al.* Paediatric pulmonary arterial hypertension: Updates on definition, classification, diagnostics and management. *Eur Respir J* 2019;53(1):1801916.
20. Hansmann G, Meinel K, Bukova M, Chouvarine P, Wählander H, Koestenberger M, *et al.* Selexipag for the treatment of children with pulmonary arterial hypertension: First multicenter experience in drug safety and efficacy. *J Heart Lung Transplant* 2020;39:695-706.
21. Geerdink LM, Bertram H, Hansmann G. First-in-child use of the oral selective prostacyclin IP receptor agonist selexipag in pulmonary arterial hypertension. *Pulm Circ* 2017;7:551-4.
22. Gallotti R, Drogalis-Kim DE, Satou G, Alejos J. Single-center experience using selexipag in a pediatric population. *Pediatr Cardiol* 2017;38(7):1405-9.
23. The Therapeutic Goods Administration TGA. Australian Public Assessment Report for Selexipag. Available from: <https://www.tga.gov.au>. [Last accessed on 2020 Aug 07].