

The role of Nesbit's procedure in surgical reconstruction of penile deviation

Der Stellenwert der Nesbit-Technik in der chirurgischen Rekonstruktion peniler Deviationen

Abstract

Objective: We review our results after surgical reconstruction with the Nesbit's procedure for congenital or acquired penile deviation.

Patients and methods: Etiology of penile deviation, surgical outcome for straightening the penis, postoperative patient satisfaction and clinical findings were evaluated for 5 patients undergoing Nesbit's procedure followed by a Medline review of contemporary literature regarding alternative surgical techniques. Follow-up included clinical examination, self-photography on erection and a standardized interview with erectile dysfunction assessment using IIEF-5 questionnaire.

Results: Overall patient satisfaction was 100% in two patients, 2 patients were partly satisfied and 1 patient reported no satisfaction because of severe penile shortening with insufficiency for sexual intercourse post-operatively. Preoperative mean angulation of the penis was 42°. Four patients had Peyronie's disease and 1 patient's curvature resulted from an untreated penile fracture during sexual intercourse.

Conclusion: The Nesbit technique can give satisfactory results for mild and moderate penile curvature. However, each technique for the reconstruction of penile deviation has its own advantages and disadvantages. Therefore proper patient selection has a major impact on further outcome.

Keywords: penile deviation, Peyronie's disease, Nesbit's procedure, surgical penile reconstruction

Zusammenfassung

Ziel: Darstellung der Ergebnisse nach chirurgischer Rekonstruktion der kongenitalen und erworbenen Penisdeviation nach Nesbit anhand des eigenen Patientenkollektivs.

Patienten und Methoden: Die Evaluation von 5 Patienten mit Penisdeviation erfolgte hinsichtlich der Genese der penilen Deviation, des chirurgischen Ergebnisses, der postoperativen Patientenzufriedenheit und anhand klinischer Merkmale. Die Daten wurden verglichen mit den Ergebnissen einer aktuellen Literaturrecherche der Medline-Datenbank bzgl. alternativer Operationstechniken der Penisdeviation. Das Follow-up beinhaltete eine klinische Untersuchung, eine Selbstfotografie des Penis im erigierten Zustand und eine standardisierte mündliche Befragung in Kombination mit dem IIEF-5 Fragebogen zur Evaluation der postoperativen erektilen Dysfunktion.

Resultate: 2 Patienten zeigten sich voll zufrieden, 2 Patienten waren teilweise zufrieden und 1 Patient war unzufrieden aufgrund einer signifikanten postoperativen Penisverkürzung, die keinen Geschlechtsverkehr ermöglichte. Das mittlere Ausmaß der präoperativen Penisdeviation war 42°. 4 Patienten hatten eine Penisdeviation im Rahmen der Peyronie-Krankheit und 1 Patient hatte anamnestisch eine Penisfraktur, die nicht unmittelbar chirurgisch behandelt wurde.

Christian Martenstein¹

Julia Peruth¹

Amir Hamza¹

¹ Department of Urology, St. Georg Hospital Leipzig, Leipzig, Germany

Schlussfolgerung: Die Operation nach Nesbit zur Begradigung der milden bis moderaten Penisdeviation zeigt zufriedenstellende Ergebnisse. In Anbetracht alternativer Operationsmethoden hat jede Technik ihre Vor- und Nachteile. Daher kommt der Patientenselektion hinsichtlich eines optimalen postoperativen Ergebnisses eine große Bedeutung zu.

Schlüsselwörter: Penisdeviation, Peyronie-Krankheit, OP nach Nesbit, chirurgisch-penile Rekonstruktion

Introduction

Reconstructive surgical urology in the 21st century maintains an important role in the correction of penile deviation. Peyronie's disease (PD), congenital penile curvature or penile deviation after genital trauma can have a major impact on quality of life, therefore several surgical techniques have been proposed according to the grade of penile deviation.

Reed M. Nesbit pioneered the reconstructive surgical management of PD in 1965 [1]. Nesbit's procedure shows a low complication rate and is recognized as gold standard for the treatment of penile deviation or Peyronie's disease. However, shortening of penile length by 1–3 inches occurs in most cases, therefore Nesbit's procedure is limited to patients with adequate penile length and mild to moderate curvature [2].

This technique has led into several modifications [3], [4], [5]. However, the results overall have been either less satisfactory or almost similar to those using the Nesbit procedure [6], [7], [8]. Other procedures involving grafting with or without excision of fibrous plaques claim better cosmetic results [9], [10], [11], but their long-term results are still pending.

The interaction of all corresponding penile tissue layers (tunica albuginea, Buck's fascia, dartos fascia, penile shaft skin) leads to an increase of rigidity and tumescence and allows an even erection of the penis (Figure 1). If there is an uneven erection, the cause can be congenital or acquired [12].

A congenital penile curvature may be caused by hypo- or epispadias, chordae without hypospadias or by a genuine congenital penile curvature.

Induratio Penis Plastica (IPP) or Peyronie's disease most commonly occurs as an acquired form of penile deviation and has been first described in 1743 [13]. The disease progresses in stages and begins with an acute inflammatory phase with painful erections and palpable painful plaques. The plaques usually develop on the dorsum of the penis in most cases and lead to a concave curvature on the side of infestation. If plaques form on either side of the penis, a significant shortening of the penis may occur due to tissue placcation (hourglass deformity). Particularly induration of the upper coronary sulcus can lead to severe deteriorating dysfunction of the alongside running vessels and the neurovascular bundle. Impaired erection and numbness of the glans may be the result. Eventually a change of curvature when the penis is erected occurs. Painful erections often resolve after 6 months and deformity of the penis stabilizes by 12 months. During

the stable phase with fibrosis, calcification and further penile deviation, erectile dysfunction (ED) may develop or progress [14].

An acquired penile curvature may also result from penile fractures mostly caused by vigorous sexual intercourse when the penis is bent by hitting the perineum of the partner. Other reasons for penile fracture leading to penile deviation are failed early surgical management after penile injuries, open surgical procedures with subsequent scarring, urethral instrumentation (e.g., internal urethrotomy) or intracavernous administered substances [12].

Patients and methods

We reviewed the short-term outcome of 5 patients who underwent Nesbit's procedure between February 2010 and October 2011 in our institution with mean duration of follow-up of 10 months (2–20 months). Preoperatively, causes for penile deviation were recorded. The patients with PD had stable disease for more than 1 year and persistent sexually disabling penile incurvation of more than 30°. The angle and degree of the penile curvature were determined by history and by photographs of the erect penis either taken by the patient or as arranged at the hospital before surgery. A subsequent detailed physical examination and response to intracavernous injection of a test dose of erectogenic medication ruled out any active organic etiology for erectile dysfunction. Postoperative outcome was recorded by clinical examination addressing complications related to the operation (shortening, decreased sensation, pain, palpable nodules and recurrence of curvature) and by auto-photography of the erect penis. In addition, a telephone interview by an independent reviewer was performed regarding erectile function (using the International Index of Erectile Function-5 questionnaire, IIEF-5 score) and overall satisfaction (completely 100%, partially 50% or not satisfied <50%). In addition an English language Medline review regarding current surgical reconstructive techniques for penile deviation was performed.

The surgical procedure starts with an artificial erection generated by injection of physiological saline (Figure 2). Then an elliptical excision of the tunica albuginea at the convex side is made, i.e. we excise an ellipse of 1 mm wide for every 10 degrees of deformation on the aspect opposite the deviation and leave the plaque on the deformed side (Figure 3). Finally, absorbable sutures are used for subsequent closure of the tunica albuginea to straighten the penile shaft. Urethral Foley catheters were

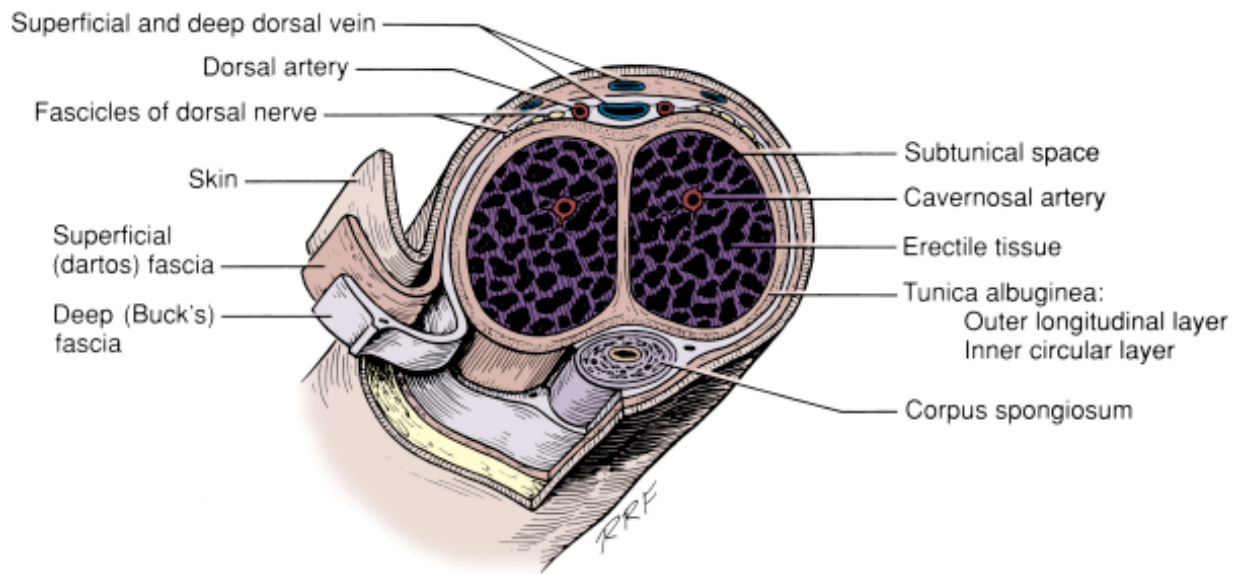


Figure 1: Anatomical cross section of the penis (Figure adapted from Campbell-Walsh Urology, Saunders, 9th Edition 2007, USA)

placed in all patients. Elastic bandages were applied in all patients postoperatively in addition with bed rest, penoscrotal elevation and prophylactic antibiotics.

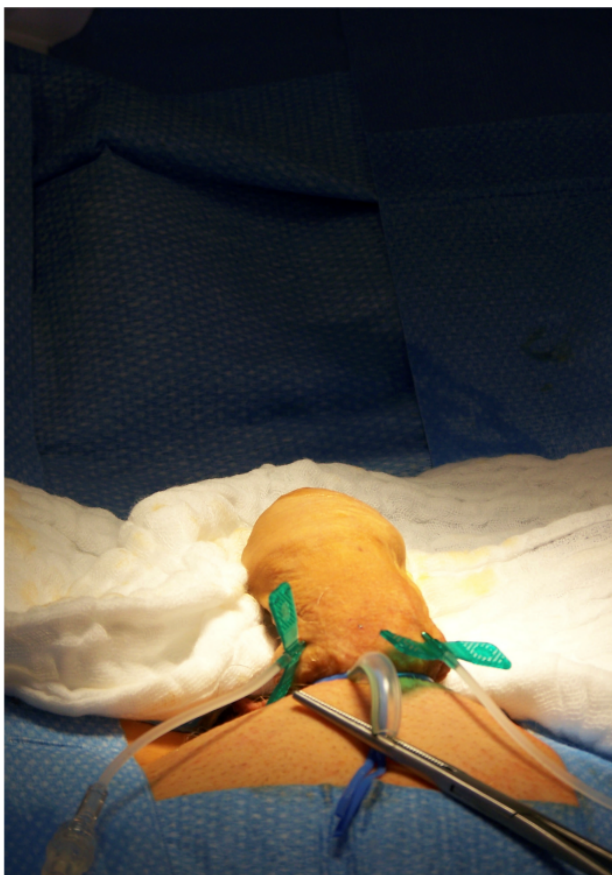

Figure 2: Intraoperative artificial penile erection

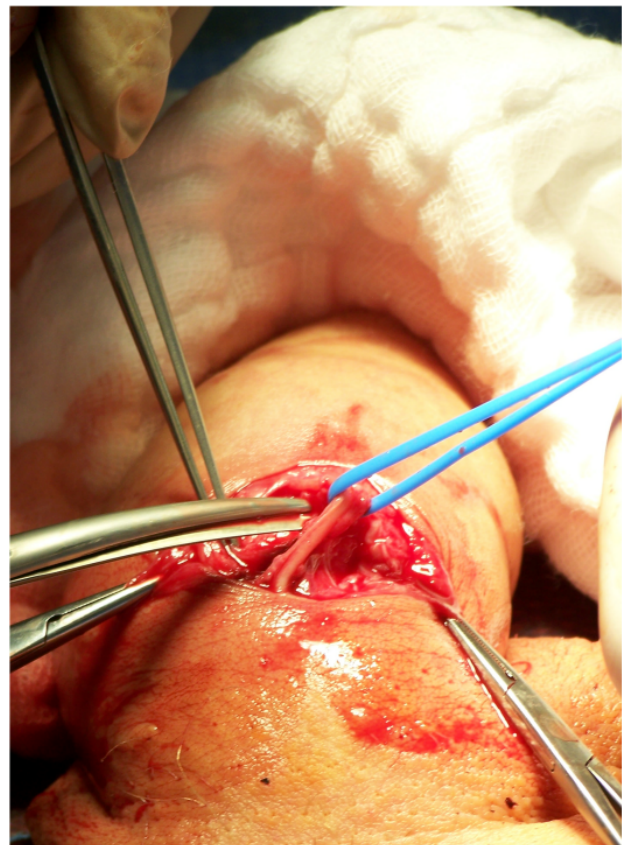


Figure 3: Ellipsoid excision of the tunica albuginea with preserving of the neurovascular bundle

Table 1: Patient characteristics

Patients	Etiology	Angle of Deviation	Direction of Deviation	IIEF-5 Score p.o.	Overall Satisfaction
1	Peyronie's Disease	35°	dorsal-left	*	not satisfied
2	Peyronie's Disease	45°	ventral	17	partially
3	Peyronie's Disease	30°	dorsal-left	21	completely
4	Peyronie's Disease	55°	lateral-right	15	partially
5	penile fracture	45°	dorsal-right	22	completely

* patient with insufficient penile length for sexual intercourse

Results

All patients presented to our hospital with a penile deviation between 30–55° (mean 42°) with a mean elapsed time from start of penile deviation to operation of 32 months (14–42 months). Mean age of patients was 58 years (51–66 years) and mean time of operation and hospitalisation were 47 minutes (38–63 minutes) and 5.6 days (4–7 days). All patients but one, whose deviation resulted from a surgically untreated penile fracture during sexual intercourse, presented with typical clinical signs of PD with penile deviation, painful erection and penile plaques not allowing satisfying sexual intercourse. Mean age of onset of disease of these 4 patients was 56 years. One patient had Dupuytren's contracture as a comorbidity and 1 patient had previous failed Extracorporeal Shock-wave Therapy (ESWT) for plaque disintegration. This patient also had a Nesbit's procedure elsewhere due to a right-sided deviation resulting in an opposite curvature to the left. Postoperative fever occurred in two cases, 2 penile hematomas were managed conservatively. Severe shortening of the penis was complained by 1 patient with insufficiency of sexual intercourse with penile size of 8 cm and therefore this patient did not answer the IIEF-5 questionnaire. In addition 1 patient reported decreased sensation of the glans, where as mean IIEF-5 score was 18.8 postoperatively. Two patients with erectile dysfunction. Furthermore, satisfying straightening of the penis after surgery was reported by all patients and proved on last consultation of follow-up. Overall, 2 patients were happy with the outcome of their surgery and 2 were partly satisfied due to reduced erectile function. However, 1 patient expressed dissatisfaction with his surgery because of severe penile shortening (Table 1).

Discussion

The surgical reconstruction of penile deviation should focus on correction of either the convex or concave side. On one hand this can be done by lengthening the shorter side (using a graft) or shortening the longer side (using a plication procedure). Plication of the tunica albuginea should be considered in patients with adequate penile length, rigidity, and curvature less than 60°. The Yachia procedure is a modification of the Nesbit's procedure and relies on the horizontal closure of a longi-

tudinal incision in a Heineke-Mikulicz fashion [3]. This procedure has also been well documented with favourable results of 95% success rates [7]. In contrast to Nesbit's procedure the Schroeder and Essed technique omits the excision of the tunica albuginea. Moreover, multiple nonabsorbable sutures shorten the length of the corpora cavernosa on the convex side and provide a compensation of the deviation [4]. A comparable large study of 124 men with mean follow-up of 2.6 years showed a patient-measured outcome satisfaction of 96% [15]. The advantages in this technique rely on the fact that there is no excision of plaques or dissection of the neurovascular bundle, thus limiting postoperative erectile impairment.

In the presence of a curvature >60°, hinge and hourglass effect a plaque excision in combination with grafting procedures should be considered [16]. With graft-based penile reconstruction the plaque is removed using microsurgery with preservation of the neurovascular bundle and the resulting defect is covered with endo- or exogenous material. The graft should be sufficiently extensible, infection-resistant, low-inflammatory and be sterile [11]. There are several different materials to cover the penile defect, e.g. autologous dermal grafts [9], the saphenous vein [10] or bovine pericardium [17]. The main advantage of these methods is to compensate the penile deviation without shortening the penis. However, the rate of postoperative erectile dysfunction is higher than after plication techniques. Austoni et al. reviewed 564 patients with a reduced stiffness during erection in 113 (20%) and a graft shrinkage with subsequent re-deviation in 17% of patients [18]. More recently, El-Sakka et al. report on 113 men treated with saphenous vein grafting with a follow up of 18 months and satisfactory straightening of the penis in 96%, but de novo ED in 12%, and a change in penile sensation lasting longer than 6 months in 10% [19]. Polyester and polytetrafluoro-ethylene represent synthetic graft options, but an increased risk of infection, allergic reaction, enhanced inflammation causing fibrosis, and higher rates of contracture do not favour for wide spread acceptance [20]. Therefore, an ideal graft tissue has not been found yet, although reports of promising alternatives have been described in small patient numbers [21].

If ED caused by cavernosal arterial insufficiency, venous leak, or combined vascular abnormalities is present, a penile implant (rigid or semi-rigid) for straightening the penis allowing on-demand erection is an option [16].

Surgical correction of penile curvature remains a challenging procedure where patient selection regarding the operational technique is of important relevance. Therefore we selected our patients carefully, i.e. we excluded patients with penile curvature $>60^\circ$ and pre-existing erectile dysfunction from offering Nesbit's procedure.

Sexual intercourse and genital self-manipulation are most causes in industrialized countries for penile fracture and, if not operated immediately, cause subsequent deviation. A recent report of the U.S. National Statistics on Penile Fracture describes 1,043 men with mean age of 36.7 years for hospital admissions secondary to penile fracture in the years of 2006 and 2007 [22]. A technique called Taqaandan, where the top of the erect penis is bent forcefully against the rest of the stationary shaft to induce a cracking noise is the cause for most penile fractures in young men in the Middle East. Zargooshi et al. report on 269 of 352 operated patients between 1990 and 2008 with penile fracture to have practised Taqaandan with mean age of 29.6 years in Iran [23]. In fact the number of patients not seeking immediate medical assistance after penile fracture remains unknown.

A recent survey in the Cologne area demonstrated a prevalence of 3.2% (142/4,432) for PD with mean age of 57.4 years [24]. Thus, PD is no longer classified as a rare disease and requires adequate treatment. The increasing prevalence is most likely due to the recognition of a bent penis during tumescence in men with erectile dysfunction who are now being treated with phosphodiesterase therapy.

Although we report of a small patient population, onset of PD with clinical findings and the presence of penile deviation after genital trauma in 1 patient coincide with reports in the literature. Moreover 2 patients reported partly satisfaction after surgical reconstruction of the penis because of erectile dysfunction validated by a decreased IIEF-5 score. Due to a follow-up of less than 4 months in these patients we have not yet started phosphodiesterase therapy allowing tissue healing. One patient reported no satisfaction because of insufficiency for sexual intercourse due to decreased penile length. The rationale for unfavourable postoperative outcome should be explained to the patient preoperatively in detail, i.e. the risk of subsequent deviation, the risk of erectile dysfunction and hypaesthesia of the penile glans with penile shortening, infection or hematoma. Ralph et al. demonstrated a 82% success rate for sexual intercourse in 359 operations over 15 years after Nesbit's procedure [2]. However, shortening of penile length by 1–3 inches occurred in most cases, therefore this procedure should be limited to patients with adequate penile length and mild to moderate curvature [2].

One patient in our study reported of persisting erectile pain and remaining penile plaques and curvature after ESWT. Performing an ESWT can relief pain and can fracture the calcified plaques [25], whereas first double-blinded, randomized, placebo-controlled studies did not observe any significant change in penile curvature after

ESWT [26]. Nevertheless it must be stated that ESWT currently does not play a significant role in the treatment of PD.

In conclusion, the surgical reconstructive management of our patient's penile deviations with the Nesbit procedure confirms temporary results for the success rate of straightening the penis hazarding the risk of erectile dysfunction and significant penile shortening. Our patients presented with all characteristics of penile deviation, future recurrence of Peyronie's Disease with subsequent penile curvature has to be determined in the long term. Despite the fact that this study shows short-term follow-up with a small number of patients, we believe that the Nesbit procedure is still a useful technique after its introduction more than 40 years ago. However, patient selection and informed consent are important factors for good success rates.

Notes

Competing interests

The authors declare that they have no competing interests.

References

1. Nesbit RM. Congenital Curvature of the Phallus: Report of Three Cases with Description of Corrective Operation. *J Urol*. 1965;93:230-2.
2. Ralph DJ, al-Akraa M, Pryor JP. The Nesbit operation for Peyronie's disease: 16-year experience. *J Urol*. 1995;154(4):1362-3. DOI: 10.1016/S0022-5347(01)66862-9
3. Yachia D. Modified corporoplasty for the treatment of penile curvature. *J Urol*. 1990;143(1):80-2.
4. Essed E, Schroeder FH. New surgical treatment for Peyronie disease. *Urology*. 1985;25(6):582-7. DOI: 10.1016/0090-4295(85)90285-7
5. Kelami A. Congenital penile deviation and straightening of the penis using the Nesbit-Kelami technique. *Urol Int*. 1985;40(5):267-8. DOI: 10.1159/000281096
6. Brake M, Keller H, Lamade F, Groh R, Horsch R. Operative Korrektur der Penisdeviation [Surgical correction of penile deviation. Nesbit vs. Schroeder-Essed method]. *Urologe A*. 1999;38(3):264-9. DOI: 10.1007/s001200050279
7. Sassine AM, Wespes E, Schulman CC. Modified corporoplasty for penile curvature: 10 years' experience. *Urology*. 1994;44(3):419-21. DOI: 10.1016/S0090-4295(94)80106-1
8. Yachia D. Incisional Corporoplasty for the Correction of Peyronie's Disease Caused Penile Curvature. In: Levine LA, ed. *Peyronie's Disease: A guide to clinical management*. Totowa, New Jersey: Humana Press; 2007. p. 161-174.
9. Kondás J, Diószeghy G, Kondér G, Vácz L, Kiss A, Philipp V. Plaque excision and dermal graft in the surgical treatment of plastic induration of the penis (Peyronie's disease). *Int Urol Nephrol*. 1998;30(3):321-6.

10. Imbeault A, Bernard G, Ouellet G, Bouhout S, Carrier S, Bolduc S. Surgical Option for the Correction of Peyronie's Disease: An Autologous Tissue-Engineered Endothelialized Graft. *J Sex Med.* 2011;8(11):3227-35. DOI: 10.1111/j.1743-6109.2011.02374.x
11. Al-Shajji TF, Brock GB. Peyronie's disease: evolving surgical management and the role of phosphodiesterase 5 inhibitors. *ScientificWorldJournal.* 2009;9:822-45. DOI: 10.1100/tsw.2009.101
12. Jordan GM, Devine CJ. Surgery of the penis and urethra. In: Walsh PC, et al., eds. *Cambell's Urology*, Vol. 3. 7th ed. Philadelphia: WB Saunders; 1998. p. 3316-94.
13. Androustos G. Francois Gigot de Lapeyronie (1678–1747), bienfaiteur de la chirurgie et promoteur de la fusion medecine-chirurgie, et la maladie qui porte son nom [Francois Gigot de La Peyronie (1678–1747), benefactor of surgery and supporter of the fusion of medicine and surgery, and the disease that bears his name]. *Prog Urol.* 2002;12(3):527-33.
14. Gelbard MK, Dorey F, James K. The natural history of Peyronie's disease. *J Urol.* 1990;144(6):1376-9.
15. Gholami SS, Lue TF. Correction of penile curvature using the 16-dot plication technique: a review of 132 patients. *J Urol.* 2002;167(5):2066-9. DOI: 10.1016/S0022-5347(05)65085-9
16. Ralph D, Gonzalez-Cadavid N, Mirone V, Perovic S, Sohn M, Usta M, Levine L. The management of Peyronie's disease: evidence-based 2010 guidelines. *J Sex Med.* 2010;7(7):2359-74. DOI: 10.1111/j.1743-6109.2010.01850.x
17. Seftel A. Treatment of Peyronie's disease by incomplete circumferential incision of the tunica albuginea and plaque with bovine pericardium graft. *J Urol.* 2002;168(2):869. DOI: 10.1016/S0022-5347(05)64786-6
18. Austoni E, Colombo F, Mantovani F, Patelli E, Fenice O. Chirurgia radicale e conservazione dell'erezione nella malattia di La Peyronie [Radical surgery and conservation of erection in Peyronie's disease]. *Arch Ital Urol Androl.* 1995;67(5):359-64.
19. El-Sakka AI, Rashwan HM, Lue TF. Venous patch graft for Peyronie's disease. Part II: outcome analysis. *J Urol.* 1998;160(6 part 1):2050-3. DOI: 10.1016/S0022-5347(01)62240-7
20. Kadioglu A, Sanli O, Akman T, Ersay A, Guven S, Mammadov F. Graft materials in Peyronie's disease surgery: a comprehensive review. *J Sex Med.* 2007;4(3):581-95. DOI: 10.1111/j.1743-6109.2007.00461.x
21. Kovac JR, Brock GB. Surgical outcomes and patient satisfaction after dermal, pericardial, and small intestinal submucosal grafting for Peyronie's disease. *J Sex Med.* 2007;4(5):1500-8. DOI: 10.1111/j.1743-6109.2007.00453.x
22. Aaronson DS, Shindel AW. U.S. national statistics on penile fracture. *J Sex Med.* 2010;7(9):3226. DOI: 10.1111/j.1743-6109.2010.01879.x
23. Zargooshi J. Sexual function and tunica albuginea wound healing following penile fracture: An 18-year follow-up study of 352 patients from Kermanshah, Iran. *J Sex Med.* 2009;6(4):1141-50. DOI: 10.1111/j.1743-6109.2008.01117.x
24. Schwarzer U, Sommer F, Klotz T, Braun M, Reifenrath B, Engelmann U. The prevalence of Peyronie's disease: results of a large survey. *BJU Int.* 2001;88(7):727-30. DOI: 10.1046/j.1464-4096.2001.02436.x
25. Hauck EW, Mueller UO, Bschiepfer T, Schmelz HU, Diemer T, Weidner W. Extracorporeal shock wave therapy for Peyronie's disease: exploratory meta-analysis of clinical trials. *J Urol.* 2004;171(2 part 1):740-5. DOI: 10.1097/01.ju.0000108060.30363.8d
26. Chitale S, Morse M, Swift L, Sethia K. Limited shock wave therapy vs sham treatment in men with Peyronie's disease: results of a prospective randomized controlled double-blind trial. *BJU Int.* 2010;106(9):1352-6. DOI: 10.1111/j.1464-410X.2010.09331.x

Corresponding author:

Dr. med. Christian Martenstein
 Department of Urology, St. Georg Hospital Leipzig,
 Delitzscher Strasse 141, 04129 Leipzig, Germany, Phone:
 +49(0)177-4238991, Fax: +49(0)341-9092775
 christianmartenstein@hotmail.com

Please cite as

Martenstein C, Peruth J, Hamza A. The role of Nesbit's procedure in surgical reconstruction of penile deviation. *GMS Interdiscip Plast Reconstr Surg DGPW.* 2012;1:Doc06.
 DOI: 10.3205/iprs000006, URN: urn:nbn:de:0183-iprs0000064

This article is freely available from

<http://www.egms.de/en/journals/iprs/2012-1/iprs000006.shtml>

Published: 2012-01-09

Copyright

©2012 Martenstein et al. This is an Open Access article distributed under the terms of the Creative Commons Attribution License (<http://creativecommons.org/licenses/by-nc-nd/3.0/deed.en>). You are free: to Share – to copy, distribute and transmit the work, provided the original author and source are credited.