

Case Report / Olgu Sunumu

Asymptomatic air collection in the left atrium after computed tomography-guided lung biopsy

Bilgisayarlı tomografi eşliğinde akciğer biyopsisi sonrası sol atriyumda asemptomatik hava birikimi

Akitoshi Inoue¹, Masatsugu Ohuchi², Shuhei Inoue²

Institution where the research was done:

National Hospital Organization, Higashi-Ohmi General Medical Center, Shiga, Japan

Author Affiliations:

¹Department of Radiology, National Hospital Organization, Higashi-Ohmi General Medical Center, Shiga, Japan

²Department of General Thoracic Surgery, National Hospital Organization, Higashi-Ohmi General Medical Center, Shiga, Japan

ABSTRACT

Systemic air embolism is a fatal lung biopsy complication, despite its low incidence. Incidental air immigration into the pulmonary vein passing through the left heart circulation results in air embolism in percutaneous lung biopsy. Herein, we report a 73-year-old man who presented with massive air collection in the left atrium after computed tomography-guided lung biopsy which resolved without any symptom. Computed tomography fluoroscopy confirmed the gradual absorption process.

Keywords: Air embolism, image-guided biopsy, lung neoplasms.

Imaging examinations are not always able to distinguish if the pulmonary nodule is benign or malignant.^[1] Histopathology is the gold standard for the diagnosis of neoplastic lesions. Tissue sampling with surgical, endoscopic, or image-guided percutaneous approach is widely accepted in lung nodules. The complication of computed tomography (CT)-guided lung biopsy includes pulmonary hemorrhage, pneumothorax, hemothorax, and systemic air embolism.^[2] Furthermore, systemic air embolism is the most crucial complication of CT-guided lung biopsy, resulting in coronary and brain infarction.

Herein, we report a case of massive air collection in the left atrium after CT-guided lung biopsy which

ÖZ

Sistemik hava embolisi, düşük insidansına rağmen, akciğer biyopsisinin ölümcül bir komplikasyondur. Perkütan akciğer biyopsisinde hava pulmoner venlerden tesadüfi olarak sol kalbe ilerleyerek, hava embolisine neden olur. Bu yazıda bilgisayarlı tomografi eşliğinde akciğer biyopsisi sonrası sol atriyumda masif hava birikimi gelişen ve semptomsuz bir şekilde düzelen 73 yaşında erkek bir olgu sunuldu. Bilgisayarlı tomografi floroskopi ile kademeli absorpsiyon süreci doğrulandı.

Anahtar sözcükler: Hava embolisi, görüntü rehberliğinde biyopsi, akciğer neoplazileri.

resolved without any symptom and CT fluoroscopy confirmed the gradual absorption process.

CASE REPORT

A 73-year-old male patient with a history of right lower lobectomy for a squamous cell carcinoma five years ago underwent CT examination for postoperative surveillance, which revealed a new nodule in the right middle lobe. As histopathological examination using a specimen obtained via transbronchial lung biopsy failed to diagnose, CT-guided biopsy was scheduled.

Computed tomography images before the procedure were obtained in the prone position. No air in the

Received: November 02, 2020 Accepted: February 07, 2021 Published online: January 28, 2022

Correspondence: Akitoshi Inoue, MD, Department of Radiology, National Hospital Organization, Higashi-Ohmi General Medical Center, 527-8505 Shiga, Japan. Tel: +81-748-22-3030 e-mail: akino@belle.shiga-med.ac.jp

Cite this article as:

Inoue A, Ohuchi M, Inoue S. Asymptomatic air collection in the left atrium after computed tomography-guided lung biopsy. Turk Gogus Kalp Dama 2022;30(1):129-131

©2022 All right reserved by the Turkish Society of Cardiovascular Surgery.

This is an open access article under the terms of the Creative Commons Attribution-NonCommercial License, which permits use, distribution and reproduction in any medium, provided the original work is properly cited and is not used for commercial purposes (<http://creativecommons.org/licenses/by-nc/4.0/>).

cardiovascular system was identified. In addition, CT-guided lung biopsy was performed using an 18-gauge biopsy needle (Starcut® aspiration type, TSK Laboratory, Tochigi, Japan) with a 1 cm-stroke length; however, no specimen was obtained. The stroke length was, then, increased to 2 cm and negative pressure was implemented by an aspiration syringe during lung biopsy. Although the white solid specimen was obtained, CT obtained immediately after procedure revealed infiltration surrounding the nodule and an air-fluid level in the left atrium (Figure 1). Air accumulation in the left atrium and pulmonary alveolar hemorrhage related to lung biopsy were considered.

The patient was asymptomatic. He was kept in the prone Trendelenburg position and whole-body

CT was performed which revealed no air in the brain and cardiovascular system, except for that in the left atrium. The total amount of air in the left atrium was monitored with CT fluoroscopy every hour. After confirming a decrease of the air in the left atrium as well as infiltration gradually (Figure 2), the patient was, then, transferred to a hospital room in the right lateral decubitus Trendelenburg position. On the next day, whole-body CT revealed no remarkable findings, as well as no air in the left atrium, suggesting that air was absorbed into the blood. The nodule was diagnosed with *nontuberculous mycobacterium* infection, and the patient was treated with antibiotics. A written informed consent was obtained from the patient.

DISCUSSION

Air embolism is a fatal complication of lung biopsy with an incidence reportedly ranging from 0.16 to 0.27%.^[2] Outside air can invade into the cardiovascular system via the pulmonary vein; therefore, the biopsy needle entering the intrapulmonary vessels can be a risk for this complication.^[3] Well-known risk factors for this complication are coughing during the procedure, positive pressure ventilation, cystic or cavitory lesion, ground-glass nodules, and the coexistence of vasculitis, prone position, and usage of a thick needle.^[2] Even a small air embolism could be fatal, if the air induces coronary ischemia and arrhythmia.^[4] Surprisingly, the abnormal air in the pulmonary vein, left atrium, coronary artery, and aorta was revealed on CT in approximately 5% of asymptomatic patients after CT-guided lung biopsy.^[5] Given the lower incidence of symptomatic systemic air embolism, larger number of asymptomatic air immigration may occur into the circulation than expected.

The present case was asymptomatic, despite a massive amount of air in the left atrium. Furthermore, whole-body CT showed no evidence of air in the peripheral vessels and organs. It is hypothesized that air is only localized to the left atrium, until the air is absorbed into the blood, preventing sequential severe complications, including cardiopulmonary arrest due to coronary ischemia, arrhythmia, or brain infarction causing neurological sequelae by waiting for natural air absorption. The optimal duration for air absorption in the blood is unclear,^[4] and some patients with abnormal air in the cardiovascular system in the previous study presented no symptoms by any specific procedure.^[6] However, keeping an asymptomatic patient with air embolism detected on CT immediately after percutaneous lung biopsy in the same position is necessary to avoid immigration of air to vital organs, until the abnormal air is absorbed.

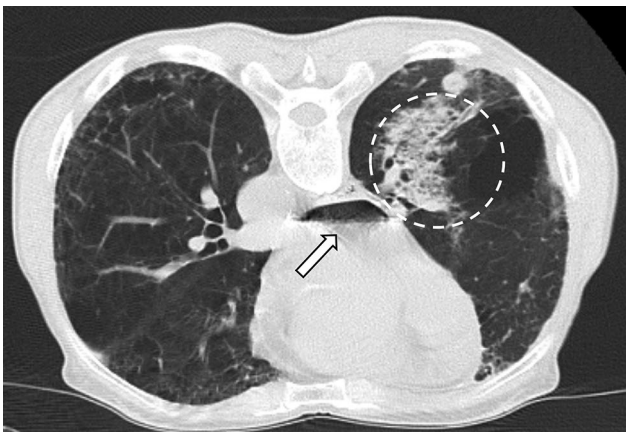


Figure 1. A computed tomography image taken immediately after lung biopsy for a nodule in the right middle lobe. An air-fluid level in the left atrium (arrow) and infiltrative opacity surrounding the nodule (circle) are observed.

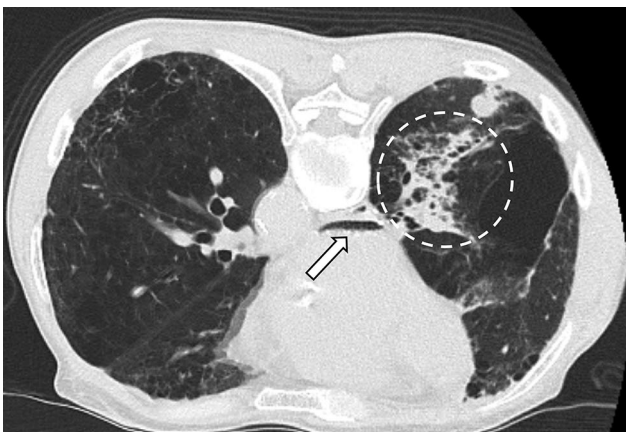


Figure 2. A computed tomography image at 4 h after lung biopsy. The amount of air in the left atrium is decreased, but still remains (arrow). Infiltrative opacity is improved (circle).

In conclusion, air collection in the heart chamber is the previous asymptomatic stage of fatal air embolism and can be absorbed by observation without moving. Thus, a computed tomography scan should be performed immediately after a computed tomography-guided lung biopsy to assess complications, including cardiovascular abnormal air.

Declaration of conflicting interests

The authors declared no conflicts of interest with respect to the authorship and/or publication of this article.

Funding

The authors received no financial support for the research and/or authorship of this article.

REFERENCES

1. Önen A, Şanlı A, Karapolat S, Karacam V, Kargı A. Pulmonary hamartoma and squamous cell carcinoma: A very rare coexistence. *Turk Gogus Kalp Dama* 2007;15:311-3.
2. Ishii H, Hiraki T, Gobara H, Fujiwara H, Mimura H, Yasui K, et al. Risk factors for systemic air embolism as a complication of percutaneous CT-guided lung biopsy: Multicenter case-control study. *Cardiovasc Intervent Radiol* 2014;37:1312-20.
3. Glodny B, Schönherr E, Freund MC, Haslauer M, Petersen J, Loizides A, et al. Measures to prevent air embolism in transthoracic biopsy of the lung. *AJR Am J Roentgenol* 2017;208:W184-W191.
4. Yoshida R, Yoshizako T, Nakamura M, Ando S, Maruyama M, Maruyama M, et al. Nonfatal air embolism complicating percutaneous CT-guided lung biopsy and VATS marking: Four cases from a single institution. *Clin Imaging* 2018;48:127-30.
5. Monnin-Bares V, Chassagnon G, Vernhet-Kovacsik H, Zargane H, Vanoverschelde J, Picot MC, et al. Systemic air embolism depicted on systematic whole thoracic CT acquisition after percutaneous lung biopsy: Incidence and risk factors. *Eur J Radiol* 2019;117:26-32.
6. Jang H, Rho JY, Suh YJ, Jeong YJ. Asymptomatic systemic air embolism after CT-guided percutaneous transthoracic needle biopsy. *Clin Imaging* 2019;53:49-57.