

Available online at www.sciencedirect.com

ScienceDirect

journal homepage: www.elsevier.com/locate/radcr

Case Report

Prenatal 3D-ultrasound diagnosis of isolated intrahepatic portal-systemic shunt with intact ductus venosus: A case report and literature review [☆]

Maxime Van Houdt, MD^{a,b,*}, Johannes van der Merwe, MD, PhD^{a,b}, Marc Gewillig, MD, PhD^c, Luc De Catte, MD, PhD^{a,b}

^aDepartment of Development and Regeneration, Cluster Woman and Child, Group Biomedical Sciences, KU Leuven University of Leuven, Belgium

^bDepartment of Obstetrics and Gynaecology, Division Woman and Child, University Hospitals Leuven, Leuven, Belgium

^cDepartment of Paediatric Cardiology, University Hospitals Leuven, Leuven, Belgium

ARTICLE INFO

Article history:

Received 24 January 2021

Revised 15 February 2021

Accepted 15 February 2021

Keywords:

Intrahepatic portosystemic shunt

Prenatal ultrasound

Umbilical-Portal Venous System

ABSTRACT

We present a case of isolated intrahepatic portosystemic shunts with an aorto- hepatic-umbilical connection; prenatally diagnosed with 3D Doppler flow in a 27-year-old patient at 27 weeks of gestation. Fetal karyotyping was normal, detailed evaluation of the venous and cardiovascular system showed a patent ductus venosus and no other abnormalities. These fetuses with isolated intrahepatic shunts are at risk for intra-uterine growth restriction (27%), all cases had a good prognosis with live births. Postnatal follow-up to control shunt closure is vital as persistent shunts may lead to subsequent complications.

© 2021 The Authors. Published by Elsevier Inc. on behalf of University of Washington.

This is an open access article under the CC BY-NC-ND license (<http://creativecommons.org/licenses/by-nc-nd/4.0/>)

Introduction

Congenital portosystemic venous shunts (CPSS) have been described in numerous cases, most commonly diagnosed in childhood or adult life. High resolution sonography and 3D Doppler flow applications have enabled the prenatal detection of liver arterio-venous malformations involving the umbilical-

portal venous system (UPVS). The UPVS is unique in the sense that it is derived from two different embryological precursors namely the portal and/or vitelline and umbilical veins.

Prenatally diagnosed isolated intrahepatic portosystemic venous shunts (IPSS) have been widely scattered among different case series with diverse presentations and variable outcomes. Most commonly they have been diagnosed in late pregnancy and involving the left portal vein and the left hepatic vein. We present a case and reviewed the literature with re-

[☆] Competing Interests: The author declares that there is no conflict of interest that could be perceived as prejudicing the impartiality of the research reported.

* Corresponding author.

E-mail address: maxime.vanhoudt@student.kuleuven.be (M. Van Houdt).

<https://doi.org/10.1016/j.radcr.2021.02.037>

1930-0433/© 2021 The Authors. Published by Elsevier Inc. on behalf of University of Washington. This is an open access article under the CC BY-NC-ND license (<http://creativecommons.org/licenses/by-nc-nd/4.0/>)

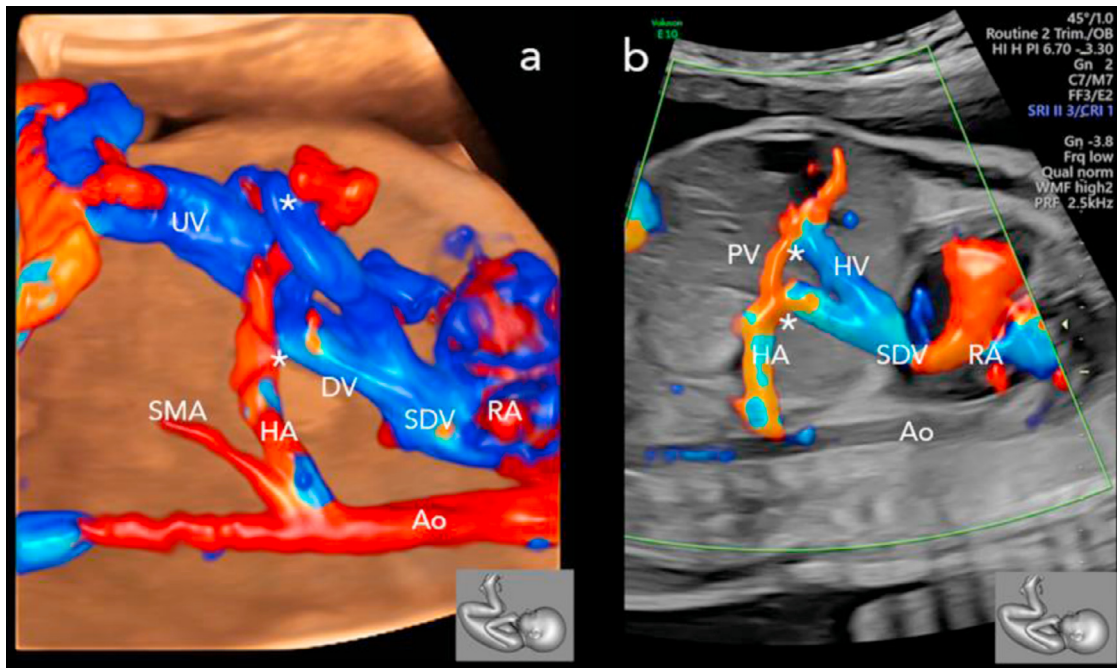


Fig. 1 – Twenty-seven-year-old primigravida at 27 weeks of gestation. (A) 3D multiplanar reconstruction & (B) 2D cross sectional sagittal colour doppler ultrasound evaluation of the portosystemic shunts (*). UV, umbilical vein; DV, ductus venosus; SMA, superior mesenteric artery; HA, hepatic artery; SDV, subdiaphragmatic vestibulum; RA, right atrium; Ao, aorta; PV, portal vein.

gards to prenatally detected isolated IPSS cases and their outcomes.

Case report

A 27-year-old primigravida was referred to our centre for a possible umbilical varicose vein dilatation (UVD) at 26 weeks and 6 days. She was in good health and had an uncomplicated pregnancy with a low risk NIPT test. The UVD of 6–9 mm was confirmed and on UPVS review multiple intrahepatic portal-systemic arterio-venous malformations were noted. Shunts were present between the portal- hepatic system incorporating the right portal vein and right hepatic vein; left inferior portal and middle hepatic vein and lastly the left inferior portal vein and left hepatic vein. The portal system, inferior vena cava and ductus venosus (DV) were present and drained separately and directly into the right atrium. Upon 3D Doppler reconstruction another shunt between the hepatic artery and the umbilical vein was also noted (Fig. 1).

The mesenteric and caval system appeared normal and no other abdominal anomalies were noted. In addition, there was mild cardiomegaly with a cardiothoracic ratio of 0.68, normal cardio-pulmonary vascular connections, grade 1 tricuspid regurgitation, and absence of any hydrops features. Just distal to the fetal umbilical cord insertion an UVD of 10 mm (normal average 6,0 mm, SD 1,0) [1] was noticed without turbulent flow (Fig. 2).

During weekly follow up visits, the fetus remained hemodynamically stable and no further anomalies were noted. At 29 weeks the dilatation of the UVD increased to 17.7 mm (normal average at 29 weeks, 6,6 mm SD 0,9 mm) [1] with presence of a small thrombosis of 5 × 6 mm (Fig. 2). Flow in the umbilical artery and vein remained laminar and non-obstructed. After multidisciplinary discussion the patient was admitted for daily CTG and Doppler monitoring and administration of antenatal corticosteroids. All features subsequently remained stable, and she was induced at 37 weeks. An uneventful delivery resulted in a girl of 2800 g being born who only needed short term CPAP support (<24 hours). Postnatal conventional cytogenetic analysis revealed a normal female karyotype.

Postnatal ultrasound and MRI angiography confirmed the prenatal findings noting multiple vascular malformations involving liver segments II (4 mm and 3 × 7 mm), IV (6 mm), VII (5,5 mm), VIII (6 mm). The hepatic veins and portal veins were of normal caliber with triphasic- and uniphasic flow respectively. There was no arterial hypertrophy nor hyperdynamic arterial flow in the liver (PSV 45 cm/s). Echocardiography noted a normal structured and functional heart with a mild left-right shunt and a patent foramen ovale, a persistent open arterial duct closed by day 21. Pathology of the umbilical cord confirmed the presence of a small thrombus.

The mother and child were discharged in good condition after 10 days. The hyperammonemia (maximal 138 mmol/l) partially resolved spontaneously by 3 weeks. But during her weekly follow ups the shunt persisted with mildly elevated hyperammonemia. At no point was any cardio-pulmonary or hemodynamic dysfunction noted. After 6 months the most

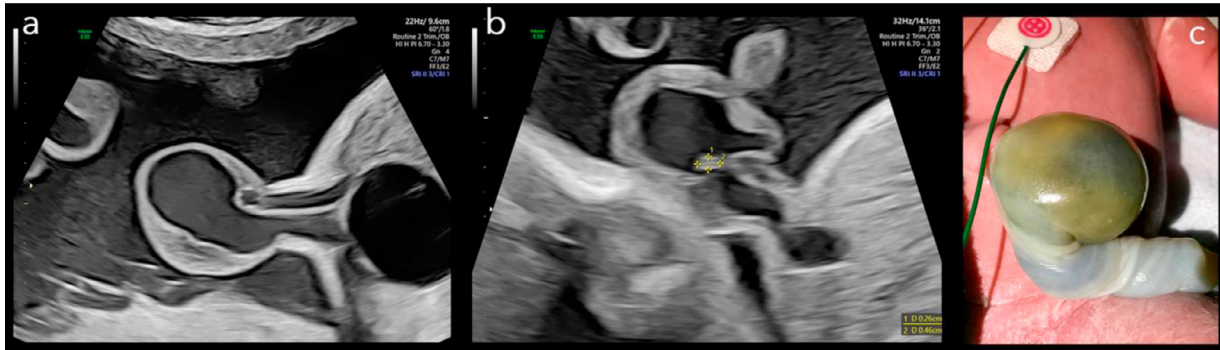


Fig. 2 – (A) 2D-ultrasound image of the dilated umbilical vein in a 27-year old primigravida at 29 weeks of gestation. **(B)** presence of the small thrombus. **(C)** postnatal image of the umbilical cord at day 1 in female neonate.

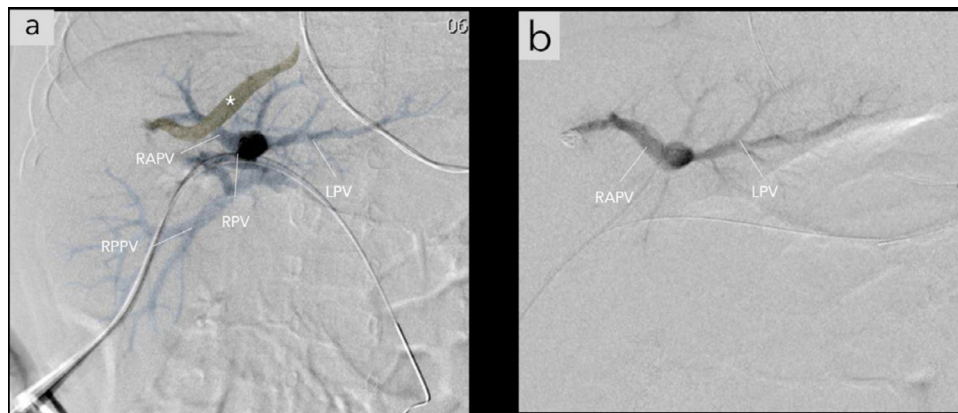


Fig. 3 – Six-month-old female patient. (A) Postpartal angiographic image of the portal-hepatic venous shunt (*) in liver segment IV. **(B)** Angiographic image after coiling. LPV, left portal vein; RAPV, right anterior portal vein; RPPV, right posterior portal vein; RPV, right portal vein.

prominent shunt in segment IV was coiled percutaneously (Fig. 3).

Discussion

CPSS are rare vascular anomalies connecting portal branches directly to systemic veins, bypassing the liver. The CPSS have been classified depending on the presence of intra and/or extrahepatic features and the presence or absence of the DV with most literature coming from the pediatric surgery field [2,3]. Achiron et al., presented a prenatal classification system with three subtypes: Type I, umbilical-systemic shunt; Type II, DV-systemic shunt; Type III, portal-systemic shunt [4]. Therefore, our case fits the description of a type IIIa, with an intrahepatic shunt between the portal venous system and the hepatic veins.

Review of the literature identified 22 prenatally detected cases of isolated IPSS with intact DV and normal karyotype, as summarized in Table 1. Median gestational age at diagnosis was 31 weeks (range 26-34 weeks). All resulted in a live birth

but 27% (6/22) was associated with in utero growth restriction (IUGR). Delle Chiaie et al., suggested that IUGR without hypoxia can be explained in these cases due to the impaired umbilical blood perfusion of the liver parenchyma [5]. In view of this finding, not only should IPSS be actively excluded in cases of unexplained IUGR, but inversely all CPSS cases should be monitored for altered fetal growth.

Since the majority of CPSS cases have been described in the context of multiple major abnormalities and syndromes, especially in the context of extrahepatic shunts [6], common associated cardiovascular anomalies must be excluded. In five cases of intrahepatic portosystemic shunts an additional aorto-portal-systemic connection was described. Two in context of chromosomal abnormalities, being trisomy 21 [7] and trisomy 17 [8]. While in those with a normal chromosomal profile, one had a left sided inferior vena cava [9], and two cases had an intrahepatic porto-systemic shunt with a coincidental shunt between the hepatic artery and de vena porta [10,11].

In 23% (5/22) there was no data reported on postnatal examinations to confirm the shunt. And in one case the shunt was not observed on postnatal ultrasound. In our case, the aorto-hepatic- umbilical connection was not confirmed post-

Table 1 – Review of prenatally diagnosed isolated intrahepatic portal-systemic shunt cases with DV present and normal karyotype.

	Case	Maternal Age (years)	GA (weeks) at diagnosis	Shunt origin and drainage	DV	Prenatal additional anomalies	Pregnancy outcome	Postnatal confirmation	Shunt outcome or resolution
Achiron et al. [4]	1	32.2 ±5.3	21	LPVm–RHV LPVi–MHV Absent RPV	Present	SUA. SVC to coronary sinus. Right clubfoot	Live birth	Confirmed	Spontaneous closure
	2		28	LPVs–LHV Absent RPV	Present	None	Live birth	Confirmed	Spontaneous closure
	3		27	LPVm–MHV	Present	None	Live birth	Confirmed	Spontaneous closure
	4		35	LPV–LHV	Present	None	Live birth	Confirmed	Spontaneous closure
	5		36	LPVi–MHV	Present	None	Live birth	Confirmed	Spontaneous closure
	6		35	LPV–LHV	Present	None	Live birth	Confirmed	Spontaneous closure
	7		31	LPVi–LHV	Present	None	Live birth	Confirmed	Spontaneous closure
Delle et al. [5]	8	32	33	LPV–HV cavernous	Present	Early IUGR Dilated echogenic Bowel.	Live birth	Confirmed	Spontaneous closure
	9		26	LPV–HV cavernous	Present	Early IUGR Hepatic calcifications, Right Hydronephrosis.	Live birth	Confirmed	Spontaneous closure
	10		23	PV–HV aneurysm	Present	IUGR, oligohydramnios	Live birth, 35 weeks	Confirmed (US)	Spontaneous closure at 3 m
Han et al. [10]	11	27.8 (20-40)	36	LPV–LHV with shunt HA–PV	Present	SGA	Live birth, 39,3 weeks	Confirmed (US)	coiling after 1 month hyperammonaemia
	12		28	LPV–LHV	Present	IUGR, Prominent umbilical vein	Live birth, 30 weeks	Confirmed (US)	Spontaneous closure 2 m
Jerabek-klestil et al. [13]	13	27.8 (20-40)	34	LPV–LHV	Present	Early IUGR	Live birth, 36w5d	Confirmed (US)	Spontaneous closure 8 m
	14		33	LPV–RHV/LHV/MHV	Present	DCDA twin IUGR in affected fetus	Live birth, PPRM 34weeks	Confirmed (US)	Spontaneous closure 28d
Achiron et al. [14]	15	27.8 (20-40)	22	RPV–HV	Present	None	Live birth	Confirmed (US)	Spontaneous closure 6 m
Wu et al. [11]	16		31	PV–LHV	Present	Cardiomegaly	Live birth	Not reported	Unknown
	17		25	PV–HV With HA–PV	Present	Cardiomegaly	Live birth	Not reported	

(continued on next page)

Table 1 (continued)

Case	Maternal Age (years)	GA (weeks) at diagnosis	Shunt origin and drainage	DV	Prenatal additional anomalies	Pregnancy outcome	Postnatal confirmation	Shunt outcome or resolution
18	43	31 ⁶	LPV-MHV	Present	None	Live birth	Not confirmed (US)	Not confirmed
19	26	26 ⁴	LPV-MHV	Present	None	Live birth	Confirmed (US)	Persistent after 7 m
20	39	31 ⁵	PV-MHV PV-RHV	Present	None	No data	Not reported	Unknown
21	31	36 ⁶	LPV-MHV LPV-RHV	Present	None	Live birth	No postnatal examinations	Unknown
22	43	28 ³	LPV-LHV RPV-RHV	Present	None	Live birth	No postnatal examinations	Unknown

GA, gestational age; DV, ductus venosus; IUGR, intra uterine growth restriction; LPV, left portal vein; LPVi, left portal vein inferior branch; LPVm, left portal vein medial branch; LPVs, left portal vein superior branch; MPV, main portal vein; RPV, right portal vein; HV, hepatic vein; RHV, right hepatic vein; LHV, left hepatic vein; MHV, medial hepatic vein; HA, hepatic artery; SUA, single Umbilical artery; SVC, superior vena cava; UV, Umbilical vein; BW, birth weight at delivery in grams; PPRM, preterm rupture of membranes; DGDA twin, dichorial diamniotic twin; SGA, small for gestational age; US, Ultrasound.

nately. Prenatal compensatory dilatation of the hepatic artery may have been misleading by indicating a more complex arteriovenous malformation.

Continuous post-natal re-evaluations are of vital importance since persistent portosystemic shunts can lead to hepatic encephalopathy, hepatopulmonary syndrome, and pulmonary hypertension. Neonates should be monitored until spontaneous shunt closure occurs, in IPSS patients this mostly happens during the first year of life. In this case series, only one case needed operative closure. Operative closure should be considered in symptomatic cases or if closure does not occur after the first year of life [12].

In conclusion, this case highlights the importance of a standardized examination of the fetal venous system during second trimester ultrasound fetal structural review. Fetuses that present with IPSS anomalies need detailed evaluation of the entire venous and cardiovascular system, and high frequency monitoring for IUGR. Patients can be reassured that most fetuses with IPSS and present DV have a normal karyotype and will result in a live term born infant.

Supplementary materials

Supplementary material associated with this article can be found, in the online version, at doi:10.1016/j.radcr.2021.02.037.

REFERENCES

- [1] Weissman, et al. Sonographic measurements of the umbilical cord and vessels during normal pregnancies. *J Ultrasound Med* 1994;13(11–14).
- [2] Park JH, Cha SH, Han JK, Han MC. Intrahepatic portosystemic venous shunt. *AJR Am J Roentgenol* 1990;155:527–8.
- [3] Lautz TB, Tantemsapya N, Rowell E, Superina RA. Management and classification of type II congenital portosystemic shunts. *J Pediatr Surg* 2011;46:308–14.
- [4] Achiron R, Kivilevitch Z. Fetal umbilical-portal-systemic venous shunt: in-utero classification and clinical significance. *Ultrasound Obstet Gynecol* 2016;47:739–47.
- [5] Delle Chiaie L, Neuberger P, Von Kalle T. Congenital intrahepatic portosystemic shunt: prenatal diagnosis and possible influence on fetal growth. *Ultrasound Obstet Gynecol* 2008;32:233–5.
- [6] Papamichail M, Pizaniyas M, Heaton N. Congenital portosystemic venous shunt. *Eur J Pediatr* 2018;177:285–94.
- [7] Hartung J, Chaoui R, Kalache K, Tennstedt C, Bollmann R. Prenatal diagnosis of intrahepatic communications of the umbilical vein with atypical arteries (A-V fistulae) in two cases of trisomy 21 using color Doppler ultrasound. *Ultrasound Obstet Gynecol* 2000;16:271–4.
- [8] Iliescu DG, Ruican D, Nagy R, Burada F. Aorta-umbilical vein fistulae in fetus with trisomy-17 mosaicism. *Ultrasound Obstet Gynecol* 2020;55:419–21.
- [9] Zhou J, Zhou Q, Peng Q, Zeng S. Prenatal diagnosis of Aorta-Porto-Umbilical vein fistulas with left-sided inferior vena cava. *AJP Rep* 2016;6:e59–61.
- [10] Han BH, Park SB, Song MJ, Lee KS, Lee YH, Ko SY, et al. Congenital portosystemic shunts: prenatal

- manifestations with postnatal confirmation and follow-up. *J Ultrasound Med* 2013;32:45–52.
- [11] Wu Y, Zhou L, Chen L. Correlations among congenital hepatic shunt, absent ductus venosus, and umbilical vein shunt revealed by prenatal ultrasound. *Fetal Diagn Ther* 2020;47:237–44.
- [12] Sokollik C, Bandsma RH, Gana JC, van den Heuvel M, Ling SC. Congenital portosystemic shunt: characterization of a multisystem disease. *J Pediatr Gastroenterol Nutr* 2013;56:675–81.
- [13] Jerabek-Klestil S, Brantner C, Nehoda R, D'Costa E, Campegi S, Scheier M. Prenatal sonographic diagnosis of intrahepatic portosystemic shunts. *J Ultrasound Med* 2014;33:543–6.
- [14] Achiron R, Gindes L, Kivilevitch Z, Kuint J, Kidron D, Boyanover Y, et al. Prenatal diagnosis of congenital agenesis of the fetal portal venous system. *Ultrasound Obstet Gynecol* 2009;34:643–52.
- [15] Wang Y, Yan Y, Yang Z, Wei J, Liu G, Pei Q. Prenatal diagnosis of congenital portosystemic shunt: a single-center study. *J Obstet Gynaecol Res* 2020;46:1988–93.