

Contents lists available at [ScienceDirect](http://www.sciencedirect.com)

## International Journal of Surgery Case Reports

journal homepage: [www.casereports.com](http://www.casereports.com)

## Pericardiocentesis followed by thoracotomy and repair of penetrating cardiac injury caused by nail gun injury to the heart



Vasu Chirumamilla, Kartik Prabhakaran\*, Petrone Patrizio, John A. Savino, Corrado P. Marini, Zobair Zoha

Division of Trauma, Acute Care Surgery and Surgical Critical Care, Department of Surgery New York Medical College, Westchester Medical Center University Hospital, Valhalla, NY, United States

## ARTICLE INFO

## Article history:

Received 6 March 2016

Received in revised form 11 April 2016

Accepted 11 April 2016

Available online 19 April 2016

## Keywords:

Nail gun  
Pericardiocentesis  
Trauma  
Thoracotomy  
Cardiac injury

## ABSTRACT

**INTRODUCTION:** Work site injuries involving high projectile tools such as nail guns can lead to catastrophic injuries. Generally, penetrating cardiac injuries are associated with a high mortality rate.

**PRESENTATION OF CASE:** A construction worker was brought to the emergency room having sustained a nail gun injury to the chest. The patient was hypotensive, tachycardic with prominent jugular venous distention, and had a profound lactic acidosis. Bedside ultrasound confirmed the presence of pericardial fluid. Pericardiocentesis was performed twice using a central venous catheter inserted into the pericardial space, resulting in improvement in the patient's hemodynamics. Thereafter he underwent left anterolateral thoracotomy and repair of a right atrial laceration. He recovered uneventfully.

**DISCUSSION:** Penetrating cardiac injuries caused by nail guns, although rare, have been previously described. However, pericardiocentesis, while retaining a role in the management of medical causes of cardiac tamponade, has been reported only sporadically in the setting of trauma. We report a rare case of penetrating nail gun injury to the heart where pericardiocentesis was used as a temporizing measure to stabilize the patient in preparation for definitive but timely operative intervention.

**CONCLUSION:** We propose awareness that pericardiocentesis can serve as a temporary life saving measure in the setting of trauma, particularly as a bridge to definitive therapy. To our knowledge, this represents the first reported case of catheter pericardiocentesis used to stabilize a patient until definitive repair of a penetrating cardiac injury caused by a nail gun.

© 2016 The Authors. Published by Elsevier Ltd. on behalf of IJS Publishing Group Ltd. This is an open access article under the CC BY-NC-ND license (<http://creativecommons.org/licenses/by-nc-nd/4.0/>).

### 1. Introduction

The frequency of accidental injuries sustained as a result of pneumatic and explosive powered nail guns has been reported to be increasing [1]. The risk of injury is increased amongst novice users, as lack of training and experience have been shown to be independent risk factors [2]. The mechanism of injury can be secondary to ricochet effect or from inappropriate trigger pull. While most nail gun injuries are survivable, penetrating cardiac injuries from nail guns have been reported as infrequent occurrences associated with a high morbidity and mortality [3]. In most of the reported cases of cardiac nail gun injuries, survival of the patients is postulated to result from the actual nail wedging into the tissue providing locoregional tamponade. The described treatment of

these injuries typically has involved median sternotomy or anterolateral thoracotomy, followed by repair of the cardiac injury [4]. However, cardiac tamponade resulting from penetrating cardiac injuries presents the added problem of associated hemodynamic instability. Cardiac tamponade is a life threatening emergency which requires decompression of the pericardium in addition to treatment of the underlying etiology. The choice between percutaneous and open drainage of the pericardium is based upon the etiology of tamponade and underlying pathophysiology. Pericardiocentesis is a well-known and accepted technique in providing relief of tamponade, but has traditionally been reserved for atraumatic etiologies [5]. Pericardiocentesis has also been described in the successful treatment of cardiac tamponade arising from blunt traumatic injuries [6]. The management of penetrating cardiac injuries has evolved to favor emergency department thoracotomy for the hemodynamically unstable or pulseless patient, and median sternotomy/anterolateral thoracotomy for the hemodynamically stable patient [7]. There are few studies that endorse the utility of pericardiocentesis in the setting of penetrating cardiac injuries. Jones et al. report a case series where emergency room pericardial drainage for penetrating cardiac injuries had acceptably low mor-

\* Corresponding author at: Division of Trauma, Acute Care Surgery & Surgical Critical Care, Department of Surgery New York Medical College, Westchester Medical Center University Hospital, 100 Woods Road, Taylor Pavilion, Suite E-150, Valhalla, NY 10595, United States.

E-mail address: [Kartik.Prabhakaran@wmchealth.org](mailto:Kartik.Prabhakaran@wmchealth.org) (K. Prabhakaran).

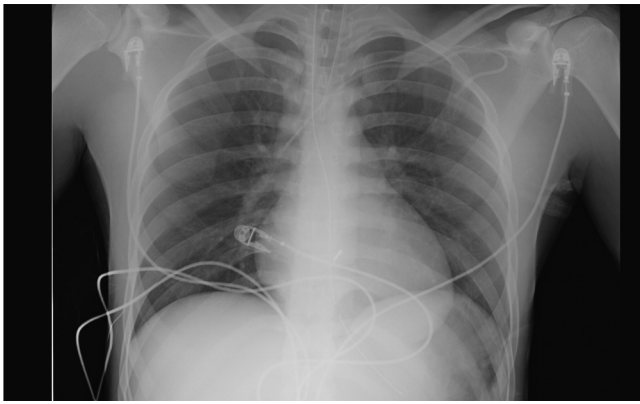


Fig. 1. Foreign body over the cardiac silhouette (arrow).

tality rates when used as a bridge to definitive surgery [8]. Herein, we describe a unique case where penetrating cardiac injury with nail gun resulted in cardiac tamponade effectively treated with emergency room pericardiocentesis with a central venous catheter allowing for repeated aspiration, followed by operative anterolateral thoracotomy with repair of the cardiac injury.

## 2. Presentation of case

A 20 year old male was brought by his relative to our emergency department after having sustained a nail gun injury to his precordium at a construction site. On arrival, the patient was lethargic and noted to be tachycardic with a heart rate of 132 beats per minute and a blood pressure of 54/43 mm Hg. Primary survey revealed an intact airway with equal bilateral breath sounds, and faint peripheral pulses. Physical examination revealed a punctate wound in the anterior midline of his chest overlying his sternum with no foreign bodies, and prominent bilateral jugular venous distention. No other injuries were noted on secondary survey. Endotracheal intubation was performed and central venous access obtained (left subclavian and right femoral veins), after which our massive transfusion protocol was initiated. Arterial blood gas demonstrated a severe lactic acidosis (serum lactate 6.9). A chest X-ray was obtained which showed a foreign body overlying the cardiac silhouette (Fig. 1). A bedside ultrasound was performed, demonstrating a pericardial effusion (Fig. 2).

A decision was made immediately to take the patient to the operating room. Within the trauma bay, a pericardiocentesis was performed with aspiration of 100 cc of blood yielding a transient decrease in tachycardia and concomitant increase in blood pressure, as well as improved ventricular contractility on bedside echocardiogram. As a temporizing measure to provide further drainage, a central venous catheter was placed into the pericardium which drained an additional 100 cc of blood upon repeated aspiration (Fig. 3). Resuscitation with blood products was ongoing as the patient was taken emergently to the operating room. A left anterolateral thoracotomy was performed after which longitudinal pericardotomy provided immediate relief of tamponade. The nail was removed from the right atrium after which a brief period of cardiac arrest (5 s) was relieved by open cardiac massage. A 1 cm laceration of the right atrium was repaired with interrupted pledgeted #1 Ethibond suture. A 32 French chest tube was left in the left pleural cavity, and the chest was closed. In total, the patient received four units of packed red blood cells, four units of fresh frozen plasma and four liters of lactated ringers solution. Post-operatively, the patient was extubated and his chest tube was removed. He made an uneventful recovery and was discharged home.

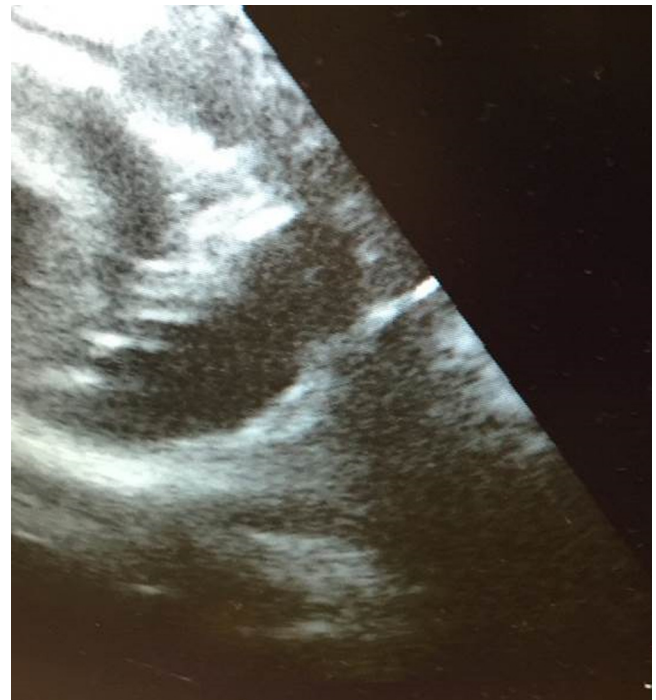

Fig. 2. A bedside ultrasound demonstrating a pericardial effusion.

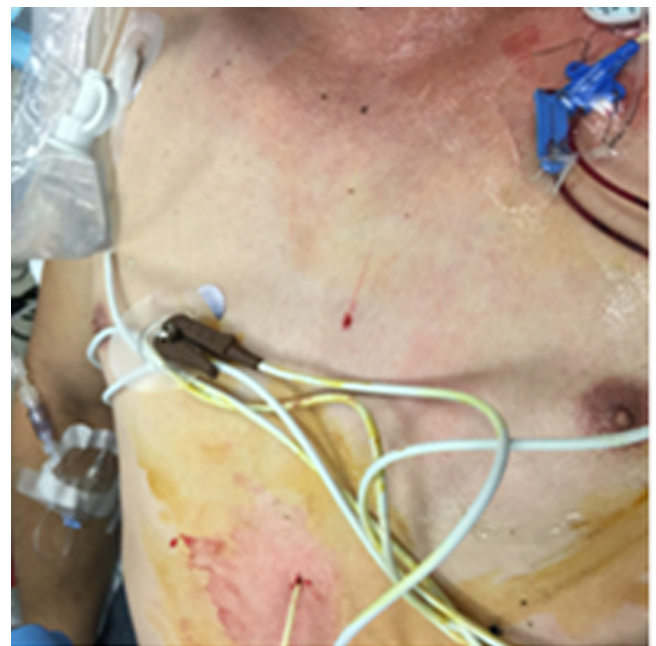

Fig. 3. Central venous catheter inserted for pericardiocentesis.

## 3. Discussion

Although predominant involving the extremity, nail gun injuries pose a significant threat to construction workers and novice users with the potential of significant morbidity and mortality. Modification of nail gun design and improvement of training and safety measures at construction sites remain important public health measures to reduce the incidence of such injuries. The fatality of nail gun injuries to the heart is attributable to several factors including the difficulty in recognizing the injury itself, particularly in the absence of external foreign bodies [4]. Entry points into the skin

can be barely visible and often do not reflect the severity of the underlying injury. Penetrating cardiac injuries have a high mortality rate amenable to reduction only by early recognition and early intervention. Therefore, a high index of suspicion is important. Tamponade physiology may or may not be readily apparent. When cardiac tamponade is present, early decompression followed by repair of the cardiac injury is essential in maximizing the chances for a favorable outcome. The rarity of these injuries precludes a fail-safe algorithm for treatment. The cardiac component of the focused assessment using sonography for trauma (FAST) is a valuable imaging modality in the emergent setting to evaluate for cardiac motion and pericardial fluid, particularly in cases such as ours where the nature of the injury is unclear. In the case of the patient presented herein, both portable chest X-ray as well as cardiac ultrasound were useful in aiding in the diagnosis of cardiac injury and tamponade. While emergency room thoracotomy would have been justified given the patient's hemodynamic instability, prompt pericardiocentesis allowed for safe transfer of the patient to the operating room for thoracotomy and definitive repair under controlled and sterile conditions. The insertion of a central venous catheter into the pericardium allowed for sustained drainage and repeated aspiration of the pericardial sac precluding recurrent tamponade en route to the operating room. Pericardiocentesis is well described as an important step in the algorithm of managing medical causes of cardiac tamponade. Although it has been reported sporadically as having a role in the management of traumatic causes of tamponade, we believe that our case highlights a role for pericardiocentesis in the appropriate setting as a life-saving, temporizing measure until definitive repair of penetrating cardiac injuries. Particularly in rural and community hospital settings where a surgeon may not be immediately available, survival of the patient depends both upon prompt recognition of these seemingly occult injuries, as well as the timeliness of temporizing, albeit lifesaving measures such as paracentesis.

#### 4. Conclusions

Nail gun injuries to the heart are rare but frequently fatal due to the difficulty in establishing a diagnosis and the severity of the injury itself. Their prevalence remains an issue amongst industrial site workers, and prompt recognition and immediate intervention are vital in preventing mortality. Our reported case highlights the subtlety of presentation amongst nail gun injuries to the heart and should increase the reader's awareness of such injuries and the difficulties that can exist in arriving at a prompt diagnosis. Cardiac tamponade in the setting of trauma must be considered in the differential diagnosis of the hemodynamically unstable patient with penetrating injuries. Moreover, while emergency department thoracotomy remains the gold standard in the treatment of penetrating cardiac injury in the unstable patient, pericardiocentesis (particularly with a catheter which can be used for sustained and/or repeated drainage) can be a potentially life-saving adjunct to definitive repair of the injury and must be considered to be part of the treatment algorithm particularly in rural and community hospital settings where surgeon availability is variable.

#### Conflicts of interest

There are no conflicts of interest.

#### Open Access

This article is published Open Access at [sciedirect.com](http://sciedirect.com). It is distributed under the [IJSCR Supplemental terms and conditions](#), which permits unrestricted non commercial use, distribution, and reproduction in any medium, provided the original authors and source are credited.

#### Sources of funding

No sponsors or funding sources were involved in the preparation of this manuscript.

#### Ethical approval

This case report is not a research study.

#### Consent

Written informed consent was obtained from the patient for publication of this case report and accompanying images. A copy of the written consent is available for review by the editor-in-chief of this journal on request.

#### Authors contribution

Dr. Zoha was the treating physician for the patient. Drs. Prabhakaran, Chirumamilla, and Petrone contributed to the manuscript writing. Drs. Marini and Savino contributed to revisions of the manuscript.

#### Guarantor

Drs. Zoha and Prabhakaran are the guarantors.

#### References

- [1] A.D. Temple, F.M. Fesmire, D.C. Seaberg, H.W. Severance, Cardiac injury due to accidental discharge of nail gun, *J. Emerg. Med.* 44 (2) (2013) e161–e163.
- [2] H.J. Lipscomb, J.M. Dement, J. Nolan, D. Patterson, Nail gun injuries in apprentice carpenters: risk factors and control measures, *Am. J. Ind. Med.* 49 (2006) 505–513.
- [3] L.R. Guo, M.L. Myers, Penetrating cardiac injury: the nail gun, a potentially dangerous tool, *Can. J. Surg.* 51 (1) (2008) E7–E8.
- [4] L. Nölke, P. Naughton, C. Shaw, J. Hurley, A.E. Wood, Accidental nail gun injuries to the heart: diagnostic, treatment, and epidemiological considerations, *J. Trauma* 58 (1) (2005) 172–174.
- [5] A.D. Ristić, M. Imazio, Y. Adler, A. Anastasakis, L.P. Badano, A. Brucato, A.L. Caforio, O. Dubourg, P. Elliott, J. Gimeno, T. Helio, K. Klingel, A. Linhart, B. Maisch, B. Mayosi, J. Mogensen, Y. Pinto, H. Seggewiss, P.M. Seferović, L. Tavazzi, W. Tomkowski, P. Charron, Triage strategy for urgent management of cardiac tamponade: a position statement of the European Society of Cardiology Working Group on Myocardial and Pericardial Diseases, *Eur. Heart J.* 35 (34) (2014) 2279–2284.
- [6] O.1 Ozer, I. Sari, V. Davutoglu, C. Yildirim, Pericardial tamponade consequent to a dynamite explosion: blast overpressure injury without penetrating trauma, *Texas Heart Inst. J.* 36 (3) (2009) 259–260.
- [7] M.J. Seamon, E.R. Haut, K. Van Arendonk, R.R. Barbosa, W.C. Chiu, C.J. Dente, N. Fox, R.S. Jawa, K. Khwaja, J.K. Lee, L.J. Magnotti, J.A. Mayglothling, A.A. McDonald, S. Rowell, K.B. To, Y. Falck-Ytter, P. Rhee, An evidence-based approach to patient selection for emergency department thoracotomy: a practice management guideline from the Eastern Association for the Surgery of Trauma, *J. Trauma Acute Care Surg.* 79 (1) (2015) 159–173.
- [8] T.S. Jones, C.C. Burlew, R.T. Stovall, F.M. Pieracci, J.L. Johnson, G.J. Jurkovich, E.E. Moore, Emergency department pericardial drainage for penetrating cardiac wounds is a viable option for stabilization, *Am. J. Surg.* 207 (6) (2014) 931–934.