

Molecular confirmation of alpha 1-antitrypsin deficiency in liver transplant setting: A province-wide experience

 Hussam Bukhari^{1,2},  Andre Mattman³,  Gordon Ritchie³,  Laura Burns³,  Eric Yoshida⁴,  David Schaeffer¹,  Hui-Min Yang³

¹King Abdulaziz University Hospital, King Abdulaziz University, Jeddah, Saudi Arabia; ²Department of Pathology and Laboratory Medicine, Vancouver General Hospital, Vancouver, Canada; ³Department of Pathology and Laboratory Medicine, Providence Health Care, University of British Columbia, Vancouver, Canada; ⁴Division of Gastroenterology, Department of Medicine, Vancouver General Hospital, University of British Columbia, Vancouver, Canada

Abstract

Background and Aim: Patients suspected of Alpha 1-Antitrypsin (A1AT) abnormality based on low serum concentration are routinely confirmed through polymerase chain reaction (PCR) testing of peripheral blood. Genotyping formalin-fixed paraffin-embedded (FFPE) tissue is a novel approach that could aid in detecting variant A1AT. We performed qPCR on FFPE liver explants with Periodic Acid Schiff after Diastase (PASD)- and A1AT-positive globules to confirm and estimate the frequency of A1AT deficiency in transplant cases.

Materials and Methods: Eighteen (12.68%) of 142 patients with end-stage liver disease showed PASD/A1AT positive globules. FFPE of the explants was tested through qPCR to detect S and Z alleles. A second age- and sex-matched control group consisting of five liver transplant patients with negative globules was included in the study.

Results: qPCR assay was successful with all the samples meeting QC parameters. All patients included in the study elucidated Z allele variants; 2 homozygous (11.1%) and 16 heterozygous (88.9%). The control group demonstrated normal wild-type MM allele.

Conclusion: Screening for A1AT deficiency using serum levels is not sufficiently sensitive to detect deficiency, especially in carriers. If A1AT testing was not performed preoperatively and the risk is high based on the PASD/A1AT-positive globules in the explants, then molecular testing of FFPE tissue can be a viable method for confirming the diagnosis.

Keywords: Alpha-1 antitrypsin; British Columbia; FFPE PCR; gene frequency; liver transplant; M and Z allele.

Introduction

Alpha-1 antitrypsin (A1AT) deficiency is an inherited autosomal recessive multi-system disorder that primarily affects the liver and lungs.^[1] The disease is caused by a mutation in the *SERPINA1* gene located at

locus 14q32.13. The *SERPINA1* gene encodes for the A1AT protein, a major plasma serine protease inhibitor that is mostly synthesized and secreted by the liver.^[2] It performs multiple physiological functions including protection of the lungs from proteolytic elastases released by white blood cells in response to environmental factors (e.g., smoking) and other inflammatory processes,^[3] and potentially even the severity of SARS CoV-2 infection.^[4] Multiple point mutations at the A1AT gene locus result in an enzyme that is structurally and functionally different from wild-type (M) allele. Each mutated allele harbors variable risk of lung or liver disease phenotype, ranging from silent to severe. Primarily in the Z allele, these mutations produce a misfolded A1AT protein that accumulates in the endoplasmic reticulum of the hepatocytes making them susceptible to environmental stressors with subsequent liver injury and fibrosis.^[5] This accumulated A1AT protein is not secreted in the peripheral blood and therefore, the serum concentration can be used as screening tool for A1AT deficiency.^[6] The accumulated A1AT in the hepatocytes from the Z allele can be highlighted under light microscopy in a periportal distribution using Periodic Acid Schiff after Diastase digestion (PASD) or via A1TT immunohistochemistry.^[7]

The Z allele (NM_000295.4: c.1096G>A, p.Glu366Lys) is the most common disease-causing allele, with up to 98% of A1AT deficiency harboring the Z allele.^[3] The homozygous form (ZZ) accounts for most of the severe cases affecting both the liver and lungs and in certain cases, necessitates transplantation. Heterozygous carriers of Z allele (MZ) are healthy in most cases; however, they still retain a slight risk of chronic liver damage, and to a lesser degree, lung disease.^[8,9] In the liver, this is demonstrated by the presence of PASD/A1AT positive globules.^[7] The second most common allele is the S allele (NM_000295.4: c.863A>T, p.Glu288Val).^[10] In addition, a few other rare alleles are also described, some of which show normal M phenotype on isoelectric focusing, such as the M Malton and M Duarte.^[11] Those alleles are more common in non-Northern European populations and can demonstrate a certain risk of disease expression.^[12] Non-Z variants of A1AT can cause disease if present in association with the Z allele (such as SZ), albeit at a much lesser expression than homozygous Z.^[13]

Disease prevalence is variable and substantially different in each population. Unfortunately, accurate data are scarce and outdated as many cases are left undiagnosed due to carrier states and the incomplete penetrance of the disease. There is however an increase in the prevalence of Z and S allele variants among individuals of Northern European descent.^[3] In British Columbia, approximately 230,000 individuals are carriers of Pi*S allele (2.6%), while 115,000 are carriers of the Pi*Z allele (1.3%).^[14]

How to cite this article: Bukhari H, Mattman A, Ritchie G, Burns L, Yoshida E, Schaeffer D, Yang HM. Molecular confirmation of alpha 1-antitrypsin deficiency in liver transplant setting: A province-wide experience. *Hepatology Forum* 2024; 5(2):68–72.

Received: December 19, 2022; **Revised:** May 15, 2023; **Accepted:** July 23, 2023; **Available online:** December 07, 2023

Corresponding author: Hussam Bukhari; Department of Pathology and Laboratory Medicine, Vancouver General Hospital, Vancouver, Canada
Phone: +1 214-205-6979; **e-mail:** hussambukhari@gmail.com



OPEN ACCESS
This work is licensed under a Creative Commons Attribution-NonCommercial 4.0 International License.

Hepatology Forum - Available online at www.hepatologyforum.org



A1AT deficiency has a bimodal distribution with differing presentations between adults and infants. It presents in infancy as neonatal hepatitis/cholestasis and in adulthood as chronic liver disease and/or chronic lung disease.^[8] In the liver, it can also result in hepatocellular carcinoma and not uncommonly and fulminant liver failure.^[1] Liver and lung disease phenotypes occur independently and may present at different ages in the same individual.^[15] Various algorithms are available and can be utilized to test populations for A1AT deficiency. British Columbia adapts a modified version of a protocol by Snyder et al.^[16] whereby serum A1AT level is used as an initial test followed by polymerase chain reaction (PCR) analysis and/or isoelectric focusing of peripheral blood if the serum level is lower than 1.15 g/L. Gene sequencing is to be performed if PCR or isoelectric focusing yield ambiguous results. No specific therapy is available for A1AT deficiency yet, and the mainstay of management remains supportive with emphasis on delaying or preventing the need for transplantation. Liver transplantation is the only definitive therapy and leads to phenotypic conversion.^[15] New emerging gene therapies are gaining momentum such as the use of siRNA and stem cell technology to assist in reversing genetic aberrations in the A1AT gene.^[17]

It is not uncommon to under detect A1AT-positive globules in liver explants of patients with clinically presumed liver pathology etiologies other than A1AT when either the serum A1AT is within normal range or when A1AT is not tested preoperatively. This may result in an unsatisfying diagnosis of “cryptogenic” liver cirrhosis in cases with homozygous or heterozygous mutant alleles, resulting in the loss of opportunity to diagnose, and subsequently screen the family of affected individuals. With the advent of advanced molecular testing, genotyping of A1AT through molecular testing of formalin-fixed paraffin-embedded (FFPE) tissue is a novel and theoretically feasible approach if pre-operative assessment was not conducted and the suspicion of A1AT deficiency is high based on histological assessment.^[18]

In this study, we performed real-time PCR assay of FFPE liver explant tissue in specimens that showed PAS-positive, diastase-resistant, and A1AT immunoreactive globules to estimate the frequency of A1AT deficiency in liver transplant patients in the province of British Columbia.

Materials and Methods

The study had research ethics approval by the institutional review boards (UBC Ethics #H19-02913). All the patients who received liver transplant surgery for end-stage liver disease in British Columbia, Canada, from May 1, 2016, to May 1, 2019, were accrued from the electronic medical records of the only liver transplant center in British Columbia. A total of 142 patients had liver transplants performed during the stated period, including two cases preoperatively attributed to A1AT deficiency. The mean age at transplant is 54 (33-72). Of those, 91 cases had no post-operative PASD done and thus were performed for the purpose of this study. Of the 142, 18 patients (12.68%) demonstrated periportal globules positive for PASD (Fig. 1, b) and A1AT immunohistochemical stain (Fig. 1c). Interestingly, one of the cases (case #07) that was negative for PASD+ globules on the pre-transplant biopsy demonstrated the globules on the hepatectomy sections. Another case (case #18) was identified on a failed liver allograft. Of the 18 patients, 7 patients (38.9%) had normal pre-transplant A1AT serum levels, 3 patients (16.7%) had a low serum A1AT levels, and 8 patients (44.4%) were not tested preoperatively for A1AT serum concentration. Normal serum A1AT level is defined as a concentration ranging from 0.9 to 2.0 g/dL. The etiologies attributed to transplantation are detailed in Table 1.

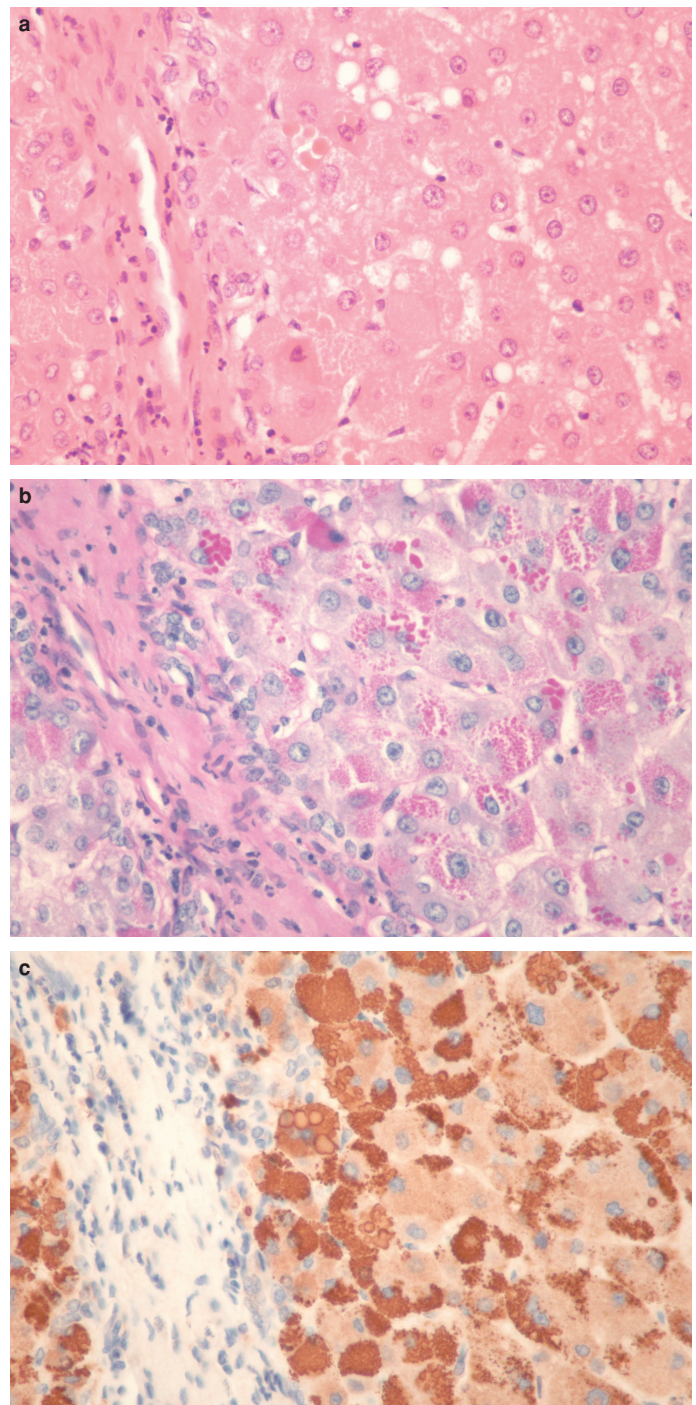


Figure 1. Hematoxylin and Eosin (H&E) stain (a), Periodic Acid Schiff after diastase digestion, (b) and Alpha-1 Antitrypsin immunohistochemical stain, (c) show Alpha-1 Antitrypsin globules from case 8 (40X magnification).

The 18 (n=18) patients were selected for targeted genotyping through real-time PCR amplification and melting curve analysis of FFPE hepatic explant tissue to detect S and Z allele variants. Z Allele is defined as (NM_000295.4:c.1096G>A, p.Glu366Lys), whereas the S allele is defined as (NM_000295.4: c.863A>T, p.Glu288Val). Sanger sequencing of rare alleles variants is to be performed in cases with a negative PCR result.

Table 1. Summary of the clinical and molecular findings

Case#	Age	Sex	Pre-transplant serum A1AT levels (g/L)	Clinical diagnosis	A1AT allele variant
1	44	F	0.16	Autoimmune hepatitis	ZZ
2	54	F	0.22 and 0.18	A1AT Deficiency and alcoholic liver disease	ZZ
3	33	F	0.69 and 0.71	Primary biliary cholangitis and A1AT deficiency	MZ
4	65	M	1.01 and 0.93	Alcoholic liver disease	MZ
5#	40	M	1.2	Alcoholic liver disease	MZ
6	38	M	0.88, 0.75, and 0.51	Alcoholic liver disease	MZ
7	48	F	1.08	Alcoholic liver disease	MZ
8	39	M	Not performed	Alcoholic liver disease	MZ
9	67	M	Not performed	Alcoholic liver disease	MZ
10#	71	M	1.16	Non-alcoholic Steatohepatitis	MZ
11	56	M	0.99	Non-alcoholic Steatohepatitis	MZ
12	70	F	0.93	Non-alcoholic Steatohepatitis	MZ
13	56	M	Not performed	Non-alcoholic Steatohepatitis	MZ
14	58	M	Not performed	Non-alcoholic Steatohepatitis	MZ
15	56	F	0.94	Chronic hepatitis C	MZ
16	72	M	Not performed	Chronic hepatitis C	MZ
17	48	M	Not performed	Chronic hepatitis C	MZ
18	63	F	Not performed	Chronic transplant rejection and hepatitis C (19 years apart)	MZ

F: Female; M: Male; A1AT: Alpha 1-antitrypsin; g/L: Grams per deciliter; #: Genotyped and confirmed preoperatively.

In addition, a second age- and sex-matched control group consisting of five patients who also received liver transplants during the same period but who did not demonstrate PASD-positive globules were also included. All the five cases are of European descent and therefore have the highest risk of Z-allele. The mean age for the control population at the time of transplant is 50 (27–71). Given the absence of the PASD-positive globules, the Z variant was not expected in any of the five cases; these were tested primarily to rule out technical issues that could potentially lead to the false positive detection of Z allele in the FFPE liver samples. The predicted allele frequency, from the BC population (1.3%), was used as the comparator prevalence rate for Z containing genotypes (2.6%), the pre-requisite for most PASD-positive hepatocyte inclusions. Descriptive and simple statistical tests, that do not require a commercial statistical software package, were employed.

To process the FFPE tissue, 0.5 µm sections of formalin-fixed paraffin-embedded hepatic tissue were placed in an Eppendorf tube with 100 µL of 0.1 mm glass beads (Biospec), 700 µL of PBS, 0.36% SDS and 15U of Proteinase K (Roche), and incubated at 55°C overnight with shaking. The sample was bead lysed in a Qiagen TissueLyser LT at 50 setting for 3 min. After 5 s centrifugation, 400 µL of supernatant was extracted on the MagNA Pure compact (Roche, Pleasanton CA), and eluted in 50 µL. Targeted genotyping was performed using real-time PCR amplification and melting curve analysis to detect the S and Z alleles.

Results

Real-time PCR assay of the FFPE tissue was successful with the PCR products robustly amplifying and meeting quality control parameters in each case. All the patients included in the study elucidated Z allele variants; two of which are homozygous (11.1%) and 16 heterozygous (88.9%). None showed S allele. All the cases in the control group demonstrated normal wild-type MM allele. This is summarized as follows:

- PASD-positive samples: n=18/142 or 12% (7.6%–19%); all tested positive for the Z allele
- Expected maximum PASD-positive rate based on predicted BC population prevalence (ethnicity dependent Z allele frequency, based on Canadian 2016 Census and gnomAD population frequency=2.6%)
- PAS-negative samples (n=5; all tested negative for the S and Z alleles).

Discussion

It is not uncommon to encounter cases of hepatic transplant whereby the liver shows exuberant periportal PASD+ globules highly suspicious for A1AT accumulation, with subsequent confirmation through A1AT immunohistochemistry.^[7,19] A majority of these cases had either a negative pre-operative screening result (i.e., a serum concentration within normal range) or no pre-transplant screening for A1AT deficiency. In our province, a negative A1AT screening result usually translates to no further clinical testing (in the absence of additional information, e.g., PASD-positive inclusions) and likely contributes to an underdiagnoses of heterozygous A1AT deficiency and a missed opportunity to screen family members of those carriers. Therefore, A1AT serum testing is not sufficiently sensitive to detect all heterozygous cases or cases with rare allele variants which are more difficult to detect (e.g., M Malton allele). Recent studies suggest that heterozygous states (e.g., MZ) can still show subtle liver phenotype which may, solely or additively, lead to the development of chronic liver disease and subsequent cirrhosis requiring transplantation, further cementing the need to detect carriers of abnormal alleles and perform subsequent familial testing.^[8,9]

Our aim is to assess if such cases can be molecularly tested postoperatively on the liver explant specimen and therefore capture abnormal A1AT alleles that were not identified before transplantation.

The results of our study show that all of the cases that are positive for A1AT globules expectedly showed Z allele, both heterozygous and homozygous. This suggests that FFPE PCR testing of explant tissue is a valid method for the detection of Z allele and that PASD+ globules are highly reliable predictor for the Z alleles. It also demonstrates that pre-operative A1AT serum testing alone is not sufficiently sensitive for the detection of this risk-predisposing condition, given that most of our patients had normal A1AT serum level before transplant hepatectomy. It can also help explain a portion of cases labeled “cryptogenic cirrhosis.”

The use of PASD and A1AT positive periportal globules as a surrogate marker for the Z allele had been previously utilized in as early as 1980 by Clausen et al.^[19] whereby liver biopsies were assessed for A1AT globules. Thirty-four of 850 biopsies (4%) demonstrated PASD and A1AT positive globules and therefore assumed to harbor a Z allele variant. Half of their positive biopsies showed either fibrotic or cirrhotic livers, suggesting that the Pi*Z allele in both homozygous and heterozygous forms correlates with the development of liver cirrhosis. The genotypes of these cases however were not confirmed with subsequent testing.

Moreover, not all patients who are heterozygous for the Z allele demonstrate PASD/A1AT-positive globules, as is demonstrated by their follow-up study in 1984, showing that only 47% of patients with a confirmed (through Isoelectric Focusing) Pi*Z allele demonstrate PASD/A1AT-positive globules (>3 um) on their liver tissue histology.^[20] This suggests that the globules, albeit specific, are not sufficiently sensitive or reliable as a screening tool for heterozygous Z allele.

In 1997, Iezzoni et al.^[21] performed PASD stain on liver explant specimens from cases with cirrhosis and found that 10% (17 of 171) demonstrated PASD- and A1AT-positive globules, which is similar to the 12% (18 of 142) we demonstrated in our study. The etiology for the majority of their cases was attributed preoperatively to causes other than A1AT deficiency. Furthermore, a subsequent isoelectric focusing elucidated homozygous or heterozygous Z phenotype in most of their cases (11 of 17; 65%), while one demonstrated SS phenotype (one of 17; ~5%) and the remainder were of the MM phenotype (four of 17; 25%). They concluded that an unsuspected PASD/A1AT positive globules, regardless of the presence or absence of other concomitant causes of chronic liver disease, should prompt the pathologist to alert the clinician of the possibility of an A1AT abnormality.

It is important to pay attention to the distribution of the globules; Qizilbash et al.^[7] in 1983 had performed PASD on liver tissue from 500 autopsy cases and subsequently classified the PASD+ globules into Type 1, whereby the globules are periportal in distribution and positive for A1AT immunoperoxidase stain, and Type 2 which are centrilobular and negative for the aforementioned stain. The majority (10 out of 14; 71%) of the cases with Type I globules showed cirrhosis and a few demonstrated dysplastic foci.

Lincoln et al.^[18] successfully validated real-time PCR assay to detect the S and Z alleles in FFPE liver tissue in 2018 and demonstrated that PCR testing of FFPE tissue is potentially a good alternative to peripheral blood tests.

Molecular DNA testing of FFPE tissue offers multiple advantages including the potential to test anatomic pathology specimens, eliminating the need to bring-in patients for additional peripheral blood

sampling. Moreover, in certain instances (such as case #18), the liver specimen under investigation is not native to the patient but instead is an allograft. Therefore, whole blood-based genotyping may not accurately reflect the presence of A1AT deficiency in the patient due to potential pathology in the allograft liver. More recently, a case has been reported in the literature involving a patient who underwent allogeneic hematopoietic stem cell transplantation following liver transplantation.^[22] It is also possible that advances in immunology and transplant medicine could enable patients who have undergone allogeneic stem cell transplant to become eligible for liver transplantation in the future. In such cases, direct testing of liver tissue may provide a more reliable means of detecting A1AT deficiency cases that might otherwise be missed through whole blood-based genotyping.

PCR testing is relatively rapid, inexpensive, and easier to interpret. One pitfall is detecting a false negative wild-type allele on real-time PCR when the actual liver histology shows convincing evidence of A1AT deficiency (i.e., classic PASD/A1AT positive globules). In such cases, additional testing such as Sanger sequencing can be performed on blood samples to detect rare alleles. Testing FFPE tissue is not exempt from limitations. It is not uncommon to encounter assay failures due to technical or specimen-related issues, such as small biopsies with low cellularity, improper fixation time, DNA fragmentation, and degradation. The latter is a significant factor in archived FFPE tissue, particularly after prolonged storage.^[23] In such cases, peripheral blood testing might be necessary. In addition, PCR testing does not detect rare allele variants such as M Malton, and therefore, a more definitive assay for rare allele detection might be required.

Conclusion

Screening for A1AT deficiency using serum A1AT levels is not sufficiently sensitive to detect all A1AT deficiency carriers, leading to underdiagnosis of the carrier status. If A1AT genotyping was not performed preoperatively and the risk is high based on the histological presence of PASD- and A1AT-positive globules in the explanted liver, then molecular testing of FFPE tissue can be a viable method for confirming the diagnosis of A1AT deficiency. From our study, we also find that PASD- and A1AT-positive globules in the periportal distribution are highly reliable predictors for the presence of the Z allele. In addition, we advocate for the routine use and careful examination of the PASD special stain in explanted livers to detect A1AT globules with subsequent confirmation by A1AT immunohistochemistry, even in cases with negative PASD in the pre-operative biopsies.

Ethics Committee Approval: The University of British Columbia Ethics Committee granted approval for this study (date: 10.06.2019, number: #H19-02913).

Peer-review: Externally peer-reviewed.

Author Contributions: Concept – HY, AM, HB, GR, LR; Design – HY, AM, HB, GR, LR; Supervision – HY, AM, HB, GR, LR; Fundings – HY, HB; Materials – HY, HB, EY, DS; Data Collection and/or Processing – HY, HB; Analysis and/or Interpretation – HY, HB, GR, DS; Literature Search – HY, HB; Writing – HB; Critical Reviews – HY, AM, HB, EY, GR, DS.

Conflict of Interest: The authors have no conflict of interest to declare.

Financial Disclosure: The authors declared that this study has received no financial support.

References

1. van Steenberghe W. Alpha 1-antitrypsin deficiency: an overview. *Acta Clin Belg* 1993;48(3):171-189.
2. Cox DW, Markovic VD, Teshima IE. Genes for immunoglobulin heavy chains and for alpha 1-antitrypsin are localized to specific regions of chromosome 14q. *Nature* 1982;297(5865):428-430.
3. Blanco I, Bueno P, Diego I, Pérez-Holanda S, Casas-Maldonado F, Esquinas C, et al. Alpha-1 antitrypsin Pi*Z gene frequency and Pi*ZZ genotype numbers worldwide: an update. *Int J Chron Obstruct Pulmon Dis* 2017;12:561-569.
4. Wettstein L, Weil T, Conzelmann C, Müller JA, Groß R, Hirschenberger M, et al. Alpha-1 antitrypsin inhibits TMPRSS2 protease activity and SARS-CoV-2 infection. *Nat Commun* 2021;12(1):1726.
5. Teckman JH, Perlmuter DH. Retention of mutant alpha(1)-antitrypsin Z in endoplasmic reticulum is associated with an autophagic response. *Am J Physiol Gastrointest Liver Physiol* 2000;279(5):G961-G974.
6. Ferrarotti I, Thun GA, Zorzetto M, Ottaviani S, Imboden M, Schindler C, et al. Serum levels and genotype distribution of α 1-antitrypsin in the general population. *Thorax* 2012;67(8):669-674.
7. Qizilbash A, Young-Pong O. Alpha 1 antitrypsin liver disease differential diagnosis of PAS-positive, diastase-resistant globules in liver cells. *Am J Clin Pathol* 1983;79(6):697-702.
8. Catz EG, Speir WA Jr. alpha 1-Antitrypsin deficiency. *South Med J* 1984;77(4):479-483.
9. Pittschieler K. Liver disease and heterozygous alpha-1-antitrypsin deficiency. *Acta Paediatr Scand* 1991;80(3):323-327.
10. de Serres FJ, Blanco I. Prevalence of α 1-antitrypsin deficiency alleles PI*S and PI*Z worldwide and effective screening for each of the five phenotypic classes PI*MS, PI*MZ, PI*SS, PI*SZ, and PI*ZZ: a comprehensive review. *Ther Adv Respir Dis* 2012;6(5):277-295.
11. Graham A, Kalsheker NA, Newton CR, Bamforth FJ, Powell SJ, Markham AF. Molecular characterisation of three alpha-1-antitrypsin deficiency variants: proteinase inhibitor (Pi) nullcardiff (Asp256---Val); PiMmalton (Phe51---deletion) and PiI (Arg39---Cys). *Hum Genet* 1989;84(1):55-58.
12. Häggblom J, Kettunen K, Karjalainen J, Heliövaara M, Jousilahti P, Saarelainen S. Prevalence of PI*Z and PI*S alleles of alpha-1-antitrypsin deficiency in Finland. *Eur Clin Respir J*. 2015;2:28829.
13. Franciosi AN, Carroll TP, McElvaney NG. SZ alpha-1 antitrypsin deficiency and pulmonary disease: more like MZ, not like ZZ. *Thorax* 2021;76(3):298-301.
14. Estey MP, Tahooni T, Nelson TN, Parker ML, Agbor TA, Yang HM, et al. Is the diagnostic rate for the common subtypes of A1AT deficiency consistent across two Canadian Provinces? *Clin Biochem* 2021;95:84-88.
15. Nelson DR, Teckman J, Di Bisceglie AM, Brenner DA. Diagnosis and management of patients with α 1-antitrypsin (A1AT) deficiency. *Clin Gastroenterol Hepatol*. 2012;10(6):575-580.
16. Snyder MR, Katzmann JA, Butz ML, Wiley C, Yang P, Dawson DB, et al. Diagnosis of alpha-1-antitrypsin deficiency: An algorithm of quantification, genotyping, and phenotyping. *Clin Chem* 2006;52(12):2236-2242.
17. Lomas DA. New therapeutic targets for alpha-1 antitrypsin deficiency. *Chronic Obstr Pulm Dis* 2018;5(4):233-243.
18. Pac LJ, Cheeney G, Westerhoff M, Konnick EQ, Greene DN, Lockwood CM. Real-time PCR to detect α -1 antitrypsin S and Z alleles in formalin-fixed paraffin-embedded tissue. *J Appl Lab Med* 2018;3(1):18-25.
19. Clausen PP. Alpha-1-antitrypsin globules in liver biopsies. *Acta Pathol Microbiol Scand A* 1980;88(4):225-230.
20. Clausen PP, Lindskov J, Gad I, Kreutzfeldt M, Orholm M, Reinicke V, et al. The diagnostic value of alpha 1-antitrypsin globules in liver cells as a morphological marker of alpha 1-antitrypsin deficiency. *Liver* 1984;4(6):353-359.
21. Iezzoni JC, Gaffey MJ, Stacy EK, Normansell DE. Hepatocytic globules in end-stage hepatic disease: relationship to alpha 1-antitrypsin phenotype. *Am J Clin Pathol* 1997;107(6):692-697.
22. Bastin DJ, Mount G, Hsia CC, Jarrar M, McCann K, Xenocostas A, et al. The tale of two organs: allogeneic hematopoietic stem cell transplantation following liver transplantation in a myelofibrosis patient. *Hematol Transfus Cell Ther* 2021:S2531-1379(21)01335-3. doi: 10.1016/j.htct.2021.11.011. [Epub ahead of print].
23. Guyard A, Boyez A, Pujals A, Robe C, Tran Van Nhieu J, Allory Y, et al. DNA degrades during storage in formalin-fixed and paraffin-embedded tissue blocks. *Virchows Arch* 2017;471(4):491-500.