

# A Case of Pleural Paragonimiasis Confused with Tuberculous Pleurisy

Junwhi Song, M.D.<sup>1\*</sup>, Goohyeon Hong, M.D.<sup>1\*</sup>, Jae-Uk Song, M.D.<sup>1</sup>, Wooyoul Kim, M.D.<sup>1</sup>, Seo Goo Han, M.D.<sup>1</sup>, Yousang Ko, M.D.<sup>1</sup>, Boksoon Chang, M.D.<sup>1</sup>, Byeong-Ho Jeong, M.D.<sup>1</sup>, Jung Seop Eom, M.D.<sup>1</sup>, Ji Hyun Lee, M.D.<sup>1</sup>, Byung Woo Jhun, M.D.<sup>1</sup>, Kyeongman Jeon, M.D.<sup>1</sup>, Hong Kwan Kim, M.D.<sup>2</sup> and Won-Jung Koh, M.D.<sup>1</sup>

<sup>1</sup>Division of Pulmonary and Critical Care Medicine, Department of Medicine, <sup>2</sup>Department of Thoracic Surgery, Samsung Medical Center, Sungkyunkwan University School of Medicine, Seoul, Korea

Here, we report a case of pleural paragonimiasis that was confused with tuberculous pleurisy. A 38-year-old man complained of a mild febrile sensation and pleuritic chest pain. Radiologic findings showed right pleural effusion with pleural thickening and subpleural consolidation. Adenosine deaminase (ADA) activity in the pleural effusion was elevated (85.3 IU/L), whereas other examinations for tuberculosis were negative. At this time, the patient started empirical anti-tuberculous treatment. Despite 2 months of treatment, the pleural effusion persisted, and video-assisted thoracoscopic surgery was performed. Finally, the patient was diagnosed with pleural paragonimiasis based on the pathologic findings of chronic granulomatous inflammation containing *Paragonimus* eggs. This case suggested that pleural paragonimiasis should be considered when pleural effusion and elevated ADA levels are observed.

**Keywords:** Adenosine Deaminase; Paragonimiasis; Pleural Effusion; Tuberculosis

## Introduction

Pleuropulmonary paragonimiasis is a food-borne zoonosis commonly caused by the trematode *Paragonimus westermani*<sup>1</sup>. This parasitic infection has diverse symptoms and can mimic other conditions, such as mycobacterial infection or

neoplasm<sup>2,3</sup>. Routine laboratory test results with pleural fluid examination and radiologic findings are non-specific for pleuropulmonary paragonimiasis, often delaying diagnosis<sup>4</sup>.

Lymphocytic pleural effusions, often caused by tuberculosis, are commonly encountered in clinical practice. The measurement of adenosine deaminase (ADA) levels can facilitate the diagnosis of tuberculous effusions, but false-positive findings from lymphocytic effusions have been reported<sup>5-7</sup>. Here, we report clinical, radiologic, and laboratory features of a case that mimicked tuberculous pleurisy, but was ultimately diagnosed as pleural paragonimiasis after surgical biopsy.

**Address for correspondence:** Won-Jung Koh, M.D.

Division of Pulmonary and Critical Care Medicine, Department of Medicine, Samsung Medical Center, Sungkyunkwan University School of Medicine, 81 Irwon-ro, Gangnam-gu, Seoul 135-710, Korea

**Phone:** 82-2-3410-3429, **Fax:** 82-2-3410-3849

**E-mail:** wjkoh@skku.edu

\*Junwhi Song and Goohyeon Hong contributed equally to this work.

**Received:** Dec. 7, 2012

**Revised:** Dec. 31, 2012

**Accepted:** Oct. 28, 2013

©It is identical to the Creative Commons Attribution Non-Commercial License (<http://creativecommons.org/licenses/by-nc/3.0/>).

Copyright © 2014

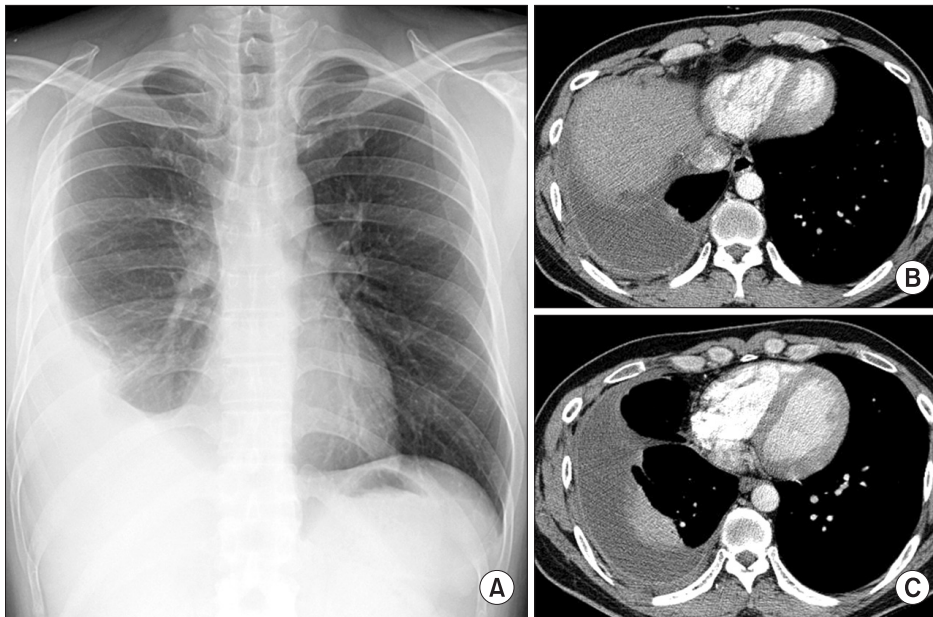
The Korean Academy of Tuberculosis and Respiratory Diseases.

All rights reserved.

## Case Report

A 38-year-old man developed right chest pain and dyspnea. He had been healthy until 12 months previously, when he developed right spontaneous pneumothorax. After drainage with a chest tube at a local hospital, the pneumothorax improved. He had no history of tuberculosis and the ingestion history of raw crab or river fish was uncertain.

One month before his visit to our hospital, the patient re-



**Figure 1.** A 38-year-old man with pleural effusion who was diagnosed with pleural paragonimiasis. (A) Chest radiography showed pleural effusion. (B) Chest computed tomography showed pleural thickening with pleural effusion. (C) Sub-pleural consolidation.

ported right chest pain and mild dyspnea. Three weeks later, a chest radiograph taken at a local hospital revealed right pleural effusion. Serous fluid (400 mL) was removed and pleural fluid analysis showed that the white blood cell (WBC) count was 700/ $\mu$ L (67% lymphocytes) and the ADA level was 85.3 IU/L. The patient then started empirical anti-tuberculous treatment including isoniazid, rifampin, ethambutol, and pyrazinamide. The patient was referred to our hospital because of persistent pleural effusion after 10 days of anti-tuberculous treatment.

Upon admission to our hospital, clinical laboratory testing showed that the blood leukocyte count was 8,600/ $\mu$ L, with a differential of 67.9% neutrophils and 5.2% eosinophils (normal range, 0–9.3%). The erythrocyte sedimentation rate was 120 mm/hr and the C-reactive protein level had increased to 8.27 mg/dL. A human immunodeficiency virus antibody test was negative. Chest radiography and computed tomography revealed right loculated pleural effusion with diffuse pleural thickening (Figure 1).

A percutaneous catheter was inserted and analysis of aspirated pleural fluid showed the following values: pH, 7.3; WBC count, 100/ $\mu$ L (69% polymorphonuclear neutrophils, 28% lymphocytes, 0% eosinophils); protein, 6.9 g/dL; lactate dehydrogenase (LDH), 2,226 U/L (serum LDH, 246 U/L); glucose, 12 mg/dL; and ADA, 84 IU/L. The patient continued anti-tuberculous treatment. In addition, percutaneous catheter drainage of pleural fluid was performed with intrapleural urokinase instillation for 5 days. Despite these efforts, the loculated pleural effusion did not improve.

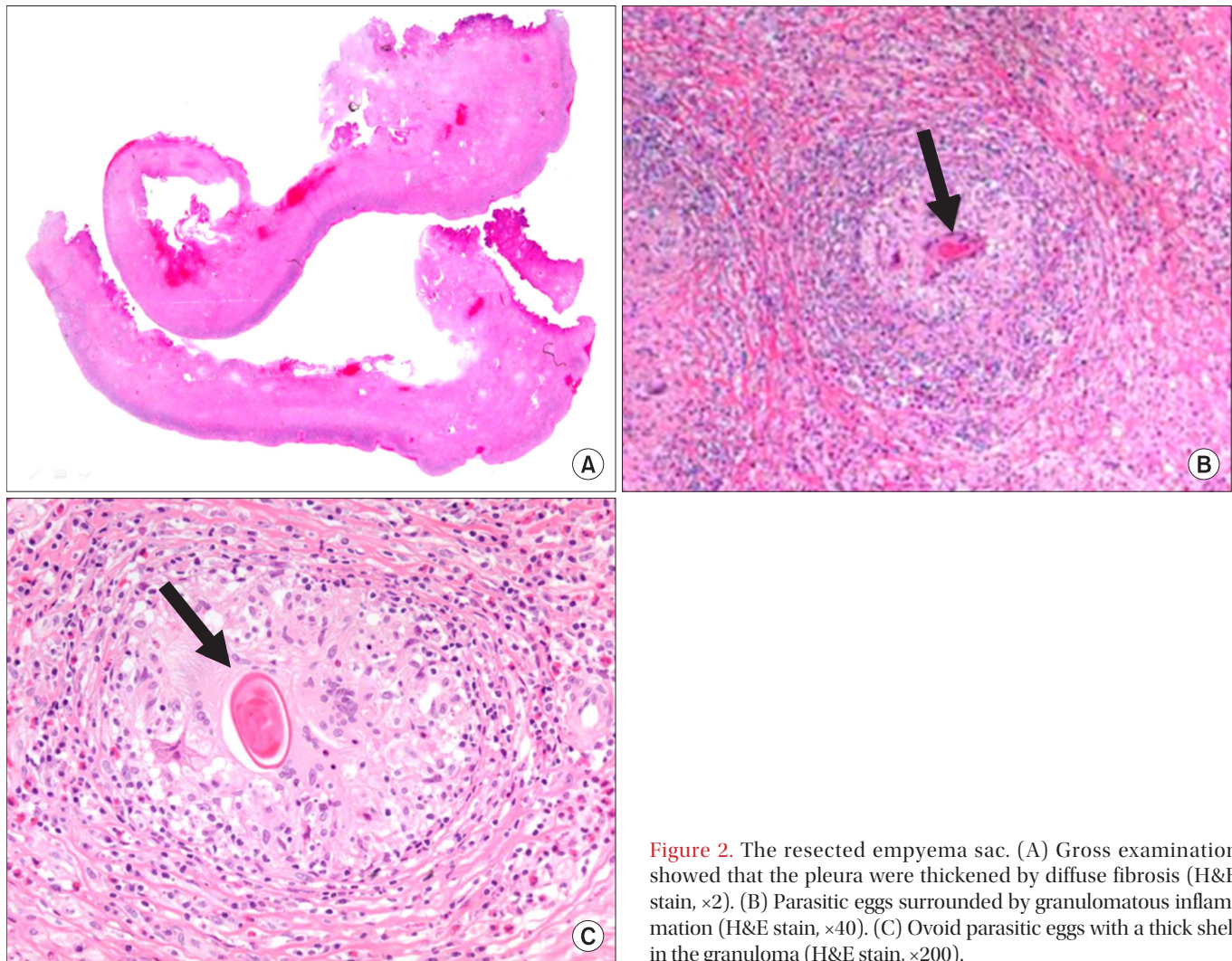
Therefore, video-assisted thoracoscopic surgery was performed for decortication. Diffuse, dense fibrosis of the pleura and empyema sacs was observed. Adhesiolysis and decortication were performed. Pathologic examination

showed chronic granulomatous inflammation with parasitic eggs, many eosinophils, and necrosis, which were consistent with paragonimiasis (Figure 2). Parasite-specific enzyme-linked immunosorbent assay after surgery was positive for *Paragonimus*. The patient was finally diagnosed with pleural paragonimiasis. Anti-tuberculous treatment was discontinued and praziquantel (25 mg/kg) was prescribed for 2 days. His symptoms and chest radiography were recovered 20 days after discharge. After 2 years of follow-up, the patient was free of symptoms and showed no pleural effusion on chest radiography.

## Discussion

Paragonimiasis is an infection caused by lung flukes, including *Paragonimus westermani* and related subspecies. *Paragonimus* is endemic in the Far East, including Korea, and in central South America and western Africa<sup>8</sup>. In these areas, reservoir hosts such as freshwater crab or crayfish harboring metacercariae of the parasite are an important source of human infection. When humans ingest pickled or inadequately cooked food, metacercariae reach the small intestine and excyst. They then penetrate the intestinal wall and enter the peritoneal cavity, migrate into the diaphragm, pleura, and reach the lung. Most patients are asymptomatic, but can present hemorrhage or inflammation causing necrosis and cysts<sup>9</sup>. Microscopic demonstration of eggs in stool or sputum and detection of antibodies to *Paragonimus* are important for diagnosis<sup>10,11</sup>. Surgical evaluation is also an important diagnostic option in complicated cases<sup>4</sup>.

Because pleural involvement of *Paragonimus* is a main



**Figure 2.** The resected empyema sac. (A) Gross examination showed that the pleura were thickened by diffuse fibrosis (H&E stain,  $\times 2$ ). (B) Parasitic eggs surrounded by granulomatous inflammation (H&E stain,  $\times 40$ ). (C) Ovoid parasitic eggs with a thick shell in the granuloma (H&E stain,  $\times 200$ ).

presentation of pleuropulmonary paragonimiasis, the differentiation of this infection from other causes of pleural effusion is important<sup>12</sup>. Differentiation is especially important in tuberculosis-endemic areas because pleuropulmonary paragonimiasis is often difficult to distinguish from tuberculosis, leading to misdiagnosis. Although peripheral blood or pleural fluid eosinophilia is reported with a high incidence in patients with paragonimiasis, a small proportion of patients do not have these characteristic findings<sup>2,13</sup>. Our patient did not present with eosinophilia in the peripheral blood or eosinophils in pleural fluid and bronchoalveolar lavage. Ova or parasite bodies were not found in the bronchoalveolar lavage or stool. Furthermore, elevated ADA activity was suggestive of tuberculous pleurisy. Percutaneous drainage was ineffective, and the final diagnosis was delayed until surgical pleural biopsy, although the history of previous pneumothorax could suggest the possibility of paragonimiasis.

ADA activity in pleural fluid is a useful biomarker of tuberculous pleurisy and provides a reliable basis for treatment decisions. However, high ADA levels can also be found in patients with other causes of pleural effusion<sup>5-7,14</sup>. Here, we report clinical, radiologic, and laboratory features of a case that mimicked tuberculous pleurisy, but was diagnosed with pleural paragonimiasis after surgical biopsy. In conclusion, the possibility of pleural paragonimiasis should be considered in the differential diagnosis of pleural effusion with elevated ADA levels in areas where tuberculosis and paragonimiasis could be prevalent.

## Conflicts of Interest

No potential conflict of interest relevant to this article was reported.

## References

1. Nakamura-Uchiyama F, Mukae H, Nawa Y. Paragonimiasis: a Japanese perspective. *Clin Chest Med* 2002;23:409-20.
2. Jeon K, Koh WJ, Kim H, Kwon OJ, Kim TS, Lee KS, et al. Clinical features of recently diagnosed pulmonary paragonimiasis in Korea. *Chest* 2005;128:1423-30.
3. Song JU, Um SW, Koh WJ, Suh GY, Chung MP, Kim H, et al. Pulmonary paragonimiasis mimicking lung cancer in a tertiary referral centre in Korea. *Int J Tuberc Lung Dis* 2011;15:674-9.
4. Boland JM, Vaszar LT, Jones JL, Mathison BA, Rovzar MA, Colby TV, et al. Pleuropulmonary infection by *Paragonimus westermani* in the United States: a rare cause of eosinophilic pneumonia after ingestion of live crabs. *Am J Surg Pathol* 2011;35:707-13.
5. Lee YC, Rogers JT, Rodriguez RM, Miller KD, Light RW. Adenosine deaminase levels in nontuberculous lymphocytic pleural effusions. *Chest* 2001;120:356-61.
6. Jimenez Castro D, Diaz Nuevo G, Perez-Rodriguez E, Light RW. Diagnostic value of adenosine deaminase in nontuberculous lymphocytic pleural effusions. *Eur Respir J* 2003;21:220-4.
7. Krenke R, Korczynski P. Use of pleural fluid levels of adenosine deaminase and interferon gamma in the diagnosis of tuberculous pleuritis. *Curr Opin Pulm Med* 2010;16:367-75.
8. Kagawa FT. Pulmonary paragonimiasis. *Semin Respir Infect* 1997;12:149-58.
9. Im JG, Whang HY, Kim WS, Han MC, Shim YS, Cho SY. Pleuropulmonary paragonimiasis: radiologic findings in 71 patients. *AJR Am J Roentgenol* 1992;159:39-43.
10. Slemenda SB, Maddison SE, Jong EC, Moore DD. Diagnosis of paragonimiasis by immunoblot. *Am J Trop Med Hyg* 1988;39:469-71.
11. Xu ZB. Studies on clinical manifestations, diagnosis and control of paragonimiasis in China. *Southeast Asian J Trop Med Public Health* 1991;22 Suppl:345-8.
12. Vidamaly S, Choumlivong K, Keolouangkhon V, Vannavong N, Kanpittaya J, Strobel M. Paragonimiasis: a common cause of persistent pleural effusion in Lao PDR. *Trans R Soc Trop Med Hyg* 2009;103:1019-23.
13. Taniguchi H, Mukae H, Matsumoto N, Tokojima M, Katoh S, Matsukura S, et al. Elevated IL-5 levels in pleural fluid of patients with paragonimiasis westermani. *Clin Exp Immunol* 2001;123:94-8.
14. Porcel JM, Esquerda A, Bielsa S. Diagnostic performance of adenosine deaminase activity in pleural fluid: a single-center experience with over 2100 consecutive patients. *Eur J Intern Med* 2010;21:419-23.