

Emergency Quadrilo-Bentall Procedure for Aortic Rupture in a Patient with Behcet's Disease

Sung Jun Park, M.D., Jeong-woo Lee, M.D., Joon Bum Kim, M.D., Ph.D.

Cardiovascular involvement in cases of Behcet's disease is a rare but life-threatening condition, and prosthetic valve detachment is a frequent and serious complication attributable to Behcet's disease following the surgical repair of aortic regurgitation. We report the case of a patient with Behcet's disease presenting with contained aortic rupture around the aortic root. The patient had previously undergone aortic valve surgery three times due to recurrent prosthetic valve detachment. An emergency operation was performed, consisting of aortic root replacement (ARR) using a composite valved conduit and the replacement of the hemiarch. ARR may be an appropriate surgical option for patients with Behcet's disease in order to prevent recurrence of the disease.

Key words: 1. Aortic valve
2. Aortic valve insufficiency
3. Extracorporeal circulation
4. Behcet syndrome
5. Surgery

CASE REPORT

A 38-year-old male patient was referred to Asan Medical Center due to severe shock attributable to contained aortic rupture around the aortic root. The patient had been treated with systemic corticosteroids after being diagnosed with Behcet's disease 14 years previously. The patient had previously undergone aortic valve surgery three times in another hospital for the management of aortitis and consequent aortic regurgitation associated with underlying Behcet's disease. The first two mechanical aortic valve replacement (AVR) procedures had been performed 14 years previously, followed by a Ross procedure two years after the second operation.

When the patient presented to our emergency department,

he was in severe shock (systolic blood pressure, 65 mmHg) despite maximal intravenous inotropic support (epinephrine and norepinephrine), and exhibited a drowsy mental state. On enhanced computed tomography, a contained aortic rupture was found around the aortic root and the ascending aorta, abutting the sternum. The contained hematoma was measured up to 72 mm in diameter (Fig. 1). An emergency operation was planned. A transesophageal echocardiography performed in the operating room showed mild aortic regurgitation (AR) and severely depressed cardiac function with a left ventricular (LV) ejection fraction of 17% despite full inotropic support.

Massive hemorrhage during the reopening of the sternum and consequent catastrophic events were anticipated; therefore, deep hypothermic circulatory arrest (DHCA) was im-

Department of Thoracic and Cardiovascular Surgery, Asan Medical Center, University of Ulsan College of Medicine

Received: September 2, 2014, Revised: December 23, 2014, Accepted: January 6, 2015, Published online: October 5, 2015

Corresponding author: Joon Bum Kim, Department of Thoracic and Cardiovascular Surgery, Asan Medical Center, University of Ulsan College of Medicine, 88 Olympic-ro 43-gil, Songpa-gu, Seoul 05505, Korea
(Tel) 82-2-3010-3580 (Fax) 82-2-3010-6966 (E-mail) jbkim1975@amc.seoul.kr

© The Korean Society for Thoracic and Cardiovascular Surgery. 2015. All right reserved.

© This is an open access article distributed under the terms of the Creative Commons Attribution Non-Commercial License (<http://creativecommons.org/licenses/by-nc/4.0>) which permits unrestricted non-commercial use, distribution, and reproduction in any medium, provided the original work is properly cited.

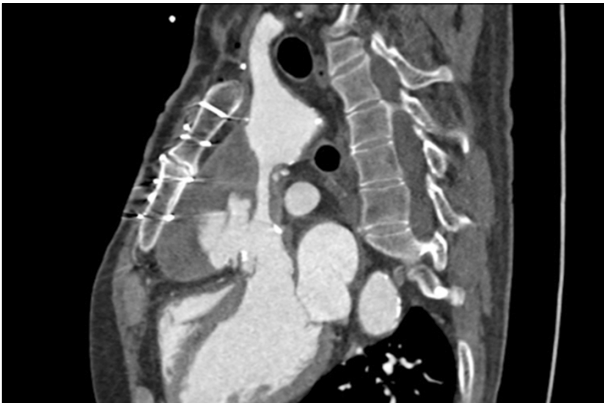

Fig. 1. A preoperative enhanced computed tomography image shows a contained rupture of the ascending aorta with pseudoaneurysm formation.

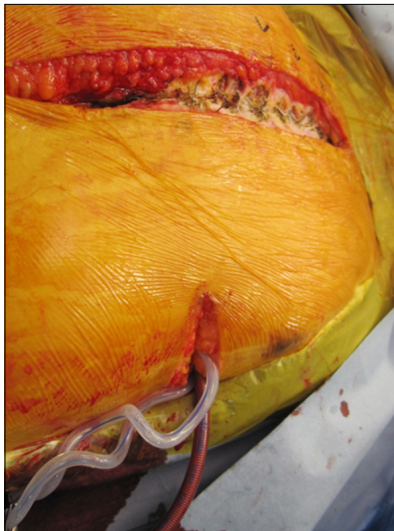


Fig. 2. While inducing deep hypothermia, transapical left ventricular (LV) venting was achieved through a left-side mini-thoracotomy in order to prevent LV distension during cardiac arrest.

plemented before opening the sternum, using femoral cardiopulmonary bypass (CPB) with direct trans-apical LV venting through a left-side mini-thoracotomy (Fig. 2). Once the nasopharyngeal temperature cooled to 18°C, sternal opening was attempted using an oscillating saw. As expected, a massive hemorrhage occurred from the ruptured aorta while the hematoma was being removed after sternal opening, at which point the CPB was stopped. Distal ascending aorta clamping was achieved securely within one minute of DHCA, and CPB

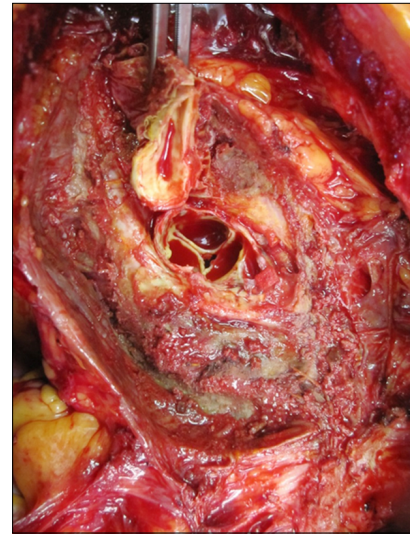


Fig. 3. Two discrete rupture sites were observed in the aorta, corresponding to the distal anastomosis site of the previous Ross procedure and the right coronary button site.

was restarted. Two discrete rupture sites were found in the aorta: one at the distal anastomosis site of the previous Ross procedure and the other at the right coronary button site (Fig. 3). After complete adhesiolysis of the mediastinum and the removal of the previously implanted pulmonic autograft, several tiny pseudoaneurysms were identified at the level of the aorto-ventricular junction, and further resection of this area was therefore conducted. DHCA was then reimplemented (15 minutes) in order to conduct hemiarch replacement using a 28-mm Hemashield vascular graft (Boston Scientific, Boston, MA, USA), which was followed by the reimplementation of CPB and systemic rewarming. During this period, complete root replacement was carried out, using a 27-mm composite mechanical valved conduit (St. Jude Medical Inc., St Paul, MN, USA). The circulatory arrest and cardiac ischemic times were 16 minutes and 188 minutes, respectively. The patient failed to be weaned from CPB due to profound LV dysfunction, therefore, CPB was substituted with venous-arterial extracorporeal membrane oxygenation (ECMO). Massive hemorrhage from the surgical sites continued despite meticulous hemostatic maneuvers and massive blood product transfusions. The patient was transferred to the intensive care unit (ICU) with an open sternum. The transfusion of large quantities of blood products for two days resulted in adequate hemostasis.

Follow-up echocardiography showed a significant recovery of LV function at this point, and the patient was successfully weaned off ECMO after four days of ECMO support, after which a delayed sternal closure was performed. The follow-up computed tomography images and echocardiogram were unremarkable in that neither paravalvular dehiscence nor leakage on the anastomosis site was observed. LV function was found to be normal, with an ejection fraction of 56% without any inotropic support. The patient was discharged on postoperative day 31 without any neurologic sequelae or residual complications. On the echocardiographic follow-up performed six months after the surgery, cardiac function was completely normal, with adequate function of the mechanical valve and no pathologic findings around the aortic root and ascending aorta. The patient has undergone 14 months of follow-up while prescribed an oral corticosteroid medication, and has exhibited no cardiovascular complications.

DISCUSSION

Cardiovascular involvement in Behcet's disease is a rare but life-threatening condition; in particular, involvement of the aortic root is known to be the leading cause of death in patients with Behcet's disease [1]. Surgical treatment of the aortic valve is required in these conditions, however, conventional AVR is frequently complicated by prosthetic valve detachment due to the fragility of the aortic tissue and recurrent inflammation [2,3]. Various surgical methods have been suggested to improve the outcomes of the surgical treatment of aortic root diseases associated with Behcet's disease [4-6].

Since observations have revealed that the inflammation in Behcet's disease primarily involves the aorto-ventricular junction of the aortic root, the complete resection of the inflammatory tissue in this area has been considered important for preventing the recurrence of the disease. With this in mind, aortic root replacement (ARR) is considered an ideal surgical option for AR attributable to Behcet's disease [2,3,7].

The largest series of aortic valve operations in patients with Behcet's disease presented 19 patients who underwent 46 aortic valve procedures and demonstrated an 80% reoperation rate after AVR alone due to valve dehiscence, whereas excellent results were observed with ARR [3]. The authors

suggested that ARR should be performed as the initial surgical treatment of AR in patients with Behcet's disease. Ando et al. [8] also reported excellent results of ARR procedures in eight patients with Behcet's disease; only one patient died of arrhythmia, while the other seven patients survived through a long follow-up period. Of those seven patients, only one patient required reoperation due to valve detachment over the course of a mean follow-up period of 74 months. In agreement with these previous studies, we believe that AR attributable to Behcet's disease should be treated with ARR as the initial surgical procedure in order to prevent prosthetic valve detachment.

In the present case, AR attributable to Behcet's disease was initially treated with conventional AVR that was followed by a repeated AVR procedure and a Ross procedure due to recurrent prosthetic valve detachment. The patient ultimately presented with contained aortic rupture with pseudoaneurysm formation around the aortic root and ascending aorta twelve years after the third surgery. Since a massive hemorrhage and consequent cardiac arrest were anticipated during the opening of the sternum, we decided to induce DHCA with transapical LV venting before opening the sternum. Through a left-side mini-thoracotomy, it was possible to achieve LV venting without encountering severe mediastinum adhesion or fatal hemorrhage from the ruptured aorta. This strategy enabled the prompt identification of the ruptured location and the complete resection of the diseased aortic tissue. Since this patient had been suffering from cardiac insufficiency attributable to preoperative shock, preventing LV distention injury during DHCA was believed to be crucial for minimizing further myocardial damage associated with the surgical procedures.

The intensive transfusion of blood products, including platelet concentrate and fresh frozen plasma, was performed after transferring the patient to the ICU. Serious mediastinal bleeding and a coexisting low cardiac output state requiring ECMO support gradually improved during postoperative ICU care after the correction of coagulopathy. We believe that an optimal surgical strategy and dedicated intensive care allowed the patient to recover from a desperate condition.

In conclusion, we report the case of a patient with Behcet's disease presenting with a contained aortic rupture in the pre-

vious surgical sites of the aortic root, who was treated with a sophisticated surgical approach and postoperative care. The long-term outcomes associated with this procedure need to be addressed in further studies.

CONFLICT OF INTEREST

No potential conflict of interest relevant to this article was reported.

REFERENCES

1. James DG, Thomson A. *Recognition of the diverse cardiovascular manifestation in Behcet's disease.* Am Heart J 1982;103:457-8.
2. Ando M, Kosakai Y, Okita Y, Nakano K, Kitamura S. *Surgical treatment of Behcet's disease involving aortic regurgitation.* Ann Thorac Surg 1999;68:2136-40.
3. Jeong DS, Kim KH, Kim JS, Ahn H. *Long-term experience of surgical treatment for aortic regurgitation attributable to Behcet's disease.* Ann Thorac Surg 2009;87:1775-82.
4. Azuma T, Yamazaki K, Saito S, Kurosawa H. *Aortic valve replacement in Behcet's disease: surgical modification to prevent valve detachment.* Eur J Cardiothorac Surg 2009; 36:771-2.
5. Tang Y, Xu J, Xu Z. *Supra-annular aortic replacement in Behcet's disease: a new surgical modification to prevent valve detachment.* Int J Cardiol 2011;149:385-6.
6. Liang MY, Yao JP, Zhang X, Wang ZP. *Surgical technique for aortic regurgitation attributable to Behcet's disease: modified aortic valve replacement with reinforcement of the aortic wall.* Eur J Cardiothorac Surg 2012;41:647-8.
7. Okada K, Eishi K, Takamoto S, Ando M, Kosakai Y, Nakano K, et al. *Surgical management of Behcet's aortitis: a report of eight patients.* Ann Thorac Surg 1997;64:116-9.
8. Ando M, Sasako Y, Okita Y, Tagusari O, Kitamura S. *Valved conduit operation for aortic regurgitation associated with Behcet's disease.* Jpn J Thorac Cardiovasc Surg 2000;48: 424-7.