

Vertical Continuous Meniscal Suture Technique



José Leonardo Rocha de Faria, M.D., Douglas Mello Pavão, M.D., M.Sc.,
Raphael Serra Cruz, M.D., M.Sc., Eduardo Branco de Sousa, M.D., Ph.D.,
João Matheus Guimarães, M.D., Ph.D., Marcelo Costa de Oliveira Campos, M.D., and
Alan de Paula Mozella, M.D., M.Sc.

Abstract: Meniscal injuries are common in the population, representing the major cause of functional impairment in the knee. Vertical longitudinal injuries of the meniscus can be stable or unstable. When extensive, they are commonly unstable and can lead to clinical signs of significant functional disability. Vertical longitudinal injuries have the best prognosis for repair, especially when occurring in the meniscal periphery, called the red-red zone. A recently developed type of meniscal suture device called Meniscus 4 A-II enables the surgeon to perform a meniscal suture from the inside-out continuously, reducing surgical time. Because it allows the surgeon to use a single and inexpensive device to repair the entire injury, costs are significantly reduced. Here, an approach to carry out continuous meniscal repair with vertical sutures is described. This technique warrants excellent stability to the meniscal repair, increasing the chances of a successful outcome. We believe that the popularization of the repair technique from the inside out using the Meniscus 4-All device will help many surgeons around the world save menisci that otherwise would have a great chance of being excised, since it is a cheap, reproducible, and easy-to-handle device.

The menisci are structures found on the medial and lateral compartments of the knee. The medial meniscus is C-shaped, and the lateral meniscus presents a similar format, but with closer roots and greater mobility.^{1,2} Meniscal injuries are common in the population, representing the major cause of functional impairment in the knee.³ Meniscal injuries can be degenerative or traumatic, with a bimodal profile. Acute trauma is more commonly found in young active patients, whereas chronic degenerative injuries mostly occur in patients >50 years of age.^{4,5}

Acute injuries can occur from different trauma mechanisms, generating injuries of different morphologies. This can lead to multiple clinical conditions, such as joint block, audible clicks, instability, and pain that can be reported from mild to disabling. The clinical condition is directly related to the type of injury suffered.^{6,7}

Vertical longitudinal injuries can be stable or unstable. When extensive, they are more commonly unstable and can lead to clinical signs of significant functional disability such as pain, instability, and a feeling of joint blockage. This type of injury can be classified as a “bucket handle” injury, characterized by the fact that its central portion moves toward the center of the knee.^{3,8} Vertical longitudinal injuries are the kind of injury that have the best prognosis for repair,⁹ especially when occurring in the meniscal periphery, the so-called red-red zone.^{10,11}

Partial meniscectomy can also be performed if repair is not possible or if the patient does not wish to have meniscal suture. In the short and medium term, partial meniscectomy shows good results, but in the long term, there is a significant increase in risk of developing early osteoarthritis in the affected compartment. An important observation is that the size of the resected meniscal

From the Knee Surgery Center (J.L.R.F., D.M.P., R.S.C., E.B.S., A.P.M.) and the Research and Teaching Division (J.M.G.), National Institute of Traumatology and Orthopedics of Brazil; and the Orthopedics Discipline of the Medical Science Faculty of the State University of Rio de Janeiro (M.C.O.C., A.P.M.), Rio de Janeiro, Brazil.

The authors report the following potential conflicts of interest or sources of funding: J.L.R.F. reports Dispositivo de Sutura Meniscal/Meniscus Suture Device patent pending. A.P.M. reports Dispositivo de Sutura Meniscal/Meniscus Suture Device patent pending. Full ICMJE author disclosure forms are available for this article online, as [supplementary material](#).

Received March 28, 2020; accepted May 24, 2020.

Address correspondence to José Leonardo Rocha de Faria, M.D., Instituto Nacional de Traumatologia e Ortopedia Jamil Haddad, Av. Brasil, 500, São Cristóvão, Rio de Janeiro - RJ, Brazil. E-mail: drjoseleonardorocha@gmail.com

© 2020 by the Arthroscopy Association of North America. Published by Elsevier. This is an open access article under the CC BY-NC-ND license (<http://creativecommons.org/licenses/by-nc-nd/4.0/>).

2212-6287/20511

<https://doi.org/10.1016/j.eats.2020.05.014>

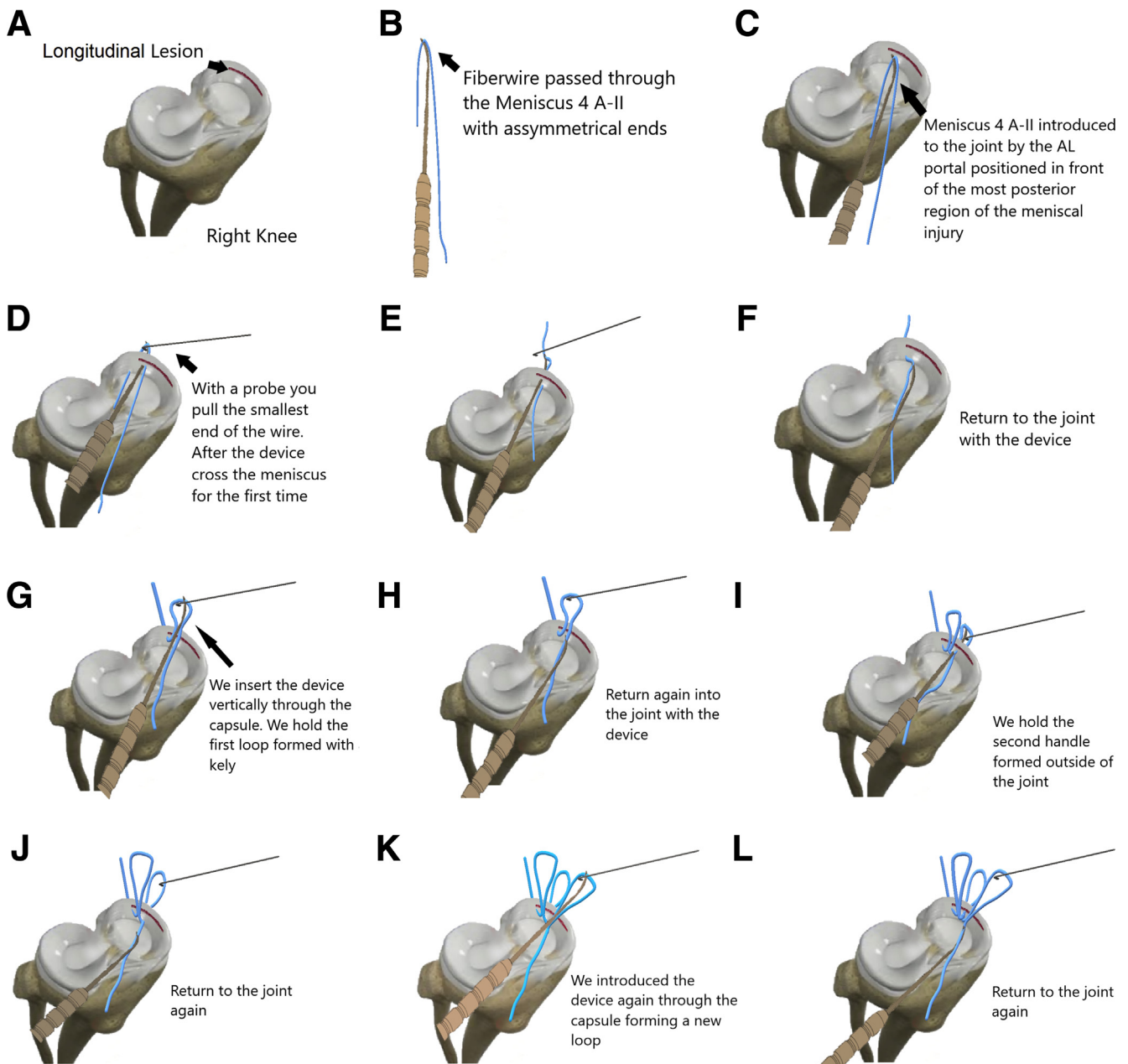


Fig 1. Longitudinal lesion seen in the posterior horn and body of the medial meniscus on a right knee (A). The Meniscus 4 A-II prepared with 2-0 FiberWire passed in its ends asymmetrically (B). The meniscal suture device is inserted into the most posteriorly injured region of the medial meniscus, with the Meniscus 4 A-II being inserted through the anterolateral portal (C). After the device has crossed the meniscus and capsules through the posteromedial approach, we identify the shortest wire and pull it out of the joint with the help of a probe or a Kelly tweezers (D and E). We return with the device to the interior of the joint (F). We insert the Meniscus 4 A-II 5 to 7 mm vertically, this time crossing only the capsule. With the help of a probe or Kelly tweezers, we hold the first loop formed outside of the joint (G). We return to the joint again with the device (H). We introduce the device again vertically more anteriorly than the last one, and this time crossing the injured meniscus again, and we form the second handle, repairing it with a Kelly or probe (I). We return to the joint again (J). We insert the Meniscus 4 A-II vertically again, crossing only the capsule forming the third handle, holding it with a probe or Kelly (K). We return with the device to the joint again (L). We cross the meniscus again, forming the last handle, repairing it with a Kelly or probe (M). We return to the joint (N). We cross the capsule for the last time and pull the other end of the wire out of the device (O).

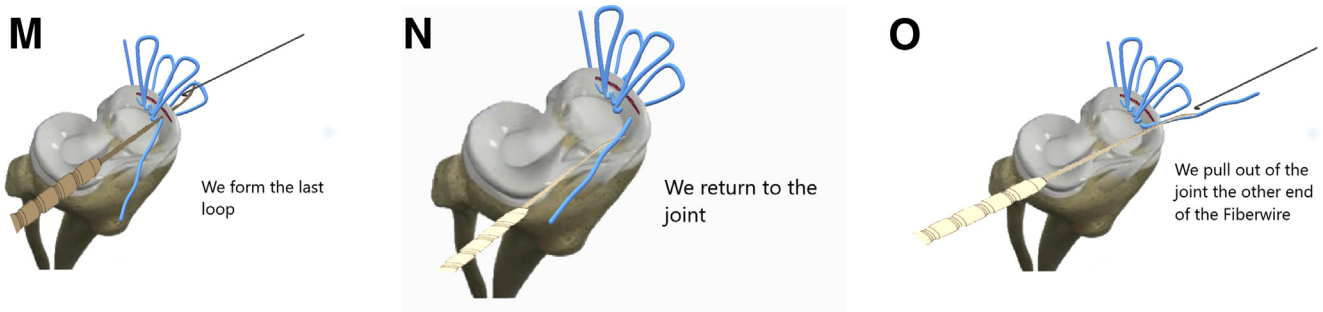


Fig 1. (continued).

fragment is directly correlated with the degree of degeneration developed.¹²⁻¹⁴

There are different types of meniscal suturing techniques, such as outside-in, all-inside, and inside-out. Outside-in is usually indicated for lesions in the anterior horn and meniscal body, all-inside is indicated mainly for lesions in the posterior horn of the menisci, and inside-out is most suitable for repairs in the body and posterior horn of the meniscus.^{15,16} Recent studies such as that of Kang et al.¹⁶ have shown that both inside-out and all-inside sutures have favorable and similar clinical results.

We have developed a type of meniscal suture device called Meniscus 4 A-II (Rio de Janeiro, Brazil) that enables the surgeon to perform a meniscal suture from the inside-out continuously, decreasing surgical time and costs, since a single, inexpensive device is enough to repair the entire injury.^{17,18} Here we describe a technique to perform a continuous meniscal suture with vertical seam, warranting the desired stability to the meniscal repair, thus increasing the chances of successful outcomes.

Surgical Technique

After the patient is anesthetized with spinal anesthesia, we place the patient in the supine position and install the pneumatic cuff on the proximal third of the thigh. Asepsis and antisepsis are performed using detergent chlorhexidine followed by alcoholic chlorhexidine. Sterile surgical fields are placed, and the pneumatic cuff is inflated.

Anteromedial and anterolateral arthroscopic portals and the transpatellar accessory portal are made. The transpatellar accessory portal is made longitudinally in the center of the patellar tendon. Joint exploration is performed, and the longitudinal lesion on the medial meniscus is diagnosed (Fig 1A).

To perform the inside-out suture, it is necessary to take a posteromedial surgical approach. For that, we identify 3 anatomical landmarks before incising the skin: the joint line, the adductor tubercle, and the posterior aspect of the tibial plateau. We make a vertical and oblique incision starting from the adductor tubercle

toward the posterior region of the previously demarcated tibial plateau, extending ~2 cm distally to the joint line. It is important not make the incision too posteriorly because of the anatomic position of the saphenous nerve (5 cm posterior to the adductor tubercle). After the skin incision, the sartorius tendon fascia is found and incised as proximal as possible to avoid damage to the gracilis and semitendinosus tendons.

After blunt dissection toward the joint line, we can observe a triangle formed by the articular capsule (anterior), medial gastrocnemius (posterior), and the semitendinosus tendon (distal). A digital dissection is performed between the joint capsule and the medial gastrocnemius to facilitate the passage of the meniscal suture device and position the neurovascular retractors. These retractors can be metal structures similar to vaginal speculums or even sterile metal spoons.¹⁹

The Meniscus 4 A-II device is then preloaded with a nonabsorbable meniscal suture, such as 2-0 FiberWire (Arthrex, Naples, FL), which is passed asymmetrically, with the smaller end of the suture thread to the anterior region of the device (Fig 1B). The camera is placed in the anteromedial portal and the suture device through the anterolateral portal or the transpatellar portal, according to the area of the meniscus in which the surgeon will work first. If the lesion starts at the transition of the posterior horn to the meniscal body, we start the meniscal repair through the lateral portal. If the lesion starts at the posterior horn, we start the meniscal repair through the transpatellar portal. We always place the first stitch through the most posterior injured region of the medial meniscus (Fig 1C).

While the device is introduced through the chosen arthroscopic portal into the proximal injured face of the meniscus, a retractor is used in the posteromedial approach to protect the neurovascular bundle, pulling the medial gastrocnemius posteriorly. Digital palpation is used to locate the place at which the tip of the device will come out on the posterior aspect of the knee. Because of the stiffness of the suture device, it is possible to palpate it before it completely pierces the joint capsule. After identifying the exit site, we progress

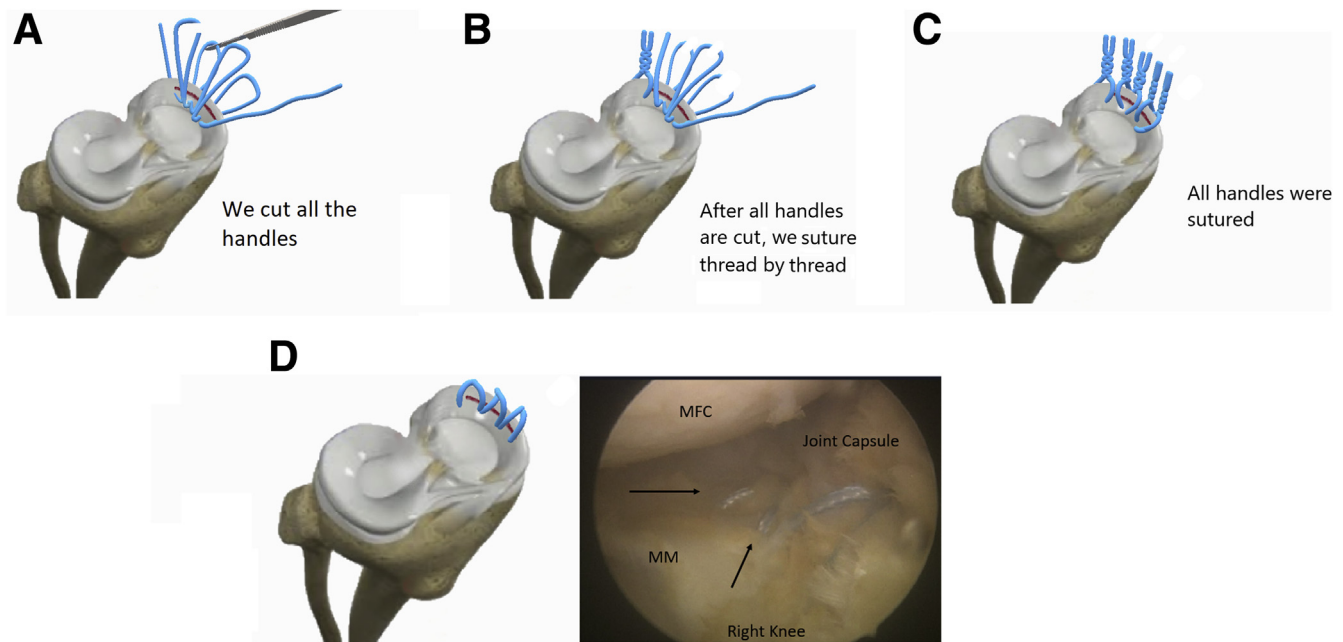


Fig 2. We cut all the handles formed in the central region (A). After all the handles are cut, we suture thread by thread (B and C). The final aspect of the vertical suture remains in the schematic model on the left, and the arthroscopic view of this type of meniscal repair in the cadaver knee on the right, with the black arrows showing the vertical continuous meniscal suture (D). MFC, medial femoral condyle; MM, medial meniscus.

the Meniscus 4 A-II and pull the shorter side of the suture out of the knee (Fig 1D, E). After this step, we repair this end of the FiberWire with Kelly tweezers. We then return with the Meniscus 4 A-II device inside the joint and choose the next entry point of the suture (Fig 1F). We perform the next passage of the suture vertically into the capsule, adjacent to the first one, by repeating the steps above. The surgeon must always be aware to protect the neurovascular structures. At this point, a Kelly forceps or a probe is used in the posteromedial approach to hold the suture, creating a loop outside the joint (Fig 1G). While still holding the loop, the surgeon pulls the suture device back into the joint (Fig 1H).

The next site of introduction of the device is chosen ~5 to 7 mm anterior of the previous one, passing through the proximal surface of the meniscus, fully introducing the device into the meniscus, moving away the posteromedial structures and repairing a new handle with FiberWire in the extra-articular region (Fig 1I). After the second loop is repaired, we return the device to the inside of the joint (Fig 1J) and insert the suture device vertically into the joint capsule immediately proximal to the previous passage, repeating the steps and forming a new loop (Fig 1K). These steps are repeated until the lesion is completely addressed or the wire runs out (Fig 1L-N). After completing the approach to injury (Fig 1N), we introduce the device

Table 1. Advantages, Disadvantages, Risks, and Limitations Associated With the Meniscus 4 A-II

Advantages	Disadvantages	Risks	Limitations
Greater control over device needle exit point	Need posteromedial approach for neurovascular protection	Chondral injury with the tip of the device	A long nonabsorbable thread is necessary
Lower risk of neurovascular injury	Need to repair each loop of suture stitch	Neurovascular injury if posteromedial protector is not properly positioned	The device can be deformed at its extremity if it is pressed in an erroneous way: for example, if it is pressed against the tibial plateau or femoral condyle
Multiple sutures in several planes continuously			Can only be performed with the Device Meniscus 4 A-II
Greater agility to the meniscal repair process			
Low cost: a single device allows suturing the entire meniscus			
Theoretical greater stability, as they are vertical sutures			

through the capsule one last time to pull the end of the wire out of the joint through the posteromedial approach (Fig 1O). We then cut all the handles in their central region (Fig 2A) and suture thread by thread (Fig 2B, C) completing the repair (Fig 2D) (Video 1).

Discussion

Vertical longitudinal lesions, mainly bucket handles, have high rates of reoperation, as high as 24% in the study by Kramer et al.,²⁰ compared with partial meniscectomy (8%). Although meniscal repair has a higher rate of reoperation and a longer recovery period, in the long run, it is related to better functional results and less occurrence of early osteoarthritis, since it may reestablish absorption and load distribution properties of the meniscus.²¹

A recent study²² conducted an analysis of a database, assessing the risk of osteoarthritis progression of patients undergoing meniscal repair compared to meniscectomy. The participants were selected between January 1998 and December 2010 and followed up by the database system until December 2015, searching for knee osteoarthritis development. The authors concluded that meniscal repair reduces between 25% and 50% the risk of knee osteoarthritis development, compared with partial meniscectomy.²² The study showed a relative protection from meniscal repair, compared with the other group. However, it is noteworthy that it was carried out on database evaluation and did not identify which knee was diagnosed with osteoarthritis.²²

Ahn et al.²³ published a study evaluating the risk of developing osteoarthritis after meniscectomy in discoid lateral menisci. The authors analyzed 202 patients who underwent partial meniscectomy in 5 years of follow-up, noting that 67 patients progressed to knee osteoarthritis in an average follow-up of 84.8 months. The results showed that the highest percentage of sectioned discoid meniscus and the presence of horizontal lesions were risk factors having significant association with the development of osteoarthritis.²³

There are several devices and techniques for meniscal repair. As previously mentioned, we can divide the techniques into 3 groups: outside-in, inside-out, and all-inside. Each of them can be performed with different repair devices.¹⁶ The gold standard technique for meniscal repair of extensive vertical longitudinal lesions is the inside-out, as it allows suturing almost the entire length of the meniscus with stitches in several anatomic planes, whether on its upper or lower faces, with horizontal or vertical mattresses, according to what the surgeon deems to be ideal.²⁴

Among the most popular devices that assist the surgeon in meniscal repairs from the inside-out, we can mention the malleable needles attached to the suture thread, which have the disadvantage of needing 1 device for each suture, making the repair very costly.²⁵ There are malleable needles with a lumen that allow the use of a single kit in >1

point; however, these cannulas are fragile and sometimes crush and obstruct their lumen during use, requiring often ≥ 2 devices to repair extensive injuries.^{2,26}

We herein describe the meniscal suture technique using the Meniscus 4-All device, which is resistant and allows countless stitches with a single device (Table 1). In addition, it allows the surgeon to use the suture of choice and availability, from specific threads like FiberWire to more common threads like Ethibond (Ethicon, Somerville, NJ).

We highlight the main precautions with the access and making of arthroscopic portals, minimizing the risks of chondral and neurovascular injuries during repair, based on similar studies in the literature.¹⁹ We believe that the popularization of the repair technique from the inside-out using the Meniscus 4-All will make the suture technique more reproducible and less costly, improving the functional results and reducing the occurrence of osteoarthritis secondary to the loss of meniscus function.

Acknowledgments

The filming was performed at the arthroscopy laboratory of Rio de Janeiro State University with a human cadaver knee.

References

1. McDermott ID, Sharifi F, Bull AMJ, Gupte CM, Thomas RW, Amis AA. An anatomical study of meniscal allograft sizing. *Knee Surg Sports Traumatol Arthrosc* 2004;12:130-135.
2. Vaquero-Picado A, González-Morán G, Moraleta L. Management of supracondylar fractures of the humerus in children. *EFORT Open Rev* 2018;3:526-540.
3. Twomey-Kozak J, Jayasuriya CT. Meniscus repair and regeneration: A systematic review from a basic and translational science perspective. *Clin Sports Med* 2020;39:125-163.
4. Baker BE, Peckham AC, Puppato F, Sanborn JC. Review of meniscal injury and associated sports. *Am J Sports Med* 1985;13:1-4.
5. Clayton RA, Court-Brown CM. The epidemiology of musculoskeletal tendinous and ligamentous injuries. *Injury* 2008;39:1338-1344.
6. Englund M, Guermazi A, Gale D, et al. Incidental meniscal findings on knee MRI in middle-aged and elderly persons. *N Engl J Med* 2008;359:1108-1115.
7. Doral MN, Bilge O, Huri G, Turhan E, Verdonk R. Modern treatment of meniscal tears. *EFORT Open Rev* 2018;3:260-268.
8. Duchman KR, Westermann RW, Spindler KP, et al. The fate of meniscus tears left in situ at the time of anterior cruciate ligament reconstruction: A 6-year follow-up study from the MOON cohort. *Am J Sports Med* 2015;43:2688-2695.
9. Krych AJ, McIntosh AL, Voll AE, Stuart MJ, Dahm DL. Arthroscopic repair of isolated meniscal tears in patients

- 18 years and younger. *Am J Sports Med* 2008;36:1283-1289.
10. Woodmass JM, LaPrade RF, Sgaglione NA, Nakamura N, Krych AJ. Meniscal repair: Reconsidering indications, techniques, and biologic augmentation. *J Bone Joint Surg Am* 2017;99:1222-1231.
 11. Uzun E, Misir A, Kizkapan TB, Ozcamdalli M, Akkurt S, Guney A. Factors affecting the outcomes of arthroscopically repaired traumatic vertical longitudinal medial meniscal tears. *Orthop J Sports Med* 2017;5:2325967117712448.
 12. Lutz C, Dalmay F, Ehkirch FP, et al. Meniscectomy versus meniscal repair: 10 years radiological and clinical results in vertical lesions in stable knee. *Orthop Traumatol Surg Res* 2015;101:S327-S331 (suppl).
 13. Englund M, Lohmander LS. Risk factors for symptomatic knee osteoarthritis fifteen to twenty-two years after meniscectomy. *Arthritis Rheum* 2004;50:2811-2819.
 14. Stärke C, Kopf S, Petersen W, Becker R. Meniscal repair. *Arthroscopy* 2009;25:1033-1044.
 15. Jurist KA, Greene PW 3rd, Shirkhoda A. Peroneal nerve dysfunction as a complication of lateral meniscus repair: A case report and anatomic dissection. *Arthroscopy* 1989;5:141-147.
 16. Kang DG, Park YJ, Yu JH, Oh JB, Lee DY. A systematic review and meta-analysis of arthroscopic meniscus repair in young patients: Comparison of all-inside and inside-out suture techniques. *Knee Surg Relat Res* 2019;31:1.
 17. Faria JLR, Pavão DM, Villardi AM, et al. Continuous meniscal suture of the knee. *Arthrosc Tech* 2020;9:e791-e796.
 18. Faria JLR, Pavão DM, Pedrinha ISM, et al. Posterior meniscal root repair using a meniscal suture device. *Arthrosc Tech* 2020;9:e905-e912.
 19. Chahla J, Serra Cruz R, Cram TR, Dean CS, LaPrade RF. Inside-out meniscal repair: Medial and lateral approach. *Arthrosc Tech* 2016;5:e163-e168.
 20. Kramer DE, Kalish LA, Martin DJ, et al. Outcomes after the operative treatment of bucket-handle meniscal tears in children and adolescents. *Orthop J Sports Med* 2019;7:2325967118820305.
 21. Xu C, Zhao J. A meta-analysis comparing meniscal repair with meniscectomy in the treatment of meniscal tears: The more meniscus, the better outcome? *Knee Surg Sports Traumatol Arthrosc* 2013;23:164-170.
 22. Persson F, Turkiewicz A, Bergkvist D, Neuman P, Englund M. The risk of symptomatic knee osteoarthritis after arthroscopic meniscus repair vs partial meniscectomy vs the general population. *Osteoarthritis Cartilage* 2018;26:195-201.
 23. Ahn JH, Kang DM, Choi KJ. Risk factors for radiographic progression of osteoarthritis after partial meniscectomy of discoid lateral meniscus tear. *Orthop Traumatol Surg Res* 2017;103:1183-1188.
 24. Samuelsen BT, Johnson NR, Hevesi M, et al. Comparative outcomes of all-inside versus inside-out repair of bucket-handle meniscal tears: A propensity-matched analysis. *Orthop J Sports Med* 2018;6:2325967118779045.
 25. Yilmaz S, Cankaya D, Firat A, Deveci A, Ozkurt B, Bozkurt M. Combined inside-out and all-inside technique in bucket-handle meniscus tears. *Acta Ortop Bras* 2016;24:179-183.
 26. Fillingham YA, Riboh JC, Erickson BJ, Bach BR, Yanke AB. Inside-out versus all-inside repair of isolated meniscal tears. *Am J Sports Med* 2017;45:234-242.