



## Case Report

# Adult-onset temporal lobe epilepsy, cognitive decline, multi-antiepileptic drug hypersensitivity, and Hashimoto's encephalopathy: Two case studies<sup>☆</sup>



Ofer Sadan<sup>a,\*</sup>, Estelle Seyman<sup>a,1</sup>, Elissa L. Ash<sup>a</sup>, Svetlana Kipervasser<sup>a,b</sup>, Miri Y. Neufeld<sup>a,b</sup>

<sup>a</sup> Department of Neurology, Tel-Aviv Sourasky Medical Center, Tel-Aviv, Israel

<sup>b</sup> Sackler School of Medicine, Tel-Aviv University, Tel-Aviv, Israel

## ARTICLE INFO

## Article history:

Received 24 July 2013

Accepted 26 July 2013

Available online 31 August 2013

## Keywords:

Hashimoto's encephalopathy

Temporal lobe epilepsy

Hypersensitivity

AED

## ABSTRACT

Hashimoto's encephalopathy is defined by the coexistence of encephalopathy and antithyroid antibodies. We report two cases of adult-onset temporal lobe epilepsy with subacute cognitive decline, high titers of antithyroid antibodies, multi-antiepileptic drug hypersensitivity, and good response to immunomodulatory treatment. The relevance of multidrug hypersensitivity in the setting of adult-onset epilepsy and the importance of searching for autoimmune causes for epilepsy are discussed.

© 2013 The Authors. Published by Elsevier Inc. All rights reserved.

## 1. Introduction

There has been increasing interest in an immune-based etiology for adult-onset epilepsy [1]. One of the autoimmune disorders linked to epilepsy is Hashimoto's encephalopathy. This disorder, which is also called steroid-responsive encephalopathy associated with autoimmune thyroiditis (SREAT), was first described by Brain et al. [2] as an association between antithyroid antibodies and encephalopathy. Its prevalence is estimated to be 2:100,000, with a predominance of females in their 5th–6th decades of life and with varying presentations, such as stroke-like events or behavioral changes with or without epilepsy [3]. One of the proposed mechanisms for antiepileptic drug hypersensitivity is also an immune-mediated process [4]. We report two cases of Hashimoto's encephalopathy manifesting as adult-onset temporal epilepsy, cognitive decline, and multi-antiepileptic drug (AED) hypersensitivity.

## 2. Case 1

A 60-year-old female with a medical history remarkable for satisfactorily treated hypothyroidism and dyslipidemia was first admitted

because of a dissociative event that lasted for 1 h, in which she described viewing herself outside of her body. No abnormal movements, amnesia, focal neurological deficits, fever, or systemic signs were noted. Her neurological examination was normal, as were her head computerized tomogram (CT) and routine laboratory workup (complete blood count, electrolytes, kidney and liver function, and thyroid functions). An electroencephalogram (EEG) demonstrated interictal right frontotemporal epileptiform activity. A lumbar puncture demonstrated high opening pressure (285 mm H<sub>2</sub>O) with normal content and no detectable oligoclonal bands. She was discharged from the hospital on a regimen of lamotrigine treatment (25 mg/day, with instructions for a slow, gradual increase in the dosage). She returned one week later because of a severe rash over her entire body for which she received prednisone (60 mg/day) and antihistamines (chlorpheniramine maleate, 2 mg bid). The lamotrigine was discontinued, and carbamazepine (100 mg bid, with instructions of a 100-mg/week increase) was started. Two weeks later, she presented with worsening of the rash and reported that she had stopped the steroid therapy without tapering down the dose as instructed. She was admitted to the hospital and treated with IV hydrocortisone and then oral prednisone (1 mg/kg), following a stepwise decrease of the steroid dosage. The carbamazepine was replaced by valproate (with an initial dosage of 250 mg bid). The valproate dose was increased gradually, but the AED treatment was switched to levetiracetam (with an initial oral dosage of 250 mg bid) when she developed thrombocytopenia (down to 25,000/ml) that began 48 h after the first dosage. Her condition subsequently improved, and she was discharged, ending a total of 17 days with either IV or oral steroid therapy. She was instructed to reduce the steroid treatment for several weeks until it was stopped.

<sup>☆</sup> This is an open-access article distributed under the terms of the Creative Commons Attribution-NonCommercial-No Derivative Works License, which permits non-commercial use, distribution, and reproduction in any medium, provided the original author and source are credited.

\* Corresponding author at: Department of Neurology, Tel-Aviv Sourasky Medical Center, 6 Weizmann St., Tel-Aviv, Israel.

E-mail address: [ofer.sadan@gmail.com](mailto:ofer.sadan@gmail.com) (O. Sadan).

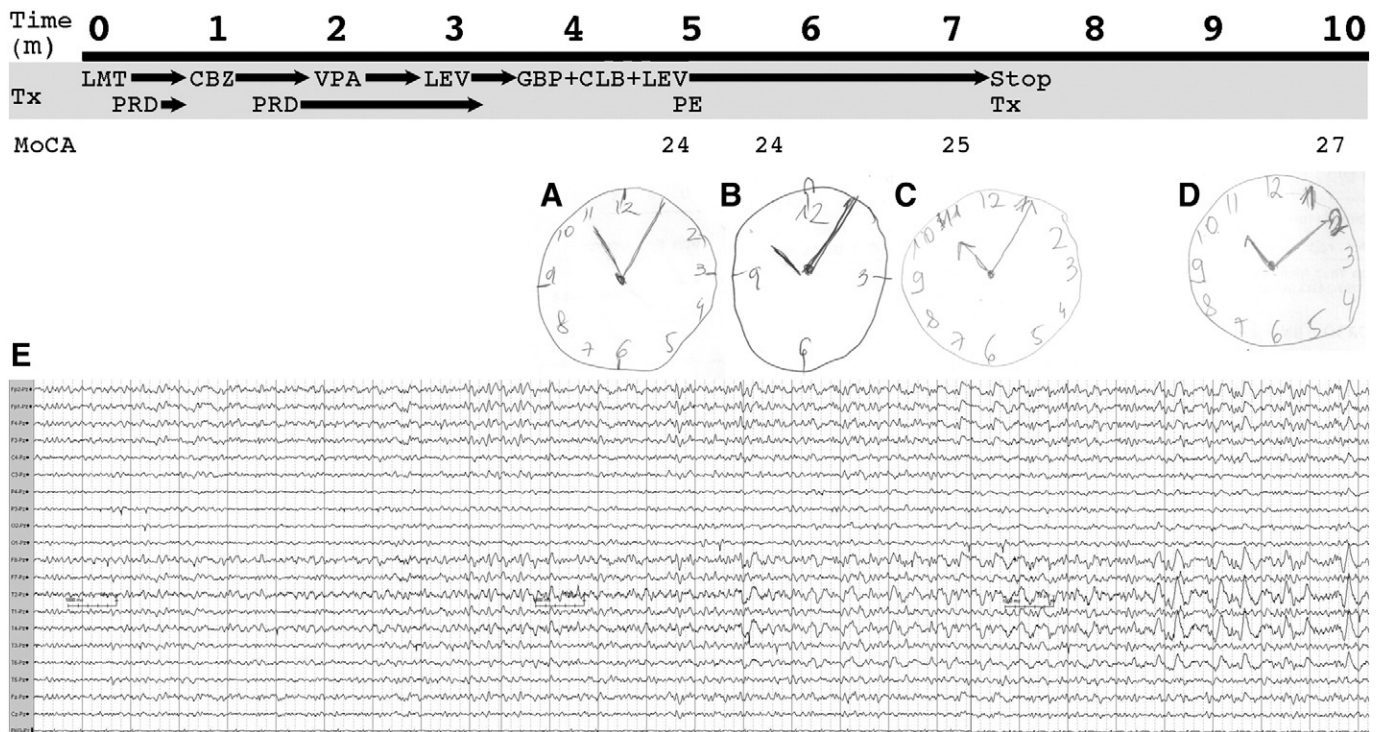
<sup>1</sup> Contributed equally to this manuscript.

A few months later, the patient was readmitted to our department because of cognitive changes, insomnia, and agitation. A brain magnetic resonance imaging (MRI) scan demonstrated asymmetry of the hippocampi without abnormal signal or any other pathological finding. Video-EEG monitoring revealed multiple right temporal electroencephalographic seizures during the night. Serology results for HIV, hepatitis B and C, VDRL, TPHA, and HHV6 were all negative. Thyroid function was normal. A routine rheumatologic workup and testing for antiphospholipid antibodies were negative. Blood samples were sent to test neoplastic markers as well as the following paraneoplastic antibodies: anti-Yo (anti-Purkinje cell cytoplasmic antibody, associated with ovarian and breast cancer) and anti-Hu (antineuronal nuclear antibody type I, associated with small-cell lung cancer). The result of a full gynecological examination including ultrasonography and mammography was normal. She also underwent colonoscopy, which revealed a single polyp whose histology was consistent with high-grade dysplastic adenoma, as well as chest-abdominal and pelvic CT, the results of which were normal. The paraneoplastic laboratory results turned out to be normal. Thus, the only positive finding was extremely high titers of antithyroglobulin (5318 U/ml) and of antithyroid peroxidase (TPO, >3000 U/ml), corresponding to the diagnosis of Hashimoto's encephalitis. Since steroid therapy had been previously administered for the diagnosis of severe drug eruption and found to be ineffective for the clinical presentation of Hashimoto's encephalitis as cognitive changes were added to the clinical picture, she was treated with plasma exchange (5 courses over 10 days). Although no clinical improvement was noted at first, EEG monitoring demonstrated significant improvement after 14 days, with only one EEG-verified electroencephalographic seizure per night, compared to 3–4 electroencephalographic seizures per night before the plasma exchange (Fig. 1E). Cognitive assessment (Montreal Cognitive Assessment [MoCA]) performed before and after plasma exchange revealed a mild cognitive impairment (24/30, mainly attention deficit and memory) that improved by two points after receiving treatment (Figs. 1A–D). She was discharged with the recommendation of continued ambulatory immunomodulatory treatment with

plasma exchange. There was no further improvement in the MoCA score at the 1-month follow-up, but the patient reported that she felt that her cognitive function improved. At that time, she complained of side effects related to the AED treatment (mainly fatigue). She was offered intravenous immunoglobulin (IVIg) treatment which she refused. One month later, she returned for another scheduled outpatient visit, after having stopped all antiepileptic therapy, and felt that she had returned to her regular levels of function, an observation supported by her spouse. She refused to undergo another EEG examination and blood tests. Further follow-up demonstrated clinical and electroencephalographic relapses every few months, with elevated antithyroid antibodies at similar levels, which responded to an additional course of plasma exchange with improvement in her clinical state. Our suggestion was therefore to continue treatment with plasma exchange on a regular basis, and because of the good response, there was no need for more aggressive immunomodulatory treatment.

**3. Case 2**

A 70-year-old woman with a past medical history of well-controlled hypothyroidism and hypertension was admitted to our service because of events manifested by a detachment from her surroundings lasting for about 1 min each that had started 18 months earlier. Some of these began with a scream, following a tonic phase with loss of consciousness. Her EEG and head CT were unremarkable, and oral lamotrigine treatment beginning at 25 mg/day (with instructions for a slow increase) was initiated. A hypersensitivity reaction presenting as a rash all over her body appeared about 10 days later, and the treatment was switched to oral valproate (beginning at a dosage of 250 mg bid with a slow increase). A brain MRI scan demonstrated hyperintense periventricular lesions, suggesting a vascular basis. The valproate treatment did not lead to any significant reduction in the seizure frequency, and oral topiramate (beginning at 25 mg/day) was added. She was then hospitalized because of two seizure events, each lasting up to 15 min, in



**Fig. 1.** Timeline of Case 1. Clock drawing as a sample of the cognitive assessment before plasma exchange (A), after plasma exchange (notice the relative worsening, attributed to the side effects of the treatment) (B), and two (C) and five (D) months following plasma exchange, with increasingly better performance. The clock was fully accurate only on the last test. (E) This representative right temporal electroencephalographic seizure was recorded during a night's sleep. LMT – lamotrigine, CBZ – carbamazepine, VPA – valproate, LEV – levetiracetam, GBP – gabapentin, CLB – clobazam, PRD – prednisone, PE – plasma exchange, MoCA – Montreal Cognitive Assessment.

which she collapsed and was nonresponsive. These events were not accompanied by abnormal movements or loss of consciousness.

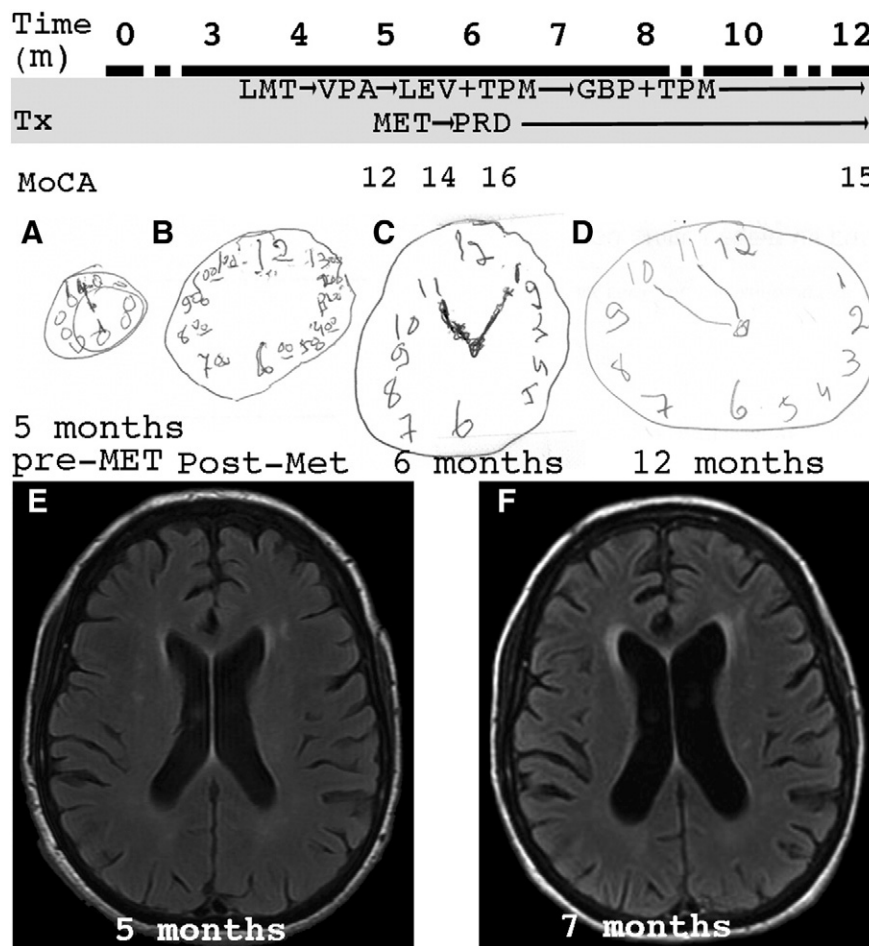
The neurological examination on admission was notable for disorientation and evident cognitive abnormality as demonstrated by a MoCA score of 12/30 (specifically, abnormal serial seven, immediate memory, and abstraction). She exhibited mild extrapyramidal signs and flapping tremor. An EEG showed focal left frontal intermittent slowing. The lumbar puncture had normal opening pressure and content, and the tau protein level was within the normal range. Routine blood work revealed polycythemia and mild leukocytosis, while the electrolyte levels, liver and kidney functions, thyroid functions, C-reactive protein levels, and neoplastic markers were all normal. Routine rheumatologic tests and antiphospholipid antibodies were normal. The only positive relevant result was very high titers of antithyroglobulin (5564 U/ml) and antithyroid microsomal antibody (>3000 U/ml). A repeated brain MRI revealed progressive mild atrophy and a hyperintense temporal cortical signal restricted in diffusion. Methylprednisolone (IV, 500 mg/day for 5 days) was administered, and the valproate was switched to levetiracetam (500 mg bid) because of extrapyramidal side effects. She was released from the hospital with instructions to taper the oral prednisone dosage. She returned three weeks later with an allergic drug reaction, manifested through a skin rash and pruritus, while being treated with 30-mg prednisone (during the tapering down) that was attributed to the levetiracetam. Gabapentin was started in addition to topiramate with disappearance of the rash. The repeated MoCA score was 16/30, suggesting mild improvement. At a follow-up visit several months later, the patient and her family reported

significant improvement. She had returned to her usual levels of function and normal lifestyle, and she was seizure-free. Although we did not notice a prominent cognitive improvement, she did return to her baseline daily function, and, therefore, we did not suggest further immunomodulatory treatment, except for low prednisone dosage (10 mg daily). Further measurement of the antithyroid antibodies demonstrated a marked reduction (anti-TPO: 349 U/ml, antithyroglobulin: 461 U/ml, Fig. 2).

#### 4. Discussion

We describe here two cases of adult-onset temporal lobe epilepsy with cognitive decline and antithyroid antibodies (Hashimoto's encephalopathy), as well as multi-AED hypersensitivity and clinical improvement with immunomodulatory therapy. Hashimoto's encephalopathy has been previously linked to new-onset epilepsy [5–7] and to cognitive changes [6–8]. However, to our knowledge, this is the first report describing multi-AED hypersensitivity coexisting with Hashimoto's encephalopathy.

Hashimoto's encephalopathy is a controversial syndrome, since it is defined as an association of autoantibodies (anti-TPO and antithyroglobulin) and encephalopathy, a weak connection between two common entities without any known causal relationship. Notably, antithyroid antibodies are common (over 10%) in the healthy population [9]. The mechanism of Hashimoto's encephalitis is unclear. Proposed pathogenesis includes autoimmune central nervous system (CNS) vasculitis and an autoimmune reaction to antigens shared by the thyroid



**Fig. 2.** Timeline of Case 2. Clock drawing as a sample of the cognitive assessment before methylprednisolone treatment (A), immediately after the steroid pulse therapy (B), and one month (C) and 7 months (D) following treatment, that began 5 months after the first admission. These drawings demonstrate progressive improvement. T<sub>2</sub> FLAIR axial section at the time of diagnosis (E) and 2 months later (F), showing a progressive periventricular hyperintense signal with increasing atrophy. LMT – lamotrigine, VPA – valproate, LEV – levetiracetam, TPM – topiramate, GBP – gabapentin, MET – methylprednisolone, PRD – prednisone, MoCA – Montreal Cognitive Assessment.

and the CNS. This syndrome can be manifested by a wide range of symptoms and signs, including behavioral changes, confusion, cognitive decline, epileptic seizures, and stroke-like episodes. There is little evidence for delineating the relevant target of antithyroid antibodies in Hashimoto's encephalopathy, although Blanchin et al. demonstrated how anti-TPO antibodies adhere to human astrocytes and monkey-derived cerebellar slices, and Ochi et al. reported neuronal alpha enolase as a target for antithyroid autoantibodies [10,11].

Hashimoto's encephalopathy is probably an immune-based syndrome, not only because of its correlation with autoantibodies but also because of its response to immune-mediated treatment. It is possible that the antithyroid antibodies are markers of a predisposition to the syndrome and not necessarily active participants in the encephalopathic process [3]. Multiple drug hypersensitivity is also an immune-mediated process. One research study demonstrates that patients with multidrug hypersensitivity have a subpopulation of regulatory T-cells which are in a preactivation state, as opposed to healthy controls [12]. Another recent study demonstrated how specific human leukocyte antigens (HLAs) known to predispose to specific drug reactions (e.g., for carbamazepine) activate the immunological system when exposed to the drug [13]. However, no connection between multidrug hypersensitivity and antithyroid autoantibodies has been reported to date. These case reports are intended to raise the level of awareness on immune-based epilepsy and/or dementia, especially since these entities may respond to immunomodulatory therapies [8,14]. Both of our reported patients showed improvement following treatment by steroids or plasma exchange. We suggest that an immune-based etiology should be considered in the differential diagnosis of patients who present with adult-onset temporal epilepsy, especially in patients with idiosyncratic drug reactions.

## Acknowledgment

Esther Eshkol is thanked for editorial assistance.

## References

- [1] McKnight K, Jiang Y, Hart Y, et al. Serum antibodies in epilepsy and seizure-associated disorders. *Neurology* 2005;65:1730–6.
- [2] Brain L, Jellinek EH, Ball K. Hashimoto's disease and encephalopathy. *Lancet* 1966;288:512–4.
- [3] Mocerlin R, Walterfang M, Velakoulis D. Hashimoto's encephalopathy, epidemiology, pathogenesis and management. *CNS Drugs* 2007;21:799–811.
- [4] Zaccara G, Franciotta D, Perucca E. Idiosyncratic adverse reactions to antiepileptic drugs. *Epilepsia* 2007;48:1223–44.
- [5] Ferlazzo E, Raffaele M, Mazzù I, Pisani F. Recurrent status epilepticus as the main feature of Hashimoto's encephalopathy. *Epilepsy Behav* 2006;8:328–30.
- [6] Olmez I, Moses H, Sriram S, et al. Diagnostic and therapeutic aspects of Hashimoto's encephalopathy. *J Neurol Sci* 2013;331:67–71.
- [7] Mazzù I, Mosti S, Caltagirone C, Carlesimo GA. Hashimoto's encephalopathy: neuropsychological findings. *Neurol Sci* 2012;33:653–6.
- [8] Flanagan EP, McKeon A, Lennon VA, et al. Autoimmune dementia: clinical course and predictors of immunotherapy response. *Mayo Clin Proc* 2010;85:881–97.
- [9] Hollowell JG, Staehling NW, Flanders WD, et al. Serum TSH, T4, and thyroid antibodies in the United States population (1988 to 1994): National Health and Nutrition Examination Survey (NHANES III). *JCEM* 2002;87:489–99.
- [10] Blanchin S, Coffin C, Viader F, et al. Anti-thyroperoxidase antibodies from patients with Hashimoto's encephalopathy bind to cerebellar astrocytes. *J Neuroimmunol* 2007;192:13–20.
- [11] Ochi H, Horiuchi I, Araki N, et al. Proteomic analysis of human brain identifies alpha-enolase as a novel autoantigen in Hashimoto's encephalopathy. *FEBS Lett* 2002;528:197–202.
- [12] Daubner B, Groux-Keller M, Hausmann OV, et al. Multiple drug hypersensitivity: normal Treg cell function but enhanced in vivo activation of drug-specific T cells. *Allergy* 2012;67:58–66.
- [13] Illing PT, Vivian JP, Dudek NL, Kostenko L, et al. Immune self-reactivity triggered by drug-modified HLA-peptide repertoire. *Nature* 2012;486:554–8.
- [14] Quek AM, Britton JW, McKeon A, et al. Autoimmune epilepsy. *Arch Neurol* 2012;69:582–93.