

A case report of an interrupted inferior vena cava and azygos continuation: implications for preoperative screening in minimally invasive cardiac surgery

Wiebe G. Knol ^{1,2*}, Frans B. Oei¹, Ricardo P.J. Budde², and Maarten ter Horst ³

¹Department of Cardiothoracic Surgery, Erasmus Medical Center, Rg-620, PO Box 2040, 3000-CA Rotterdam, The Netherlands; ²Department of Radiology and Nuclear Medicine, Erasmus Medical Center, Rg-620, PO Box 2040, 3000-CA Rotterdam, The Netherlands; and ³Department of Cardiothoracic Anesthesiology, Erasmus Medical Center, Rg-620, PO Box 2040, 3000-CA Rotterdam, The Netherlands

Received 1 May 2021; first decision 31 May 2021; accepted 13 July 2021; online publish-ahead-of-print 29 July 2021

Background

Femoral cannulation is commonly used in minimally invasive cardiac surgery to establish extracorporeal circulation. We present a case with a finding that should be evaluated when screening candidates for minimally invasive cardiac surgery.

Case summary

A 57-year-old male patient was scheduled for minimally invasive repair of the mitral and tricuspid valve and a MAZE procedure. During surgery there was difficulty advancing the venous cannula inserted in the right femoral vein. On transoesophageal echocardiography a guidewire advanced from the femoral vein was observed entering the right atrium from the superior vena cava. Despite inserting a second venous cannula in the jugular vein, venous drainage was insufficient for minimal invasive surgery. The approach was converted to a median sternotomy with bicaval cannulation. Re-examination of the preoperative computed tomography (CT) scan showed an interrupted inferior vena cava (IVC) with azygos continuation.

Discussion

In patients with major venous malformations such as the interrupted IVC with azygos continuation a full sternotomy is the preferred approach. The venous system should be evaluated when screening candidates for minimally invasive mitral valve surgery with preoperative CT. Additional cues to suspect interruption of the IVC are polysplenia and a broad superior mediastinal projection on the chest radiograph, mimicking a right paratracheal mass.

Keywords

Minimally invasive cardiac surgery • Preoperative screening • Venous malformation • Case report

Learning points

- Preoperative computed tomography can aid patient selection and guide surgical strategy prior to minimally invasive cardiac surgery.
- Next to ilioaortic atherosclerosis, aortic dilatation, and iliac vessel diameter and tortuosity, the venous system should be evaluated for malformations.
- Cues to suspect interruption of the inferior vena cava are polysplenia and a broad superior mediastinal projection on the chest radiograph, mimicking a right paratracheal mass.

*Corresponding author. Tel: +31 010-7035411, Email: w.knol@erasmusmc.nl

Handling Editor: Michel Pompeu Sá

Peer-reviewers: Marcelo Haertel Miglioranza; Roman Gottardi; Andras Jonosi

Compliance Editor: Hibba Kurdi

Supplementary Material Editor: Mariame Chakir

© The Author(s) 2021. Published by Oxford University Press on behalf of the European Society of Cardiology.

This is an Open Access article distributed under the terms of the Creative Commons Attribution Non-Commercial License (<http://creativecommons.org/licenses/by-nc/4.0/>), which permits non-commercial re-use, distribution, and reproduction in any medium, provided the original work is properly cited. For commercial re-use, please contact journals.permissions@oup.com

Introduction

Femoral cannulation is commonly applied in minimally invasive cardiac surgery to establish extracorporeal circulation (ECC). Preoperative computed tomography (CT) is frequently used, among others to rule out aortoiliac atherosclerosis and prevent retrograde cerebral embolization.¹ We describe an additional finding to evaluate on preoperative CT prior to minimally invasive cardiac surgery with femoral cannulation.

Timeline

Day 0	Hospital admission for collapse, with decompensated heart failure and new-onset atrial fibrillation Diagnosis of underlying moderate tricuspid regurgitation with annular dilatation >40 mm and severe mitral regurgitation due to a flail posterior mitral valve leaflet Management: antidiuretic therapy, rate control, and workup for surgical intervention
Day 17	Transfer to a tertiary referral centre with cardiac surgery unit for surgical intervention
Day 18	Tricuspid and mitral valve repair with concomitant MAZE procedure. Conversion from anterolateral thoracotomy to median sternotomy for insufficient venous drainage
Day 23	Discharge after uneventful recovery Review of a preoperative computed tomography scan shows an interrupted inferior caval vein with azygos continuation

Case presentation

A 57-year-old male Caucasian patient presented to the hospital with decompensated heart failure and new-onset atrial fibrillation. Besides varicose veins there was no past medical history. A trans-thoracic and transoesophageal echocardiography (TOE) revealed moderate tricuspid regurgitation with annular dilatation >40 mm (normal value 28 ± 5 mm, with a cut-off value <35 mm) and severe mitral regurgitation due to a flail posterior mitral valve leaflet.² After a Heart Team meeting a workup was initiated for minimally invasive repair of the mitral and tricuspid valve and a MAZE procedure. An invasive angiography ruled out coronary heart disease and the report of a non-contrast-enhanced CT scan performed in another hospital described no calcifications in the aortic arch or iliac arteries, with adequate diameters for arterial and venous cannulation. However, during surgery there was difficulty advancing the venous cannula inserted in the right femoral vein. On TOE monitoring the guidewire was seen entering the right atrium from

the superior vena cava (SVC) (*Video 1*). In addition, the guidewire was observed in the azygos vein between the oesophagus and the descending aorta (*Video 2*). An attempt to initiate ECC failed because of inadequate venous drainage of the right femoral cannula. A second venous catheter was inserted in the right internal jugular vein and ECC was initiated. Filling of the heart persisted and venous drainage with both venous cannula's remained insufficient for surgery. The decision was made to convert to full sternotomy. A single-stage venous cannula was inserted in the vein entering the right atrium at the usual insertion site of the inferior caval vein, after which ECC was successfully initiated. Both valves were repaired and the MAZE procedure was performed without further complications. The postoperative recovery was uneventful, and the patient was discharged 5 days after surgery. Re-examination of the preoperative CT scan by the radiologist in our hospital revealed an interruption of the inferior vena cava (IVC) just above the renal veins, with azygos continuation and the hepatic veins draining with one common ostium into the right atrium. Polysplenia was also observed.

Discussion

The femoral arteries and veins are easily accessible and provide a safe route to bypass heart and lungs in patients without aortoiliac atherosclerosis.³ Patients with atherosclerosis are at increased risk of retrograde cerebral embolization and preoperative CT screening can be used to prevent this.¹ Computed tomography also allows the diameters of the femoral vessels to be evaluated to verify that femoral cannulation is possible. Our case shows the importance of checking the course of the venous anatomy to rule out malformations, even though this can be more difficult in a non-contrast-enhanced scan.

In retrospect, the inadequate venous drainage was caused by the hepatic venous return. The IVC was interrupted above the renal veins and continued along the course of the azygos vein (see the yellow arrow in *Figure 1, 2B*). The common hepatic vein (red arrow in *Figure 1, 2B*), that connects the hepatic venous return to the right atrium at the usual insertion location of the IVC, could be regarded as a 'hepatic part of the IVC' or as a common hepatic vein. Since there is no connection between these hepatic veins and the IVC below the interruption, we used the latter. This common hepatic vein is thus isolated from percutaneous access.

During embryological development the IVC is formed by fusion of five different segments. Agenesis of one of these segments or failed fusion leads to interruption of the IVC.⁴ The interrupted IVC with azygos or hemiazygos continuation is a rare condition, with a prevalence of 0.15%.⁴ It is more frequent in patients with congenital heart disease and often coincides with polysplenia, as was present in our patient. Another cue to suspect azygos continuation is a widened superior mediastinal projection on the chest radiograph, mimicking a right paratracheal mass.⁵ On ultrasound, the absence of the IVC and in some patients the insertion of several hepatic veins directly into the right atrium are pathognomonic signs.

Peripheral ECC cannulation can be guided by fluoroscopy or by visual confirmation of guidewire and cannula by TOE.⁶ Since fluoroscopy requires a hybrid operation theatre, echography is frequently applied for valve evaluation and guidance of peripheral cannulation in

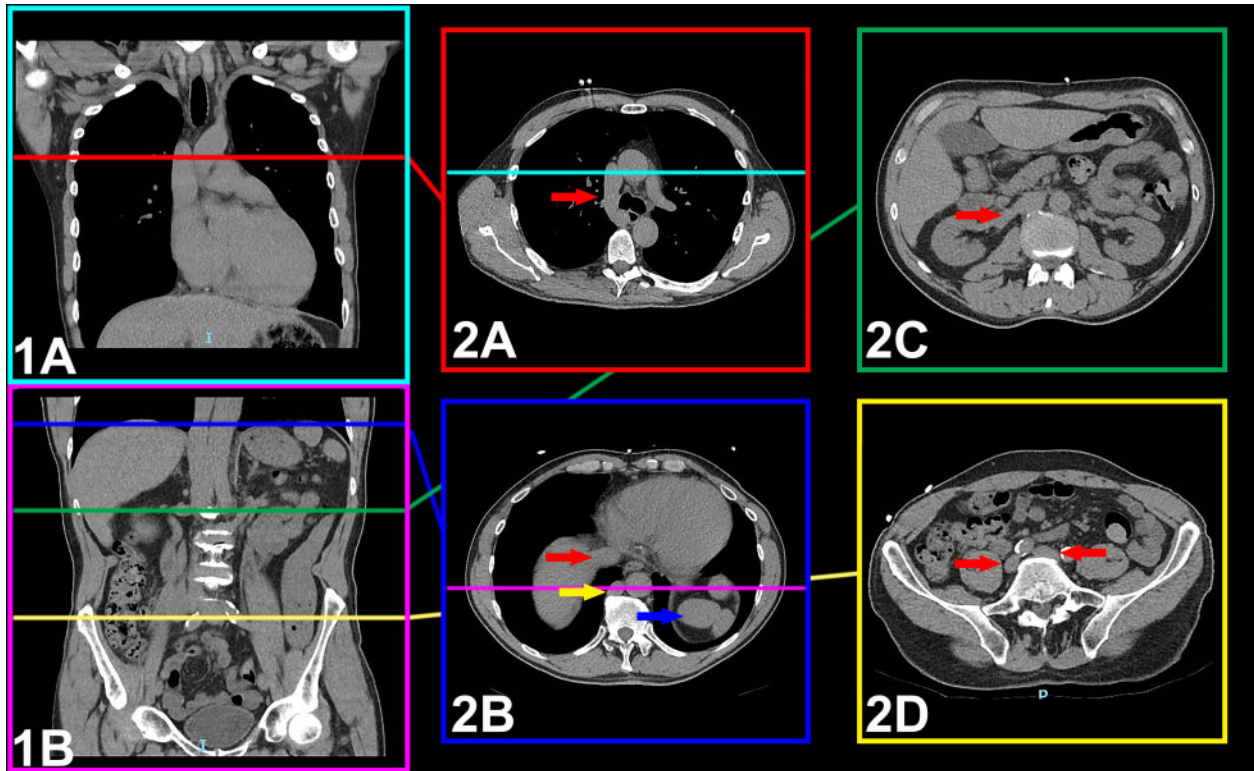
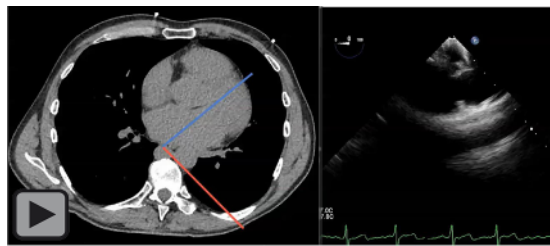
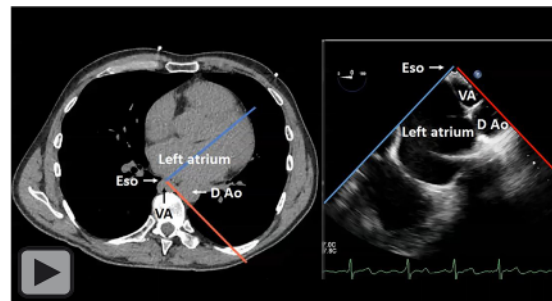


Figure 1 Preoperative computed tomography images. (1A and 1B) The coloured lines show the level of the axial views. (2A) The insertion of the azygos vein into the superior vena cava. (2B) Red arrow: the common hepatic vein inserting into the right atrium, while the inferior vena cava continues as the azygos vein (yellow arrow). Blue arrow: polysplenia, an important sign in heterotaxy syndromes. (2C) The insertion of the right renal vein into the inferior vena cava, as usual. (2D) The common iliac veins, joining to form the inferior vena cava.



Video 1 Intraoperative transoesophageal echocardiography shows the guidewire entering the right atrium via the superior vena cava.



Video 2 Intraoperative transoesophageal echocardiography shows the guidewire in the azygos vein between the oesophagus and the descending aorta. Transoesophageal echocardiography view boundaries correspond to computed tomography (red = right, blue = left).

minimally invasive cardiac surgery. This case also emphasizes the additional value of an experienced cardiothoracic anaesthesiologist or cardiologist to perform a comprehensive TOE, supporting intraoperative decision-making.

Previous cases with an interrupted IVC undergoing cardiac surgery have been described. One patient undergoing coronary artery bypass grafting suffered a postoperative deterioration in liver function after inadequate hepatic vein drainage. A two-stage venous cannula,

inserted in the right atrium, partially blocked the, likely narrower, ostium of the hepatic vein. The authors recommended a single-stage cannula for adequate venous drainage.⁷ Nevertheless, when right atrial access is not required, a two-stage cannula adequately

Table 1 Relevant findings on preoperative CT and subsequent management.

Surgical procedure	CT finding	Management options
Cannulation	Ilioortic calcification/atherosclerosis	Avoid femoral arterial cannulation or even aortic clamping
	Ilioortic vessel diameter and tortuosity	Avoid femoral cannulation
	Venous malformation	Adapt appropriate venous cannulation strategy to ensure adequate drainage
Clamping	Ascending aortic dilatation	Avoid endoballoon occlusion
Surgical exposure	Thoracic deformities, level of left atrium, Waterston's groove, and the mitral valve in relation to the right hemidiaphragm	Adjust the intercostal entry level, or use full sternotomy in case of severe pectus excavatum
	Mitral annular calcification	Reconsider surgical strategy

CT: computed tomography.

positioned under TOE guidance is also a viable option. Another patient, with additional dextrocardia, situs inversus, dilated aortic annulus, and bilateral SVCs, underwent a Bentall procedure and mitral valve replacement. After careful planning of the surgical approach including a CT scan, a median sternotomy was used and four venous cannulas were inserted in the right femoral vein, both SVCs and the hepatic vein.⁸

Only one prior publication mentions the possibility of a minimally invasive approach using a left thoracotomy in six patients. In two patients the left atrioventricular valve was replaced using venous cannulation of the innominate vein and the main pulmonary artery.⁹ The authors describe excellent exposure of the left atrioventricular valve. However, this approach does not expose the tricuspid valve, and would therefore not have sufficed in our patient. Moreover, the conventional median sternotomy is the most familiar approach, offering exposure to the entire chest cavity and flexibility to deal with unforeseen complications. In patients with venous malformations such as an interrupted IVC and without contra-indications, a median sternotomy is our preferred approach.

Preoperative CT can be used to select patients scheduled for minimally invasive cardiac surgery and to guide the surgical strategy.¹⁰ Table 1 shows the main findings to look out for when evaluating these scans. The need for contrast enhancement remains unclear, although most studies reporting outcomes of minimally invasive surgery with preoperative screening use contrast.¹ It facilitates evaluation of vascular structures and provides more information on the severity of atherosclerosis. Indeed, in a recent study in 270 patients undergoing minimally invasive surgery, aortic wall thickness successfully selected candidates for safe femoral cannulation.¹¹ This, however, comes at the cost of a risk of renal dysfunction and allergic reactions secondary to the use of contrast medium.¹²

Conclusion

When screening patients with a CT scan prior to minimally invasive cardiac surgery using femoral cannulation, the presence of venous malformations such as interruption of the inferior caval vein needs to be evaluated and the cannulation strategy adjusted accordingly.

Polysplenia or the presence of a widened mediastinum or right paratracheal mass could indicate the presence of an interrupted IVC with azygos continuation.

Lead author biography



Wiebe G. Knol (1990) obtained his medical degree at the Erasmus University Rotterdam, the Netherlands in 2016 and is currently affiliated to the Departments of Cardiothoracic Surgery and Radiology of this institution as a PhD candidate.

Supplementary material

Supplementary material is available at *European Heart Journal - Case Reports* online.

Slide sets: A fully edited slide set detailing this case and suitable for local presentation is available online as [Supplementary data](#).

Consent: The authors confirm that written consent for submission and publication of this case report including images and associated text has been obtained from the patient in line with COPE guidance.

Conflict of interest: None declared.

Funding: None declared.

References

- Leonard JR, Henry M, Rahouma M, Khan FM, Wingo M, Hameed I et al. Systematic preoperative CT scan is associated with reduced risk of stroke in

- minimally invasive mitral valve surgery: a meta-analysis. *Int J Cardiol* 2019;**278**: 300–306.
2. Lancellotti P, Moura L, Pierard LA, Agricola E, Popescu BA, Tribouilloy C et al; European Association of Echocardiography. European Association of Echocardiography recommendations for the assessment of valvular regurgitation. Part 2: mitral and tricuspid regurgitation (native valve disease). *Eur J Echocardiogr* 2010;**11**:307–332.
 3. Barbero C, Marchetto G, Ricci D, El Qarra S, Attisani M, Filippini C et al. Right minithoracotomy for mitral valve surgery: impact of tailored strategies on early outcome. *Ann Thorac Surg* 2016;**102**:1989–1994.
 4. Koc Z, Oguzkurt L. Interruption or congenital stenosis of the inferior vena cava: prevalence, imaging, and clinical findings. *Eur J Radiol* 2007;**62**: 257–266.
 5. Ganju N, Kandoria A, Mahajan K, Sharma R. Right paratracheal mass on chest X-ray: an important part of the checklist before cardiac catheterisation. *BMJ Case Rep* 2016;**2016**.
 6. Ahn HJ, Lee JW, Joo KH, You YH, Ryu S, Lee JW et al. Point-of-care ultrasound-guided percutaneous cannulation of extracorporeal membrane oxygenation: make it simple. *J Emerg Med* 2018;**54**:507–513.
 7. Pillai JB, Kpodonu J, Yu C, Borger MA. Heterotaxy syndrome with azygous continuation-causing pseudo Budd-Chiari syndrome after cardiopulmonary bypass. *Ann Thorac Surg* 2006;**81**:1890–1892.
 8. Yokoyama Y, Satoh H, Abe M, Nagashima M, Kurata A, Higashino H. Cardiac surgery for annuloaortic ectasia and mitral regurgitation in an adult patient with dextrocardia. *Gen Thorac Cardiovasc Surg* 2011;**59**:341–343.
 9. Suzuki T, Masuoka A, Uno Y, Iwazaki M, Yamagishi S, Katogi T. Cardiopulmonary bypass through a left thoracotomy using venous drainage from the innominate vein in congenital heart surgery. *J Card Surg* 2013;**28**:591–594.
 10. Heuts S, Maessen JG, Sardari Nia P. Preoperative planning of left-sided valve surgery with 3D computed tomography reconstruction models: sternotomy or a minimally invasive approach? *Interact CardioVasc Thorac Surg* 2016;**22**: 587–593.
 11. Nakamura Y, Nishijima S, Kuroda M, Nakayama T, Tsuruta R, Yoshiyama D et al. Perfusion strategy using axillary or femoral cannulation for minimally invasive cardiac surgery: experience in 270 patients with computed tomography-based criteria. *Eur J Cardiothorac Surg* 2021;**59**:1200–1207.
 12. Rose TA Jr, Choi JW. Intravenous imaging contrast media complications: the basics that every clinician needs to know. *Am J Med* 2015;**128**:943–949.