

CNNM2 Heterozygous Variant Presenting as Hypomagnesemia and West Syndrome: Expanding the Spectrum of CNNM2 Gene-Related Epileptic Disorders

Dear Editor,

West syndrome (WS) is one of the few most common early infantile epileptic encephalopathy. Although structural etiology contributes to a significant proportion of WS in developing countries, at the same time monogenic variants also play a critical role in the pathogenesis.^[1] More than 60 EIEE genes have been identified till date, out of which the majority can cause west syndrome and the number is increasing every year.^[2-4] Mutations in the *CNNM2* gene originally described to be associated with renal hypomagnesemia and recently also have been reported to be associated with seizures and developmental delay. However, mutations in the *CNNM2* gene have never been associated with WS. Here, we are reporting for the first time a 4-month-old girl with WS caused by de novo novel heterozygous pathogenic mutation in the *CNNM2* gene.

A 4-month-old female infant firstborn to a non-consanguineous couple with an uneventful perinatal period, presented with flexor epileptic spasms occurring in the clusters, especially at sleep-wake transition for 1 week. There was no family history of any neurological disorder. Her developmental milestones, anthropometry, and physical examination were normal. Blood sugar, arterial blood gas (pH-7.35, pCO₂-32, pO₂-84, HCO₃-23), serum calcium (9.4 mg/dl), serum sodium (137 mEq/l), serum phosphate (4.6 mg/dl), serum potassium (4.2 mEq/l), fractional excretion of potassium (4.2%), serum parathyroid hormone (46 pg/ml), and vitamin D levels were within normal limits except serum hypomagnesemia (0.46 mmol/L, range: 0.7–1.15 mmol/L). Serum biotinidase levels, Tandem mass spectrometry, and urinary organic acid profile were also normal. Her electroencephalography (EEG) showed a modified hypsarrhythmia pattern [Figure 1] and magnetic resonance imaging (MRI) of the brain was normal. Ultrasonography of the abdomen did not show any nephrocalcinosis.

She was started on intravenous magnesium supplementation, but the hypomagnesemia and epileptic spasms persisted. The seizures did not respond to an adequate trial of pyridoxine, pyridoxal phosphate, folic acid, and biotin. Subsequently, she was started on intramuscular adrenocorticotropin hormone (ACTH) injection and her epileptic spasms reduced by around 80% in frequency. Later, she also developed the arrest of developmental milestones and seizures of other semiology like tonic and focal clonic seizures and required multiple antiepileptic drugs (valproate[50 mg/kg/day], levetiracetam[50 mg/kg/day], clobazam). The hypomagnesemia also persisted, along

with increased fractional excretion of magnesium (8.4%, normal 0.5-4%). Next-generation sequencing detected a novel heterozygous missense variant in exon 1 of the *CNNM2* gene (c.82G>A) that results in the amino acid substitution of Threonine for Alanine at codon 28 (p.Ala28Thr; ENST00000369878.4). The *in silico* predictions of the variant was found to be possibly damaging by PolyPhen-2 (HumDiv) and deleterious by SIFT, LRT, MutationTaster2, and Mutation Assessor. The final PROVEAN score of the protein variant was also found to be deleterious. The evolutionary conservation of the putative pathogenic mutation was also assessed by the HomoloGene tool. The variant could not be detected in any of the parents on Sanger sequencing and most probably is of de novo origin. The parents were counseled regarding the nature and prognosis of the disease. After 1 year of follow-up, she was found to have microcephaly, global developmental delay (the developmental quotient of 45 on the developmental assessment of Indian infants-2), central hypotonia, and brief infrequent tonic seizures (1--2 episodes/week). The follow-up EEG at 16 months of age showed frequent spikes and polyspikes-wave discharges [Figure 2]. However, no repeat neuroimaging could be performed on the follow-up to look for the evolution of any new abnormality.

Hypomagnesemia is a known etiology for seizures in neonates and infants, but in most cases, it is associated with hypocalcemia, as hypomagnesemia causes resistance to parathormone secretion. However, in such cases, correction of electrolyte abnormality leads to control of seizures and normal developmental outcome.^[5] But in rare monogenetic disorders caused by mutations in *TRPM6* and *TRPM7* genes may cause seizures, migraine, intellectual disability, and depression, along with hypomagnesemia. Hypomagnesemia, seizures, and mental retardation 1 (HOMGSMR1) (OMIM*607803) is another recently described disorder caused by both monoallelic and biallelic mutations in the *cyclin M2 (CNNM2)* gene. Till date, seven kindreds from various parts of the world have been described by three different study groups.^[6-8]

The Cystathionine-β-synthase (CBS)-pair domain divalent metal cation transport mediators (CNNMs) are involved in maintaining Mg²⁺ homeostasis. Among them CNNM2 is ubiquitously expressed in the brain, lung, spleen, testes, liver, and heart, thus mutations in this gene are likely to cause developmental delay and seizures. CNNM2 encoded protein either itself is an Mg²⁺ transporter or regulates proteins involved in its transport. The mutation in exon 1 in our case most probably distorted the large 64 amino acid signal peptide located at the N-terminal extracellular domain or CBS-par

domain in the cytosolic region and led to conformational changes in the protein. These domains have been described in the literature to be essential for Mg²⁺-ATP binding or phosphatases of regenerating liver (PRL) binding and thus mutations affecting these crucial domains are likely to cause pathogenic loss of function mutations.

Arjona *et al.*^[6] were first to describe six children with this rare illness from five different German kindreds in 2014. All of them had de novo heterozygous missense mutations, except one kindred who had homozygous recessively inherited mutations from consanguineous parents and had severe presentation beginning from the neonatal period. Severe phenotype with neonatal-onset epileptic encephalopathy refractory to multiple antiepileptic drugs and brain malformations has also been reported by Accogil *et al.*^[7] in another recessively inherited case.

Four out of five patients with heterozygous mutations described by Arjona *et al.*^[6] had seizure onset between 4 and 12 months like our case. All these cases subsequently developed limited

motor skills and social communication and even one patient developed characteristic features of autism.

None of the reported cases till date has been described to manifest epileptic spasms like our case and it widens the clinical spectrum of epilepsy associated with the *CNNM2* mutations. Valproate, lamotrigine, topiramate, and clobazam were various antiepileptic drugs tried in previous cases.^[6,7] Three reported cases with homozygous mutations till now had drug-resistant epilepsy, like our case. Relatively more severe epilepsy in our case despite heterozygous mutation, that is, presence of West syndrome might be because of the characteristics of the novel mutation. In all reported children with *CNNM2* mutations, seizures persisted despite multiple efforts attempting at correcting hypomagnesemia and required multiple antiepileptic drugs. These cases also had normal serum calcium levels, no evidence of nephrocalcinosis on kidney ultrasound, and renal sodium wasting as measured

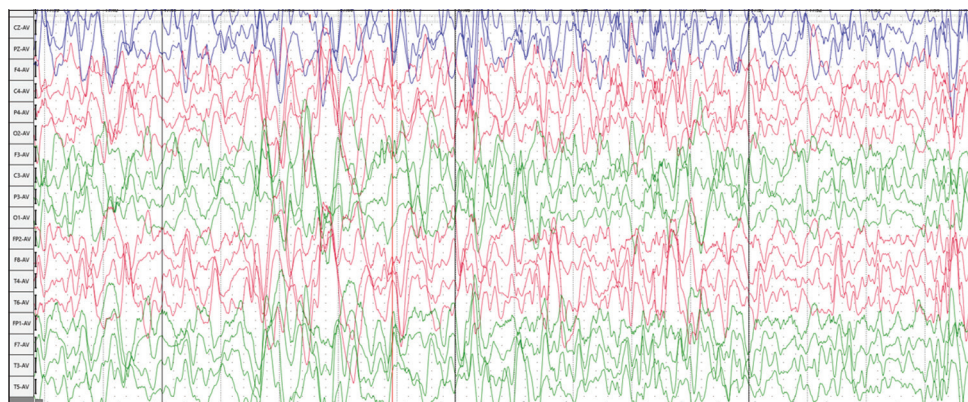


Figure 1: A sedated electroencephalogram at 4-months of age (international 10-20 system, average montage, sensitivity: 7µV/mm, sweep speed: 30 mm/sec, low filter: 1 Hz and high filter 70 Hz) showing disorganized, asynchronous, chaotic high amplitude slow waves activity with interspersed multifocal spikes suggestive of Hypsarrhythmia

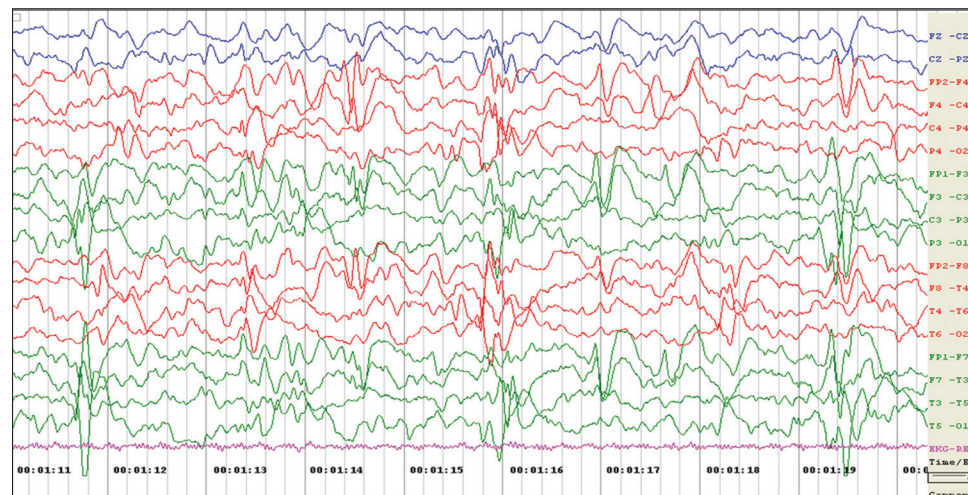


Figure 2: A sedated electroencephalogram at 16-months of age (international 10-20 system, bipolar montage, sensitivity: 7.5µV/mm, sweep speed: 30 mm/sec, low filter: 1 Hz and high filter 70 Hz) showing asymmetric and asynchronous generalized (frontal dominant), high amplitude spike-slow wave complexes with frequent polyspikes

by inappropriately high fractional excretion of magnesium, despite low serum magnesium level, resembling our case. Even on follow-up, all cases continued to have low serum magnesium levels.

One female case with a heterozygous variant reported by Arjona *et al.*^[6] had a mild intellectual disability, apart from myoclonus, muscle spasm, and dysesthesia from 16 years of age, without any definite clinical seizures in early childhood. A similar mild clinical presentation has also been reported by Khalaf-Nazall *et al.*,^[8] in multiple family members spanning over three generations in a family harboring heterozygous CNNM2 mutation with autosomal dominant inheritance. Apart from mild impairment in fine motor skills like dyslalia and dyslexia, they had no other neurological abnormalities. However, all of them had hypomagnesemia and hypermagnesuria, refractory to oral magnesium supplementation. The same authors described another family cohort with heterozygous CNNM2 variants presenting with a magnesium independent neurodevelopmental phenotype with intellectual disability, autism spectrum disorder, and cone-rod dystrophy causing visual impairment, but no clinical seizures.^[8] Thus, clinicians need to remember although CNNM2 mutations associated disorder has been initially described as an autosomal recessive disorder, it can present with neurological symptoms, even with epileptic spasms and low serum magnesium levels, in the heterozygous state and accordingly should provide appropriate genetic counseling to parents.

To conclude, the current case highlights the importance of considering the possibility of underlying CNNM2 mutations when the child presents with epileptic spasms and persistent hypomagnesemia. Clinicians also need to rule out hypomagnesemia in children having an epileptic spasm, without any apparent definite cause clinically and should order a renal ultrasound, if they obtain low serum magnesium levels.

Financial support and sponsorship

Nil.

Conflicts of interest

There are no conflicts of interest.

Prateek K. Panda, Radhapyari Lourembam, Indar K. Sharawat

Pediatric Neurology Division, Department of Pediatrics, All India Institute of Medical Sciences, Rishikesh, Uttarakhand, India

Address for correspondence: Dr. Indar K. Sharawat, Associate Professor and Chief, Pediatric Neurology Division, Department of Pediatrics, All India Institute of Medical Sciences, Rishikesh - 249 203, Uttarakhand, India.
E-mail: sherawatdrindar@gmail.com

REFERENCES

1. Paciorkowski AR, Thio LL, Dobyns WB. Genetic and biologic classification of infantile spasms. *Pediatr Neurol* 2011;45:355-67.
2. Peng J, Wang Y, He F, Chen C, Wu L-W, Yang L-F, *et al.* Novel West syndrome candidate genes in a Chinese cohort. *CNS Neurosci Ther* 2018;24:1196-206.
3. Sharawat IK, Kasinathan A, Sahu JK, Sankhyan N. Response to carbamazepine in KCNQ2 related early infantile epileptic encephalopathy. *Indian J Pediatr* 2019;86:301-2.
4. Sharawat IK, Yadav J, Saini L. Novel GRIN2B mutation: A rare cause of severe epileptic encephalopathy. *Neurol India* 2019;67:562-3.
5. Sood A, Grover N, Sharma R. Biochemical abnormalities in neonatal seizures. *Indian J Pediatr* 2003;70:221-4.
6. Arjona FJ, de Baaij JHF, Schlingmann KP, Lameris ALL, van Wijk E, Flik G, *et al.* CNNM2 mutations cause impaired brain development and seizures in patients with hypomagnesemia. *PLoS Genet* 2014;10:e1004267.
7. Accogli A, Scala M, Calcagno A, Napoli F, Di Iorgi N, Arrigo S, *et al.* CNNM2 homozygous mutations cause severe refractory hypomagnesemia, epileptic encephalopathy and brain malformations. *Eur J Med Genet* 2019;62:198-203.
8. Khalaf-Nazzal R, Giménez-Mascarell P, Dweikat IM, Oyenarte I, Müller D, Claverie-Martín F, *et al.* Phenotypic and genetic heterogeneity linked to the magnesium transport mediator CNNM2. Conference Abstract: 2nd International Conference on Educational Neuroscience. *Frontiers*. 2017. doi: 10.3389/conf.fnhum.2017.222.00035.

Submitted: 21-Nov-2020 **Revised:** 07-Dec-2020 **Accepted:** 11-Dec-2020

Published: 04-Feb-2021

This is an open access journal, and articles are distributed under the terms of the Creative Commons Attribution-NonCommercial-ShareAlike 4.0 License, which allows others to remix, tweak, and build upon the work non-commercially, as long as appropriate credit is given and the new creations are licensed under the identical terms.

DOI: 10.4103/aian.AIAN_1130_20