

# Arthroscopic Bennett Lesion Resection and Posterior Labral Repair Using All-Suture Anchors



Matthew R. Cohn, M.D., Allison K. Perry, B.S., Daniel J. Kaplan, M.D.,  
Steven F. DeFroda, M.D., M. Eng., Harsh Singh, B.A., Michael Fu, B.A., and  
Nikhil N. Verma, M.D.

**Abstract:** The Bennett lesion is an extra-articular ossification at the posteroinferior glenoid rim that is common among overhead-throwing athletes. While the majority of these exostoses are asymptomatic, some may cause posterior shoulder pain during throwing motion and frequently have concomitant posterior labral tears. Multiple approaches to Bennett lesion resection have been described, and there is debate regarding the need for capsulotomy, posterior labral repair, and capsular repair. The purpose of this article is to describe our preferred surgical technique for arthroscopic Bennett lesion resection and posterior labral repair using knotless all-suture anchors.

The Bennett lesion, also known as thrower's exostosis, is a calcification located at the posterior glenoid rim that is common in throwing athletes.<sup>1,2</sup> An incidence of approximately 22% has been reported among professional baseball pitchers.<sup>3</sup> Exostoses in several locations along the posterior glenoid may be referred to as Bennett lesions<sup>2</sup>; however, the conventional location originally described by Bennett refers to

an extra-articular ossification at the posteroinferior glenoid rim.<sup>1</sup> Although this lesion was initially thought to be due in part to an epiphysitis of the triceps origin,<sup>1</sup> it is now believed to be reactive bone formation in the posterior capsule and posterior inferior glenohumeral ligament due to repeated traction.<sup>4-8</sup>

These lesions are often asymptomatic and are a normal physiologic adaptation to repetitive throwing motion in some cases. However, local inflammation of the joint capsule and axillary nerve or fracture of the lesion and subsequent nonunion may result in posterior shoulder pain.<sup>7</sup> Whereas posterosuperior exostoses and associated internal impingement may cause pain during the late cocking and early acceleration phases,<sup>9</sup> throwers with a classic Bennett lesion often have pain during the follow-through phase.<sup>10,11</sup> Symptoms related to these lesions are initially treated nonoperatively, with physical therapy focused on posterior capsular stretching (i.e., sleeper stretch) and strengthening of the rotator cuff.<sup>2</sup> Excision of the Bennett lesion and addressing associated intra-articular pathology are considered in patients with recalcitrant symptoms or inability to return to previous level of activity despite 3 to 6 months of nonoperative treatment.

Concomitant labral tears are common and may contribute to patients' symptoms.<sup>4</sup> Meister et al.<sup>4</sup> reported that 68% of collegiate or professional baseball players with Bennett lesions had associated posterior labral tears. It is unclear how to best address labral pathology in this setting. Some prefer labral repair with suture anchor constructs, whereas others routinely perform labral debridement in the presence of fraying or small tears.<sup>2</sup>

*From the Division of Sports Medicine, Midwest Orthopaedics at Rush, Rush University Medical Center, Chicago, Illinois (M.R.C., A.K.P., S.F.D., H.S., N.N.V.); Department of Orthopedic Surgery, New York University Langone Health New York, New York (D.J.K.); and Division of Sports Medicine, Hospital for Special Surgery, New York, New York (M.F.), U.S.A.*

*The authors report the following potential conflicts of interest or sources of funding: S.F.D. reports board member/committee appointments for American Academy of Orthopaedic Surgeons. M.F. reports editorial or governing board: Arthroscopy, HSS Journal; and paid presenter or speaker: DJ Orthopaedics. N.N.V. reports board or committee member: American Orthopaedic Society for Sports Medicine, American Shoulder and Elbow Surgeons, and Arthroscopy Association of North America; research support: Arthrex, Breg, Ossur, Smith & Nephew, and Wright Medical Technology; publishing royalties: Arthroscopy and Vindico Medical-Orthopedics Hyperguide; stock: Cymedica, Mini-invasive, and Omeros; paid consultant: Orthospace; editorial or governing board: Knee, SLACK Incorporated; and IP Royalties: Smith & Nephew. Full ICMJE author disclosure forms are available for this article online, as supplementary material.*

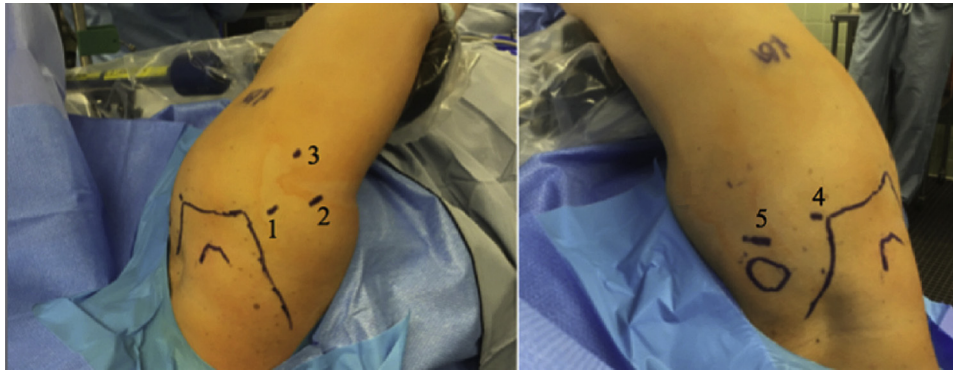
Received February 15, 2021; accepted March 1, 2021.

Address correspondence to Matthew R. Cohn, M.D., 1611 W Harrison St., Chicago IL, 60612. E-mail: [matthew.r.cohn@gmail.com](mailto:matthew.r.cohn@gmail.com)

© 2021 THE AUTHORS. Published by Elsevier Inc. on behalf of the Arthroscopy Association of North America. This is an open access article under the CC BY-NC-ND license (<http://creativecommons.org/licenses/by-nc-nd/4.0/>).

2212-6287/21243

<https://doi.org/10.1016/j.eats.2021.03.001>



**Fig 1.** The patient is positioned in the lateral decubitus position on a bean bag with the right shoulder held in approximately 15° of forward flexion and 45° of abduction using a pneumatic arm-holding device. (A) Posterior portals including the (1) posterior viewing portal, (2) posterior mid-glenoid working portal, and (3) 7-o'clock portal used for inferior anchor placement. (B) Anterior portals including (4) anterosuperior viewing portal and (5) anterior mid-glenoid working portal.

In addition, a posterior capsulotomy is typically performed to access the exostosis, and previously reported techniques involve capsular repair following excision of the lesion.<sup>4,5,12</sup> Others recommend a more selective approach, reserving repair of the capsulotomy for cases with associated posterior subluxation<sup>13</sup> and foregoing repair if patients show glenohumeral internal rotation deficit. Few techniques for Bennett lesion resection have been described since the initial description in 1959,<sup>1</sup> and techniques continue to evolve with advances in arthroscopic instrumentation and suture anchors. We present an arthroscopic technique for the resection of a Bennett lesion and repair of an associated posterior labral tear using all-suture anchors.

## Surgical Technique (With Video Illustration)

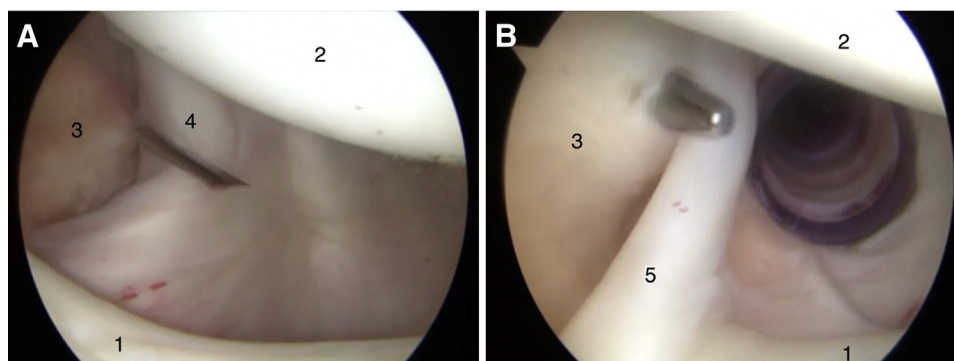
### Patient Positioning and Examination Under Anesthesia

The full technique can be viewed in [Video 1](#). This technique is performed with the patient in the lateral

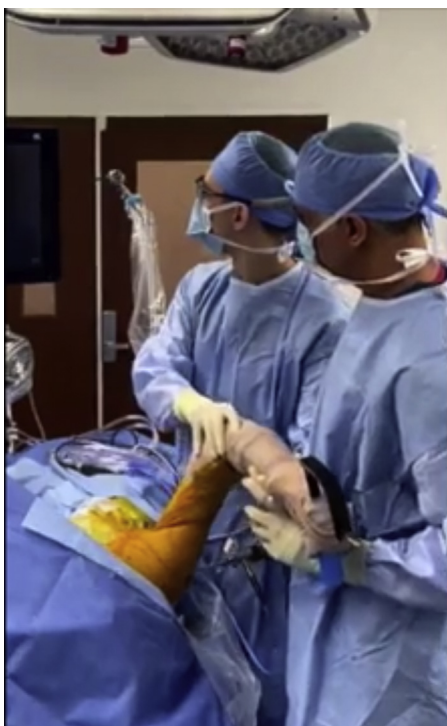decubitus position as previously described by the senior author (N.N.V.).<sup>14</sup> The patient is positioned on a beanbag (Olympic Vac-Pac System; Natus Medical, San Carlos, CA) with an axillary roll under the nonoperative axilla and all bony prominences padded. An examination under anesthesia (EUA) is performed, with particular attention paid to the presence of internal rotation deficit or posterior subluxation. The operative arm is positioned in approximately 15° of forward flexion and 45° of abduction using a pneumatic arm-holding device (SPIDER2 Limb Positioner; Smith & Nephew, Andover, MA), and a maximum of 10 pounds of balances suspension is applied.

### Portal Placement and Dynamic Examination

A posterior portal is made just inferior to the posterolateral corner of the acromion and is used as the initial viewing portal ([Fig 1](#)). The rotator cuff insertion is visualized and a dynamic examination for internal impingement is performed by bringing the arm into maximum abduction and external rotation. If present,



**Fig 2.** Arthroscopic images in the lateral decubitus position viewing from the posterior viewing portal for the right shoulder with a 30° arthroscope. (A) Establishment of an anterior working portal using spinal needle localization low in the rotator interval just superior to the subscapularis tendon. (B) Establishment of an anterosuperior viewing portal posterior to the long head of biceps tendon. Labels in figure: 1. labrum, 2. humeral head, 3. rotator interval, 4. subscapularis tendon, 5. long head of biceps tendon.



**Fig 3.** External view of dynamic examination for internal impingement. The arm is brought into maximum abduction and external rotation to assess for superior labral peel back and/or undersurface tearing and abnormal contact at the junction of the posterior rotator cuff insertion and the posterosuperior labral complex.

the surgeon will visualize peel back of the superior labrum and/or abnormal contact and undersurface tearing at the rotator cuff junction with the posterior superior labral complex (Fig 2).

Using outside-in spinal needle localization, an anterior working portal is created low in the rotator interval just superior to the upper border of the subscapularis tendon (Fig 3). An 8.25-mm cannula (Arthrex, Naples, FL) is placed to allow smooth passage of arthroscopic instruments and sutures. Next, an anterosuperior viewing portal is established high in the rotator interval that will allow a trajectory just posterior to the long head of the biceps tendon using a similar outside-in spinal needle technique. The position of these portals and appropriate spacing between them is crucial to avoid portal crowding. The 30° arthroscope is moved to the anterosuperior portal for the remainder of the procedure, which allows excellent visualization of the inferior glenoid from a 12-o'clock position.

### Bennett Lesion Exposure and Resection

Viewing from the anterosuperior portal, a probe is used to assess the integrity of the posterior labrum and to define the location of the Bennett lesion (Fig 4). The posterior labrum is debrided from the anterior working portal using a mechanical shaver (Arthrex), and the

tear is elevated from the glenoid to facilitate greater access to the adjacent Bennett lesion. A posterior mid-glenoid portal is created under direct visualization to ensure adequate location and trajectory to resect the bony exostosis. An arthroscopic basket (Arthrex) is used to make a capsulotomy over the lesion. Overlying periosteum and capsular tissue is debrided with a mechanical shaver and radiofrequency ablator (Arthrex) through the posterior mid-glenoid portal until the entirety of the lesion is exposed. We use a 5.0-mm bone-cutting shaver (Arthrex) from the posterior portal to resect the bony prominence to the level of the glenoid neck.

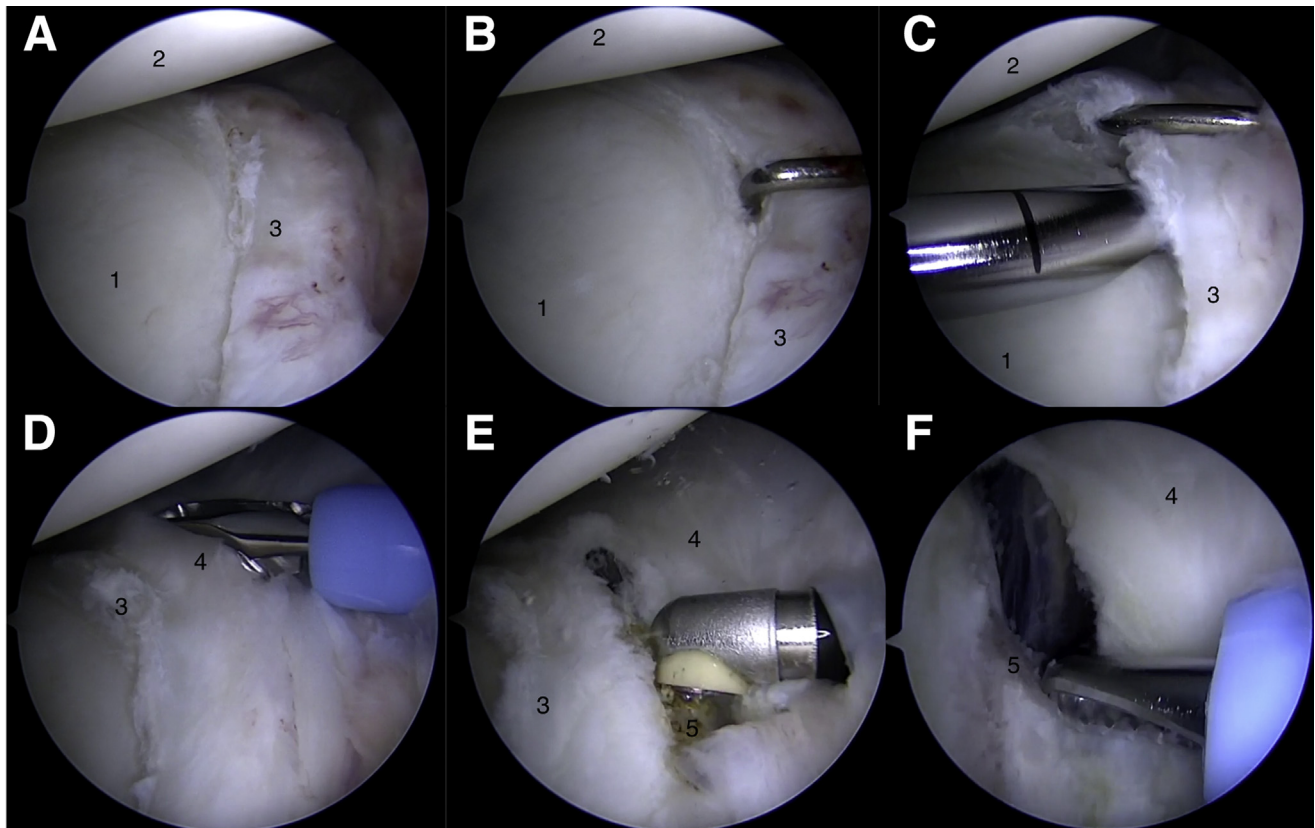
### Accessory Portal and Labral Repair

An accessory percutaneous portal at the 7-o'clock position is created to allow placement of an anchor orthogonal to the posterior inferior glenoid articular margin (Fig 5). This portal is typically 3 cm inferior and 1 cm lateral to the posterolateral corner of the acromion and anatomically passes through the teres minor tendon. We prefer labral repair using all-suture knotless anchors (Knotless 1.8mm FiberTak) to avoid prominent knot stacks at the articular margin. A curved suture passing device (Spectrum; ConMed Linvatec, Largo, FL) from the posterior portal is passed beneath the labrum to the articular margin, and a polydioxanone passing suture (PDS) and the working limb from the suture anchor are retrieved through the anterior portal. The suture is then passed around the capsulolabral tissue and is tensioned to secure the repair. Additional anchors are placed in a similar fashion through the posterior mid-glenoid portal as needed in an inferior to superior direction to repair the labral tear. With each subsequent suture anchor tensioned, the previous anchor is retensioned before being cut to ensure a secure repair. We typically do not repair the capsulotomy unless posterior subluxation was present on EUA, and we initiate early range of motion postoperatively (Table 1).

### Discussion

Once indicated for surgery, operative strategies for Bennett lesion resection must be made on a patient-specific basis. The first consideration is whether the Bennett lesion should be resected or if the patient would benefit from a strictly intra-articular debridement/repair. Early work (including Bennett's) found resection unnecessary<sup>1,13</sup>; however, subsequent studies found utility in capsulotomy and resection for larger lesions (>100 mm<sup>2</sup>), as they may contribute to irritation and impingement in the early phases of throwing.<sup>4,5,15</sup>

The question of whether to repair the posterior capsulotomy remains controversial. Given that concomitant posterior capsular contracture is often present with symptomatic Bennett lesions, many authors suggest leaving the capsule released may allow for improved



**Fig 4.** Arthroscopic images in the lateral decubitus position viewing from the anterosuperior viewing portal for the right shoulder with a 30° arthroscope. (A) visualization of the Bennett lesion with local inflammation of the capsule and associated posteroinferior labral tear, (B) probing from the posterior mid glenoid portal to assess the extent of the labral tear, (C) elevation of the labral tear, (D) capsulotomy performed with arthroscopic basket from the posterior mid-glenoid working portal, (E) debridement of the Bennett lesion using a radiofrequency ablator, and (F) resection of the lesion using a 5.0-mm bone-cutting shaver from the posterior working portal. Labels in figure: 1. glenoid articular surface, 2. humeral head, 3. posterior labrum, 4. posterior capsule, 5. Bennett lesion located at the posteroinferior glenoid rim.

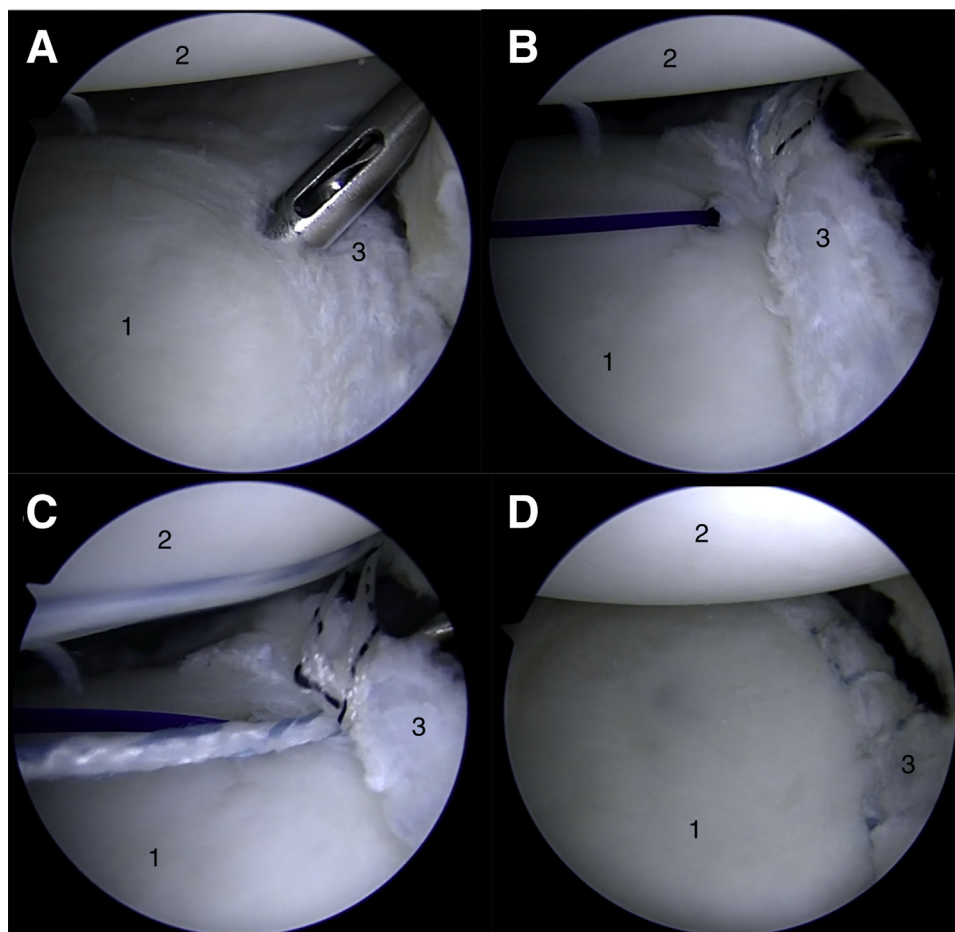
range of motion and kinematics.<sup>4,15</sup> Posterior capsular tightness and glenohumeral internal rotation deficit are common among throwing athletes and have been associated with diminished shoulder strength, supraspinatus and infraspinatus atrophy, and limitations in total arc of motion.<sup>16</sup> The ability to address the tight posterior capsule by performing a capsulotomy without repair makes this the senior author's (N.N.V.) preferred technique. Critically, if one is planning to leave the capsule open, absence of posterior instability must be confirmed on EUA, as capsular release may exacerbate underlying posterior instability.

If the posterior labrum is destabilized, suture fixation is required with either knotted or knotless anchors. No comparative biomechanical studies exist to help guide this decision, and only one comparative clinical study is available, which found equivalent results between

the two types of anchors.<sup>17</sup> We prefer a knotless technique, as it has been demonstrated that arthroscopic knots may migrate toward the articular surface with shoulder motion.<sup>18,19</sup> Knot migration risks chondral abrasion, particularly in throwers who require rapid rotation of their humeral head to generate velocity. In addition, a knotless technique has been shown to require less operative time.<sup>17</sup>

If a trial of nonoperative treatment fails, arthroscopic Bennett lesion excision with concomitant labral repair is an effective option that provides a high rate of return to play in overhead throwing athletes.<sup>2</sup> Several pearls and pitfalls (Table 2) are provided to assist surgeons in performing the procedure safely and effectively. Decisions regarding whether to repair the posterior capsule and/or repair the posterior labrum should be made on an individual patient basis.

**Fig 5.** Arthroscopic images in the lateral decubitus position viewing from the anterosuperior viewing portal for the right shoulder with a 30° arthroscope. (A) placement of posteroinferior all-suture anchor for labral repair using a 7-o'clock accessory portal, (B) left-curving suture passing device from the posterior working portal being used to pass suture around the labral tissue, (C) shuttling the poly-dioxanone suture from the suture passer and the working limb of the suture anchor through the anterior working portal, (D) final construct with stable fixation of the labrum to the articular margin and capsulotomy remaining open. Labels in figure: 1. glenoid articular surface, 2. humeral head, 3. posterior labrum.



**Table 1.** Postoperative Rehabilitation Guidelines for Bennett Lesion Resection and Posterior Labral Repair

Maximum protection phase, 0-4 weeks	POD 0-14: Sling immobilization, elbow/wrist/hand ROM POD 14: Initiate passive ROM with Codman's exercises
Moderate protection phase, 4-6 weeks	Begin Passive → AAROM → AROM FE restricted to 90°, ER at side to tolerance, IR to stomach, no cross-body adduction Begin isometric exercises with arm at side ER/IR (submaximal) with arm at side Begin gentle deltoid and scapular stabilizer strengthening
Minimal protection phase, 6-12 weeks	Increase ROM to within 20° of opposite side. No manipulations per therapist. Encourage patient to work on ROM daily. Continue isometric exercises Once FE to 140°, advance strengthening as tolerated: isometrics —bands or light weights (1-5 lbs); 8-12 repetitions/2-3 set per rotator cuff, deltoid, and scapular stabilizers Strengthening maximum 3×/week to avoid rotator cuff tendonitis Closed chain exercises
Strengthening phase, 3-12 months	Advance to full painless ROM Begin eccentrically resisted motions, plyometrics, proprioception, and closed chain exercises at 12 weeks. Begin sports related rehabilitation at 3 months, including advanced conditioning Return to throwing at 4.5 months Throw from pitcher's mound at 6 months

AAROM, active assisted range of motion; AROM, active range of motion; ER, external rotation; FE, forward elevation; IR, internal rotation; POD, postoperative day; ROM, range of motion.

**Table 2.** Pearls and Pitfalls

Pearls	Pitfalls
Lateral positioning with the use of a pneumatic arm positioner provides excellent distraction to allow access to the posteroinferior glenoid	It is important to pad all bony prominences in the lateral decubitus position
The use of pneumatic arm holder allows the operative arm to be easily removed to perform a dynamic examination to evaluate for internal impingement	Examination under anesthesia before prepping and draping is necessary to evaluate for internal rotation deficit and instability
Viewing from the anterosuperior portal allows viewing of the entire glenoid and Bennett lesion from a 12-o'clock position	Thorough exposure of the Bennett lesion using a mechanical shaver and radiofrequency ablator from the posterior working portal is necessary to perform a complete resection
Posterior capsulotomy provides full visualization of the Bennett lesion and avoids exacerbation of the glenohumeral internal rotation deficit	Passing sutures through the labrum near the 6-o'clock position should be performed with care to prevent iatrogenic injury to the axillary nerve
Use of a 7-o'clock accessory portal provides an orthogonal angle to place the most posteroinferior suture anchor(s)	
Knotless suture anchors avoid knot stacks at the articular margin, which risk chondral irritation in throwing athletes	

## References

- Bennett GE. Elbow and shoulder lesions of baseball players. *Am J Surg* 1959;98:484-492.
- Freehill MT, Mannava S, Higgins LD, Lädermann A, Stone AV. Thrower's exostosis of the shoulder: A systematic review with a novel classification. *Orthop J Sports Med* 2020;8:2325967120932101.
- Wright RW, Paletta GA Jr. Prevalence of the Bennett lesion of the shoulder in major league pitchers. *Am J Sports Med* 2004;32:121-124.
- Meister K, Andrews JR, Batts J, Wilk K, Baumgarten T. Symptomatic thrower's exostosis. Arthroscopic evaluation and treatment. *Am J Sports Med* 1999;27:133-136.
- Yoneda M, Nakagawa S, Hayashida K, Fukushima S, Wakitani S. Arthroscopic removal of symptomatic Bennett lesions in the shoulders of baseball players: Arthroscopic Bennett-plasty. *Am J Sports Med* 2002;30:728-736.
- Heyworth BE, Williams RJ 3rd. Internal impingement of the shoulder. *Am J Sports Med* 2009;37:1024-1037.
- Spiegl UJ, Warth RJ, Millett PJ. Symptomatic internal impingement of the shoulder in overhead athletes. *Sports Med Arthrosc Rev* 2014;22:120-129.
- Corpus KT, Camp CL, Dines DM, Altchek DW, Dines JS. Evaluation and treatment of internal impingement of the shoulder in overhead athletes. *World J Orthop* 2016;7:776-784.
- Walch G, Boileau P, Noel E, Donell ST. Impingement of the deep surface of the supraspinatus tendon on the posterosuperior glenoid rim: An arthroscopic study. *J Shoulder Elbow Surg* 1992;1:238-245.
- Bennett GE. Shoulder and elbow lesions of the professional baseball pitcher. *JAMA* 1941;117:510-514.
- Nakagawa S, Yoneda M, Hayashida K, Mizuno N, Yamada S. Posterior shoulder pain in throwing athletes with a Bennett lesion: Factors that influence throwing pain. *J Shoulder Elbow Surg* 2006;15:72-77.
- Lombardo SJ, Jobe FW, Kerlan RK, Carter VS, Shields CL Jr. Posterior shoulder lesions in throwing athletes. *Am J Sports Med* 1977;5:106-110.
- Ferrari JD, Ferrari DA, Coumas J, Pappas AM. Posterior ossification of the shoulder: The Bennett lesion. Etiology, diagnosis, and treatment. *Am J Sports Med* 1994;22:171-175. discussion 175-176.
- Hamamoto JT, Frank RM, Higgins JD, Provencher MT, Romeo AA, Verma NN. Shoulder arthroscopy in the lateral decubitus position. *Arthrosc Tech* 2017;6:e1169-e1175.
- Vo AM, Rogers KM, Bonner KF. Arthroscopic resection of symptomatic Bennett lesions. *Arthrosc Tech* 2019;8:e1463-e1467.
- Amin NH, Ryan J, Fening SD, Soloff L, Schickendantz MS, Jones M. The relationship between glenohumeral internal rotational deficits, total range of motion, and shoulder strength in professional baseball pitchers. *J Am Acad Orthop Surg* 2015;23:789-796.
- Bents EJ, Brady PC, Adams CR, Tokish JM, Higgins LD, Denard PJ. Patient-reported outcomes of knotted and knotless glenohumeral labral repairs are equivalent. *Am J Orthop (Belle Mead NJ)* 2017;46:279-283.
- Kim SH, Crater RB, Hargens AR. Movement-induced knot migration after anterior stabilization in the shoulder. *Arthroscopy* 2013;29:485-490.
- Yamamura K, Mifune Y, Inui A, et al. Relationship between glenohumeral internal rotation deficit and shoulder conditions in professional baseball pitchers [published online December 5, 2020]. *J Shoulder Elbow Surg*. <https://doi.org/10.1016/j.jse.2020.10.041>.