

Short Communication

Eosinophilic myositis in a slaughtered Korean native cattle

Sun Hee Do^{1,2}, Da-Hee Jeong¹, Jae-Yong Chung¹, Jin-Kyu Park¹, Hai-Jie Yang¹, Dong-Wei Yuan¹, Kyu-Shik Jeong^{1,*}

¹Department of Veterinary Pathology, College of Veterinary Medicine, Kyungpook National University, Daegu 702-701, Korea

²College of Veterinary Medicine, Konkuk University, Seoul 143-701, Korea

Histopathological findings of eosinophilic myositis in the carcass of a slaughtered Korean native cow are presented. Lesions contained massive fibrous septae with vacuolar changes in some lesions, and the hypercontraction and rupturing of muscle bundles, with replacement by eosinophils. Necrosis and severe eosinophil infiltration were observed. Sarcoplasmic fragmentation and atrophy developed. Typical of granuloma, calcified myofibers were focally surrounded by macrophages and numerous inflammatory cells, and multinucleated giant cell formation was evident.

Keywords: eosinophilic myositis, granuloma, Korean native cow, myofiber

Eosinophilic myositis (EM) is a collective term used in meat inspection to designate diseases of clinically healthy animals that have focal, green-colored muscular lesions of unknown origin [7,10]. EM is a relatively rare condition in cattle and sheep of all ages [7,8]. Previous reports have provided evidence that *Sarcocystis* are directly associated with the lesions and contribute to rejection and downgrading of carcasses at meat-processing plants [1,2,5]. Bovine EM has been only rarely described. The cause of EM remains unknown since most cases were detected during a routine postmortem inspection and because there is little tissue reaction in the intermediate host, cattle, in which asexual development of *Sarcocystis* occurs.

Presently, we describe a case of EM in a 3-year-old cow with a normal history and no pre-existing clinical conditions at the time of slaughter. A routine postmortem inspection of the carcass revealed generalized whitish and pale skeletal muscles in the cervical region (Fig. 1). Carcasses with locally whitish and pale lesions that had

been rejected by inspectors were acquired for comparative purposes. Representative sections of cervical skeletal muscles were fixed immediately in 10% neutral buffered formalin, processed routinely, and embedded in paraffin. Tissue sections 4 µm in thickness were cut and stained with hematoxylin and eosin and periodic acid-Schiff (PAS) for detection of pathogen.

Histopathological examination of the lesions revealed interstitial fibrosis, more developed fibrous septa, and augmented numbers of fibroblasts between the myofibers as compared with normal skeletal muscles (Fig. 2). The carcass was whitish and pale (Fig. 1). The skeletal muscles showed histopathological features of eosinophilic myositis that contained focal granulomatous lesions with multifocal calcified necrotic fibers, mixed inflammatory cells mainly consistent with eosinophils, and the infiltration of a multinucleated giant cell. Massive intramuscular infiltration of the eosinophils was identified in the specimens; as well, most myofibers were hypercontracted, ruptured, and were replaced by eosinophils (Fig. 3). Eosinophils were present within and adjacent to the



Fig. 1. Appearance of the skeletal muscle of the Korean native cow. The muscle was generally whitish and pale with a white streak.

*Corresponding author

Tel: +82-53-950-5975; Fax: +82-53-950-5955

E-mail: jeongks@knu.ac.kr

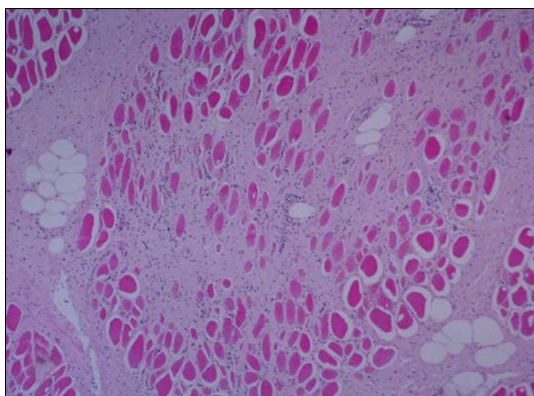


Fig. 2. Histochemical examination of the skeletal muscle of the Korean native cow. The whitish and pale muscle exhibited augmented interstitial fibrous septa and the strong activation of fibroblasts between the myofibers. H&E stain. $\times 12$.

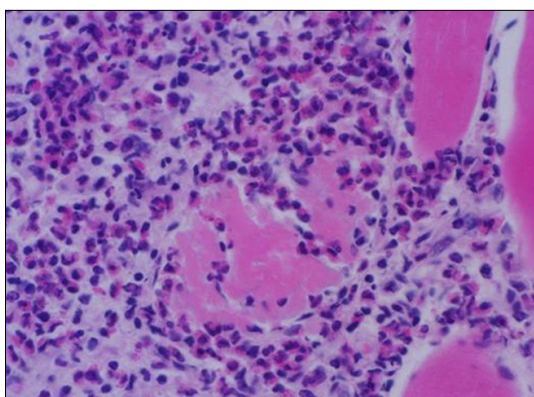


Fig. 3. Eosinophil examination of the skeletal muscle of the Korean native cow. Massive eosinophils are present within and adjacent to the affected myofibers. H&E stain. $\times 33$.

affected myofibers (Fig. 4). There was no evidence of infection from parasites, or sarcocystosis. Especially considering the appearance of tissues following PAS staining, a diagnosis of bovine idiopathic EM was made.

EM is a group of three inflammatory disorders - eosinophilic polymyositis, eosinophilic perimyositis and focal eosinophilic myositis - characterized pathologically by an eosinophilic cell infiltrate in the skin and skeletal muscles [4,6]. The pathogenesis of EM varies; a correlation between serum interleukin-5 levels and disease severity [9] suggests a role for this interleukin species in eosinophil activation.

Sarcocystis spp. has long been suspected as an etiological agent of EM [7]. Recent reports have provided evidence that sarcocysts are directly associated with lesions and contribute to the rejection and down grading of carcasses at meat-processing plants [1,2,5,10]. In one study, up to 5% of carcasses rejected in the United States were positive for

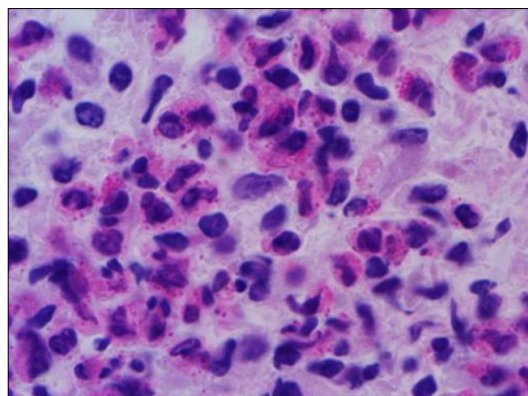


Fig. 4. High magnification of Fig. 3. $\times 66$.

sarcocysts [5]. Presently, generalized inflammatory reactions were common in sections of all the acquired rejected carcasses, and sections of all lesions revealed granulomatous reactions. Most of the granulomas observed in the EM carcasses may have resulted from sarcocysts that served as chronic inflammatory stimuli. It is not surprising that sarcocysts were found in only a small proportion of granulomas.

Currently, there are no tests that can predict the presence of EM prior to slaughter. Immunoglobulins that are specific to species of *Sarcocystis* have been found in both affected and unaffected cattle [2]. Speciation of the responsible pathogen in cattle is unclear. Regarding the respective occurrence of EM and sarcocytosis, EM has little economic importance while sarcocystosis has great economic importance to the meat-producing and meat packing industries, and to the overall public health.

There have been a few reports of carcasses with numerous disseminated lesions that were rejected as human food sources and presented a public health threat. Although carcasses with a few localized or excisable lesions can be approved, nearly all grossly affected carcasses are assumed to contain disseminated lesions, even though such lesions may be difficult to find.

In the present study, a cow with pale and whitish skeletal muscles grossly evident in the loggismus capitus was observed at the slaughter house. Histosections of carcass tissue revealed lesions that were characterized by a massive infiltration of eosinophils between the myofibers, hypercontraction and rupture of the muscle bundles, and augmented fibrous septae. As well, focally granulomatous inflammatory lesions were observed. Our case may well represent *Sarcocystis spp.* EM, although the direct cause was not ascertained.

When confronted by EM, we suggest that not only rejected carcass should be examined, but the entire animal stock of the farm as well. While it is likely that the cause of EM a *Sarcocystis spp.* infection, livestock officials can

prevent or reduce sarcocystosis by controlling the movement of working dogs and cats, and eliminating stray and wild animals from cattle and sheep pastures, feedlots, and feedmills to avoid feed and water-being contaminated with sporocysts. Eliminating bovine and ovine raw muscles and viscera from the diets of dogs and cats is prudent to prevent infecting the definitive hosts. Moreover, human defecation in or near feed or water that could be consumed by cattle should be restricted so as to avoid the transmission of *Sarcocystis* spp. oocysts to cattle.

Acknowledgements

The authors wish to thank the veterinary meat inspectors who collected the material. This work was supported by the faculty research fund of Konkuk University in 2007.

References

1. **Bundza A, Feltmate TE.** Eosinophilic myositis/lymphadenitis in slaughter cattle. *Can Vet J* 1989, **30**, 514-516.
2. **Gajadhar AA, Yates WD, Allen JR.** Association of eosinophilic myositis with an unusual species of *Sarcocystis* in a beef cow. *Can J Vet Res* 1987, **51**, 373-378.
3. **Granstrom DE, Ridley RK, Baoan Y, Gershwin LJ.** Immunodominant proteins of *Sarcocystis cruzi* bradyzoites isolated from cattle affected or nonaffected with eosinophilic myositis. *Am J Vet Res* 1990, **51**, 1151-1155.
4. **Hall FC, Krausz T, Walport MJ.** Idiopathic eosinophilic myositis. *QJM* 1995, **88**, 581-586.
5. **Jensen R, Alexander AF, Dahlgren RR, Jolley WR, Marquardt WC, Flack DE, Bennett BW, Cox MF, Harris CW, Hoffmann GA, Troutman RS, Hoff RL, Jones RL, Collins JK, Hamar DW, Cravans RL.** Eosinophilic myositis and muscular sarcocystosis in the carcasses of slaughtered cattle and lambs. *Am J Vet Res* 1986, **47**, 587-593.
6. **Pickering MC, Walport MJ.** Eosinophilic myopathic syndromes. *Curr Opin Rheumatol* 1998, **10**, 504-510.
7. **Reiten AC, Jensen R, Griner LA.** Eosinophilic myositis (sarco-sporidiosis; sarco) in beef cattle. *Am J Vet Res* 1966, **27**, 903-906.
8. **Thomas JH.** Muscle and tendon. In: Jubb KVF, Kennedy PC, Palmer N (eds.). *Pathology of Domestic Animals*. Vol. 1. 3rd ed. pp. 245-252, Academic Press, Orlando, 1985.
9. **Trüeb RM, Lubbe J, Torricelli R, Panizzon RG, Wüthrich B, Burg G.** Eosinophilic myositis with eosinophilic cellulitislike skin lesions. Association with increased serum levels of eosinophil cationic protein and interleukin-5. *Arch Dermatol* 1997, **133**, 203-206.
10. **Wouda W, Snoep JJ, Dueby JP.** Eosinophilic myositis due to *Sarcocystis hominis* in a beef cow. *J Comp Pathol* 2006, **135**, 249-253.