

Research Article

Diagnosis of Waist Muscle Injury after Exercise Based on High-Frequency Ultrasound Image

Bingke Wang 

Sports Institute, Pingdingshan University, Pingdingshan 467000, China

Correspondence should be addressed to Bingke Wang; 3044@pdsu.edu.cn

Received 22 January 2021; Revised 9 March 2021; Accepted 17 March 2021; Published 26 March 2021

Academic Editor: Zhihan Lv

Copyright © 2021 Bingke Wang. This is an open access article distributed under the Creative Commons Attribution License, which permits unrestricted use, distribution, and reproduction in any medium, provided the original work is properly cited.

The low back is the weight-bearing part of the human trunk and has a complex anatomy with a variety of lesions. The traditional diagnostic imaging methods include X-ray, CT, and magnetic resonance imaging (MRI). With the rapid development of ultrasound diagnostic instruments and diagnostic techniques, high-frequency ultrasonography plays a more important role in the diagnosis of musculoskeletal disorders by virtue of its advantages of being safe, noninvasive, inexpensive, repeatable in a short period of time, and real-time imaging, especially for the display of fine structures of soft tissues, which is superior to CT and MRI. In this paper, the puncture needle was punctured near the intervertebral foramen, anti-inflammatory analgesics were injected under ultrasound surveillance. The anti-inflammatory and analgesic drugs mainly consist of local anesthetics and glucocorticoids. Local anesthetics can immediately block the nociceptive transmission of the diseased nerve, improve muscle tension, and eliminate muscle spasm, and glucocorticoids can effectively eliminate edema and inflammation of the lumbar nerve root and its surrounding tissues. The results showed that high-frequency ultrasound, as a noninvasive imaging examination, can clearly display the structure and spatial hierarchy of the skin, superficial fascia, deep fascia, and muscles of the low back, can provide real-time dynamic bilateral contrast observation, which can be the preferred imaging examination method for soft tissue disorders of the low back, and can compensate with general X-ray, CT, and magnetic resonance imaging to provide richer clinical diagnosis and treatment. It can provide richer imaging information for clinical diagnosis and treatment.

1. Introduction

Clinicians usually use X-rays, CT, and magnetic resonance imaging (MRI) to examine musculoskeletal disorders. Because X-rays are not effective in examining soft tissues, CT only shows static images and is nonfunctional, lacking detailed information on soft tissue lesions; MRI can be used to examine joints and soft tissues, but it is expensive, takes a long time, and has some contraindications, so it is not yet a routine examination. High-frequency ultrasound has the advantages of no radiation damage, noninvasive, inexpensive, repeatable within a short period of time, real-time imaging, high resolution, and so on and is widely used. It has been proved that high-frequency ultrasound can clearly display the hierarchical relationship and internal structure of muscles and other soft tissues, identify tissue lesions of joints, muscles, tendons, and ligaments, and also observe the

relationship between lesions and surrounding tissues from any direction and angle to obtain all-round information of lesions [1]. High-frequency ultrasound can play a more important role in the diagnosis of musculoskeletal system diseases.

The low back is the bridge between the human trunk and the lower extremities. Military training, physical exercise, physical labor, and sudden violence can easily lead to various acute and chronic injuries to the muscles of the low back. Active and violent contraction or passive overstretching of the muscles of the low back can cause acute lacerations, that is, muscle strains, and can involve myofascia, tendons, ligaments, and other soft tissues. High-frequency ultrasonography can make an accurate assessment of the site, extent, and degree of muscle injury. Previous authors [2] used high-frequency ultrasound to examine 43 patients with muscle injuries, 3 of which were located in the lumbar back

muscle, and noted that minor tears could show no significant changes or mild hypoechogenicity in the injured muscle on sonogram. Others [3] reported a case of partial tear of the latissimus dorsi muscle in a basketball player, in which the sonogram showing muscle thickening, echogenic enhancement, partial interruption of the echogenic continuity of the muscle fibers, and intramuscular hematoma formation was an important manifestation, and the echogenic nature of the hematoma could change with the migration of the injury time, as shown in Figure 1. A complete tear is characterized by a complete disruption of the muscle echogenic continuity, with the broken end being hyper-echoic and retracted to form a “mass,” which is surrounded by a larger hematoma, forming a typical “bell and tongue sign” [4]. When the low back muscle is violently impacted or crushed, it can cause muscle contusions and diffuse swelling of the damaged muscle, which can bleed under the extramuscular membrane or within the muscle to form a hematoma. Previous studies [5–10] concluded that the sonograms of 15 cases of muscle contusions showed subcutaneous soft tissue swelling, increased thickness of the injured muscles, and enlarged, hypoechoic muscle bundles with irregular no or hypoechoic areas around them. Severe muscle crush injuries can be complicated by rhabdomyolysis, which is essentially skeletal muscle necrosis. The ultrasound characteristics of 21 clinically confirmed cases of rhabdomyolysis were retrospectively analyzed by someone [11], which showed that the lesion area was shuttle-shaped or irregular, with good overall continuity of the rhabdomyolysis muscle, blurred muscle texture, echogenic enhancement, and “cloudy” or “hairy glass-like.” The color Doppler flow imaging (CDFI) shows a small amount of punctate or no blood flow signal in the lesion area. One study [12] pointed out that the loss of muscle texture is the most characteristic ultrasound change in rhabdomyolysis. Other studies [13–16] have opened new avenues for the early diagnosis and management of rhabdomyolysis by establishing experimental animal models.

Ultrasound-guided nerve block techniques have been widely used and developed in pain management and clinical anesthesia over the past decade or so. Clinicians first use ultrasound to scan peripheral nerves and their surrounding structures to detect or rule out abnormalities and then perform safe and accurate puncture and drug injection for the target nerve under dynamic real-time ultrasound guidance. Real-time ultrasound guidance avoids puncture damage to blood vessels, internal organs, and other critical tissue structures, greatly reduces treatment complications, and improves effectiveness. As a noninvasive imaging test, high frequency ultrasound can be used as the first choice of skin, superficial fascia, deep fascia and muscle structure and lumbar spatial hierarchy, and hip soft tissue disorders and can compensate for general X-ray, CT, and MRI and provide more extensive image information for clinical diagnosis and treatment. At present, there is little research on ultrasound anatomy of the low back in China, and there is a lack of unified operation standard. It is believed that with the continuous improvement of high-end ultrasound diagnostic instruments and new diagnostic techniques, high-frequency

ultrasonography will play a pivotal role in the diagnosis and prognosis assessment of low back diseases. In this paper, the puncture needle was punctured near the intervertebral foramen and next to the lumbar nerve root under ultrasound dynamic real-time guidance, and anti-inflammatory analgesics were injected under ultrasound surveillance. The anti-inflammatory and analgesic drugs mainly consist of local anesthetics and glucocorticoids. Local anesthetics can immediately block the nociceptive transmission of the diseased nerve, improve muscle tension, and eliminate muscle spasm, and glucocorticoids can effectively eliminate edema and inflammation of the lumbar nerve root and its surrounding tissues.

2. Data and Methods

2.1. Research Subjects. A total of 101 cases with complete data on muscle injury and 80 cases without muscle injury were included in this study. The subject group was 20–39 years old, with a mean age of (29.6 ± 4.1) years, a mean height of (162.43 ± 4.99) cm, a mean preinjury weight of (57.58 ± 8.97) kg, and a mean preinjury BMI (there was no difference in age, height, weight, and BMI between the study group and the control group). The differences were not statistically significant ($P > 0.05$) when compared with the control group in terms of age, height, weight, and BMI, and the results are shown in Table 1.

2.2. Research Methods. Chiropractic treatment of ultrasound-guided lumbar nerve root block and American lumbar muscle injury has a constant effect, has relatively clear advantages, and at the same time has its own drawbacks. Ultrasound-guided lumbar nerve root block treatment is safe and reliable and is effective in imaging guided puncture injections. This can provide rapid pain relief and effective swelling and anti-inflammatory treatment for damaged nerve roots in a short period of time, but since it does not fundamentally resolve the problem of nonuniform force to the intervertebral disc, it is likely to cause recurrent seizures and long-term efficacy is not satisfactory [17]. American chiropractic treatment of lumbar muscle injuries has clear long-term efficacy because it significantly improves the unbalanced force on the intervertebral discs, but because patients with lumbar muscle injuries often have difficulty moving and American chiropractic treatment requires patients to assume specific positions and to withstand instantaneous tonal pressure, many patients cannot accept this treatment, especially if they are in acute edema of nerves and soft tissues. This is especially true if the patient is in acute neurological and soft tissue edema, which makes it difficult to assume a standard position for treatment, and therefore affects the widespread use of this technique [18]. If the two classical treatment protocols can be effectively combined for the treatment of lumbar muscle injuries, it can be expected that the immediate and long-term results will be more satisfactory. Clinical efficacy analysis of the combination of the two in the treatment of lumbar muscle injuries is rarely reported in the domestic and international literature, so this

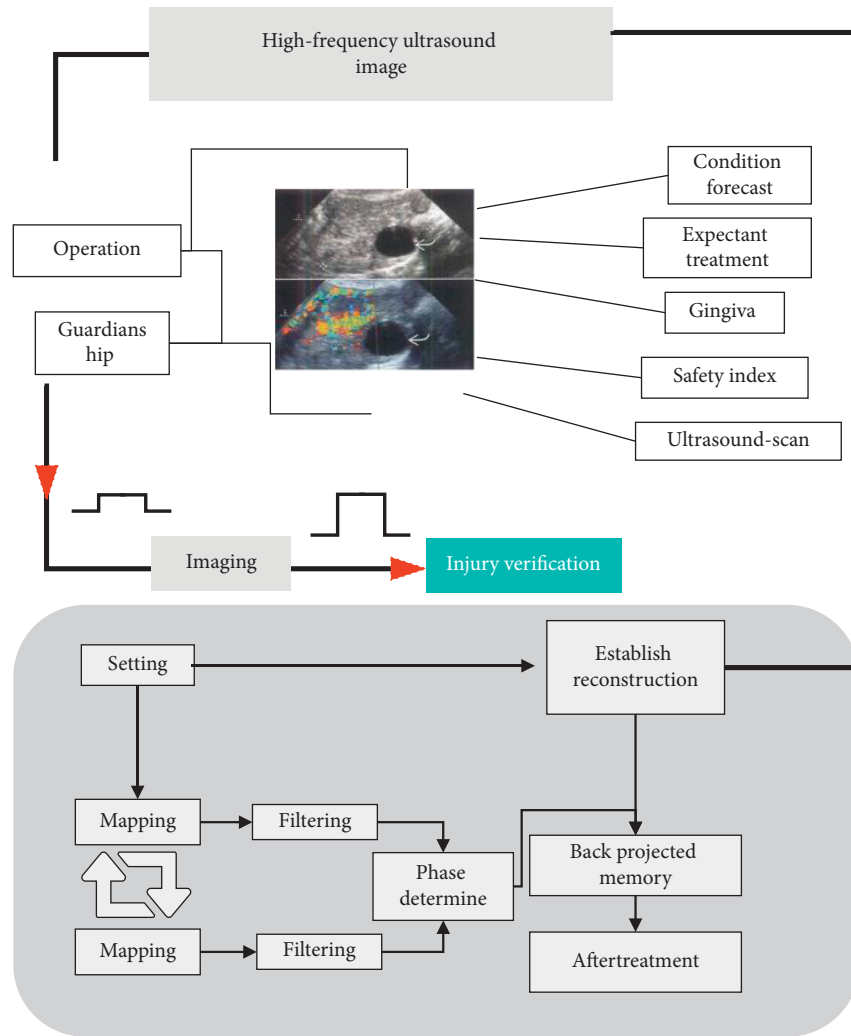


FIGURE 1: Echogenic properties of hematoma.

TABLE 1: The general information of selected patients.

Group	Average age (weeks)	Gender (male/female)	Disease duration (month)	Injury part	
				Arterial narrowing	Arteriosclerosis
Control	29.6 ± 4.1	27/53	0.83 ± 0.12	44	36
Observation	29.6 ± 4.1	24/56	0.76 ± 0.07	47	33
<i>t</i>	—	1.713	0.699	1.723	1.635
<i>P</i>	—	0.089	0.679	0.078	0.098

research group aimed to study the clinical efficacy of the combination of the two methods in the treatment of lumbar muscle injuries and to provide some reference for clinicians when choosing a treatment plan for lumbar muscle injuries [19].

The diagnosis is made based on the patient’s history, clinical symptoms, and signs, combined with direct images of the protrusion on X-ray, CT, or MRI.

- (1) Low back pain and lower extremity pain which are typical of pain in the area of lumbosacral nerve root distribution, often showing more lower extremity pain than low back pain.

- (2) Two of the four signs of neurological disorders, namely, muscle atrophy, muscle weakness, sensory abnormalities, and reflex changes, which are manifested by nerve distribution area.
- (3) Positive straight leg raise test.
- (4) Abnormal signs such as X-rays, CT, MRI, or special imaging that were found to be consistent with the clinical presentation.

For differential diagnosis, lumbar muscle injury needs to be differentiated from lumbar spinal stenosis, lumbar spinal tuberculosis, lumbar spine tumor, lumbar spine slippage, lumbar spine infection, and pear-shaped muscle syndrome.

Treatment indications were as follows: ① typical history of intravertebral low back pain, note the differentiation from extravertebral low back pain. ② Physical examination was as follows: pressure pain in the corresponding paraspinal process and its interspace with radiation to the affected side, straight leg raising test (+), strengthening test (+), and jerk test (+) on the affected side. ③ CT or MRI of the intervertebral disc confirms lumbar disc protrusion: the size of the protrusion does not exceed 1/3 of the spinal canal, and the protrusion is not significantly calcified. ④ Physiotherapy and conservative treatment were ineffective after 1 month. ⑤ A frontal and lateral view of the lumbar spine in a standing position and a pelvic plain film were taken. The symptomatic areas can be shown in Table 2.

3.3. Statistical Processing. The data were statistically processed using SPSS22.0 software, and the count data were expressed as rate by χ^2 test; the measurement data of normal distribution were expressed as $x \pm s$, in which the t -test was used for the paired control group within the group and the t -test for two independent samples between the groups, and the measurement data of nonnormal distribution were tested by rank sum test, and the difference was considered statistically significant at $P > 0.05$.

3. Ultrasound-Guided Diagnosis of Lumbar Injuries

3.1. Ultrasound-Guided Lumbar Nerve Diagnosis. In the treatment of lumbar muscle injury with ultrasound-guided lumbar nerve root block, the core factor that ultimately determines the treatment effect is whether the puncture needle can safely and accurately reach the external orifice of the intervertebral foramen, where the nerve root penetrates the spinal canal. However, due to the deformity or trauma of the lumbar spine [20], the traditional “blind puncture” technique is difficult to palpate bony structures such as the spinous process, resulting in a high failure rate of puncture and a certain potential risk, which makes the treatment outcome less than ideal for some patients. As a type of visual imaging technology, ultrasound technology is widely used in the medical field to effectively identify bony landmarks, blood vessels, nerves, and muscles, as shown in Figure 2. With ultrasound display, the spines, articular processes, transverse processes, puncture needles, ligaments, and diffusion of the injected drug can be clearly identified in the vertebral body, which makes the accuracy and safety of the puncture injection operation greatly enhanced. The results of this study, which included 120 patients, showed that there was a statistically significant difference ($P < 0.05$) in the change in treatment pain score (VAS score) and Oswestry dysfunction index between the study group (Group A) and the control group (Group B). This indicates that ultrasound-guided lumbar nerve root block combined with American chiropractic treatment has a higher accuracy rate and better efficacy and can be effectively used for the treatment of low back pain due to lumbar muscle injury. In summary, ultrasound-guided lumbar nerve root block combined with

American chiropractic treatment for lumbar muscle injury has the advantages of simple operation, high patient satisfaction, and safety and effectiveness when applied clinically. The combination of ultrasound-guided lumbar nerve root block and American chiropractic treatment for lumbar muscle injuries has high application value in clinical promotion [21–25].

3.2. Muscle Injury under High-Frequency Ultrasound.

First of all, a series of syndromes related to lumbar spinal pain caused by the irritation or compression of lumbar nerve roots, spinal cord, or cauda equina nerve due to degeneration of lumbar disc, rupture of fibrous ring, and herniated nucleus pulposus are known as lumbar muscle injury. Lumbar muscle injury is very common in clinical orthopedics, pain medicine, rehabilitation, and acupuncture and is also the most common cause of lumbar pain. The main reason is that modern young and middle-aged people have more ambulatory workers, generally lack of scientific and adequate physical exercise; sedentary lifestyle can accelerate the degenerative changes of the lumbar intervertebral discs, and the human waist structure needs to bear the weight of the upper body, but also to bear the mechanical conduction of the buffer, the combination of the above factors lumbar muscle injury belongs to a disease of the times that urgently needs to be solved. The causes of intervertebral disc degeneration are divided into many kinds; nowadays the society is highly developed electronic products, most people are sedentary leading to lumbar muscle strain, and the improper posture of people’s work life and lack of exercise is also another important cause of lumbar disc degeneration.

Over the years, the pace of modern urban life is getting faster and faster, the pressure of life is gradually increasing, and people’s lifestyles have also undergone a radical change, but modern people lack the concept and awareness of health care in general and does not love exercise; most people have developed the bad habit of sitting for a long time; sedentary lifestyle can lead to the muscles being in a state of tension for a long time. In the case of imbalance, the strength of the waist muscles will increase over time. The lumbar muscles are the most important structure to play a supporting role in addition to the lumbar vertebrae. Once the lumbar muscles declined in function can not well maintain the physiological curvature of the lumbar spine, the lumbar spine physiological curvature changes after the lumbar spine anatomy and histology will be followed by pathological changes; these results are often incorrect and overuse and are often caused by incorrect and excessive use of the lumbar spine.

The fibrous annulus of the already fragile lumbar intervertebral disc in humans is very vulnerable to destruction, which leads to the protrusion of the nucleus pulposus through the fibrous annulus and subsequent compression and stimulation of the nerve roots, spinal cord, cauda equina, and other tissue structures, eventually leading to local sterile inflammation and impaired blood circulation, which can also cause lumbar nerve edema and other corresponding clinical symptoms. The core of this study is how to eliminate the entrapment of lumbar nerve roots, spinal

TABLE 2: Clinical symptoms and signs of nerve injury at different levels were summarized.

Affected nerve root	Painful area	Shallow sensory decline	Decreased muscle strength
L4	Waist, hip, anterior and outer thighs, inner calf	Anterolateral thigh	Quadriceps muscle strength
L3	Sacroiliac, hips, outer thighs, outer calves, back of feet	Outer calf	First toe extension
L2	Sacroiliac, waist, buttocks, back of thighs	Back of the calf	Toe flexion
L1	Calf posterior lateral, posterior lateral	Outside of foot	Back extensor strength

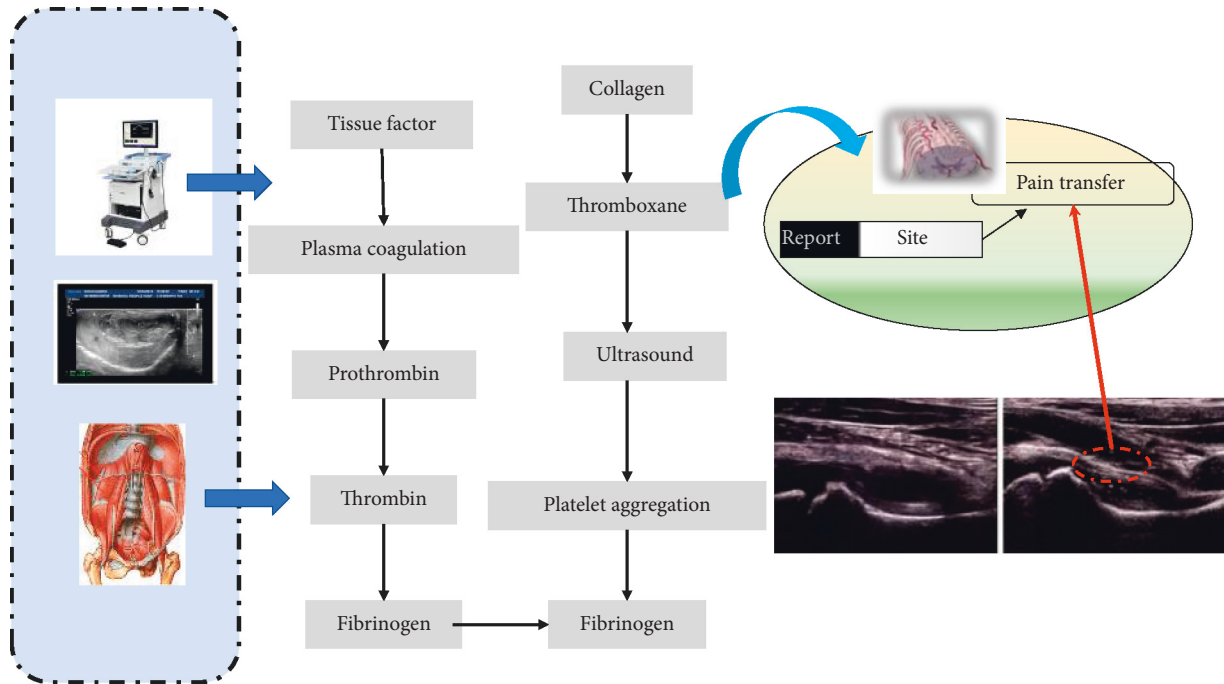


FIGURE 2: Ultrasound-guided lumbar nerve diagnosis.

cord, and cauda equina nerve, eliminate edema and sterile inflammation of nerve roots, and repair the injured nerve roots and adjacent soft tissues, as shown in Figure 3. Lumbar muscle injury also has a very close relationship with the soft tissues around the lumbar spine such as muscle ligaments, and the actual clinical treatment process also needs to take into account the treatment and postcare of the area around the lesion to avoid recurrent attacks, so as to consolidate the efficacy and maximize the avoidance of the adverse effects of this disease on people’s lives and work. Secondly, as the name implies, the main cause of lumbar muscle injury is lumbar disc herniation, but it is worth mentioning that if only the lumbar disc is herniated and there is no compression of the corresponding spinal nerve, then the patient will not produce symptoms of lumbar pain; that is, it cannot be called “lumbar muscle injury,” if the herniated lumbar disc does compress or stimulate the corresponding nerve roots or spinal cord and cause aseptic inflammation of the nerve tissues and thus produce the corresponding symptoms; this kind of low back pain with a clear cause and clinical symptoms and auxiliary examination can be called “lumbar muscle injury.” If the imaging shows a herniated lumbar disc but no clinical symptoms, this is not the same as a “lumbar muscle injury,” which is known as a normal phenomenon in imaging. Again, the actual clinical

treatment of lumbar muscle injuries is divided into surgical and nonsurgical treatments. Despite the recent surgical techniques, rapid development of surgical instruments, and the advent of many minimally invasive surgical techniques, the efficacy is poor, but the trauma caused by surgical treatment itself is still relatively large, the risk of surgery is high and expensive, and the psychological pressure on patients is very great. For patients, the acceptance of surgical treatment is very low and the majority of the majority of the patients still prefer nonsurgical treatment, and in most cases, most patients will be able to relieve symptoms, traction, manipulation, and interventional therapy like only noninvasive and minimally invasive treatments. Of course, not all patients are suitable for nonsurgical treatment, and not all nonsurgical treatments can be very effective; for example, if traction is not reasonable, it can cause muscle damage and ligament relaxation, leading to further aggravation of the patient’s symptoms; if pain medication is not used properly, it may also delay the disease or even damage and stimulate the patient’s gastrointestinal tract.

In conclusion, this study evaluated ultrasound-guided lumbar nerve root block combined with American chiropractic for the treatment of lumbar muscle injuries. American chiropractic manipulation is easy, effective, inexpensive, and less risky, so it is used as one of the first

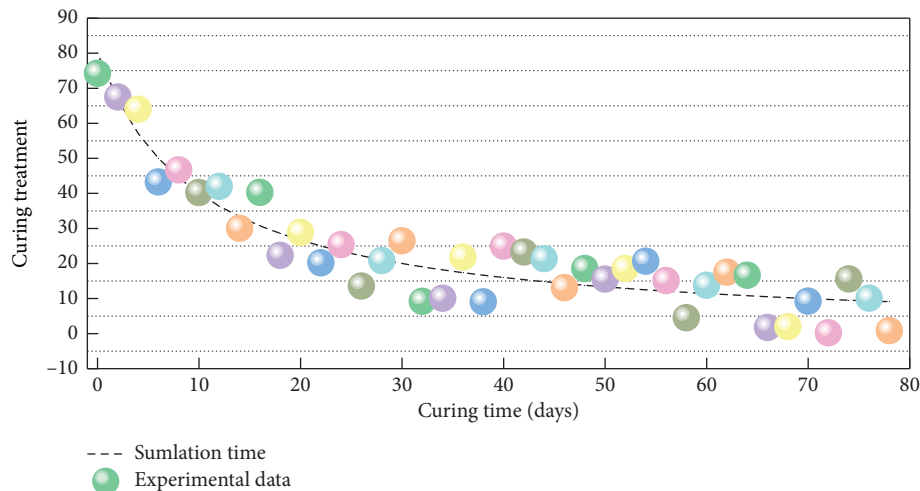


FIGURE 3: Pain relief of lumbar nerve roots.

treatments for nonsurgical treatment of lumbar muscle injuries in the United States and other countries. The anti-inflammatory and analgesic solution required for lumbar nerve root block treatment consists of Depo-Provera and local anesthetics, of which Depo-Provera can play a strong anti-inflammatory role, and local anesthetics can provide immediate pain relief and block pain transmission, while ultrasound guidance ensures that the puncture needle can quickly and safely reach the external orifice of the intervertebral foramen to inject the anti-inflammatory and analgesic mixture through the intervertebral foramen to reach the disease and rapidly control the symptoms, as shown in Figure 4. Both methods have their own treatment characteristics, and the efficacy time can complement each other. Therefore, this study adopts ultrasound-guided lumbar nerve root block combined with American chiropractic treatment for lumbar muscle injury, which is safe, simple, efficient, and inexpensive to operate, and the patient's compliance is high, and it is worthy of clinical promotion.

3.3. Imaging Observations under Minimally Invasive or Interventional Treatment. Conservative treatment is often ineffective, and many patients come to the clinic because they are unwilling to undergo open surgery. Minimally invasive interventions and manual therapy are often easily accepted by patients. Minimally invasive treatment methods have developed rapidly in recent years, mainly because of the rapid development of imaging; clear visualization of medical treatment makes minimally invasive technology grow a pair of “perspective eyes” because ultrasound scanning does not produce any radiation and adverse effects on the doctor and the patient and can guide the doctor to adjust the puncture needle in real time and other characteristics. The ultrasound scan has become a hot topic among the many guidance methods for the treatment of lumbar muscle injuries. Nerve block treatment can quickly stop pain and target nerve roots for rapid anti-inflammation and swelling, which achieves efficient and safe treatment purpose. Therefore, ultrasound-guided lumbar nerve root block treatment has become one

of the treatment modalities frequently adopted by pain departments, orthopedic departments, rehabilitation departments, and other related departments at home and abroad.

American chiropractic has low requirements for the treatment environment and treatment equipment, and any doctor with formal training can operate this method to treat spinal disorders such as lumbar muscle injuries. American chiropractic quickly corrects subluxated vertebrae through noninvasive and convenient treatment, immediately relieves nerve root entrapment symptoms, solves the real problem of uneven disc pressure, prevents further subluxation of vertebrae, and has better long-term efficacy. The long-term results are good, as shown in Figure 5. Mild lumbar muscle injury is often treated with oral nonsteroidal anti-inflammatory drugs or other methods; these are effective but have more side effects. Moderate or severe lumbar muscle injury is often treated with nerve blocks or chiropractic operations and has the following advantages: rapid pain relaxation and fewer side effects.

Lumbar muscle injury is one of the main causes of lumbar pain in clinical practice, and conservative treatments such as bracing, drugs, and physiotherapy are the most common treatments for it. Most of the patients whose conservative treatments are ineffective in clinical practice can get improvement through nerve block treatment and Chinese orthopedic massage, but some patients with persistent lumbar muscle injury still do not improve after the above treatments, and the number of recurrences is frequent, or the treatment. The effect does not last long, and there are certain patients who have gastrointestinal reactions, local skin muscle damage, and other changes due to receiving prolonged medication and physical therapy, which instead aggravate the injury and pain, and some patients even lose their labor force as a result. In this study, we observed the efficacy of lumbar muscle injury by precisely blocking the lumbar nerve roots combined with American chiropractic under ultrasound guidance, and through clinical research, we concluded that ultrasound-guided puncture needles reach the nerve roots, while anti-inflammatory and analgesic

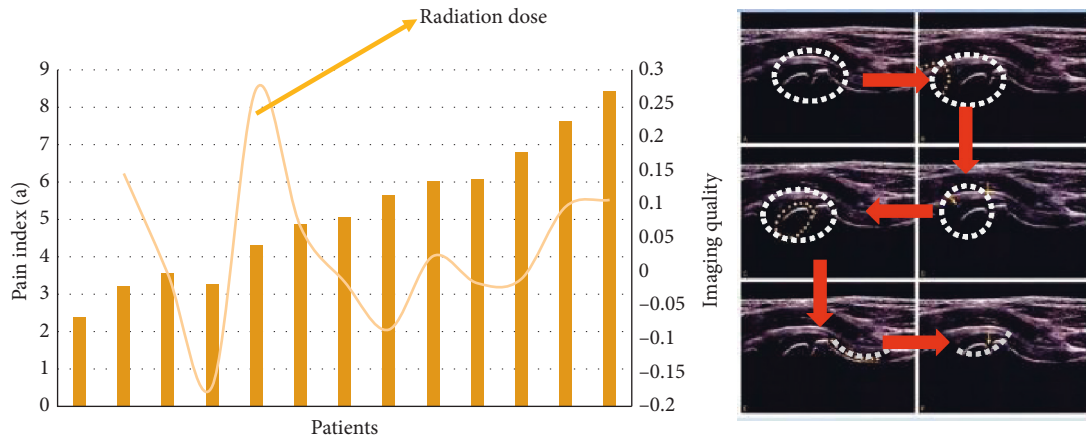


FIGURE 4: Ultrasound-guided pain control.

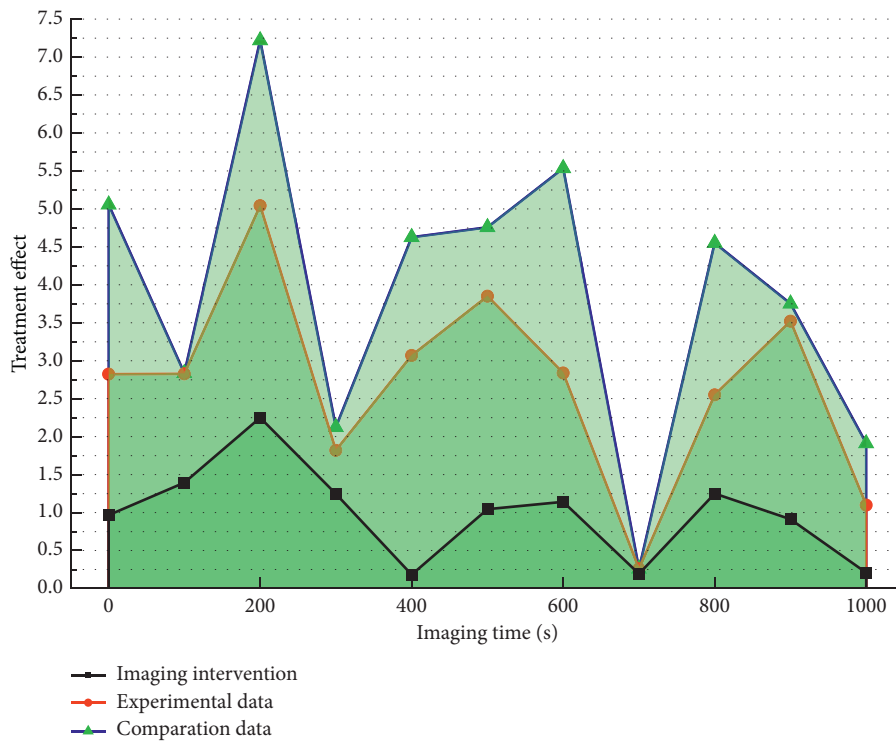


FIGURE 5: Long-term outcomes with imaging interventions.

solution can be precisely injected into the diseased nerve roots under ultrasound guidance to improve patients' lumbar and lower limb dysfunction. Nerve root block therapy mainly exerts its clinical effects through safe doses and concentrations of glucocorticoids and is currently used mainly for bone and joint, nerve, and soft tissue treatment. Lidocaine blocks nerve excitation and conduction by inhibiting nerve cell sodium channels. Related studies have shown that this approach has become a safe and effective therapy for aseptic inflammation.

However, the long-term effect of this method of treatment is not ideal, because it does not change the main cause of disc rupture but is only "symptomatic treatment," so the effect is short, but American chiropractic treatment

complements this defect, and it uses a quick and safe way to resolve vertebral subluxation and ossify the diseased vertebra. The long-term efficacy is addressed by stabilizing the diseased vertebrae in a state of pressure balance for a longer period of time. Few studies combining the two techniques have been reported, so we collected such patients for combined treatment and observed their long-term and short-term outcomes. It was found that the combination of the two techniques had a "complementary" effect, so "ultrasound-guided lumbar nerve root block combined with American chiropractic for lumbar muscle injuries" may be a more effective method for lumbar muscle injuries. The combination of ultrasound-guided lumbar nerve root block and American chiropractic treatment for lumbar muscle

injuries can provide satisfactory results in both immediate and long-term outcomes. Minimally invasive or interventional treatment is the core technology of pain management, so if pain physicians can combine their core technology with American chiropractic treatment for clinical application, there will be great application prospects and socioeconomic benefits.

4. Results and Discussion

Lumbar muscle injury is a series of clinical symptoms mainly caused by lumbar pain and cauda equina dysfunction due to the rupture of the fibrous ring and protrusion of the nucleus pulposus as a result of external forces or unbalanced forces on the basis of degenerative changes in the lumbar disc, mechanical compression of the adjacent nerve roots and spinal cord by the fibrous ring and/or nucleus pulposus, and stimulation of the nerves and surrounding soft tissues by inflammatory factors released from the nucleus pulposus. In recent years, electronic products are widely used, and sedentary workers are becoming more and more common, which leads to tension, weakness, spasm, force imbalance, and even atrophy of lumbar muscles and ligaments, which cannot protect the lumbar vertebrae and ancillary structures well, so the incidence of lumbar muscle injury has gradually increased in recent years, as shown in Figure 6. The incidence of lumbar muscle injury is mainly in young adults, more males than females, more heavy manual workers than light manual workers, more purely mental workers than mixed mental and physical workers, and more workers who work in a sedentary and permanent position. Because of the different segments of the lumbar muscle injury, the onset of the disease, and the individual differences of the patients, there is a large difference in the characteristics of clinical symptoms and the degree of impact on work and life of different patients. Lumbar muscle injury is a multidisciplinary cross-cutting disease, and the clinical understanding of lumbar muscle injury varies among different fields, different disciplines, and even different doctors in the same specialty, resulting in relatively large differences in treatment plans.

Patients with low back pain in the acute phase need at least half a month of bed rest, during which time the doctor will generally prohibit the patient from most of the exercises; sufficient scientific bed rest can make the injured muscles and ligaments get more adequate rest and repair, and the squeezed and strained muscles and ligaments can get very good relief, at the same time, bed rest can also help patients improve the lumbar spine. For these reasons, bed rest can not only improve the compression and stimulation of the lumbar nerve roots, spinal cord, and cauda equina, but also promote blood circulation in the lumbar region and eliminate sterile inflammation of the lumbar nerves, muscles, and ligaments. In taking bed rest for treatment, different patients should be different in the choice of mattress; generally speaking, fat patients can choose relatively hard mattress, relatively thin patients can choose relatively soft mattress, and moderate weight patients choose moderate hardness of the mattress, and for those who absolutely can

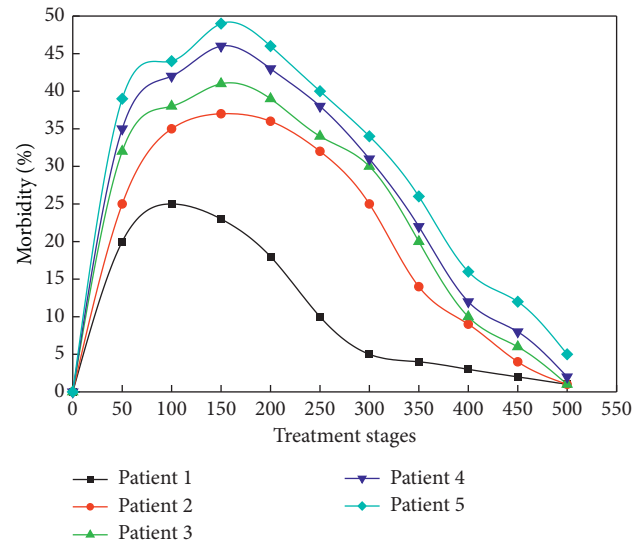


FIGURE 6: Incidence of lumbar muscle injuries.

not be generalized, all choose harder mattress, because hard mattress will be easier to damage thin patients stress contact parts of the soft tissue, is not conducive to improving the curvature of the patient's lumbar spine, and is not conducive to the repair of soft tissue in the lumbar region. This is mainly because of the following. (1) The clinical receiving physician was inexperienced and did not take into account the lumbar muscle rupture, and the examination request form only requested to examine the triceps calf injury. (2) Poor examination technique of the ultrasonographer resulted in the acoustic beam not being perpendicular to the lumbar muscles and affected by anisotropic artifacts, leading to missed diagnosis and misdiagnosis. (3) The lumbar muscle rupture occurred proximally, not in the good area of 2–6 cm on the heel bone, and the examining physician was inexperienced and did not move proximally until the muscle moved to the tendon as a result of continuous dynamic examination, as shown in Figure 7. (4) The scarring adhesions of the lumbar muscles are serious, and the calcification forms strong light clusters, which are obscured by the acoustic shadow behind the strong light clusters, resulting in a messy and unclear echogenicity, leading to a missed diagnosis. Compared with ultrasound, MRI is less common to miss lumbar muscle rupture, and it has the advantages of high soft tissue resolution, multisectional, multisequence, and multiparameter imaging, which can clearly show the site of lumbar muscle injury and has a high diagnostic accuracy. The advantages of ultrasound examination are mainly economical, convenient, reproducible, real-time dynamic observation, and facilitating follow-up.

High-frequency ultrasound is widely used for musculoskeletal system examination in recent years because of its high-frequency and high spatial resolution. The lumbar muscles are close to the subcutaneous layer of the heel skin and are superficially located, so high-frequency ultrasound can clearly show the lumbar muscles and peritendinous tissues, and MRI is the best way to examine soft tissue lesions. The area 2–6 cm above the heel stop of the lumbar

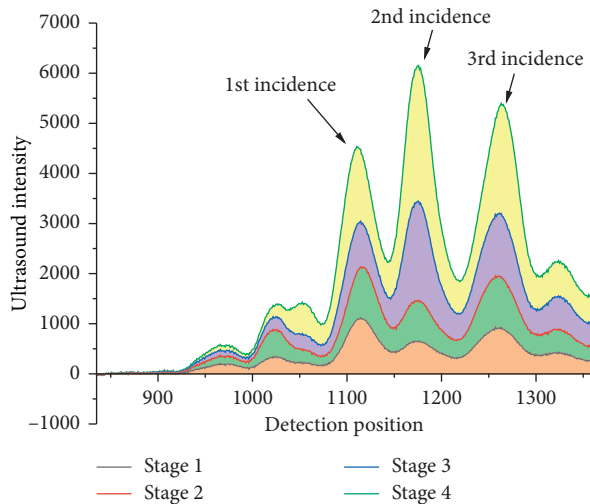


FIGURE 7: Site shift in the occurrence of lumbar muscle rupture.

muscles has the worst blood supply and is the most frequent site of lumbar muscle rupture, accounting for 72%–73% of lumbar muscle ruptures. Acute lumbar muscle rupture is mostly caused by trauma and is most common in sports enthusiasts, with typical symptoms and signs: sudden heel “stick sensation” during exercise, followed by pain, progressive swelling, limited plantar flexion of the ankle joint, and increased pain when walking (positive Thompson’s sign and positive single-footed heel lift test on physical examination). Acute lumbar muscle rupture has typical ultrasound findings: disruption of lumbar muscle continuity, visible severed ends, hypochoic filling between the severed ends, and retraction of the severed ends. High-frequency ultrasound has a diagnostic accuracy of 80% to 90% for acute lumbar muscle rupture, as shown in Figure 8, and is therefore often used as the first-line examination modality for lumbar muscle rupture. If the patient has insignificant postinjury swelling and pain, or can even flex the ankle or walk, coupled with insignificant ultrasound signs, it can easily lead to missed diagnosis and misdiagnosis, with a misdiagnosis rate of about 20% to 40%. Old lumbar muscle rupture accounts for about 25%–35% of the misdiagnosis rate of lumbar muscle rupture, which is mainly related to the misdiagnosis of acute lumbar muscle rupture, improper treatment method, degenerative changes of lumbar muscle, and glucocorticoid drug use. Currently, there is controversy regarding the time frame for old lumbar muscle rupture, with the literature using 3 weeks as the dividing line between fresh lumbar muscle rupture and old lumbar muscle rupture. Surgical pathology reveals that old lumbar muscle ruptures tend to have old clots, calcified tissue, severe scarring, and significant local adhesions. The literature reports numerous capillaries, vascular endothelial cell proliferation and luminal narrowing, and fibrous connective tissue hyperplasia within the severed ends of old lumbar muscle ruptures. Atypical sonogram of old lumbar muscle rupture shows the disappearance of normal continuous lumbar muscle echogenicity, replaced by thickened soft tissue echogenicity of uneven strength, with inconspicuous or faintly visible

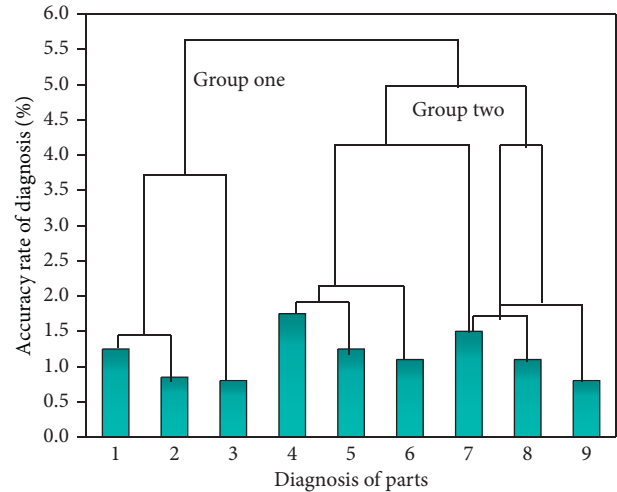


FIGURE 8: Diagnostic accuracy of lumbar muscle rupture.

severed ends, filled with weak or slightly strong echogenicity between severed ends, with dotted or patchy strong echogenicity, and partially obscured posterior acoustic shadow.

5. Conclusion

In this study, the diagnostic compliance rates of ultrasound and MRI for old lumbar muscle rupture were 81.1% and 96.2%, respectively, which were generally consistent with the data reported in the literature. The diagnostic accuracy of high-frequency ultrasound and MRI for complete and partial rupture of obsolete Achilles tendon in this study was 90.9% and 33.3% versus 97.7% and 88.9%, respectively. It can be seen that the difference between ultrasound and MRI for the diagnosis of complete rupture of obsolete lumbar muscles was not significant and the difference was not statistically significant ($\chi_2 = 1.908$, $P = 0.167$); the diagnostic compliance rate of ultrasound for partial rupture of obsolete lumbar muscles was significantly lower than that of MRI and the difference was statistically significant ($\chi_2 = 5.844$, $P = 0.016$), which is consistent with the results of previous studies. The sensitivity, specificity, positive predictive value, negative predictive value, and accuracy of ultrasound and MRI in the diagnosis of old lumbar muscle rupture in this study were 81.1%, 65.0%, 86.0%, 56.5%, and 76.7% and 96.2%, 95.0%, 98.1%, 90.5%, and 95.7%, respectively, indicating that the diagnostic value of ultrasound for old lumbar muscle rupture was lower than that of MRI, and the difference was statistically significant ($P < 0.05$).

Data Availability

The data used to support the findings of this study are available from the corresponding author upon request.

Conflicts of Interest

The authors declare that they have no known competing financial interests or personal relationships that could have appeared to influence the work reported in this paper.

References

- [1] M. Hosseini, R. Kelishadi, M. Yousefifard et al., "Height-adjusted percentiles evaluated central obesity in children and adolescents more effectively than just waist circumference," *Acta Paediatrica*, vol. 106, no. 1, pp. 112–119, 2017.
- [2] D. S. Buchan, G. McLellan, S. Donnelly, and R. Arthur, "Diagnostic performance of body mass index, waist circumference and the waist-to-height ratio for identifying cardiometabolic risk in scottish pre-adolescents," *Annals of Human Biology*, vol. 44, no. 4, pp. 297–302, 2017.
- [3] C. P. S. Pinho, A. D. S. Diniz, I. K. G. D. Arruda, A. P. D. L. Leite, M. D. M. V. Petribu, and I. G. Rodrigues, "Waist circumference measurement sites and their association with visceral and subcutaneous fat and cardiometabolic abnormalities," *Archives of Endocrinology and Metabolism*, vol. 62, no. 4, pp. 416–423, 2018.
- [4] P. R. D. F. Costa, A. M. O. Assis, C. D. M. Cunha et al., "Hypertriglyceridemic waist phenotype and changes in the fasting glycemia and blood pressure in children and adolescents over one-year follow-up period," *Arquivos Brasileiros De Cardiologia*, vol. 109, no. 1, pp. 47–53, 2017.
- [5] A. A. Mulligan, M. A. H. Lentjes, R. N. Luben, N. J. Wareham, and K.-T. Khaw, "Changes in waist circumference and risk of all-cause and cvd mortality: results from the European prospective investigation into cancer in norfolk (Epic-Norfolk) cohort study," *BMC Cardiovascular Disorders*, vol. 19, no. 1, p. 238, 2019.
- [6] M. S. Farris, K. S. Courneya, K. A. Kopciuk, S. E. McGregor, and C. M. Friedenreich, "Anthropometric measurements and survival after a prostate cancer diagnosis," *British Journal of Cancer*, vol. 118, no. 4, pp. 607–610, 2018.
- [7] Y. Li, X. Huang, Y. Wu et al., "The homa-1r cut-off values for diagnosis of insulin resistance and relationship of metabolic syndrome with insulin resistance in elderly people in minhang district of shanghai," *Chinese Journal of Endocrinology and Metabolism*, vol. 35, no. 8, pp. 672–677, 2019.
- [8] A. Andreasson, A. C. Carlsson, K. Önnérhag, and H. Hagström, "Waist/hip ratio better predicts development of severe liver disease within 20 years than body mass index: a population-based cohort study," *Clinical Gastroenterology and Hepatology*, vol. 15, no. 8, pp. 1294–1301, 2017.
- [9] A. Sam, C. Prez-Lpez, D. Rodriguez-Martín et al., "Estimating bradykinesia severity in Parkinson's disease by analysing gait through a waist-worn sensor," *Computers In Biology and Medicine*, vol. 84, pp. 114–123, 2017.
- [10] Y. Luo, X. Ma, Y. Shen et al., "Neck circumference as an effective measure for identifying cardio-metabolic syndrome: a comparison with waist circumference," *Endocrine*, vol. 55, no. 3, pp. 822–830, 2017.
- [11] Y. Assyov, A. Gateva, A. Tsakova, and Z. Kamenov, "A comparison of the clinical usefulness of neck circumference and waist circumference in individuals with severe obesity," *Endocrine Research*, vol. 42, no. 1, pp. 6–14, 2017.
- [12] J. M. Kinge, "Waist circumference, body mass index, and employment outcomes," *The European Journal of Health Economics*, vol. 18, no. 6, pp. 787–799, 2017.
- [13] K. Asahi, R. Yoshida, H. Ishii et al., "Validity of BMI and waist circumference in the diagnosis of dyslipidemia in a worksite population," *Journal for the Integrated Study of Dietary Habits*, vol. 29, no. 1, pp. 23–33, 2018.
- [14] Z.-H. Hou, B. Lu, Z.-N. Li et al., "Is waist-to-height ratio better than body mass index as a predictive indicator of coronary atherosclerosis disease? A cohort study," *Journal of Cardiovascular Computed Tomography*, vol. 13, no. 4, pp. 188–189, 2019.
- [15] M.-M. Liu, Q.-J. Liu, J. Wen et al., "Waist-to-hip ratio is the most relevant obesity index at each phase of insulin secretion among obese patients," *Journal of Diabetes and Its Complications*, vol. 32, no. 7, pp. 670–676, 2018.
- [16] T. Drijkoningen, P. Ten Berg, T. Guitton, D. Ring, and C. Mudgal, "Reliability of diagnosis of partial union of scaphoid waist fractures on computed tomography," *Journal of Hand and Microsurgery*, vol. 10, no. 3, pp. 130–133, 2018.
- [17] I. Snekvik, C. H. Smith, T. I. L. Nilsen et al., "Obesity, waist circumference, weight change, and risk of incident psoriasis: prospective data from the hunt study," *Journal of Investigative Dermatology*, vol. 137, no. 12, pp. 2484–2490, 2017.
- [18] J. P. Bembenek, M. Karlinski, M. Niewada, I. Kurkowska-Jastrzębska, and A. Członkowska, "Measurement of nutritional status using body mass index, waist-to-hip ratio, and waist circumference to predict treatment outcome in females and males with acute first-ever ischemic stroke," *Journal of Stroke and Cerebrovascular Diseases*, vol. 27, no. 1, pp. 132–139, 2018.
- [19] U. Backonja, M. L. Hediger, Z. Chen et al., "Beyond body mass index: using anthropometric measures and body composition indicators to assess odds of an endometriosis diagnosis," *Journal of Women's Health*, vol. 26, no. 9, pp. 941–950, 2017.
- [20] K. Sgambat, J. Roem, M. Mitsnefes et al., "Waist-to-height ratio, body mass index, and cardiovascular risk profile in children with chronic kidney disease," *Pediatric Nephrology*, vol. 33, no. 9, pp. 1577–1583, 2018.
- [21] F. Vasquez, P. Correa-Burrows, E. Blanco, S. Gahagan, and R. Burrows, "A waist-to-height ratio of 0.54 is a good predictor of metabolic syndrome in 16-year-old male and female adolescents," *Pediatric Research*, vol. 85, no. 3, pp. 269–274, 2019.
- [22] J. R. D. Andrade, G. Velasquez-Melendez, S. M. Barreto, T. S. S. Pereira, J. G. Mill, and M. D. C. B. Molina, "Fenótipo da cintura hipertrigliceridêmica e fatores nutricionais: um estudo com participantes do ELSA-Brasil," *Revista Brasileira De Epidemiologia*, vol. 20, no. 3, pp. 382–393, 2017.
- [23] W. Wei, B. Zhou, D. Połap, and M. Woźniak, "A regional adaptive variational PDE model for computed tomography image reconstruction," *Pattern Recognition*, vol. 92, pp. 64–81, 2019.
- [24] J. S. Almeida, P. P. Rebouças Filho, T. Carneiro et al., "Detecting Parkinson's disease with sustained phonation and speech signals using machine learning techniques," *Pattern Recognition Letters*, vol. 125, pp. 55–62, 2019.
- [25] Q. Ke, J. Zhang, W. Wei et al., "A neuro-heuristic approach for recognition of lung diseases from X-ray images," *Expert Systems with Applications*, vol. 126, pp. 218–232, 2019.