



Marked cytoreduction of a lymphocyte-rich mediastinal thymoma with neoadjuvant chemotherapy in a cat

Journal of Feline Medicine and Surgery
 Open Reports
 1–7

© The Author(s) 2015
 Reprints and permissions:
sagepub.co.uk/journalsPermissions.nav
 DOI: 10.1177/2055116915585024
jfmsopenreports.com



Linda J Tong¹, Giselle Hosgood¹, Julien Labruyère²,
 Susan L Bennett¹, Louise FitzGerald¹ and Robert E Shiel¹

Abstract

Case summary A 15-year-old neutered female domestic shorthair cat presented with lethargy and acute-onset dyspnoea. Thoracic computed tomography (CT) revealed a large, cranial mediastinal mass with an estimated volume of 180.7 cm³. Chemotherapy consisting of dexamethasone followed by L-asparaginase, prednisolone, vincristine and doxorubicin was commenced owing to the severity of disease and initial possibility of lymphoma. A diagnosis of lymphocyte-rich thymoma was made based upon histological examination, positive pancytokeratin staining, variable lymphocyte CD3 expression and T cell receptor gamma polyclonality. Thoracic CT performed 35 days after the commencement of chemotherapy showed a marked reduction in the size of the mass, with an estimated volume of 9.4 cm³. A median sternotomy and thymectomy were performed. No clinical signs have recurred 34 months after surgery.

Conclusions and relevance The response to chemotherapy in this case was unusual, and is likely associated with the high non-neoplastic lymphoid component of the mass. The case demonstrates that preoperative chemotherapy can be used to reduce thymoma volume prior to surgery, potentially decreasing anaesthetic risk.

Accepted: 20 October 2014

A 15-year-old neutered female domestic shorthair cat was referred for assessment of lethargy of 1 month's duration and acute-onset dyspnoea.

On physical examination, a moderate, restrictive, inspiratory dyspnoea pattern with increased abdominal effort was noted. Heart sound intensity was decreased over the left hemithorax and increased over the cranio-ventral right hemithorax. The apex beat was palpable, and lung sounds audible, over the right hemithorax but not the left. Anterior chest compressibility was reduced.

Radiographs performed prior to referral showed a large mediastinal mass occupying the left, ventral hemithorax extending from the thoracic inlet to the left diaphragmatic outline, causing right displacement of the cardiac silhouette (Figure 1a,b).

A complete blood count showed a moderate lymphocytosis ($13.7 \times 10^9/l$; reference interval [RI] $1.5\text{--}7.0 \times 10^9/l$). Circulating lymphocytes were predominantly small and well differentiated.

Serum biochemistry parameters and serum total thyroxine concentration were within the RIs. Feline leukaemia virus antigen and feline immunodeficiency virus antibody ELISA tests were negative (Witness FeLV-FIV; Zoetis).

Thoracic computed tomography (CT; Somatom Emotion Duo 2003 [Siemens]) was performed under general anaesthesia. Transverse 5 mm thick slices were acquired and reconstructed for soft tissue at 3–5 mm

¹Murdoch University Veterinary Hospital Murdoch, Western Australia, Australia

²Vet CT, St John's Innovation Centre, Cambridge, Australia

Corresponding author:

Linda J Tong BVSc (hons), MANZCVS, Western Australia Veterinary Emergency and Specialty, 640 Beelihar Drive, Success, Western Australia, 6164, Australia
 Email: lindajtong@gmail.com



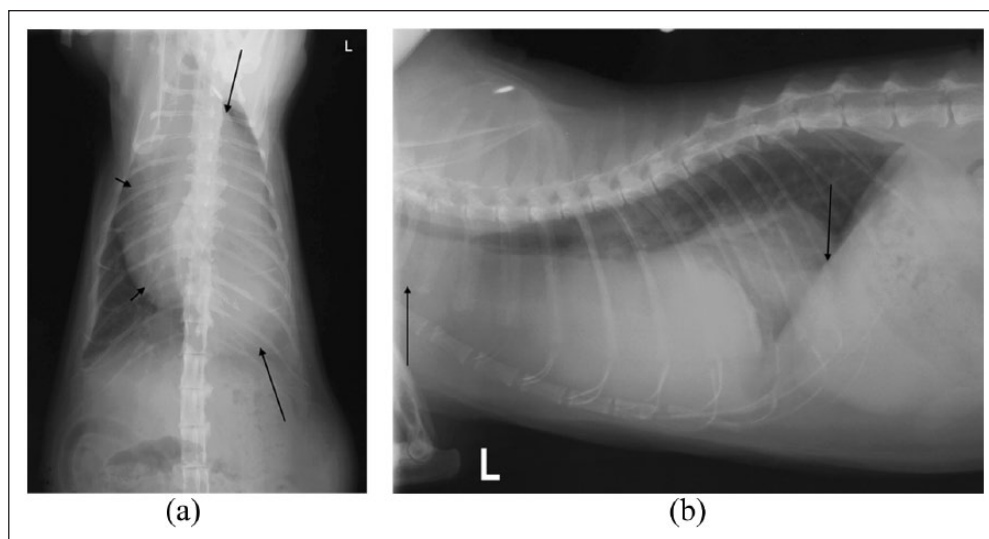


Figure 1 (a) Dorsoventral thoracic radiograph of a 15-year-old cat demonstrating a large cranial mediastinal mass. The mass extends in the left hemithorax from the level of the thoracic inlet (cranial arrow) to the level of the left diaphragmatic outline (caudal arrow). The cardiac silhouette (arrowheads) is displaced to the right. There is evidence of mild displacement of the trachea to the right as a result of the mass effect created by the cranial mediastinal mass. (b) Left lateral thoracic radiograph demonstrating a large cranial mediastinal mass extending from the level of the thoracic inlet (cranial arrow) to the diaphragmatic outline (caudal arrow)

intervals. Pre- and postcontrast (iohexol 600 mg/kg IV [Omnipaque; GE Healthcare]) images were examined in soft tissue and lung windows, and three-dimensional (3D) reconstruction was performed (Figure 2a,b). CT showed a large, poorly enhancing, soft tissue-attenuating mass in the cranial mediastinum expanding adjacent regions of the mediastinum. The mass extended from the thoracic inlet to the left diaphragmatic crura, filling most of the left hemithorax caudally and occupying the right and left hemithoraces cranially. The pulmonary parenchyma showed patchy, poorly defined regions of interstitial-alveolar density involving primarily the left caudodorsal lung lobe, consistent with atelectasia, most likely secondary to the presence of the mass and anaesthesia. There was a small amount of hypodense fluid present in both hemithoraces. There was moderate enlargement of the cranial mediastinal and tracheobronchial lymph nodes. 3D volume-rendered reconstruction of the mass was performed. Using OsiriX (Pixmeo) as a DICOM viewer, regions of interest (ROI) were drawn around the thoracic mass with the pencil tool in alternate slices, and the missing slides were interpolated by the DICOM viewer. The segmented volume was subsequently displayed as a 3D image and thymoma volume was automatically calculated. The 3D ROI was displayed in a 3D shaped surface in a separate window. Finally, a 3D volume of the entire CT study was performed and the ROI displayed into it and adjusted to the desired colour (green). The volume of the mass was estimated to be 180.7 cm³.

Fine-needle aspirates of the mediastinal mass were obtained with ultrasound guidance. Cytological

examination revealed predominantly well-differentiated small lymphocytes and an absence of epithelial cells (Table 1). Differential diagnoses considered on the basis of these findings included lymphocyte-rich thymoma or well-differentiated small cell lymphoma.

Needle biopsies (using a 14 G × 11 cm Temno-Evolution biopsy needle [Carefusion]) of the mediastinal mass were obtained with ultrasound guidance under general anaesthesia. Routine histopathological examination demonstrated sheets of predominantly small lymphocytes admixed with scattered neoplastic epithelial cells. On immunohistochemical evaluation, the majority of small lymphocytes exhibited variably intense membrane reactivity for CD3 (T cell marker) and the epithelial cell population was highlighted by strong, predominantly membranous reactivity for pancytokeratin. These findings were consistent with a diagnosis of lymphocyte-rich thymoma. Additionally, paraffin-embedded tissue submitted for a PCR for antigen receptor gene rearrangement (PARR) assay of T cell receptor gamma demonstrated a polyclonal rearrangement consistent with a non-neoplastic (reactive) T lymphocyte population within the mass.^{1,2} The results of these diagnostic evaluations are outlined in Table 1.

Chemotherapy was commenced on the day of biopsy, prior to return of the histopathology results. On recovery from general anaesthesia, the cat received chlorpheniramine maleate (1 mg/kg SC [Niramine; Jurox]), dexamethasone sodium phosphate (0.5 mg/kg IV [Dexadron; Intervet]) and L-asparaginase (400 IU/kg IM [Leunase; Aventis]), and was discharged receiving

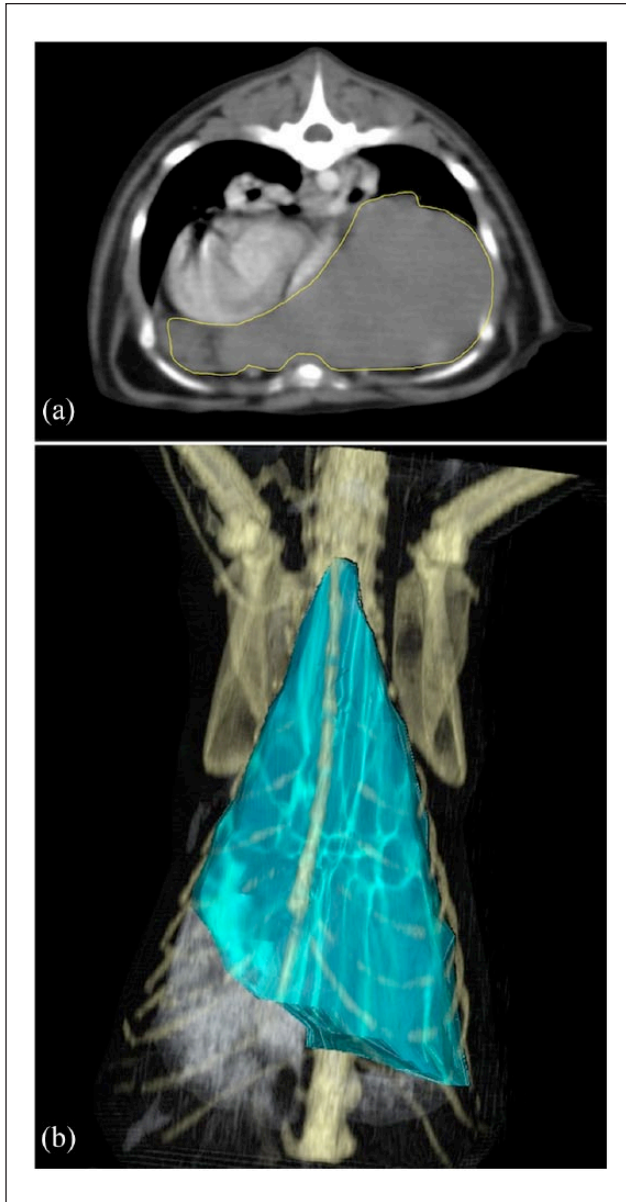


Figure 2 (a) Transverse image after contrast computed tomography of the thorax of a 15-year-old cat, at the level of the heart, demonstrating a large cranial mediastinal mass. (b) Three dimensional (3D) reconstruction of the thymoma prior to chemotherapy. The mass is outlined and the volume estimated using 3D reconstruction. The volume of the mass was 180.7 cm³

prednisolone (7.5 mg PO q24h for 2 weeks, prior to tapering to 5 mg PO q24h for 1 week followed by 2.5 mg PO q48h for 1 week [Pred-X5; Apex Laboratories]). One week following commencement of therapy, there was resolution of lymphocytosis ($5.56 \times 10^9/l$; RI $1.5\text{--}7.0 \times 10^9/l$) and vincristine (0.5 mg/m² IV [Vincristine sulfate injection; Pfizer]) was administered. Two weeks after vincristine administration, repeat thoracic radiographs showed a reduction in the size of the

mass (Figure 3a,b). There was a small, ill-defined triangular-shaped soft tissue opacity superimposed over the left caudal border of the cardiac silhouette. One week later the cat received doxorubicin hydrochloride injection (25 mg/m² IV [DBL; Hospira]). Four days following doxorubicin administration there were two episodes of vomiting. Apart from this, however, no clinical signs consistent with chemotherapeutic adverse effects were observed over the treatment period. A complete blood count (CBC) was performed prior to each chemotherapy treatment and showed no evidence of bone marrow suppression. In addition, 1 week after doxorubicin administration, a CBC and serum biochemistry profile were performed and showed no significant abnormalities.

Thoracic CT was repeated 2 weeks after doxorubicin administration (5 weeks after initiation of chemotherapy) for presurgical planning (Figure 4a,b). The volume of the mass was estimated to be 9.4 cm³, representing a 95% reduction in volume of the mass. There was persistent cranial mediastinal lymphadenomegaly but the previously reported tracheobronchial lymphadenomegaly and pleural fluid had resolved. A median sternotomy was performed under general anaesthesia, 2 weeks after doxorubicin administration (at a time when no medical therapy was being received). The mass was identified in the left cranial mediastinum and dissected free from surrounding mediastinal attachments and the pericardium. The left phrenic nerve and associated vasculature were adhered to the mass and were ligated and transected cranially and caudally and then removed with the mass. A 10 F chest tube was placed in the right hemithorax. The cat received remifentanyl hydrochloride (constant rate infusion [Remifentanyl; Sandoz]) intraoperatively, and was subsequently transitioned to fentanyl (constant rate infusion [Fentanyl injection; Astra Zeneca]) on anaesthetic recovery. A buprenorphine transdermal patch (buprenorphine 5 µg/h [Norspan; Mundipharma]) was placed postoperatively. Subsequent histopathological examination confirmed the previous diagnosis of thymoma, which this time comprised a greater proportion of neoplastic epithelial cells in addition to the small lymphocyte population (Table 1).

The cat recovered from surgery without complication. The chest tube was removed and the cat was discharged from the hospital the following day receiving transdermal buprenorphine analgesia. Twelve days after surgery, the cat re-presented with acute dyspnoea. The cat was not receiving any drug therapy at this time. Transthoracic ultrasonography revealed a large volume of pleural fluid and thoracocentesis yielded 180 ml of pink, turbid fluid. The results of the subsequent fluid evaluation, outlined in Table 2, were consistent with a non-septic exudate comprising predominantly small lymphocytes with fewer neutrophils. PARR assay revealed these lymphocytes to be polyclonal B and T lymphocyte populations,

Table 1 Diagnostic evaluation of the mediastinal mass

Test	Cytology (fine-needle aspirate)	Histopathology (needle biopsy)	Histopathology (excisional biopsy)
Morphological features	<ul style="list-style-type: none"> • 92% small lymphocytes • 4% intermediate lymphocytes • 3% neutrophils • 1% eosinophils • No epithelial or mesenchymal cells present 	<ul style="list-style-type: none"> • Sample comprises sheets of predominantly small lymphocytes admixed with scattered polygonal epithelial cells • Mitoses number <1 per 10 high-power fields in both cell populations 	<ul style="list-style-type: none"> • Sample composed of round to polygonal epithelial cells admixed with variable numbers of small lymphocytes • Mitotic figures are not observed
Ancillary tests	None	Immunohistochemistry: <ul style="list-style-type: none"> • the majority (approximately 60–70%) of small lymphocytes exhibit variable immunolabelling for CD3 (T-lymphocyte marker) and all are negative for CD79 (B-lymphocyte marker) • the epithelial cell population exhibits positive immunolabelling for pancytokeratin (AE1/AE3; epithelial cell marker) PARR assay: polyclonal T-cell population*	Immunohistochemistry: <ul style="list-style-type: none"> • the majority (>90%) of small lymphocytes are positive for CD3 • as in the previous needle biopsy, the epithelial cell population exhibits positive immunolabelling for pancytokeratin
Diagnostic interpretation	<ul style="list-style-type: none"> • Predominantly lymphoid cell population – differential diagnoses include lymphocyte-rich thymoma or well-differentiated small cell lymphoma 	<ul style="list-style-type: none"> • Thymoma (lymphocyte-rich) 	<ul style="list-style-type: none"> • Thymoma (mixed)

*Polymerase chain reaction for antigen receptor gene rearrangement (PARR) assay of T-cell receptor gamma

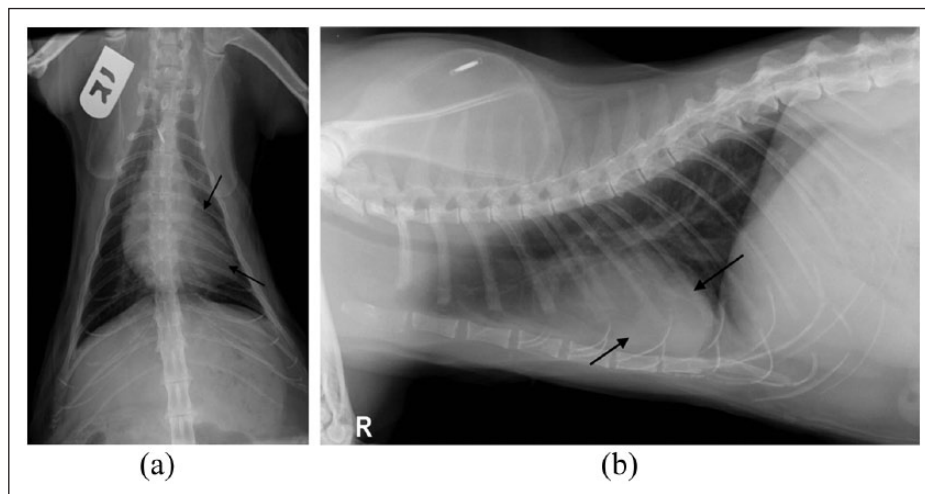


Figure 3 (a) Dorsoventral thoracic radiograph of a 15-year-old cat with a mediastinal mass (arrows) obtained 3 weeks after commencement of chemotherapy. There is a marked reduction in the size of the mass compared with Figure 1. The mass causes border effacement of the cardiac silhouette. (b) Right lateral thoracic radiograph. The mass has reduced in size considerably and is superimposed over the cardiac silhouette (arrows)

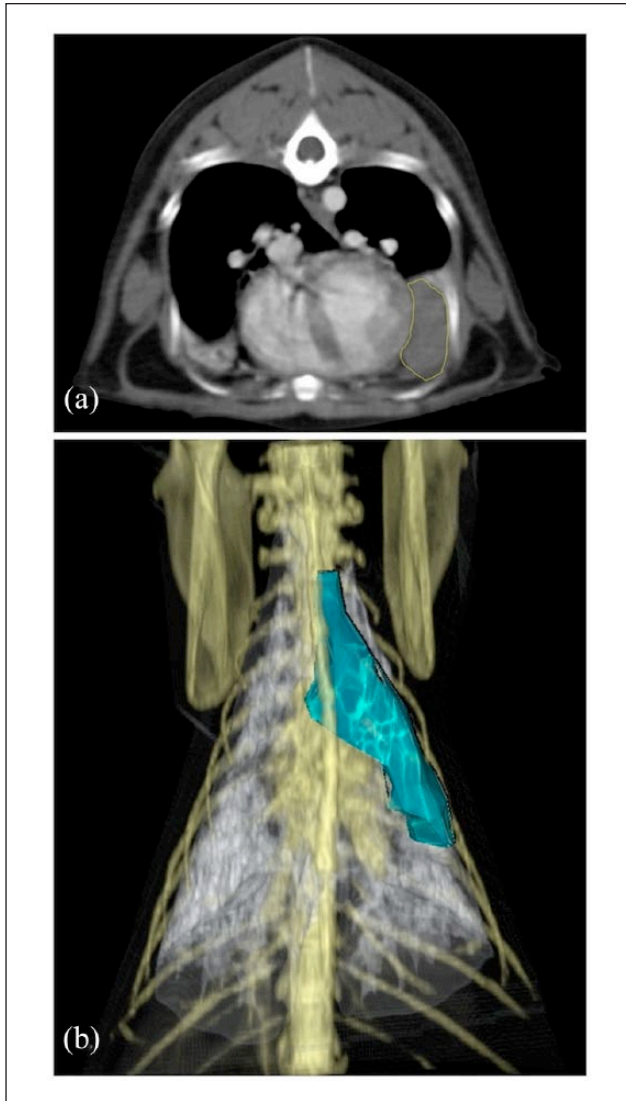


Figure 4 (a) Transverse image after contrast computed tomography of the thorax of a 15-year-old cat, at the level of the heart, demonstrating a cranial mediastinal mass 5 weeks after the start of chemotherapy. (b) Three-dimensional (3D) reconstruction of the thymoma following chemotherapy. The mass is outlined and the volume estimated using 3D reconstruction. The volume of the mass was 9.4 cm³, representing a 95% reduction in volume of the mass when compared with the previous CT examination

and flow cytometry yielded a normal percentage of lymphocyte subsets, supportive of a reactive process.¹

Serial thoracic ultrasound examinations identified progressive effusion, and thoracocentesis was repeated 2, 5 and 15 days after the original thoracocentesis, to relieve and prevent recurrent tachypnoea, with approximately 90 ml of grossly similar fluid being retrieved each time. The cat did not require any further thoracocentesis and the pleural effusion was confirmed as resolved by repeat thoracic ultrasonography 27 days after the original

thoracocentesis. The cat made a full recovery and no clinical signs have recurred 34 months after surgery.

Discussion

Thymomas are uncommon neoplasms that arise from the epithelial cells of the thymus.³⁻⁵ Thymomas are usually benign but can cause clinical signs by affecting respiratory capacity or causing compression of adjacent vital structures.⁶ In addition to the neoplastic epithelial cell component, these tumours also contain varying degrees of benign lymphocyte infiltration, and can be further categorised on this basis as being predominantly lymphocytic, predominantly epithelial or mixed.^{4,5} The presence of lymphocytes in association with the neoplastic thymic epithelium suggests that these cells retain at least some degree of lymphoid inductive capacity.⁴ As in this case, however, this feature can present a diagnostic challenge when large numbers of lymphocytes are present, obscuring the epithelial cells and mimicking the more common thymic lymphoma.^{4,5,7} This is particularly true in cytological preparations, where the lymphoid population tends to exfoliate much more readily than the epithelial component, which can lead to non-diagnostic samples.^{3,7,8} Similarly, given the frequent heterogeneous nature of these neoplasms, examination of multiple biopsies or serial sections may be required to demonstrate the epithelial cells, and immunohistochemical staining for cytokeratin is also helpful in this regard.⁴ The PARR assay is useful for evaluation of the lymphocyte population, aiding in the differentiation of a reactive (polyclonal) population from a neoplastic (monoclonal) lymphocyte proliferation.¹ Flow cytometry may also be useful in distinguishing mediastinal lymphoma from thymoma.^{3,9} Although not performed on the aspirates from the mediastinal mass in this case, predominantly owing to a lack of timely accessibility to an appropriate storage medium, flow cytometry of mediastinal masses is based on the fact that, in contrast to peripheral lymphocytes, the majority of thymic lymphocytes exhibit simultaneous expression of CD4 and CD8.^{9,10} Although not well characterised in cats for this purpose, CD4 and CD8 antibodies are available for use in cats and a study in dogs demonstrated that histologically confirmed cases of thymoma contained at least 10% of cells co-expressing CD4 and CD8, while in almost all cases of mediastinal lymphoma, CD4/CD8 co-expression was limited to <2% of lymphocytes.

In this case, the initial needle biopsy was comprised predominantly of small lymphocytes, while the excisional biopsy specimen comprised a mixed population of epithelial cells and lymphocytes. Given the frequent heterogeneous nature of thymomas,⁴ the discrepancy between the cellular components of each biopsy could be explained by the needle biopsy not being representative of the entirety of the mass. However, given the

Table 2 Pleural fluid evaluation

Fluid characteristics	Cytology	Molecular diagnostics	Additional diagnostics
<ul style="list-style-type: none"> • Pink, turbid • Cell count $57.4 \times 10^9/l$ • Protein concentration 36 g/l 	<ul style="list-style-type: none"> • 81.5% small lymphocytes • 13.0% non-degenerate neutrophils • 5.0% large mononuclear cells • 0.5% eosinophils 	<ul style="list-style-type: none"> • Flow cytometry results: normal percentage of lymphocyte subsets* • PARR assay: polyclonal (reactive) B- and T-lymphocyte populations† 	<ul style="list-style-type: none"> • Low triglyceride concentration (0.2 nmol/l) • Equal fluid triglyceride and serum triglyceride concentrations • Cholesterol to triglyceride ratio >1 • Microbial aerobic and anaerobic culture negative

*Utilising antibodies for CD4, CD8, CD3, CD5, CD14, CD21, CD22 and CD34

†PCR for antigen receptor gene rearrangement (PARR) assay of T-cell receptor γ and immunoglobulin heavy chain variable region genes

marked reduction in size of the mass following neoadjuvant chemotherapy, it is likely that chemotherapy may have effectively decreased the number of lymphocytic cells present within the mass, with or without a similar effect on the neoplastic epithelial cells. The postchemotherapy excisional biopsy histopathological findings of a higher proportion of epithelial cells to lymphocytes than that of the initial needle biopsy supports the assertion that chemotherapy was cytoreductive of the lymphocyte portion of the mass in this case.

The marked reduction in size of the thymoma in this case following neoadjuvant chemotherapy was unusual and therefore unexpected. As an optimal chemotherapeutic protocol for thymoma in dogs and cats has not been reported, a combination of L-asparaginase, vincristine, doxorubicin and prednisolone was chosen in this case because of the possibility for lymphoproliferative disease and desired activity against both lymphocytes and thymic epithelial cells. The two episodes of vomiting after the administration of doxorubicin may, according to the Veterinary Co-operative Oncology Group Common Terminology Criteria for Adverse Events, represent grade 1 gastrointestinal side effects.¹¹ Apart from this, no adverse effects occurred at any time during the treatment period and, overall, the described chemotherapeutic protocol was considered to be well tolerated.

Owing to the severity of disease and initial possibility of lymphoma, we chose to commence a CHOP (cyclophosphamide, doxorubicin, vincristine, prednisolone)-based chemotherapy protocol prior to receiving the histopathology and ancillary test results. Surgery is the treatment of choice for thymoma as complete dissection is often possible and medical management does not result in a cure.^{6,12} However, benefits of mass volume reduction prior to anaesthesia may include improved haemodynamic stability (owing to improved venous return to the cranial and caudal vena cava), reduced respiratory impairment and a reduced risk of lung reperfusion and re-expansion injury following lesion resection.^{13,14} Although thymoma was later confirmed, owing to the marked effect on tumour volume this

treatment was continued up to the time of surgery. In this case, the decision was made to proceed with surgery, while the lesion remained small and the cat remained in a clinically stable condition.

The role of chemotherapy in the treatment of thymoma in cats and dogs is unclear. In one case series reporting the outcome of surgically excised thymoma, one of two cats receiving neoadjuvant chemotherapy was documented to have a slight decrease in tumour size following chemotherapy (vincristine, cyclophosphamide and prednisolone).¹² The second cat received prednisolone alone in conjunction with pyridostigmine for myasthenia gravis but the response to treatment was not reported.¹² In another case series evaluating the efficacy of radiation therapy, 4/7 cats also received chemotherapy.¹⁵ Individual protocols consisted of prednisolone alone or in combination with L-asparaginase, single-agent doxorubicin, and a combination of cyclophosphamide, vincristine and prednisolone. A complete response was seen in two cats, a partial response in one cat and the response was not evaluable in one cat owing to concurrent illness and data censorship. In most cases the timing of chemotherapy was not specified, making it difficult to distinguish the relative effectiveness of chemotherapy and radiation therapy. However, a partial response prior to radiation therapy was described in the case receiving doxorubicin alone. The use of corticosteroids alone has also been associated with a subjective reduction in thymoma size.^{16–18} In humans, the successful use of neoadjuvant chemotherapy has been described to reduce thymoma size prior to surgery.¹⁹ Thymoma is considered a radiosensitive tumour in human medicine,²⁰ and the use of radiation therapy to reduce thymoma size is more extensively documented in the veterinary literature.^{15,18,21,22} However, this option was not available in this case.

The cause of the peripheral lymphocytosis noted during initial haematological evaluation is not known. Given the subsequent resolution of the lymphocytosis and the subsequent diagnosis of a non-lymphoproliferative neoplasm, additional diagnostic tests such as flow cytometry and PARR assay were not pursued to further characterise

this population; and given the small and well-differentiated nature of these cells a reactive process was favoured. Interestingly, peripheral T-cell lymphocytosis has been reported in association with lymphocyte rich-thymomas in humans and one dog,^{23,24} and it is possible that the peripheral lymphocytosis in this case may have been reflective of a similar paraneoplastic syndrome.

The cause of the postoperative lymphocyte-rich exudate is unknown. Possibilities include postoperative inflammatory reaction (secondary, eg, to the pleurotomy and tissue trauma), surgical disruption of the thoracic lymphatics and local immunological mechanisms.²⁵

Conclusions

In this case, a marked reduction in thymoma volume was achieved with chemotherapy, likely related to the high non-neoplastic lymphoid component of the mass. Neoadjuvant chemotherapy could be considered in cases of lymphocyte-rich thymoma, if radiation therapy is unavailable.

Acknowledgements We thank and acknowledge Victoria Park Veterinary Clinic for referring the case and supplying the initial thoracic radiographs.

Funding The authors received no specific grant from any funding agency in the public, commercial or not-for-profit sectors for the preparation of this case report.

Conflict of interest The authors do not have any potential conflicts of interest to declare.

References

- 1 Avery A. **Molecular diagnostics of hematologic malignancies.** *Top Compan Anim Med* 2009; 24: 144–150.
- 2 Moore PF, Woo JC, Vernau W, et al. **Characterization of feline T cell receptor gamma (TCRG) variable region genes for the molecular diagnosis of feline intestinal T cell lymphoma.** *Vet Immunol Immunopathol* 2005; 106: 167–178.
- 3 de Mello Souza CH. **Miscellaneous tumors: thymoma.** In: Withrow SJ, Vail DM and Page RL (eds). *Withrow & MacEwen's small animal clinical oncology*. 5th ed. St Louis, MO: Elsevier/Saunders, 2013, pp 679–715.
- 4 Jacobs RM, Messick JB and Valli VE. **Tumors of the hemolymphatic system.** In: Meuten DJ (ed). *Tumors in domestic animals*. 4th ed. Ames, IA: Iowa State Press, 2002, pp 119–198.
- 5 Valli VE. **Hematopoietic system.** In: Maxie MG (ed). *Pathology of domestic animals*. 5th ed. Philadelphia, PA: Saunders, 2007, pp 107–324.
- 6 Withrow SJ. **Thymoma.** In: Withrow SJ and Vail DM (eds). *Withrow and MacEwen's small animal clinical oncology*. 4th ed. St Louis, MO: WB Saunders, 2007.
- 7 Zitz JC, Birchard SJ, Couto GC, et al. **Results of excision of thymoma in cats and dogs: 20 cases (1984–2005).** *J Am Vet Med Assoc* 2008; 232: 1186–1192.
- 8 Rae CA, Jacobs RM and Couto CG. **A comparison between the cytological and histological characteristics in thirteen canine and feline thymomas.** *Can Vet J* 1989; 30: 497–500.
- 9 Lana S, Plaza S, Hampe K, et al. **Diagnosis of mediastinal masses in dogs by flow cytometry.** *J Vet Intern Med* 2006; 20: 1161–1165.
- 10 Reggeti F and Bienzle D. **Flow cytometry in veterinary oncology.** *Vet Pathol* 2011; 48: 223–235.
- 11 Veterinary Co-operative Oncology Group (VCOG). **Veterinary Co-operative Oncology Group-common terminology criteria for adverse events (VCOG-CTCAE) following chemotherapy or biological antineoplastic therapy in dogs and cats v1. 0.** *Vet Comp Oncol* 2004; 2: 194–213.
- 12 Zitz JC, Birchard SJ, Couto GC, et al. **Results of excision of thymoma in cats and dogs: 20 cases (1984–2005).** *J Am Vet Med Assoc* 2008; 232: 1186–1192.
- 13 Matsumiya N, Dohi S, Kimura T, et al. **Reexpansion pulmonary edema after mediastinal tumor removal.** *Anesth Analg* 1991; 73: 646–648.
- 14 Bacha EA, Chapelier AR, Macchiarini P, et al. **Surgery for invasive primary mediastinal tumors.** *Ann Thorac Surg* 1998; 66: 234–239.
- 15 Smith AN, Wright JC, Brawner W, et al. **Radiation therapy in the treatment of canine and feline thymomas: a retrospective study (1985–1999).** *J Am Anim Hosp Assoc* 2001; 37: 489–496.
- 16 North SM and Banks TA. **Small animal oncology: an introduction.** Elsevier Health Sciences, 2009 Philadelphia.
- 17 Withrow SJ. **Miscellaneous tumors: thymoma.** In: Withrow SJ and MacEwen EG (eds). *Small animal clinical oncology*. 2nd ed. Philadelphia, PA: WB Saunders, 1996, pp 530–533.
- 18 Kaser-Hotz B, Rohrer CR, Fidel JL, et al. **Radiotherapy in three suspect cases of feline thymoma.** *J Am Anim Hosp Assoc* 2001; 37: 483–488.
- 19 Macchiarini P, Chella A, Ducci F, et al. **Neoadjuvant chemotherapy, surgery, and postoperative radiation therapy for invasive thymoma.** *Cancer* 1991; 68: 706–713.
- 20 Curran W, Kornstein M, Brooks J, et al. **Invasive thymoma: the role of mediastinal irradiation following complete or incomplete surgical resection.** *J Clin Oncol* 1988; 6: 1722–1727.
- 21 Hitt M, Shaw D, Hogan P, et al. **Radiation treatment for thymoma in a dog.** *J Am Vet Med Assoc* 1987; 190: 1187.
- 22 Meleo KA. **The role of radiotherapy in the treatment of lymphoma and thymoma.** *Vet Clin North Am Small Anim Pract* 1997; 27: 115.
- 23 Barton AD. **T-cell lymphocytosis associated with lymphocyte-rich thymoma.** *Cancer* 1997; 80: 1409–1417.
- 24 Batlivala T, Bacon N, Avery A, et al. **Paraneoplastic T cell lymphocytosis associated with a thymoma in a dog.** *J Small Anim Pract* 2010; 51: 491–494.
- 25 Charniot J-C, Zerhouni K, Kambouchner M, et al. **Persistent symptomatic pleural effusion following coronary bypass surgery: clinical and histologic features, and treatment.** *Heart Vessels* 2007; 22: 16–20.