


Weightbearing Forefoot Axial Radiography - Technical Description and Reproducibility Evaluation*

Radiografia axial do antepé com carga - Descrição da técnica e avaliação da reprodutibilidade

Rafael Barban Sposeto¹  Marcos Hideyo Sakaki¹ Alexandre Leme Godoy-Santos¹
Rafael Trevisan Ortiz¹ Rodrigo Sousa Macedo¹ Tulio Diniz Fernandes¹

¹ Foot and Ankle Group, Orthopedics and Traumatology Institute, Hospital das Clínicas da Faculdade de Medicina da Universidade de São Paulo (HCFMUSP), São Paulo, SP, Brazil

Address for correspondence Rafael Barban Sposeto, MD, Rua Dr. Ovídio Pires de Campos, 333. Cerqueira Cesar, São Paulo, SP, CEP: 05403-010, Brazil (e-mail: rafael.barban@hc.fm.usp.br).

Rev Bras Ortop 2020;55(3):367-373.

Abstract

Objective The present study aims to describe a new weightbearing radiographic method to visualize the heads of the five metatarsals on the coronal plane, evaluating their accuracy through intraclass correlation coefficients.

Methods The subjects were evaluated, with weightbearing, with the ankle at 20 degrees of plantar flexion and the metatarsophalangeal joints at 10 degrees of extension, positioned on a wooden device. Two independent foot and ankle surgeons evaluated the radiography, with one of them doing it twice, at different moments, achieving an inter and intraobserver correlation, with intraclass correlation coefficients.

Results We radiographed 63 feet, achieving an interobserver correlation coefficient of the radiographic method for the metatarsal heads heights in the coronal plane of the 1st, 2nd, 3rd, 4th, and 5th metatarsals of, respectively, 0.90, 0.85, 0.86, 0.83, 0.89. The intraobserver correlation coefficient were, respectively, 0.95, 0.93, 0.93, 0.86, 0.92.

Conclusion Those correlations demonstrate that the method is accurate and can be used to investigate metatarsal head misalignments in this plane.

Keywords

- ▶ forefoot, human
- ▶ radiography
- ▶ metatarsalgia
- ▶ metatarsal bones
- ▶ foot diseases
- ▶ metatarsophalangeal joint

Resumo

Palavras-chave

- ▶ antepé humano
- ▶ radiografia
- ▶ metatarsalgia
- ▶ ossos do metatarso
- ▶ doenças do pé
- ▶ articulação metatarsofalângica

Objetivo Este estudo tem como objetivo descrever um novo método radiográfico com carga fisiológica para visualizar as cabeças dos cinco metatarsos no plano coronal.

Métodos Os indivíduos foram radiograficamente avaliados com carga, com o tornozelo a 20° de flexão plantar e as articulações metatarsofalângicas a 10° de extensão, posicionadas em um dispositivo de madeira. As medidas foram aferidas por dois avaliadores independentes, sendo que um deles mediu em dois momentos distintos, obtendo a correlação inter e intraobservador, com o coeficiente de correlação intraclassas.

Resultados Examinamos 63 pés, obtendo um coeficiente de correlação interobservador do método radiográfico para as alturas das cabeças dos metatarsos no plano coronal do 1°,

* Foot and ankle Group, Orthopedics and Traumatology Institute, Hospital das Clínicas HCFMUSP, Medicine School, University of São Paulo, São Paulo, SP, Brazil

2°, 3°, 4° e 5° metatarsos de, respectivamente, 0,90, 0,85, 0,86, 0,83, 0,89. O coeficiente de correlação intraobservador foi, respectivamente, 0,95, 0,93, 0,93, 0,86, 0,92.

Conclusão Essas correlações demonstram que o método é preciso e pode ser usado para investigar os desalinhamentos de cabeça dos metatarsos nesse plano.

Introduction

Much is discussed about the position of metatarsal heads in the coronal plane, with some authors defending the arch disposition and others stating that the five heads position themselves aligned in the same plan.¹⁻¹⁰

Traditionally the transverse arch at the height of the metatarsal head was considered existing, in a way that the distal portions of the 1st and 5th metatarsals would be closer to the soil than the central ones during the load.¹⁰

The existence of the transverse arch at the height of the metatarsal heads is quite controversial, and debated since the mid-1800s, presenting contradictory results.²⁻¹¹

While Lelièvre,¹² Mann,¹³ Saló,¹⁴ Sarrafian and Kelikian,¹⁵ and Viladot^{16,17} affirm that the metatarsals' heads are aligned in the coronal plane with load, Simonsen et al⁸ and Kapandji,¹⁸ among others,^{19,20} defend the three-point support theory, with the transverse arch with apex dorsal at the head height of the 2nd metatarsal.

Walter-Muller (1926), Blondin-Walter (1948), Guntz (1938) apud Lelièvre,¹⁹ Viladot,¹⁷ Suzuki et al,²¹ and Osher et al²² propose different radiographic techniques to visualize the disposition of metatarsal head in the coronal plane. Some were criticized for not loading the foot, others for excessive extension of the metatarsophalangeal joints. So far, there is no consensus on what would be the physiological disposition of the metatarsal heads with load in the coronal plane, whether aligned or arched. It also questions what would be the best radiographic method to evaluate this plan.

The shape and disposition of the metatarsal is considered to have a direct impact on the load distribution of the feet.^{13,23} Changes in the physiological alignment of the metatarsal are related to poor distribution of load, overloading several structures of the forefoot,^{6-8,24-26} causing metatarsalgia.

The metatarsal heads are the most distal structures of these bones that will dissipate the forefoot load during the gait detachment phase. Thus, the alignment of these structures in the coronal plane has an impact on the load distribution and eventual lesions of the region, culminating in metatarsalgia.⁹⁻¹¹

Thus, knowing the physiological coronal alignment of the metatarsal heads can give us an additional parameter to aid the etiological diagnosis of metatarsalgia and complement the correction surgical technique.²⁷

However, in order to adequately study this coronal alignment, it is essential to determine a precise and reproducible radiographic method to evaluate the projection of the metatarsal heads with load on the coronal plane.

Our hypothesis is that the proposed radiographic method to assess the disposition of the heads of the five metatarsals with load in the coronal plane is precise and can be used as an

investigation of misalignments of the metatarsal heads in the transverse arch of the forefoot.

The aim of the present study is to describe a new radiographic method for visualizing the heads of the five metatarsals in the coronal plane with load, evaluating its accuracy and reproducibility through intra- and interobserver correlation.

Materials and methods

The study project was approved by the Ethics and Institutional Research Committee, with registration number 13000.

The patients were randomly recruited in the ankle and foot service, respecting the inclusion and exclusion criteria.

The patients were instructed on what the research consisted of, and the written consent term was obtained. Patients who did not accept the term were not included in the study.

An initial clinical evaluation was performed, seeking specific plantar complaints in the forefoot and proximal deformities.

Inclusion criteria

- Ambulatory patients, between 30 and 65 years of age, without restrictions on sex or race;
- Absence of rigid deformities in the midfoot, hindfoot, and ankle;
- Absence of:
 - Previous surgeries or fractures in the foot;
 - Rheumatologic diseases and causes of secondary metatarsalgia (tumor in the forefoot, Frieberg's disease, foreign body, Morton's infection and neuroma not associated with mechanical disturbance);
 - Osteoneuromuscular syndromes;
 - Unilateral amputation of the lower limb;
 - Retrofoot alignments considered abnormal at physical examination (valgus and varus).

Exclusion criterion

- Poor quality radiography that does not allow evaluation.

The individuals were submitted to an axial radiography with forefoot load, evaluating the coronal plane.

Method for acquiring images

The patient was positioned in orthostasis, conferring load on the foot with the ankle at 20° plantar flexion and 10° extension of the metatarsophalangeal joints, with the foot

supported in a molded wooden bracket. The radiographic film was supported immediately anterior and perpendicular to the bracket.

The tube was positioned posterior to the calcaneus, so that the rays incised from posterior to anterior parallel to the horizontal support plane, 1 m from the radiographic film. Each foot was radiographed in isolation, so that the contralateral maintained a plantigrade load on a 2 cm tall wood platform in the center of the bracket. (► **Figure 1**)

The wooden device consists of a flat rectangular base, containing in its center another wood rectangle, 2 cm high, allowing plantar support of the contralateral foot to the one examined. On each side of this bracket, two ramps were positioned. The posterior ramp is fixed, which allowed the positioning of the ankle in equine of 20°, and the anterior ramp is movable extending all metatarsophalangeal joints in 10°.

The anterior ramp moved in the longitudinal direction of the feet, moving away or towards the heads of the metatarsals, and rotating on the axial plane.

This mobility of the anterior ramp creates a space for forefoot support, allowing the plantar region under the heads of the five metatarsals to be supported in the same plane. To standardize the position of the forefoot in this space, there is a marking for the positioning of the head of the 5th metatarsal (► **Figure 2**).

The radiographic technical parameters for obtaining axial projection were standardized for all patients and calibrated so that it kept the ampoule with a focus of 100 mA, with 55 kV at a focus-film distance of 100 cm, with exposure time of 0.1 second, 10 mA/s and using a 24 × 30 cm chassis for each foot. The center of the rays' focus was defined in the topography of the head of the 2nd metatarsal, with the opening large enough to design the tibiotalar articular line,

the malleolus, and the plantar face of the forefoot, with a 3-cm region being visible plantar to the support level of the wooden device.

The measurement of the incidence parameters of the coronal plane of the forefoot with load was done with the program Philips iSite Enterprises 4.1 (Philips Healthcare, Best, Netherlands). Initially the load surface of the forefoot is located. It is the line in which the epidermis makes contact with the wood, here called the support line. Subsequently, the point most plantar of the head of each metatarsal is found. In the 1st metatarsal, different from the other four, the load is distributed in the sesamoids, so we use the most plantar point of the most plantar sesamoid. From these five points, we traced five perpendicular lines to the support line previously drawn, gauging their distances in millimeters (► **Figure 3**).

So, we recruited 35 individuals, participating with 70 feet.

Radiographs were independently evaluated by two orthopedists specializing in foot and ankle surgery. After 2 months, they were reassessed by one of them. The examiners had no access to the patients' anamnesis data and physical examination, as well as the previous radiographic measurements, at the time of radiographic measurement.

The inter- and intraobserver method error was evaluated using the intraclass correlation coefficient for continuous variables, with their respective confidence intervals.^{28,29} For the comparison of the coefficients, we followed the guidelines of Landis and Koch.²⁸

Results

Thirty-five individuals (70 feet) were evaluated. In the initial phase of the study, we were adjusting both the positioning of the device and the radiographic technique, so seven feet

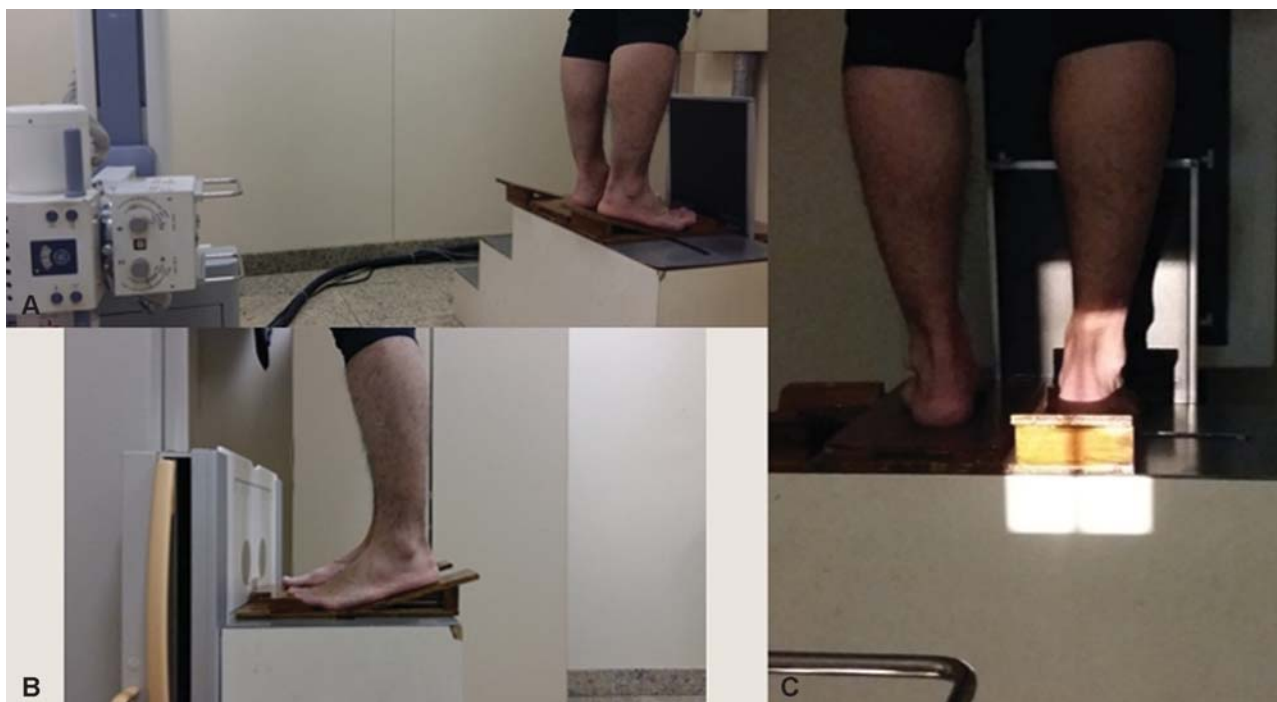


Fig. 1 Positioning of the patient for the acquisition of axial radiography of the forefoot with load. (A) radiographic ampoule at 1 m away from the film; (B) positioning of the ankle in 20° of equine, with 10° of finger extension in relation to the support; (C) total radiographed area.




Fig. 2 Positioning bracket for radiographic acquisition. (A) top view with the anterior ramp in the most proximal position; (B) top view with the anterior ramp in the most distal position. Blue arrow indicating the positioning of the 5th metatarsal head; (C) top view with the previous round ramp to accommodate the fingers; (D) posterior view, evidencing the central support of the device for the positioning of the foot contralaterally to the examination; (E) side view, showing the anterior and posterior ramps.

were excluded due to poor radiography quality that made the evaluation impossible.

The intra- and interobserver correlation was performed in the remaining 63 feet, with 31 feet being the right-side ones, and 91% of the individuals being male.

The results of the intra-observer evaluation are in ► **Table 1**.

The results of the interobserver evaluation are in ► **Table 2**.

The interobserver correlation coefficient of the radiographic method for the heights in the coronal plane of the 1st, 2nd, 3rd, 4th and 5th metatarsal were, respectively, 0.90, 0.85, 0.86, 0.83, 0.89.

The intra-observer correlation coefficient of the radiographic method for the heights in the coronal plane of the 1st, 2nd, 3rd, 4th and 5th metatarsal were, respectively, 0.95, 0.93, 0.93, 0.86, 0.92 (► **Table 3**).

Discussion

The aim of the present study was to evaluate the accuracy and reproducibility of the use of axial radiography of the forefoot with load. The technique was designed so that the heads of the metatarsals could be adequately visualized by creating clear and reproducible criteria for positioning the feet with load on the platform.

The aim of the study was not to compare the coronal alignment of the metatarsal heads between the patients, but to assess the accuracy of the radiographic method. For this reason, we did not divide patients into groups, by sex, laterality or metatarsalgia and included unilateral and bilateral radiographs of the individuals.

At the beginning of the study, we observed that if we kept the positioning of the anterior and posterior ramps fixed and

in direct contact, there would be no room to support the whole forefoot in the same plane, forcing an artificial support of each of the metatarsal heads. As the metatarsals have different lengths, they were supported at different heights in the ramps, projecting an axial radiographic image not compatible with the physiological load disposition.

The radiographic proposals of Suzuki et al.²¹ and Mittlemeier and Haar³⁰ to assess the position of sesamoids also allow the assessment of lateral metatarsal heads. However, as the devices described by them place the fixed anterior and posterior ramps in contact, they position the heads of the metatarsal inappropriately, being unsuitable for assessing the alignment of the heads in the coronal plane with load. That is one of the differences in our radiographic proposal.

Based on the 2004 study by Suzuki et al.,²¹ we adapted our radiographic technique in relation to the distance and incidence of the X-ray, so as to standardize all examinations, avoiding differences in magnifications between radiographs. The intensity of the radiation, as well as the exposure time, were based on the studies of Osher et al.²² and Simonsen et al.⁸ and modified so that we can accurately observe the radiographic projection of the heads, reaching the parameters proposed in our study.

Our first seven radiographic incidences were used to adapt the adopted positioning and radiographic parameters. For this reason, 7 feet were excluded for inadequate radiographs, and we evaluated 63 feet.

Similarly to the study of Suzuki et al.,²¹ we chose to position the ankle with 20° of equine and 10° of extension of the metatarsophalangeal joint in relation to the soil to reproduce the moment of detachment of the foot in the calcaneal elevation phase, when the forefoot is subjected to greater overload.³¹⁻³³

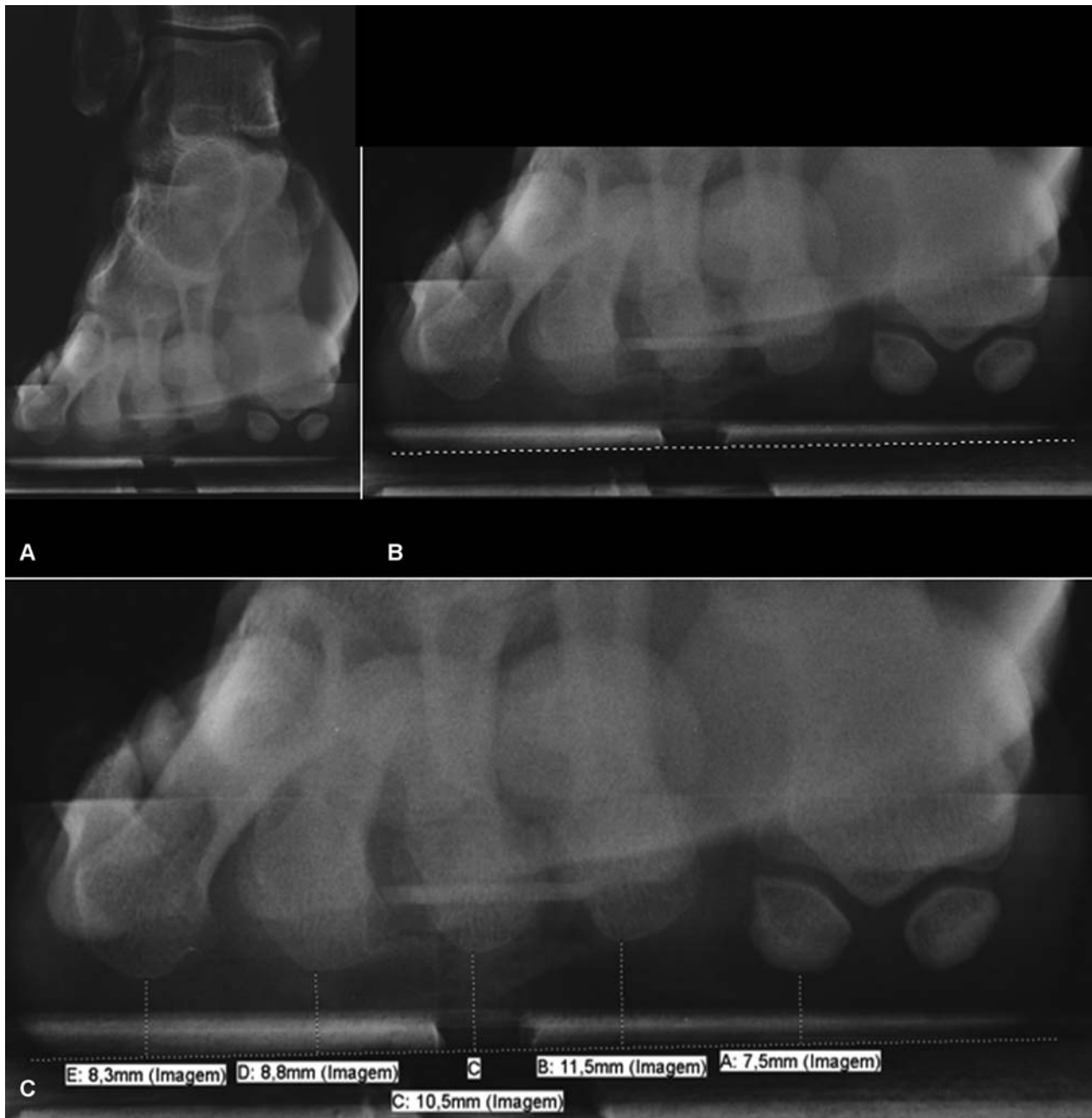

Fig. 3 Visual aspect of axial radiography with forefoot load. (A) image obtained allowing the visualization of all forefoot; (B) line of support drawn, marking the plane of the forefoot load; (C) from the most plantar points of the five rays we measure the distance to the line.

Table 1 Results of the measurements of the same evaluator at two different moments (evaluation intra-observer)

	1 st evaluation			2 nd evaluation		
	Average	95%CI	SD	Average	95%CI	SD
1 st MTT	7.6	7.23–8.01	1.57	7.6	7.18–8.10	1.85
2 nd MTT	12.2	11.80–12.54	1.50	12.0	11.70–12.40	1.40
3 rd MTT	10.7	10.45–11.06	1.24	10.6	10.27–11.01	1.50
4 th MTT	9.5	9.21–9.70	0.98	9.5	9.15–9.84	1.40
5 th MTT	9.4	9.00–9.85	1.72	9.6	9.10–10.14	2.11

Abbreviations: CI, confidence interval; MTT, metatarsal; SD, standard deviation.

Table 2 Results of the measurements of the second evaluator

	Average	95%CI	SD
1 st MTT	7.2	6.76–7.70	1.86
2 nd MTT	11.7	11.40–12.10	1.47
3 rd MTT	10.4	9.98–10.75	1.56
4 th MTT	9.2	8.81–9.53	1.46
5 th MTT	9.3	8.80–9.82	2.06

Abbreviations: CI, confidence interval; MTT, metatarsal; SD, standard deviation.

Table 3 Inter and intra-observer evaluation of axial radiography of the forefoot with load

	Interobserver correlation coefficient	95%CI	Intraobserver correlation coefficient	95%CI
1 st MTT	0.9	0.843–0.940	0.95	0.921–0.970
2 nd MTT	0.85	0.765–0.907	0.93	0.882–0.955
3 rd MTT	0.86	0.776–0.912	0.93	0.883–0.955
4 th MTT	0.83	0.736–0.895	0.86	0.785–0.915
5 th MTT	0.89	0.824–0.932	0.92	0.877–0.953

Abbreviations: CI, confidence interval; MTT, metatarsal.

However, unlike Suzuki et al,²¹ our device features a previous mobile ramp that allows the skin under the heads of the five metatarsals to rest on the same level of the wooden bracket, avoiding artificial modifications of its heights in the coronal plane by the support of the heads in different heights on the previous ramp.

We used the head support point of the 5th metatarsal as the initial fixed parameter of positioning. Thus, we mobilized the anterior ramp, for distal or proximal position, in order to allow the cushion support under the five heads on the same porch. We used to rotate the previous ramp, accommodating the formula of the toes, to keep the five toes in the desired extension.

To assess the reliability of the axial radiographic study, we used intra- and inter-observer evaluation, according to Simonsen et al⁸ and Deleu et al.³⁴ To classify the values of the correlation coefficients, we used the orientation of Landis and Koch.²⁸ Thus, the results of the intra and interobserver evaluation coefficients on axial radiography of the forefoot with load showed a strong correlation, according to Landis and Koch,²⁸ for the five metatarsals.

We observed a better correlation in the intra and interobserver evaluation in our study compared to that of Simonsen et al,⁸ probably related to the methodological difference and the accuracy of the positioning of the two studies. Comparing our correlation indexes with those of the sonographic study by Wang et al,³⁵ we observed, once again, greater correlation accuracy in our study, especially when comparing the situation with load in the study by Wang et al.³⁵ The difference can be explained by the difficulty in performing the sonographic examination with the patient keeping load.

The study subjects were not divided into groups with and without metatarsalgia, which was a weakness of the study. However, this has low impact on the evaluation of intra and interobserver, since the objective was to evaluate the accuracy of the radiography obtained of each foot. The validation of this methodology will allow the quantification of the heights of the metatarsal heads with load in the coronal plane, comparing groups with and without metatarsalgia in later studies.

Conclusion

We present a new radiographic methodology to evaluate the disposition of the five metatarsal heads with load, in the coronal plane. The strong intra and interobserver correlation demonstrate that the method is accurate and can be used to investigate the dealignments of metatarsal heads in this plane.

Conflict of Interests

The authors have no conflict of interests to declare.

References

- Luger EJ, Nissan M, Karpf A, Steinberg EL, Dekel S. Patterns of weight distribution under the metatarsal heads. *J Bone Joint Surg Br* 1999;81(02):199–202
- Bygrave CJ, Betts RP. The plantar tissue thickness in the foot: a new ultrasound technique for loadbearing measurements and a metatarsal head depth study. *Foot* 1993;3(02):71–78
- Demp PH. Pathomechanical metatarsal arc: radiographic evaluation of its geometric configuration. *Clin Podiatr Med Surg* 1990;7(04):765–776
- Kaipel M, Krapf D, Wyss C. Metatarsal length does not correlate with maximal peak pressure and maximal force. *Clin Orthop Relat Res* 2011;469(04):1161–1166
- Kanatli U, Yetkin H, Bolukbasi S. Evaluation of the transverse metatarsal arch of the foot with gait analysis. *Arch Orthop Trauma Surg* 2003;123(04):148–150
- Khurana A, Kadamabande S, James S, Tanaka H, Hariharan K. Weil osteotomy: assessment of medium term results and predictive factors in recurrent metatarsalgia. *Foot Ankle Surg* 2011;17(03):150–157
- Lauf E, Weinraub GM. Asymmetric “V” osteotomy: a predictable surgical approach for chronic central metatarsalgia. *J Foot Ankle Surg* 1996;35(06):550–559, discussion 601
- Simonsen O, Vuust M, Understrup B, Højbjerg M, Böttcher S, Voigt M. The transverse forefoot arch demonstrated by a novel X-ray projection. *Foot Ankle Surg* 2009;15(01):7–13
- Wang CL, Hsu TC, Shau YW, Shieh JY, Hsu KH. Ultrasonographic measurement of the mechanical properties of the sole under the metatarsal heads. *J Orthop Res* 1999;17(05):709–713
- Weijers RE, Walenkamp GHIM, Kessels AGH, Kemerink GJ, van Mameren H. Plantar pressure and sole thickness of the forefoot. *Foot Ankle Int* 2005;26(12):1049–1054
- Daentzer D, Wülker N, Zimmermann U. Observations concerning the transverse metatarsal arch. *Foot Ankle Surg* 1997;3(01):15–20
- Lelièvre J. *Arquitectura del Pie*. In: Lelièvre J, editor. *Patología del pie - clínica, tratamiento médico, ortopédico y quirúrgico*. Barcelona: Masson; 1970
- Mann RA, Haskell A. *Biomechanics of the foot and ankle*. In: Coughlin MJ, Mann RA, Saltzman C, editors. *Surgery of the foot and anklefoot and ankle*. 8th ed. Philadelphia, PA: Mosby Elsevier; 2007:3–44

- 14 Saló JM. Metatarsalgia. In: Viladot A, editor. *Quinze lições sobre patologias do pé*. Rio de Janeiro: Revinter; 2003:145–164
- 15 Sarrafian SK, Kelikian AS. Osteology. In: Kelikian AS, editor. *Anatomy of the foot and ankle*. 3rd ed. Philadelphia, PA: Lippicott Williams & Wilkins; 2011:40–119
- 16 Viladot A. Anatomia e biomecânica. In: Viladot A, editor. *Quinze lições sobre patologias do pé*. Rio de Janeiro: Revinter; 2003:1–40
- 17 Viladot A. The betatarsal. In: Jahss MH editor. *Disorders of the foot*. Philadelphia: Saunders; 1982:659–710
- 18 Kapandji AI. *Fisiologia articular: membro inferior*. 4ª ed. São Paulo: Manole; 1980
- 19 Lelièvre J. Estática del pie. In: Lelièvre J, editor. *Patología del pie - clínica, tratamiento médico, ortopédico y quirúrgico*. Barcelona: Masson; 1970
- 20 Chang JW, Griffiths H, Chan DP. A new radiological technique for the forefoot. *Foot Ankle* 1984;5(02):77–83
- 21 Suzuki J, Tanaka Y, Takaoka T, Kadono K, Takakura Y. Axial radiographic evaluation in hallux valgus: evaluation of the transverse arch in the forefoot. *J Orthop Sci* 2004;9(05):446–451
- 22 Osher LS, DeMore M III, Atway S, Thomson MK. Extended pedal imaging via modifications of the traditional forefoot axial radiographic study: teaching new tricks to an old dog? an initial report with case presentations. *J Am Podiatr Med Assoc* 2008;98(03):171–188
- 23 Coughlin MJ. Common causes of pain in the forefoot in adults. *J Bone Joint Surg Br* 2000;82(06):781–790
- 24 Trnka HJ, Mühlbauer M, Zettl R, Myerson MS, Ritschl P. Comparison of the results of the Weil and Helal osteotomies for the treatment of metatarsalgia secondary to dislocation of the lesser metatarsophalangeal joints. *Foot Ankle Int* 1999;20(02):72–79
- 25 Davies MS, Saxby TS. Metatarsal neck osteotomy with rigid internal fixation for the treatment of lesser toe metatarsophalangeal joint pathology. *Foot Ankle Int* 1999;20(10):630–635
- 26 Maestro M, Besse JL, Ragusa M, Berthonnaud E. Forefoot morphology study and planning method for forefoot osteotomy. *Foot Ankle Clin* 2003;8(04):695–710
- 27 Devos Bevernage B, Leemrijse T. Predictive value of radiographic measurements compared to clinical examination. *Foot Ankle Int* 2008;29(02):142–149
- 28 Landis JR, Koch GG. The measurement of observer agreement for categorical data. *Biometrics* 1977;33(01):159–174
- 29 Lin LI. A concordance correlation coefficient to evaluate reproducibility. *Biometrics* 1989;45(01):255–268
- 30 Mittlmeier T, Haar P. Sesamoid and toe fractures. *Injury* 2004;35 (Suppl 2):SB87–SB97
- 31 Canseco K, Long J, Marks R, Khazzam M, Harris G. Quantitative characterization of gait kinematics in patients with hallux rigidus using the Milwaukee foot model. *J Orthop Res* 2008;26(04):419–427
- 32 Caravaggi P, Leardini A, Crompton R. Kinematic correlates of walking cadence in the foot. *J Biomech* 2010;43(12):2425–2433
- 33 Arnold JB, Mackintosh S, Jones S, Thewlis D. Differences in foot kinematics between young and older adults during walking. *Gait Posture* 2014;39(02):689–694
- 34 Deleu PA, Pod H, Leemrijse T, Birch I, Vande Berg B, Bevernage BD. Reliability of the Maestro radiographic measuring tool. *Foot Ankle Int* 2010;31(10):884–891
- 35 Wang TG, Hsiao TY, Wang TM, Shau YW, Wang CL. Measurement of vertical alignment of metatarsal heads using a novel ultrasonographic device. *Ultrasound Med Biol* 2003;29(03):373–377