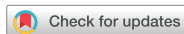

Case Report

Infectious Diseases,  
Microbiology & Parasitology



# Mixed Infection with *Plasmodium falciparum* and *Plasmodium ovale* in a Returned Traveller: the First Case in Korea

Gayeon Kim ,<sup>1</sup> Hyo-Lim Hong ,<sup>2</sup> So Yeon Kim ,<sup>3</sup> Hye Ryun Lee ,<sup>3</sup>  
Dong Geun Kim ,<sup>4</sup> Seungman Park ,<sup>5</sup> Hyoung-Shik Shin ,<sup>1</sup> Bum Sik Chin ,<sup>1</sup>  
and YeonJae Kim <sup>1</sup>

<sup>1</sup>Department of Internal Medicine, National Medical Center, Seoul, Korea

<sup>2</sup>Department of Internal Medicine, Catholic University of Daegu School of Medicine, Daegu, Korea

<sup>3</sup>Department of Laboratory Medicine, National Medical Center, Seoul, Korea

<sup>4</sup>Department of Laboratory Medicine, Seoul National University Hospital, Seoul, Korea

<sup>5</sup>Green Cross Laboratories, Yongin, Korea

OPEN ACCESS

Received: Jan 19, 2018

Accepted: Oct 22, 2018

Address for Correspondence:

Gayeon Kim, MD

Department of Internal Medicine, National  
Medical Center, 245 Eulji-ro, Jung-gu,  
Seoul 04564, Korea.

E-mail: simply.gayeon@gmail.com

© 2019 The Korean Academy of Medical  
Sciences.

This is an Open Access article distributed  
under the terms of the Creative Commons  
Attribution Non-Commercial License ([https://  
creativecommons.org/licenses/by-nc/4.0/](https://creativecommons.org/licenses/by-nc/4.0/))  
which permits unrestricted non-commercial  
use, distribution, and reproduction in any  
medium, provided the original work is properly  
cited.

ORCID iDs

Gayeon Kim

<https://orcid.org/0000-0001-9788-9800>

Hyo-Lim Hong

<https://orcid.org/0000-0003-2147-1381>

So Yeon Kim

<https://orcid.org/0000-0003-1774-0382>

Hye Ryun Lee

<https://orcid.org/0000-0001-9175-6441>

Dong Geun Kim

<https://orcid.org/0000-0002-3248-4623>

Seungman Park

<https://orcid.org/0000-0003-2123-3711>

Hyoung-Shik Shin

<https://orcid.org/0000-0002-5998-2956>

## ABSTRACT

Mixed-species malaria infections are often unrecognized or underestimated. We hereby report the first described case of mixed infection with *Plasmodium falciparum* and *Plasmodium ovale* malaria in a returned traveller in Korea. In August 2016, a 25-year-old returned traveller from Cameroon and Democratic Republic of Congo presented with fever. He was diagnosed as *P. falciparum* malaria and successfully treated with artesunate. And 5 weeks after the completion of treatment, he presented with fever and diagnosed as *P. ovale* infection. *P. ovale* infection is a rare cause of malaria and often shows delayed presentation due to its dormant liver stage as hypnozoites. At re-presentation, the immunochromatographic test and microscopic examinations of our patient did not reveal *P. ovale*, which was only detected via polymerase chain reaction (PCR) assay. This case highlights the importance of considering malaria infection even in persons who have previously received malaria treatment. It also shows the usefulness of PCR testing for diagnosing *P. ovale* infections, which often present with a low level of parasitaemia.

**Keywords:** Mixed Infection; *Plasmodium falciparum*; *Plasmodium ovale*

## INTRODUCTION

Mixed-species malaria infections are often unrecognized or underestimated.<sup>1</sup> Such infections accounted for 2.1% of the 1,140 cases of malaria logged by the GeoSentinel Surveillance Network based on treating physician diagnoses between 1997 and 2002.<sup>2</sup> We hereby report the first described case of mixed infection with *Plasmodium falciparum* and *Plasmodium ovale* in a returned traveller in Korea.

Bum Sik Chin <https://orcid.org/0000-0003-3021-1434>YeonJae Kim <https://orcid.org/0000-0003-4144-9077>**Disclosure**

The authors have no potential conflicts of interest to disclose.

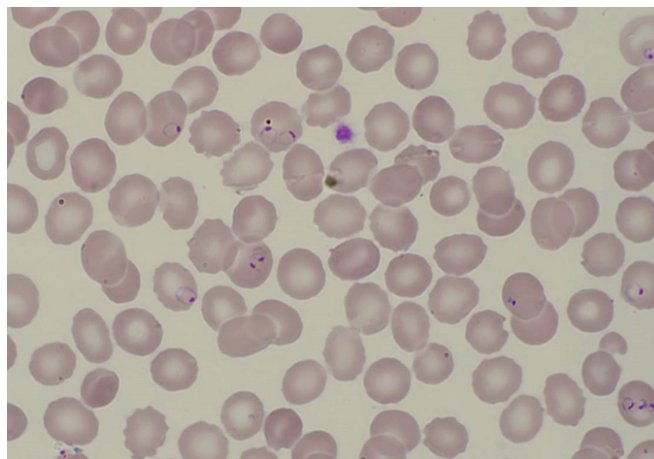
**Author Contributions**

Conceptualization: Kim G. Investigation: Hong HL, Kim SY, Lee HR, Kim DG, Park S. Writing - original draft: Kim G. Writing - review & editing: Kim SY, Shin HS, Chin BS, Kim Y.

**CASE DESCRIPTION**

A 25-year-old man of Korean origin, presented to the emergency department of the National Medical Center in August 2016. He travelled Cameroon and the Democratic Republic of the Congo for sixteen days, arriving Korea on 20th July 2016. He did not take malarial chemoprophylaxis. On 2nd August he had fever, headache and vomiting and visited National Medical Center on 5th August. Laboratory tests showed normal values for hemoglobin (Hb) and white blood cells, but the patient had a low platelet count of 16,000/ $\mu$ L (normal, 130,000–400,000/ $\mu$ L). Both aspartate transaminase (AST) and alanine transaminase (ALT) were elevated, with levels of 57 U/L (normal, < 40 U/L) and 58 U/L (normal, < 45 U/L), respectively. A peripheral blood smear revealed the presence of malarial parasites at a concentration of 459,448/ $\mu$ L (parasite density, 10.1%) (Fig. 1). The malarial parasites exhibited ring forms with occasional double chromatin dots. The Pf/Pan immunochromatographic test (ICT; SD BIOLINE Malaria Ag Pf/Pan™; Standard Diagnostics, Inc., Suwon, Korea) was positive for both *P. falciparum*-specific histidine-rich protein-2 and lactate dehydrogenase of *Plasmodium* species (*P. falciparum*, *Plasmodium vivax*, *Plasmodium malariae*, and *P. ovale*). *Plasmodium* species-specific polymerase chain reaction (PCR) assays confirmed the presence of *P. falciparum* and were negative for *P. vivax*, *P. malariae*, and *P. ovale*. For the PCR assays, nucleic acids were extracted from peripheral blood using MagnaPure 96 automated nucleic acid extractor and DNA and Viral NA SV Kit according to the manufacturer's instructions (Roche Diagnostics, Mannheim, Germany). A nested PCR for *Plasmodium* spp. 18S rRNA (490 bp amplicon), *P. vivax* (470 bp), and *P. falciparum* (340 bp) was performed according to the modified protocols from previous report.<sup>3</sup>

Upon being diagnosed with falciparum malaria, the patient was admitted and treated with intravenous artesunate (2.4 mg/kg body weight/dose at 0, 12, 24, and 48 hours), followed by atovaquone/proguanil at a dose of 1,000/400 mg per day for 3 days. Fever subsided on the 3rd day after the initial examination, and the patient remained afebrile until the day of discharge. Based on peripheral blood smear, the number of malarial parasites in the bloodstream had decreased to 386,579/ $\mu$ L (parasite density, 9.2%) at the 12-hour follow-up, and malarial parasites were not observed at the 24-hour follow-up. Both AST



**Fig. 1.** Peripheral blood smear (5th August 2016). Microscopic examination was performed by two independent clinical pathologists. Microscopic examination of Wright-Giemsa stained peripheral blood smear revealed that many ring forms of *Plasmodium* parasites with occasional double chromatin dots (459,448/ $\mu$ L). Multiply-infected red blood cells were frequent.

and ALT continuously increased until they reached maximum levels of 231 U/L and 233 U/L, respectively, on the 3rd day after the initial examination and decreased thereafter. The patient's platelet count continuously increased after the initial examination and was 184,000/ $\mu$ L on the 12th day after the initial examination. The patient's condition improved, and he was discharged on 10th August.

On 14th September 2016, which was 36 days after completing artesunate treatment, and 33 days after completing atovaquone/proguanil treatment, the patient developed fever with a body temperature of 40°C. He visited Daegu Catholic University Hospital on 19th September. A peripheral blood smear revealed no malarial parasites. The *Plasmodium* species-specific PCR assays were performed. For the PCR assays, nucleic acids were extracted from peripheral blood using Chemagic 360 according to the manufacturer's instructions (PerkinElmer, Waltham, MA, USA). *Plasmodium*-screening PCR and *Plasmodium* species-typing PCR were performed according to the modified protocols from previous reports.<sup>4,5</sup> These assays produced positive result for *P. ovale* and negative results for *P. falciparum*, *P. vivax*, and *P. malariae*. Laboratory tests showed Hb of 7.0 d/dL (haematocrit of 21.1%) and a platelet count of 106,000/ $\mu$ L. Chloroquine was given, but the patient did not take the drug. He visited the National Medical Center on 6th October. He was afebrile and in good general condition. The PCR assays performed at National Medical Center showed positive result for *Plasmodium* spp., but the involved species could not be determined due to the low parasite concentration. The ICT was negative for both Pan and Pf column. A peripheral blood smear revealed no malarial parasites. Chloroquine 600 mg base was given and followed by at a dose of 300 mg base at 6, 24, and 48 hours for the *P. ovale* treatment, and fourteen days of primaquine (30 mg base/day) were administered for the eradication of possible hypnozoites. PCR tests were performed on 26th October and produced negative results for *P. falciparum*, *P. ovale*, *P. vivax*, and *P. malariae*. The patient has remained symptom-free.

### Ethics statement

The patient provided written informed consent.

## DISCUSSION

Among mixed malaria infections, mixed *P. falciparum* and *P. ovale* infections are particularly rare, accounting for only 0.3% of total malaria infections in the afore mentioned GeoSentinel study.<sup>2</sup> The rarity of *P. ovale* infection is the primary reason for the extremely low incidence of such mixed infections. *P. ovale* occurs in Africa and in foci within Asia and Oceania and is often present with other *Plasmodium* species in the context of mixed infections. The natural distribution of *P. ovale* is in sub-Saharan Africa and the islands of the western Pacific.<sup>6</sup> In the Manyemen forest region of Cameroon, the prevalence of *P. ovale* was 10.5%.<sup>7</sup> Of 198 malaria-positive samples of children under 5 years old, 17.2% were positive for *P. ovale* in Democratic Republic of Congo.<sup>8</sup> The other reason for the rarity of *P. falciparum* and *P. ovale* mixed infection is that *P. ovale* tends to be missed in mixed infections because of its low parasite density.<sup>9</sup> To our knowledge, there have been four case reports to date that have described mixed-species malaria infections in Korea, all of which involved *P. falciparum* and *P. vivax* mixed infections<sup>10-13</sup>; thus, the case described here is the first reported case of *P. falciparum* and *P. ovale* mixed infection in Korea.

The delayed clinical presentation of *P. ovale* malaria could be attributable to its different life cycle compared with that of *P. falciparum*. *P. ovale* has a dormant liver stage during which

parasites exist as hypnozoites and can remain silent for years. In our case, the patient had no history of prior travel to endemic area for *P. falciparum* or *P. ovale* other than Cameroon and the Democratic Republic of the Congo. And he did not travel outside of Korea during the period between the two episodes of *Plasmodium* infection. Since Korea is free of those two *Plasmodium* species, it is likely that the patient was infected with both *Plasmodium* species during his trip to Cameroon and the Democratic Republic of the Congo. At the first presentation of *Plasmodium* infection, the PCR assays were positive only for *P. falciparum* and negative for *P. ovale*. The mean prepatent period of *P. ovale* infection is 12–20 days, with a median of 14.5 days.<sup>14</sup> The symptom onset of second presentation took place on the 52nd day after leaving Cameroon and the republic of Congo. It is likely that *P. ovale* remained dormant in hepatocytes as hypnozoites at the time of initial presentation, rather than in the prepatent period, since 52 days are longer than typical prepatent period of *P. ovale*.

In an entomological survey that investigated 2,485 *Anopheles* mosquito specimens in Cameroon from October 2004 to September 2005, the annual average sporozoite rate was 5.8%, and no specimens with *P. falciparum* and *P. ovale* mixed infection were found.<sup>15</sup> In Papua New Guinea, 2.3% of infected mosquitoes were found to carry a mix of *P. falciparum* and *P. vivax* malarial organisms, whereas the prevalence of mixed infections in humans was 69.3%.<sup>16</sup> Given the relatively low prevalence of mixed infections in mosquitoes, it is plausible that mixed infections result from separate inoculations of sporozoites from mosquitoes infected with a single species rather than the simultaneous inoculation of sporozoites from mosquitoes infected with multiple species.

The ICT, which permits immediate diagnosis, is known to have suboptimal sensitivity for *P. ovale* (approximately 60%).<sup>17</sup> Expert blood film microscopy is the standard diagnostic method for malaria, but young ring forms of three malarial species may be difficult to distinguish in thick blood films during co-infections.<sup>18</sup> At re-presentation, the ICT and microscopic examinations of our patient did not reveal *P. ovale*. Compared with microscopy and the ICT, PCR testing has the highest sensitivity for detecting parasites at low levels.<sup>19</sup> In a meta-analysis that included 42 articles, the prevalence of infection detected using microscopy was 50.8% of detected using PCR.<sup>20</sup> PCR testing should be considered when a low level of parasitaemia is suspected, such as mixed-species malaria infections.

This case highlights the importance of considering malaria infection even in persons who have previously received malaria treatment. It also shows the usefulness of PCR testing for diagnosing *P. ovale* infections, which often present with a low level of parasitaemia.

## ACKNOWLEDGEMENTS

The authors thank Dr. Geehay Hong, Samkwang Medical Laboratories, for her technical assistance for this study.

## REFERENCES

1. Mayxay M, Pukrittayakamee S, Newton PN, White NJ. Mixed-species malaria infections in humans. *Trends Parasitol* 2004;20(5):233–40.  
[PUBMED](#) | [CROSSREF](#)

2. Leder K, Black J, O'Brien D, Greenwood Z, Kain KC, Schwartz E, et al. Malaria in travelers: a review of the GeoSentinel surveillance network. *Clin Infect Dis* 2004;39(8):1104-12.  
[PUBMED](#) | [CROSSREF](#)
3. Snounou G, Viriyakosol S, Zhu XP, Jarra W, Pinheiro L, do Rosario VE, et al. High sensitivity of detection of human malaria parasites by the use of nested polymerase chain reaction. *Mol Biochem Parasitol* 1993;61(2):315-20.  
[PUBMED](#) | [CROSSREF](#)
4. Ciceron L, Jaureguierry G, Gay F, Danis M. Development of a *Plasmodium* PCR for monitoring efficacy of antimalarial treatment. *J Clin Microbiol* 1999;37(1):35-8.  
[PUBMED](#)
5. Kimura M, Miyake H, Kim HS, Tanabe M, Arai M, Kawai S, et al. Species-specific PCR detection of malaria parasites by microtiter plate hybridization: clinical study with malaria patients. *J Clin Microbiol* 1995;33(9):2342-6.  
[PUBMED](#)
6. Lysenko AJ, Beljaev AE. An analysis of the geographical distribution of *Plasmodium ovale*. *Bull World Health Organ* 1969;40(3):383-94.  
[PUBMED](#)
7. Cornu M, Combe A, Couprie B, Moyou-Somo R, Carteron B, Van Harten WH, et al. Epidemiological aspects of malaria in 2 villages of the Manyemen forest region (Cameroon, Southwest Province). *Med Trop (Mars)* 1986;46(2):131-40.  
[PUBMED](#)
8. Doctor SM, Liu Y, Anderson OG, Whitesell AN, Mwandagilirwa MK, Muwonga J, et al. Low prevalence of *Plasmodium malariae* and *Plasmodium ovale* mono-infections among children in the Democratic Republic of the Congo: a population-based, cross-sectional study. *Malar J* 2016;15(1):350.  
[PUBMED](#) | [CROSSREF](#)
9. Menner N, Borchert M, Dieckmann S, Ignatius R, Mockenhaupt FP. Uncommon manifestation of a mixed-species malaria infection: cryptic falciparum malaria in a traveler with successfully treated tertian malaria. *J Travel Med* 2012;19(2):133-5.  
[PUBMED](#) | [CROSSREF](#)
10. Jeong AC, Ahn BJ, Choi CK, Yoon KS, Nam HW, Lee WJ, et al. A case of mixed malarial infection with *Plasmodium falciparum* and *Plasmodium vivax*. *Korean J Infect Dis* 1998;30(2):194-7.
11. Kim JM, Yoo TH, Park CJ, Chi HS. A mixed cerebral infection of vivax and falciparum malaria. *Korean J Clin Pathol* 2000;20(3):263-7.
12. Shin KS, Kim JS, Ryu SW, Suh IB, Lim CS. A case of *Plasmodium vivax* infection diagnosed after treatment of imported falciparum malaria. *Korean J Clin Pathol* 2001;21(5):360-4.
13. Shin SY, Yu JH, Kim JY, Kim YJ, Woo HY, Kwon MJ, et al. A case of mixed malaria infection with severe hemolytic anemia after travel to Angola. *Infect Chemother* 2012;44(5):386-90.  
[CROSSREF](#)
14. Collins WE, Jeffery GM. *Plasmodium ovale*: parasite and disease. *Clin Microbiol Rev* 2005;18(3):570-81.  
[PUBMED](#) | [CROSSREF](#)
15. Tanga MC, Ngundu WI, Tchouassi PD. Daily survival and human blood index of major malaria vectors associated with oil palm cultivation in Cameroon and their role in malaria transmission. *Trop Med Int Health* 2011;16(4):447-57.  
[PUBMED](#) | [CROSSREF](#)
16. Mehlotra RK, Lorry K, Kastens W, Miller SM, Alpers MP, Bockarie M, et al. Random distribution of mixed species malaria infections in Papua New Guinea. *Am J Trop Med Hyg* 2000;62(2):225-31.  
[PUBMED](#) | [CROSSREF](#)
17. Bigaillon C, Fontan E, Cavallo JD, Hernandez E, Spiegel A. Ineffectiveness of the Binax NOW malaria test for diagnosis of *Plasmodium ovale* malaria. *J Clin Microbiol* 2005;43(2):1011.  
[PUBMED](#) | [CROSSREF](#)
18. Roucher C, Rogier C, Sokhna C, Tall A, Trape JF. A 20-year longitudinal study of *Plasmodium ovale* and *Plasmodium malariae* prevalence and morbidity in a West African population. *PLoS One* 2014;9(2):e87169.  
[PUBMED](#) | [CROSSREF](#)
19. Khairnar K, Martin D, Lau R, Ralevski F, Pillai DR. Multiplex real-time quantitative PCR, microscopy and rapid diagnostic immuno-chromatographic tests for the detection of *Plasmodium* spp: performance, limit of detection analysis and quality assurance. *Malar J* 2009;8(1):284.  
[PUBMED](#) | [CROSSREF](#)
20. Okell LC, Ghani AC, Lyons E, Drakeley CJ. Submicroscopic infection in *Plasmodium falciparum*-endemic populations: a systematic review and meta-analysis. *J Infect Dis* 2009;200(10):1509-17.  
[PUBMED](#) | [CROSSREF](#)