

Balloon atrial septostomy as initial therapy in pediatric pulmonary hypertension

Paul J. Critser¹, Patrick D. Evers², Eimear McGovern³, Michelle Cash¹ and Russel Hirsch^{1,4}

¹Heart Institute, Cincinnati Children's Hospital Medical Center, Cincinnati, OH, USA; ²Division of Pediatric Cardiology, Oregon Health and Science University, Portland, OR, USA; ³Division of Pediatric Cardiology, University of Kentucky College of Medicine, Lexington, KY, USA; ⁴Department of Pediatrics, University of Cincinnati College of Medicine, Cincinnati, OH, USA

Abstract

Balloon atrial septostomy is a palliative procedure currently used to bridge medically refractory pulmonary hypertension patients to lung transplantation. In the current report, we present balloon atrial septostomy as an initial therapy for high-risk pediatric pulmonary hypertension patients at our institution. Nineteen patients with median age of 4.3 years (range 0.1–14.3 years) underwent balloon atrial septostomy during initial admission for pulmonary hypertension. There were no procedural complications or deaths within 24 h of balloon atrial septostomy. Patients were followed for a median of 2.6 years (interquartile range 1.0–4.8 years). Three (16%) patients died, 3 (16%) underwent lung transplantation, and 1 (5%) underwent reverse Potts shunt. Transplant-free survival at 30 days, 1 year, and 3 years was 84%, 76%, and 67% respectively. This single-center experience suggests early-BAS in addition to pharmacotherapy is safe and warrants consideration in high-risk pediatric pulmonary hypertension patients.

Keywords

Pulmonary hypertension, balloon atrial septostomy, pediatrics

Date received: 25 June 2020; accepted: 8 August 2020

Pulmonary Circulation 2020; 10(4) 1–3

DOI: 10.1177/2045894020958970

Introduction

Survival of pediatric pulmonary hypertension (PH) patients has improved over the last two decades due to new therapeutic agents. However, pediatric PH remains a progressive disease with poor prognosis. For patients who fail to respond to medical therapy, current guidelines recommend balloon atrial septostomy (BAS) or reverse Potts shunt as a bridge to lung transplantation.¹

By providing an atrial level shunt, BAS may improve left ventricular preload and cardiac output at the expense of decreased systemic saturation. BAS has been associated with improved survival in adult patients with PH.² Two reports have described BAS in pediatric PH, demonstrating an association with symptomatic improvement.^{3,4} However, the appropriate timing of BAS remains unclear as severe right ventricular (RV) failure or end stage disease are relative contraindications.¹

In the current report, we present our institutional experience with BAS as an initial therapy for high-risk pediatric PH.

Cases

Between 1 January 2011 and 31 December 2019, BAS was performed during initial admission for PH in 19 patients. Eleven patients (52%) were female. The median age at procedure was 4.3 years (range 0.1–14.3 years). Eleven patients (58%) had idiopathic pulmonary arterial hypertension, 5 (26%) had PH associated with congenital heart disease, 2 (10%) had PH after bone marrow transplant, and 1 (5%) had hereditary hemorrhagic telangiectasia. Indications for BAS included history of syncope, PH crisis, or evidence of RV failure.

Preceding the BAS, 18 (95%) patients were admitted to an intensive care unit, 13 (68%) patients were on inotropes, and 6 (32%) patients were treated with inhaled nitric oxide.

Corresponding author:

Russel Hirsch, Cincinnati Children's Hospital, 3333 Burnet Avenue, ML 5033, Cincinnati, OH 45229, USA.

Email: russel.hirsch@cchmc.org



Creative Commons Non Commercial CC BY-NC: This article is distributed under the terms of the Creative Commons Attribution-NonCommercial 4.0 License (<http://creativecommons.org/licenses/by-nc/4.0/>) which permits non-commercial use, reproduction and distribution of the work without further permission provided the original work is attributed as specified on the SAGE and Open Access pages (<https://us.sagepub.com/en-us/nam/open-access-at-sage>).

© The Author(s) 2020.
Article reuse guidelines:
sagepub.com/journals-permissions
journals.sagepub.com/home/pul



Eleven (58%) patients received pulmonary vasodilator therapy with 5 (26%) receiving monotherapy, 4 (21%) receiving dual therapy, and 2 (11%) receiving triple therapy. Eleven (58%) patients received phosphodiesterase-5 inhibitors, 4 (21%) patients received an endothelin receptor antagonist, and 4 (21%) patients received prostanoid therapy. Five (24%) had history of syncope, 3 (16%) had experienced a PH crisis, and 11 (58%) had echocardiographic evidence of RV failure.

Fifteen patients underwent BAS at the time of initial cardiac catheterization. The remaining four patients underwent BAS at two, four, six, and eight days after initial cardiac catheterization. At the time of BAS, the median cardiac index was 3.1 L/min/m² (interquartile range (IQR) 2.5–4.3), mean pulmonary artery pressure was 58 mmHg (IQR 49–72), pulmonary vascular resistance was 16.9 iWU (IQR 10.4–22.5), mean right atrial pressure (mRAP) was 8 mmHg (IQR 6–13), mean systemic arterial oxygen saturation 96% (IQR 95–96). There were no procedural complications or deaths within 24 h of BAS. Eleven patients received anticoagulation after BAS including aspirin in five, enoxaparin in one, clopidogrel in one, and warfarin in five patients.

Patients were followed for a median of 2.6 years (IQR 1.0–4.8 years). Three patients required a repeat BAS. At most recent follow-up, 14 (74%) had patent atrial level shunt. Of the five patients with intact atrial septum, two had atrial septal defect closure at time of lung transplant, and three had spontaneous closure at 9, 10, and 15 months after BAS.

Three (16%) patients died, 3 (16%) underwent lung transplantation, and 1 (5%) underwent reverse Potts shunt. The three patient deaths were within 30 days of the procedure and were admitted to the intensive care unit prior to BAS. One patient died from sepsis and two patients died from a PH crisis. There were no deaths in patients who survived to hospital discharge after BAS.

Three (16%) patients underwent lung transplantation at 7 months, 1 year, and 2 years after BAS and all are alive with post-transplant follow-up of 3.5, 4, and 4 years. Transplant-free survival at 30 days, 1 year, and 3 years was 84%, 76%, and 67% respectively (Fig. 1).

Of the 13 patients with transplant-free survival, at most recent follow-up, 3 (23%) were on no pulmonary vasodilator therapy, 3 (23%) on monotherapy, 4 (30%) on dual therapy, and 3 (23%) on triple therapy. Ten (77%) patients were treated with phosphodiesterase-5 inhibitors, 7 (54%) with an endothelin receptor antagonist, and 5 (38%) with prostanoid therapy.

Discussion

Current pediatric practice guidelines advocate the use of BAS as a deferred therapy, reserved for those with severe disease—characterized by RV failure, PH crises, functional class decline, or syncope—refractory to medical therapy.^{1,5,6} There have been two recent descriptions of this

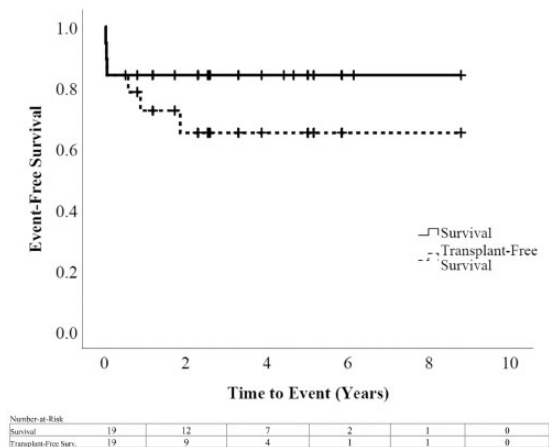


Fig. 1. Kaplan–Meier survival characteristics illustrating cohort’s overall survival and transplant-free survival.

deferred-BAS strategy in pediatric PH, both of which illustrate improved hemodynamics, functional outcomes, and low procedural risk in cohorts of significantly ill children.^{3,4}

However, there is a conceptual benefit of earlier BAS in the care of these children, as opposed to those with medically refractory disease. The era prior to the advent of modern pharmacotherapy provides insight into the hemodynamic and clinical impact of atrial communications, absent the confounding effects of concurrent pulmonary vasodilators in the modern experience. An initially observed survival advantage in adults with idiopathic PAH who had a patent foramen ovale led to several septostomy trials in adults with severe disease illustrating improvements in symptoms, cardiac output, right atrial pressure, oxygen delivery, and survival.^{7–10} More recently, Sandoval et al. provided a description of the hemodynamic improvements in 34 adult PH patients who were naïve to pulmonary vasodilator therapy.² In this study, early-BAS led to improvements in hemodynamic parameters correlated with survival after septostomy as well as further improved survival amongst those receiving early-BAS and subsequent pharmacotherapy over those receiving early-BAS alone.

In the enclosed single-center case-series, the outcomes of an early-BAS approach in pediatrics are described. This series demonstrates the safety of early-BAS in pediatrics: we illustrate no procedural complications nor deaths within 24 h of the procedure. Across the follow-up period, our absolute survival and transplant-free survival are comparable to the previously reported modern experience from other centers (Fig. 1). These outcomes are despite several patients meeting criteria for relative contraindications for BAS.^{1,10} Three (16%) had a mRAP > 20 mmHg, the highest being 33 mmHg falling to 13 mmHg after BAS. Four (21%) patients had RV cardiac output ≤ 2.5 L·min·m⁻² with the lowest being 0.85 L·min·m⁻². The only death from a PH crisis was in a patient who met both criteria, 10 days following BAS. While this complex and high-risk population demands individualized care, this single-center experience

supports consideration of early-BAS in addition to initiation of aggressive pharmacotherapy in patients with high-risk characteristics.

Author contributions

Paul Critser, Patrick Evers, and Russel Hirsch contributed to the experimental design, data analysis, drafting, and revision of the work. Eimear McGovern and Michelle Cash contributed to the experimental design, data analysis, and revision of the work.

Conflict of interest

The authors declare that there are no conflicts of interest.

Ethical approval

The institutional review board at Cincinnati Children's Hospital approved this study and waived the requirement of formal consent for this retrospective study.

Funding

This research received no specific grant from any funding agency in the public, commercial, or not-for-profit sectors.

References

- Rosenzweig EB, Abman SH, Adatia I, et al. Paediatric pulmonary arterial hypertension: updates on definition, classification, diagnostics and management. *Eur Respir J* 2019; 53: 1801916.
- Sandoval J, Gaspar J, Pena H, et al. Effect of atrial septostomy on the survival of patients with severe pulmonary arterial hypertension. *Eur Respir J* 2011; 38: 1343–1348.
- Micheletti A, Hislop AA, Lammers A, et al. Role of atrial septostomy in the treatment of children with pulmonary arterial hypertension. *Heart* 2006; 92: 969–972.
- Chiu JS, Zuckerman WA, Turner ME, et al. Balloon atrial septostomy in pulmonary arterial hypertension: effect on survival and associated outcomes. *J Heart Lung Transplant* 2015; 34: 376–380.
- Abman SH, Hansmann G, Archer SL, et al. Pediatric pulmonary hypertension: guidelines from the American Heart Association and American Thoracic Society. *Circulation* 2015; 132: 2037–2099.
- Hansmann G, Koestenberger M, Alastalo TP, et al. 2019 updated consensus statement on the diagnosis and treatment of pediatric pulmonary hypertension: the European Pediatric Pulmonary Vascular Disease Network (EPPVDN), endorsed by AEPC, ESPR and ISHLT. *J Heart Lung Transplant* 2019; 38: 879–901.
- Rozkovec A, Montanes P and Oakley CM. Factors that influence the outcome of primary pulmonary hypertension. *Br Heart J* 1986; 55: 449–458.
- Nihill MR, O'Laughlin MP and Mullins CE. Effects of atrial septostomy in patients with terminal cor pulmonale due to pulmonary vascular disease. *Cathet Cardiovasc Diagn* 1991; 24: 166–172.
- Kerstein D, Levy PS, Hsu DT, et al. Blade balloon atrial septostomy in patients with severe primary pulmonary hypertension. *Circulation* 1995; 91: 2028–2035.
- Rich S, Dodin E and McLaughlin VV. Usefulness of atrial septostomy as a treatment for primary pulmonary hypertension and guidelines for its application. *Am J Cardiol* 1997; 80: 369–371.