



Original Article

Clinical and pathologic features related to the impacted third molars in patients of different ages: A retrospective study in the Korean population



Ji-Youn Kim ^a, Hyeon-Gun Jee ^b, Hyun Chul Song ^a,
Sun-Jong Kim ^{c,d}, Myung-Rae Kim ^{c*}

^a Division of Oral & Maxillofacial Surgery, Department of Dentistry, College of Medicine, St. Vincent's Hospital, The Catholic University of Korea, Suwon, South Korea

^b Cancer Research Institute, Seoul National University College of Medicine, Seoul, South Korea

^c Graduate School of Clinical Implant Dentistry, Ewha Womans University, Seoul, South Korea

^d Department of Oral & Maxillofacial Surgery, Ewha Womans University Medical Center, Seoul, South Korea

Received 8 August 2016; Final revision received 16 January 2017

Available online 13 June 2017

KEYWORDS

impacted third molar;
extraction;
prophylactic removal;
dental caries;
periodontal disease

Abstract *Background/purpose:* The surgical extraction of impacted third molars (ITMs) is a common surgical procedure in dentistry. If prophylactic removal of ITMs is beneficial, however, is a still disputed issue. The aim of this study was to analysis the pathologic changes in impacted third molars (ITMs) and adjacent teeth according to patient age groups in the Korean population to determine if the prophylactic removal of ITMs is to be supported or not.

Materials and methods: A retrospective study of patients who underwent surgical extraction of impacted third molars was performed. The patients were divided into 5 groups according to their age. Each group was analyzed with respect to patients' chief complaints, specific pathologic conditions in ITMs, and the damage to adjacent teeth due to untreated ITMs.

Results: In this study, 2883 impacted third molars in 1109 patients were analyzed. The most common patients' chief complaint was pain, and the frequency of pain was significantly higher in older age groups. The frequency and severity of pathologic changes in ITMs and adjacent second molars due to ITMs were increased with advancing age.

* Corresponding author. Graduate School of Clinical Implant Dentistry, Ewha Womans University 1071 Anyangcheon-ro, Yangcheon-gu, Seoul, 07985, South Korea. Fax: +82 2 2650 2754.

E-mail address: Myungrae48@gmail.com (M.-R. Kim).

Conclusion: Based on the results of this study, we conclude that the prophylactic removal of ITMs that have a higher probability of pathologic changes can be considered to be a reasonable treatment modality in younger patients to reduce morbidity resulting from surgical extraction compared with patients who attained advanced age.

© 2017 Association for Dental Sciences of the Republic of China. Publishing services by Elsevier B.V. This is an open access article under the CC BY-NC-ND license (<http://creativecommons.org/licenses/by-nc-nd/4.0/>).

Introduction

Impacted third molars (ITMs) are one of the most common developmental conditions that affect humans.¹ The surgical extraction of ITMs is one of the most common surgical procedures performed worldwide by the oral and maxillofacial surgeons.^{1–3}

The ITMs are divided into “asymptomatic” or “disease-free” ITMs and “symptomatic” or “diseased” ITMs. It is reasonable to perform surgical extraction of the diseased or symptomatic ITMs for resolving the pain and symptoms of patients.⁴ But, there have been controversies about the prophylactic surgical removal of asymptomatic ITMs in younger patients.⁵ An unknown percentage of ITMs may remain asymptomatic throughout life.^{2,6} On the other hand, they have the potential to induce pathologic changes, including pericoronitis, periodontal disease, caries of ITMs, caries or resorption of the adjacent second molar, or the presence of cysts or tumors.² However, there have been very few studies comparing the prophylactic removal of ITMs with retention of ITMs and yet insufficient evidence was found to support or refute the prophylactic removal of ITMs in young adults, especially in the Asian population.⁷ This cross-sectional study utilizes clinical information of 1109 patients who visited a hospital for surgical removal of ITM in the Korean population living in South Korea. To determine if the prophylactic removal of ITMs is to be supported or not, the type and frequency of patients’ symptoms, indications for pathologic conditions associated with ITMs, damage to the adjacent second molars and their treatment were analyzed according to patient age groups.

Materials and methods

The records of all patients who underwent surgical removal of ITMs at the Department of Oral and Maxillofacial Surgery, Mokdong Hospital, Ewha Womans University during a 1-year period (from March 1st, 2011 to February 29th, 2012) were retrieved, reviewed, and analyzed. The inclusion criteria for ITMs in this study were 1) ITMs whose pre-operative panoramic radiographs were taken, 2) ITMs were either fully covered with bone or partially erupted, but prevented from reaching the occlusal plane, 3) The patients’ chief complaints and clinical examination descriptions were written clearly in the first dental examination records. Patients in whom the third molars had fully erupted to the level of the occlusal plane were excluded from the study.

The patients and their ITMs were divided into five groups according to patient age. And the groups were analyzed according to the following categories:

- 1) The patients’ chief complaints
- 2) The surgeons’ purpose of surgical extraction of ITMs
- 3) The specific pathologic conditions for therapeutic removal were assessed.
- 4) The damage to adjacent second molars due to untreated ITMs

This retrospective study was performed by means of a review of clinical records and pre-operative panoramic radiographs. The study was reviewed and approved by the Institutional Review Board of Ewha Womans University Mokdong Hospital (IRB approval number: ECT 13-04-09). Statistical analysis of the data was performed with IBM® SPSS® Statistics version 21.0 (SPSS, Chicago, IL, USA) at the 5% level of significance. The Pearson’s chi-square (χ^2) test was applied for the comparison of each groups’ variables.

Results

Total patients and ITMs

The total number of patients included in this study was 1109, and the male: female ratio was 1:1.06. The average age of total patients was 29.0 ± 10.2 years (range, 13–74 years). The total number of observed ITMs in this study was 2883. The total number of surgically removed ITMs was 2792 among the total 2883 ITMs. The patients and their ITMs were divided into five groups according to patient age. Group 1 (G1) included the patients whose age was less than 20 years. Group 2 (G2) 21 to 25, Group 3 (G3) 26 to 30, Group 4 (G4) 31 to 40, and Group 5 (G5) 41 years and older (Table 1).

Table 1 Composition of patient groups.

Group	Age (years)	Number of patients				M:F ratio	Average age \pm SD (years)
		Total	Male	Female			
G1	Less than 20 (13–20)	206	95	111	1:1.17	18.7 ± 1.5	
G2	21–25	320	148	172	1:1.16	22.9 ± 1.3	
G3	26–30	224	105	119	1:1.13	28.1 ± 1.5	
G4	31–40	213	108	105	1:0.97	34.8 ± 2.9	
G5	More than 41 (41–74)	146	83	63	1:0.76	49.5 ± 7.4	

SD = standard deviation; G1 = group 1; G2 = group 2; G3 = group 3; G4 = group 4; G5 = group 5.

Chief complaints of patients

The chief complaints of 1109 patients at their visit to the clinic were analyzed. The major chief complaint of patients was pain in ITMs. The average age (32.9 ± 11.3 yrs) of patients with this chief complaint was highest among all of the patients with other chief complaints. In G1, the major chief complaint was prophylactic removal for other dental treatment, especially orthodontic treatment. In G2 and G3, the major chief complaint was discomfort. However, in G4 and G5, the major chief complaint was pain. The difference in distribution of chief complaints among groups was statistically significant ($P < 0.0001$, Table 2). The surgeons' purpose of surgical extraction of the ITMs (prophylaxis or treatment)

In this analysis, the cases were limited to the 1109 chief complaints due to ITMs among 1109 patients. The other ITMs that did not cause chief complaints in 1109 patients were excluded. The average age of prophylactic removal patient was 24.0 ± 5.5 years. The average age of therapeutic removal patients was 32.7 ± 11.2 years. In a more older age group, the number of cases that underwent therapeutic removal was higher than the number of cases that underwent prophylactic removal. The difference in distribution of surgeons' purpose among groups was statistically significant ($P < 0.0001$, Table 3).

Specific pathologic conditions for therapeutic removal

This part of the study included 748 ITMs in 630 patients who underwent therapeutic removal. When more than one pathologic condition was noted in a single ITM, that particular ITM was all included in the respective each categories. One pathologic condition for therapeutic removal was reported in 657 ITMs, 2 pathologic conditions for therapeutic removal were reported in 83 ITMs, and 3 pathologic conditions for therapeutic removal were reported in 10 ITMs, resulting in a total of 853 cases with pathologic conditions in 748 ITMs. Thus, in this part of the study, 853 cases with pathologic conditions were subjected to analysis. The most common pathologic condition was pericoronitis.

In all groups, the most common pathologic condition was pericoronitis. But, the second most common pathologic condition in G1, G2, and G3 was follicular space widening or dental caries of ITMs. However, the second most common pathologic condition in G4 and G5 was dental caries or root

resorption of adjacent teeth due to ITMs or infection. The difference in distribution of specific pathologic conditions for therapeutic removal among groups was statistically significant ($P < 0.0001$, Table 4).

The damage to adjacent teeth (second molars) due to untreated ITMs

This part of the study included 748 ITMs in 630 patients who underwent therapeutic removal. In this category, all adjacent teeth showing pathologic changes due to untreated ITMs were included as well as those with dental caries or root resorption (Fig. 1). Thus, 199 cases of ITMs (199/748, 26.6%) were subjected to analysis. The most commonly observed damage to adjacent teeth due to untreated ITMs was distal bone loss over apical third of the adjacent teeth (81/748 (10.8%), average age: 46.8 ± 8.1 yrs).

There were less than 10% of damaged adjacent teeth in cases that underwent therapeutic removal in G1, G2, and G3. However, there were 32.4% (61/188 cases) and 68.1% (109/160 cases) of damaged adjacent teeth in cases that underwent therapeutic removal in G4 and G5. The difference in distribution of the specific damage to adjacent teeth among groups was statistically significant ($P < 0.0001$, Table 5).

Discussion

Many dental clinicians have difficulty in deciding whether an asymptomatic or disease-free ITMs should be removed in young adult patients.² Some authorities have strong opinions that prophylactic surgery is not an appropriate treatment for asymptomatic ITMs.^{2,7-9} The National Institute of Excellence (NICE) guidelines in 2000 for guidance on the extraction of wisdom teeth are representative.¹⁰ However, other authorities or dental clinicians have a strong opinion that if ITMs are removed only after the occurrence of pathologic changes, the patients may have attained advanced age and therefore they may have a very significant risk of serious complications on comparison with prophylactic removal of ITMs in young adult patients.^{2,11,12} In other words, prophylactic removal of ITMs in young adult patients is an appropriate treatment in order to avoid future pathologic conditions and complications associated with ITMs.^{7,13} This study was to determine if the prophylactic removal of ITMs is to be supported or not, to analyze and compare the patients' symptoms, pathologic conditions associated with ITMs, and damage to the adjacent second

Table 2 Chief complaints of patients.

Chief complaints	Total	Average age \pm SD (years)	G1	G2	G3	G4	G5	P
Prophylactic removal without any reason	161	24.2 ± 6.05	49	61	33	13	5	$<0.0001^*$
Prophylactic removal for other dental treatment	147	22.5 ± 5.60	72	39	24	10	2	
Discomfort	356	28.9 ± 8.57	35	123	87	80	31	
Pain	396	32.9 ± 11.3	41	83	75	104	93	
Accidental detection of ITMs pathologic condition	49	32.7 ± 14.6	9	14	5	6	15	

SD = standard deviation; G1 = group 1; G2 = group 2; G3 = group 3; G4 = group 4; G5 = group 5.

*Pearson's chi-square test = 251.111.

Table 3 The surgeons' purpose of surgical extraction of the ITMs.

Purpose of extraction	Total	Average age \pm SD (years)	G1	G2	G3	G4	G5	P
Prophylactic removal	479	24.0 \pm 5.50	147	175	108	41	8	<0.0001*
Therapeutic removal	630	32.7 \pm 11.2	59	145	116	172	138	

SD = standard deviation; G1 = group 1; G2 = group 2; G3 = group 3; G4 = group 4; G5 = group 5.

*Pearson's chi-square test = 165.925.

Table 4 Specific pathologic conditions for therapeutic removal.

Pathologic conditions	Total	Average age \pm SD (years)	G1	G2	G3	G4	G5	P
Pericoronitis	468	32.4 \pm 10.7	49	114	75	129	101	<0.0001*
Dental caries of ITMs	127	30.2 \pm 7.4	2	40	34	39	12	
Dental caries or root resorption of adjacent teeth	102	37.6 \pm 10.9	1	14	13	42	32	
Infection	81	36.6 \pm 13.7	7	13	14	15	32	
Follicular space widening	39	19.7 \pm 8.2	32	4	1	0	2	
Dentigerous cyst	30	40.2 \pm 15.7	2	6	4	4	14	
Ulceration	6	25.5 \pm 3.7	0	4	2	0	0	

SD = standard deviation; G1 = group 1; G2 = group 2; G3 = group 3; G4 = group 4; G5 = group 5.

*Pearson's chi-square test = 297.205.

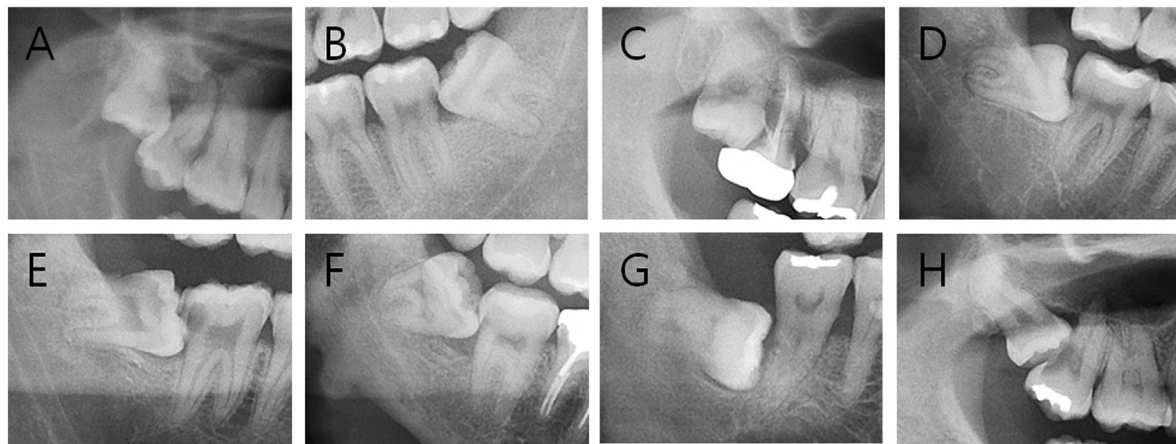


Figure 1 The radiographic features of damage types to adjacent teeth (second molars) due to untreated ITMs. All figures were cropped from the patients' panoramic radiographs. (A) Distal bone loss. (B) Dental caries that needed conservative treatment without the need for endodontic treatment or extraction. (C) Extraction of adjacent second molars. (D) Caries without treatment. (E) Endodontic treatment due to severe dental caries or apical involvement of cystic lesions in ITMs. (F) Distal bone loss with dental caries treatment (A+B). (G) Distal bone loss with dental caries, however, without the need for conservative treatment (A+D). (H) Distal bone loss with endodontic treatment (A+E).

molars and their treatments according to patient age groups.

In this study, the average age of the patients who underwent surgical removal of ITMs was 29.0 ± 10.2 years (range, 13–74 years). The average age of the patients was lesser than the average age (31.8 years in 2010) of the patients in United Kingdom after introduction of the NICE guideline that prevents prophylactic removal of ITMs.^{1,10,14} Mandibular ITMs were more commonly found in the patients' mouths and were surgically removed than maxillary ITMs, as in other studies.¹

"Pain" was the most common patients' chief complaint in this study followed by discomfort. In the twenties, the

most common chief complaint was "discomfort", and in the patients aged more than 31 years, the most common chief complaint was "pain". This means that as the age advanced, patients decided to visit the dental clinic and decided to undergo surgical removal of ITMs due to aggravation of symptoms and pain.

The average age of patients who underwent prophylactic surgical extraction of ITMs was about 8 years lesser than that of patients who underwent therapeutic surgical extraction in this study. In the patients younger than 25 years, most of the ITMs were removed for prophylaxis without pathologic changes. But, in the patients older than 31 years, most of the ITMs were removed for therapeutic

Table 5 The damage to adjacent teeth (second molars) due to untreated ITMs.

The damage to second molars	Total	Average age \pm SD (years)	G1	G2	G3	G4	G5	P
A. Distal bone loss	81	46.8 \pm 8.1	1	0	0	18	62	<0.0001*
B. Dental caries with treatment	42	37.1 \pm 11.4	1	6	4	21	10	
C. Extraction	24	47.0 \pm 12.7	0	2	2	2	18	
D. Caries without treatment	19	31.4 \pm 6.8	0	3	7	7	2	
E. Endodontic treatment	18	39.9 \pm 14.4	0	3	0	10	5	
F. (A + B)	9	48.7 \pm 8.4	0	0	0	2	7	
G. (A + D)	3	42.3 \pm 6.4	0	0	0	1	2	
H. (A + E)	3	53.3 \pm 9.5	0	0	0	0	3	

SD = standard deviation; G1 = group 1; G2 = group 2; G3 = group 3; G4 = group 4; G5 = group 5; A + B = distal bone loss with dental caries treatment; A + D = distal bone loss with dental caries, however, without conservative treatment; A + E = distal bone loss with endodontic treatment.

*Pearson's chi-square test = 290.606.

purpose with pathologic changes. When the patients experienced "discomfort", there was no pathologic change and often only food impaction occurred, especially in young patients. These ITMs may be in the "symptomatic and absence of disease" state.¹⁵ According to the NICE guideline, these ITMs should not be considered an indication for surgical removal.¹⁰ But, there is a need for discussion that really improves the patients' quality of life with the possibility of recurrent persisting discomfort or development of pain at an advanced age.

Acute/chronic or recurrent pericoronitis with/without periodontitis of adjacent teeth (54.9%) was the most common pathologic condition, and dental caries of ITMs (14.9%) was the second most common pathologic condition in this study. The trend for pathologic conditions was similar with that in other reported studies.^{2,3,16-21} In the other previously reported studies, dental caries of ITMs developed relatively slowly compared with pericoronitis, and as a consequence dental caries develops at older age in patients.^{1,22,23} However, the average age of patients with pericoronitis (32.4 \pm 10.7 years) was more than that of patients with dental caries of ITMs (30.2 \pm 7.4 years) in our study. The reason for this could be that periodontitis of adjacent second molars due to chronic pericoronitis of ITMs was included into "pericoronitis" pathologic condition in our study.

Dental caries of adjacent second molars is a significant late complication of ITMs, because it is often diagnosed late, sometimes resulting in second molar extraction.^{14,24} The previously reported incidences ranged from 7.9% to 17.2%, which are similar to that in our study (12.0%).^{3,25,26} In another study reported in U.K. in 2009, the incidence (19.3%) was higher than that in our study and other studies.²⁷ The introduction of the NICE guideline might be the cause of the higher incidence.¹ The reported incidence might increase more when patients become older, and the mean age of patients with dental carious second molars was significantly higher (about 5 years older) than that of patients without dental carious second molars, which is also similar to our results (average age: 37.6 \pm 10.9 years).^{22,23,26}

Also, the pathologic condition of infection that needed antibiotics or surgical incision and drainage of the abscess, and admission to the hospital are markedly increased in significantly older patients.

The pathological abnormal widening of the pericoronal follicle of ITMs is associated with a high incidence of dentigerous cyst.^{28,29} The patients older than 20 years showed a higher incidence of pathologic changes.^{30,31} In our study, the average age of patients with follicular space widening was 19.7 \pm 8.2 years, and the average age of patients with dentigerous cyst was 40.2 \pm 15.7 years. The results also showed that abnormal follicular space widening can cause pathologic cystic changes over time. But, all cases of follicular space widening do not develop cysts, as noted in two patients aged 52-years-old and 54-years-old who had follicular space widening in ITMs.

The 199 ITMs (26.6%) among total 748 ITMs in 630 patients were removed for therapeutic purpose because pathologic changes were accompanied by damage to adjacent second molars due to untreated ITMs in our study. Also, the incidence was markedly increased in older patients. The incidence of adjacent second molars showing pathologic changes due to untreated ITMs was only 2.2% in the under 20 year age group, 7.9% in patients in their early twenties, 10.0% in patients in their late twenties. However, the incidence increased to 32.4% in patients in their thirties and it was further increased to 68.1% in the above 41 years age group. This means that 7 out of the 10 ITMs developed pathologic changes and concerned the treatment of adjacent second molars was concomitantly needed in the patients above 41 years of age. Also, the most common indications of damage to adjacent second molars was dental caries with conservative treatment or only observation in patients less than 30 years of age, while distal bone loss of the adjacent second molar was commonly observed in the patients above 41 years of age. When the cases with distal bone loss with dental caries treatment or endodontic treatment and complex lesion were included, distal bone loss over apical third occurred in more than half of ITMs showing pathologic changes in patients aged more than 41 years. Marciani³² also reported that periodontal pathology was associated with asymptomatic third molars retained in the mouth. The clinical and microbial changes associated with the initiation of periodontitis may present first in the third molar region in young adults, and the presence of third molars in young adults was significantly associated with periodontal inflammatory disease of non-third molars.³² This means that the periodontal disease

may be associated with ITMs in young adult patients, even in asymptomatic ITMs. The periodontal disease state in all teeth as well as adjacent second molars gradually worsens in elderly patients. Also, the cases of extraction of second molars due to untreated ITMs showing pathologic changes were more in patients aged above 41 years than in patients less than 40 years of age. Interestingly, the average age of damage to the adjacent second molar was increased in accordance with the severity of damage. The average age increased in the order of dental caries only observation, dental caries with conservative treatment, endodontic treatment, and extraction. In other words, ITMs showing pathologic changes cause irreversible and severe damage to the adjacent second molars in relatively older patients.

In conclusion, "asymptomatic" does not necessarily mean "disease free" or "no possibility of developing pathologic changes".³² This study showed that prophylactic removal of ITMs that have a possibility of developing pathologic changes in the late teenage and early twenties reduces the chances of developing pathologic changes in ITMs, adjacent tissues, and second molars, and improves patients' dental health and future quality of life. Hence, prospective and retrospective studies are needed for more accurate prediction of possibility of pathologic changes in ITMs.

Conflicts of interest

The authors have no conflicts of interest relevant to this article.

References

- McArdle LW, Renton T. The effects of NICE guidelines on the management of third molar teeth. *Br Dent J* 2012;213: E8.
- Bataineh AB, Albashaireh ZS, Hazza'a AM. The surgical removal of mandibular third molars: a study in decision making. *Quintessence Int* 2002;33:613–7.
- Krishnan B, Sheikh MH, Rafa el G, Orafi H. Indications for removal of impacted mandibular third molars: a single institutional experience in Libya. *J Maxillofac Oral Surg* 2009;8:246–8.
- Phillips C, Norman J, Jaskolka M, et al. Changes over time in position and periodontal probing status of retained third molars. *J Oral Maxillofac Surg* 2007;65:2011–7.
- Knutsson K, Lysell L, Rohlin M, Brickley M, Shepherd JP. Comparison of decisions regarding prophylactic removal of mandibular third molars in Sweden and Wales. *Br Dent J* 2001;190:198–202.
- Lopes V, Mumenya R, Feinmann C, Harris M. Third molar surgery: an audit of the indications for surgery, post-operative complaints and patient satisfaction. *Br J Oral Maxillofac Surg* 1995;33:33–5.
- Mettes TD, Ghaemina H, Nienhuijs ME, Perry J, van der Sanden WJ, Plasschaert A. Surgical removal versus retention for the management of asymptomatic impacted wisdom teeth. *Cochrane Database Syst Rev* 2012;6, CD003879.
- Chuang SK, Perrott DH, Susarla SM, Dodson TB. Age as a risk factor for third molar surgery complications. *J Oral Maxillofac Surg* 2007;65:1685–92.
- Mercier P, Precious D. Risks and benefits of removal of impacted third molars. A critical review of the literature. *Int J Oral Maxillofac Surg* 1992;21:17–27.
- National Institute for Clinical Excellence. *Guidance on the extraction of wisdom teeth*. Spiring Gardens. London: NICE; 2000. Available at: <https://www.nice.org.uk/guidance/ta1> [Date accessed: November 20, 2015].
- Stavisky E. Clinical justification for the prophylactic removal of impacted third molars. *Pa Dent J (Harrisb)* 1989;56:8–9.
- Tate TE. Impactions: observe or treat? *J Calif Dent Assoc* 1994;22:59–64.
- Kandasamy S, Rinchuse DJ. The wisdom behind third molar extractions. *Aust Dent J* 2009;54:284–92.
- Renton T, Al-Haboubi M, Pau A, Shepherd J, Gallagher JE. What has been the United Kingdom's experience with retention of third molars? *J Oral Maxillofac Surg* 2012;70:548–57.
- Dodson TB. How many patients have third molars and how many have one or more asymptomatic, disease-free third molars? *J Oral Maxillofac Surg* 2012;70:S4–7.
- Hill CM, Walker RV. Conservative, non-surgical management of patients presenting with impacted lower third molars: a 5-year study. *Br J Oral Maxillofac Surg* 2006;44:347–50.
- Knutsson K, Brehmer B, Lysell L, Rohlin M. Pathoses associated with mandibular third molars subjected to removal. *Oral Surg Oral Med Oral Pathol Oral Radiol Endod* 1996;82:10–7.
- Lysell L, Rohlin M. A study of indications used for removal of the mandibular third molar. *Int J Oral Maxillofac Surg* 1988;17:161–4.
- Punwutikorn J, Waikakul A, Ochareon P. Symptoms of unerupted mandibular third molars. *Oral Surg Oral Med Oral Pathol Oral Radiol Endod* 1999;87:305–10.
- Samsudin AR, Mason DA. Symptoms from impacted wisdom teeth. *Br J Oral Maxillofac Surg* 1994;32:380–3.
- Stathopoulos P, Mezitis M, Kappatos C, Titsinides S, Stylogianni E. Cysts and tumors associated with impacted third molars: is prophylactic removal justified? *J Oral Maxillofac Surg* 2011;69:405–8.
- Bruce RA, Frederickson GC, Small GS. Age of patients and morbidity associated with mandibular third molar surgery. *J Am Dent Assoc* 1980;101:240–5.
- McArdle LW, Renton TF. Distal cervical caries in the mandibular second molar: an indication for the prophylactic removal of the third molar? *Br J Oral Maxillofac Surg* 2006;44:42–5.
- McArdle LW, McDonald F, Jones J. Distal cervical caries in the mandibular second molar: an indication for the prophylactic removal of third molar teeth? Update. *Br J Oral Maxillofac Surg* 2014;52:185–9.
- Al-Khateeb TH, Bataineh AB. Pathology associated with impacted mandibular third molars in a group of Jordanians. *J Oral Maxillofac Surg* 2006;64:1598–602.
- Chang SW, Shin SY, Kum KY, Hong J. Correlation study between distal caries in the mandibular second molar and the eruption status of the mandibular third molar in the Korean population. *Oral Surg Oral Med Oral Pathol Oral Radiol Endod* 2009;108:838–43.
- Allen RT, Witherow H, Collyer J, Roper-Hall R, Nazir MA, Mathew G. The mesioangular third molar—to extract or not to extract? Analysis of 776 consecutive third molars. *Br Dent J* 2009;206: E23; discussion 586–7.
- Adaki SR, Yashodadevi BK, Sujatha S, Santana N, Rakesh N, Adaki R. Incidence of cystic changes in impacted lower third molar. *Indian J Dent Res* 2013;24:183–7.
- Glosser JW, Campbell JH. Pathologic change in soft tissues associated with radiographically 'normal' third molar impactions. *Br J Oral Maxillofac Surg* 1999;37:259–60.
- Kugelberg CF. Periodontal healing two and four years after impacted lower third molar surgery. A comparative retrospective study. *Int J Oral Maxillofac Surg* 1990;19:341–5.
- Yildirim G, Ataoglu H, Mihmanli A, Kiziloglu D, Avunduk MC. Pathologic changes in soft tissues associated with asymptomatic impacted third molars. *Oral Surg Oral Med Oral Pathol Oral Radiol Endod* 2008;106:14–8.
- Marciani RD. Is there pathology associated with asymptomatic third molars? *J Oral Maxillofac Surg* 2012;70:S15–9.