

Contents lists available at [ScienceDirect](https://www.sciencedirect.com)

International Journal of Surgery Case Reports

journal homepage: www.casereports.com

Laparoscopic resection of a large nonadrenal ganglioneuroma adhered to the aorta and inferior mesenteric artery: A case report and literature review

Shinnosuke Nagano, Norikatsu Miyoshi*, Shiki Fujino, Tsunekazu Mizusima, Yuichiro Doki, Hidetoshi Eguchi

Department of Gastroenterological Surgery, Osaka University Graduate School of Medicine, 2-2-E2 Yamadaoka, Suita City, Osaka 565-0871, Japan

ARTICLE INFO

Article history:

Received 14 November 2020

Received in revised form

25 November 2020

Accepted 25 November 2020

Available online 2 December 2020

Keywords:

Ganglioneuroma

Retroperitoneal tumor

Laparoscopic resection

ABSTRACT

INTRODUCTION: Ganglioneuromas are well-differentiated benign tumors that arise from sympathetic ganglion cells. In ganglioneuromas of the retroperitoneum, nonadrenal cases are resected by laparotomy due to the proximity to major vessels. There have been few reports of laparoscopic resection for retroperitoneal paraaortic ganglioneuromas. We experienced a case in which laparoscopic resection was required for a 90-mm ganglioneuroma adhered to the aorta and inferior mesenteric artery.

PRESENTATION OF CASE: A 49-year-old female patient presented with epigastric pain. Computed tomography showed a 90 mm retroperitoneal tumor, partially located between the aorta and inferior mesenteric artery. A definitive diagnosis was not obtained, and laparoscopic excision of the retroperitoneal tumor was performed transabdominally. The patient recovered without postoperative complications and left the hospital on postoperative day 8. Postoperative pathological findings revealed a ganglioneuroma from the abdominal periaortic plexus.

DISCUSSION: We searched the literature for nonadrenal ganglioneuromas resected laparoscopically using a transabdominal approach and summarized the tumor locations. The median age was 33 years, and the median tumor size was 50 mm. Regarding the surgical results, the median operative time was 170.5 min, median blood loss was 21.5 mL, and median postoperative stay was 7 days.

CONCLUSION: Laparoscopic resection of nonadrenal ganglioneuromas is feasible even when a tumor adheres to major blood vessels.

© 2020 The Author(s). Published by Elsevier Ltd on behalf of IJS Publishing Group Ltd. This is an open access article under the CC BY-NC-ND license (<http://creativecommons.org/licenses/by-nc-nd/4.0/>).

1. Introduction

Ganglioneuromas are the most well-differentiated benign tumors of the neuroblastoma group arising from sympathetic ganglion cells [1,2]. In the retroperitoneum, half of the ganglioneuromas are of nonadrenal origin [3]. Recently, laparoscopic resection for adrenal retroperitoneal tumors has been standardized in the field of urology. However, many nonadrenal cases are resected by laparotomy due to the narrow operative space, deep location, and close proximity to vascular structures and the gastrointestinal tract [4]. We experienced a case of a 90-mm ganglioneuroma in contact with the aorta and inferior mesenteric artery (IMA) that was laparoscopically resected. Here, we report a review of surgical outcomes of transabdominal laparoscopic resection for nonadrenal retroperi-

toneum ganglioneuromas and our surgical techniques from the perspective of colorectal surgery, which specializes in mobilizing the mesentery. The work has been reported in line with the SCARE criteria [5].

2. Presentation of case

A 49-year-old woman with a history of epigastric pain visited a local clinic. She had no medical history or surgical history, and no relevant family history. Contrast-enhanced computed tomography (CT) showed a 90-mm non-enhanced retroperitoneal tumor, partially located between the aorta and IMA (Fig. 1). She was referred to our hospital for further examination. Laboratory data and tumor markers were all within normal limits, and endocrine tests were negative. Magnetic resonance imaging (MRI) showed hyperintensity on T2-weighted images. T1 weighted images showed that the tumor presented hyperintensity on in-phase and hypointensity on out-of-phase; this result indicated fat was included in the tumor. Differential diagnosis at that stage included ganglioneuroma and dedifferentiated liposarcoma. The imaging examinations could not

Abbreviations: IMA, inferior mesenteric artery; CT, computed tomography; MRI, magnetic resonance imaging; IVC, inferior vena cava.

* Corresponding author.

E-mail address: nmiyoshi@gesurg.med.osaka-u.ac.jp (N. Miyoshi).

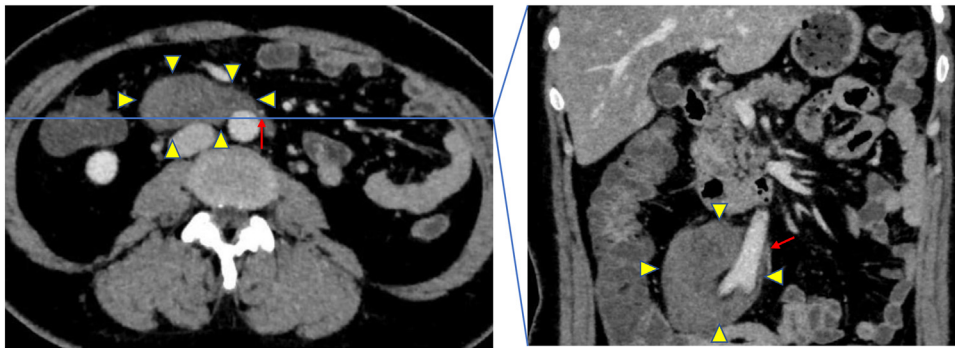


Fig. 1. Contrast-enhanced computed tomography (CT) scan showing a 90 mm not-enhanced retroperitoneal tumor (yellow arrowheads), partially located between the aorta and IMA (red arrow).

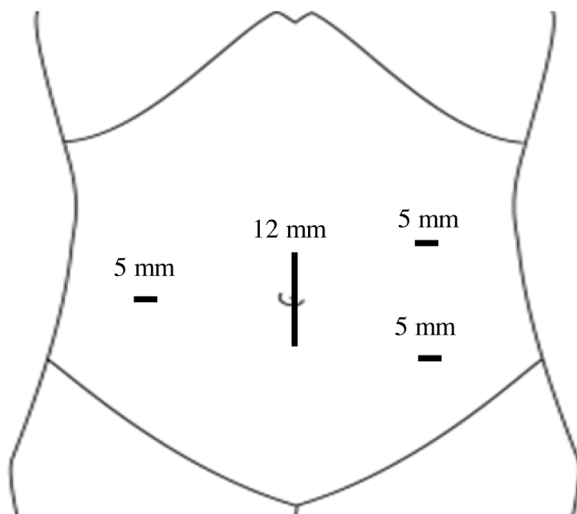


Fig. 2. Schemes of port position.

provide a definitive diagnosis, and surgical resection with diagnostic treatment was necessary. Although the tumor was adhered to the aorta, IMA, and duodenum, it did not show any infiltrative findings; therefore, we decided to perform a laparoscopic resection.

Under general anesthesia, the patient was placed in the lithotomy position. A surgical operator was colorectal surgeon, and performed at least 30 laparoscopic procedures per year during the previous 5 years. The first trocar, used for the camera port, was inserted through the umbilicus. A video (Supplemental Digital Content 1) of the procedure is shown. The tumor was well visualized through the mesentery. The cranial margin was found at the level of the duodenal horizontal, the left side was at the front of the aorta, the right side was at the right ureter, and the caudal side was at the level of the right common iliac artery. The remaining three trocar positions were chosen carefully; two 5-mm trocars were inserted on the left side of the umbilicus, and a 5-mm trocar was inserted in the right side of the umbilicus (Fig. 2). First, mobilization of the ileocecal mesentery was started, exposing the right and front of the tumor. Second, the descending colon was mobilized, and the IMA was exposed and secured from the root of the aorta. Some parts of the IMA showed adhesion to the tumor without invasion; therefore, they could be easily detached (Fig. 3A). Next, the left side of the tumor was dissected from the front of the aorta, which was partly adhered to by strong fibrous tissue. Recognizing that it was the tumor base that was continuous to the aortic sympathetic trunk, we dissected it sharply by using ultrasonic shears (Fig. 3B). The right side of the tumor was detached continuously, exposing the front of the right common iliac artery, the inferior vena cava (IVC),

and the right ureter (Fig. 3C). Finally, the tumor was extracted from the umbilical port incision (Fig. 3D).

The operation time was 239 min and blood loss was 20 mL. The patient recovered without postoperative complications and left the hospital on postoperative day 8. Histology reported a ganglioneuroma from the abdominal periaortic plexus (Fig. 4). The patient exhibits no evidence of recurrence by CT in the outpatient follow-up for 1 year after surgery.

3. Discussion

Ganglioneuromas are part of the neuroblastoma group, together with neuroblastomas and ganglioneuroblastomas. They are well-differentiated benign tumors comprising mature sympathetic ganglion cells and nerve fibers [6]. These neuromas are commonly located in the posterior mediastinum (43%), followed by the retroperitoneum (32%), and cervical region (8%) [7]. As a treatment for ganglioneuroma, malignancy sometimes cannot be ruled out only by preoperative imaging findings; thus, complete surgical resection is recommended.

If benign retroperitoneal tumors, including ganglioneuromas, are suspected from preoperative imaging, laparoscopic surgery may be useful, even when the tumors adhere to large vessels. Twenty-five cases of benign paraaortic paracaval neurogenic tumors were reportedly resected laparoscopically; intraoperative injury of the vena cava occurred in only one patient, but no patient required conversion to open surgery, and 23 patients were free of disease at a median follow-up of 37.5 months [8]. About 20 cases of nonadrenal retroperitoneal tumors were reportedly resected by laparoscopic surgery; the presence of adhesions to an adjacent major vessel did not affect intraoperative bleeding and postoperative hospital stay [4].

In particular, ganglioneuromas are derived from sympathetic nerves and often spread vertically to the paravertebral region arising from the sympathetic ganglion and therefore do not invade surrounding tissues [9]. Therefore, even if the tumor is adjacent to the large blood vessels on the preoperative images, it can be detached by an appropriate counter traction. Furthermore, the magnifying effect is more suitable for laparoscopic surgery. Adhesion to the detached surface of the tumor capsule is not considered to be very strong. However, a cord-like tissue with the sympathetic trunk may be found at the base of the tumor. As in our case, such cord tissue needs to be sharply dissected; therefore, it is important to pay close attention to the possibility of residual tumor and damages for large blood vessels.

Laparoscopic surgery for retroperitoneal tumors can be divided into two types: retroperitoneal and transabdominal approaches. The retroperitoneal approach was useful for adrenalectomy. Surgical outcomes of retroperitoneal adrenalectomy were reportedly

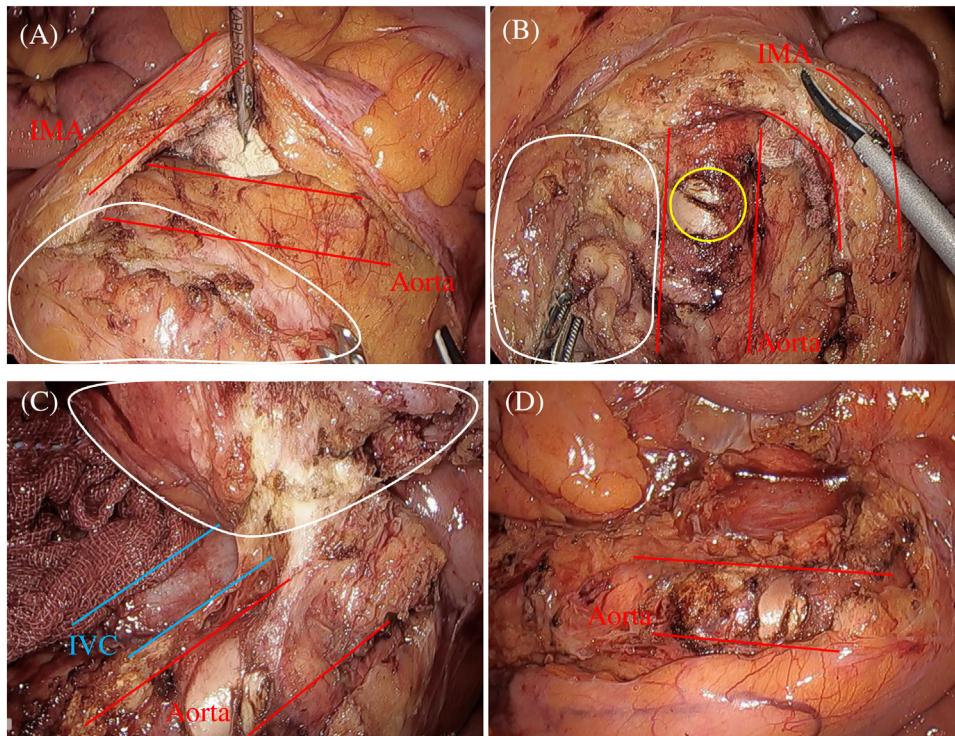


Fig. 3. Intraoperative laparoscopic view.

- (A) IMA was exposed and secured from the root of the aorta. IMA could be easily detached from the tumor (white line).
- (B) The left side of the tumor was dissected from the front of the aorta. We dissected the tumor base which was continuous to aortic sympathetic trunk (yellow circle).
- (C) The right side of the tumor was detached continuously, exposing the front of the right common iliac artery, the inferior vena cava (IVC).
- (D) The view of after removing the tumor.

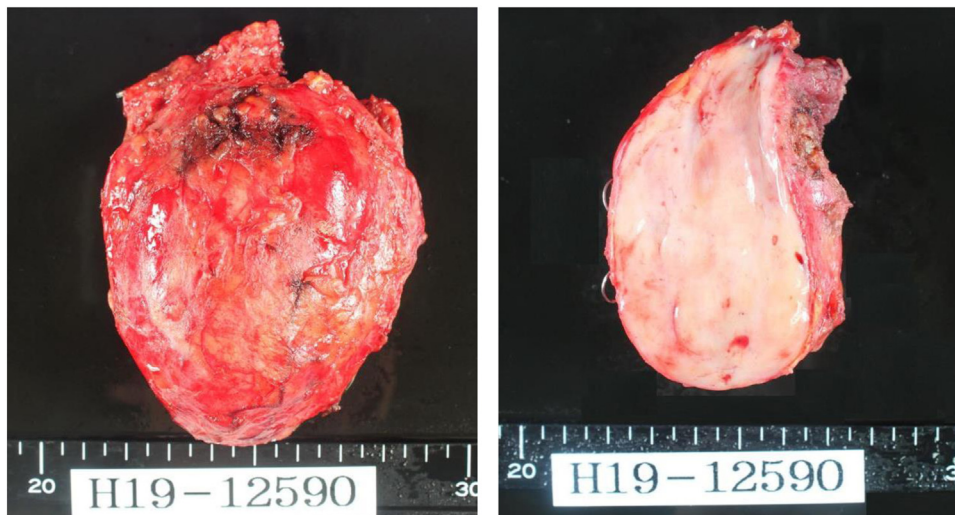


Fig. 4. The surface of the tumor was smooth, and microscopic findings showed ganglioneuroma.

superior to those of transabdominal adrenalectomy in terms of operative time, time to first oral intake, analgesic requirements, and length of hospital stay [10,11]. Therefore, the retroperitoneal approach may be useful for retroperitoneal tumors that are superior to the renal hilum. Conversely, the transabdominal approach may be appropriate for tumors that are caudal to the renal hilum. The transabdominal approach allows rapid understanding of the anatomical relationship between the tumor and the large blood vessels or intestinal tract by mobilizing mesentery from the retroperitoneum. However, in the laparoscopic surgery for retroperitoneal tumors, there is a lack of long-term data on onco-

logical outcome, such as survival and recurrence. If preoperative radiologic studies show malignant findings obviously, open operation may be preferred for oncologic safety. We consider that a careful patient selection is very important for laparoscopic resections on the basis of various preoperative examinations. If apparent invasion is observed intraoperatively, open conversion should also be considered for more radical resections.

We searched the literature for nonadrenal ganglioneuromas resected laparoscopically using a transabdominal approach (Table 1) and summarized the tumor locations (Fig. 5). The median age was 33 years, and the median tumor size was 50 mm. Regard-

Table 1
Summary of data in 12 cases of nonadrenal ganglioneuroma resected by laparoscopically transabdominal approach in the literature.

Case	Author	Year	Sex	Age	tumor location	Tumor Size	Operative Time	Blood Loss	Postop Stay
1	Sasaki	2008	F	22	the retroperitoneal space, adjacent to the roof of the left gastric artery	40	120	5	12
2	Sasaki	2008	F	31	the retroperitoneal space, between the IMA and the left psoas muscle	50	163	23	4
3	Mahesh	2010	M	37	the upper abdomen near the celiac axis	60	160	100	3
4	Keun	2011	M	29	right and posterior of IVC and PV	95	330	250	6
5	Keun	2011	M	62	medial of left adrenal gland and pancreas tail	43	80	50	7
6	Keun	2011	F	27	superior of right renal vein	40	100	20	4
7	Yagi	2013	F	29	dorsal side of IVC and superior of right kidney	70	350	10	4
8	Nakano	2013	M	40	superior of left kidney, adjacent to the left border of the SMA	50	178	120	7
9	Abe	2016	F	55	near the right Adrenal gland	60	150	120	8
10	Abe	2016	F	60	near the right Adrenal gland	60	179	0	12
11	Abe	2016	F	27	near the left Adrenal gland	60	148	0	7
12	Our Case	2020	F	49	between the aorta and IMA	90	239	20	8
Median				33		50	170.5	21.5	7

IMA: inferior mesenteric artery, IVC: inferior vena cava, PV: portal vein, SMA: superior mesenteric artery.

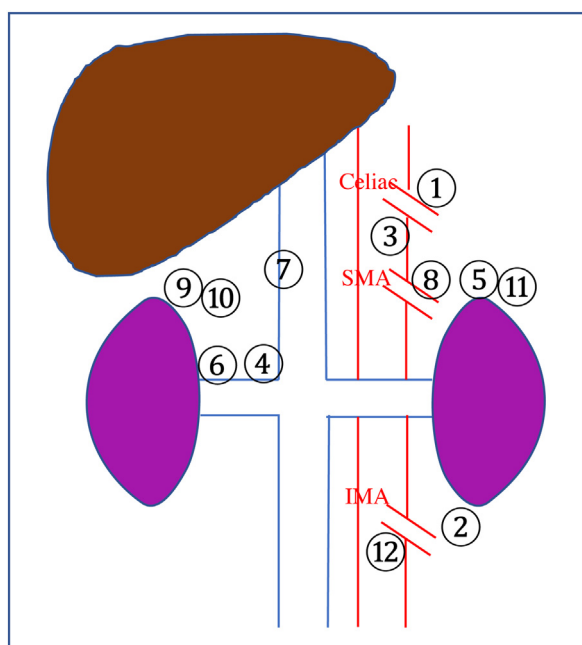


Fig. 5. Distribution of tumor locations about each cases of Table 1.

ing the surgical results, the median operative time was 170.5 min, median blood loss was 21.5 mL, and median postoperative stay was 7 days. In 10 patients, the tumor site was on the upper side of the renal vein, and in only two patients, including our case, was on the lower side of the renal vein. In both instances the tumor adhered to the IMA. In our study, there are few reported cases below the renal vein, so we consider that our surgical tricks and tips may be helpful for retroperitoneal tumors in the similar position.

4. Conclusion

Thus, laparoscopic resection of nonadrenal ganglioneuromas is feasible even when a tumor adheres to major blood vessels if there is no evidence of local invasion or malignancy on the basis of various preoperative examinations.

Declaration of Competing Interest

The authors report no declarations of interest.

Funding

This research did not receive any specific grant from funding agencies in the public, commercial, or not-for-profit sectors.

Ethical approval

This case report was exempted from ethical approval from the institution.

Consent

Written informed consent was obtained from the patients for publication of this case report and accompanying images. A copy of the written consent is available for review by the Editor-in-Chief of this journal on request.

Author contribution

S.N and N.M wrote this manuscript. S.N, N.M, S.F, T.M, Y.D and H.E had medical conference to decide this surgical procedure. All authors approved the manuscript to be published, and agree to be accountable for all aspects of the work in ensuring that questions related to the accuracy or integrity of any part of the work are appropriately investigated and resolved.

Registration of research studies

Not applicable.

Guarantor

Norikatsu Miyoshi is the Guarantor for this work.

Provenance and peer review

Not commissioned, externally peer-reviewed.

Acknowledgement

This report was approved by the ethical committee of our institution. Written, informed consent was obtained from the patient, and patient anonymity was preserved.

Appendix A. Supplementary data

Supplementary material related to this article can be found, in the online version, at <https://doi.org/10.1016/j.ijscr.2020.11.127>.

References

- [1] A. Sasaki, T. Suto, H. Nitta, O. Shimooki, T. Obuchi, G. Wakabayashi, Laparoscopic excision of retroperitoneal tumors: report of three cases, *Surg. Today* 40 (2010) 176–180.
- [2] G. Cerullo, D. Marrelli, B. Rampone, C. Miracco, S. Caruso, D.M. Marianna, M.A. Mazzei, F. Roviello, Presacral ganglioneuroma: a case report and review of literature, *World J. Gastroenterol.* 13 (2007) 2129–2131.
- [3] T. Yoshida, T. Inoue, T. Nishida, et al., Laparoscopic excision of a retroperitoneal ganglioneuroma: a case report, *Acta Urol.* 60 (2014) 279–282.
- [4] K.S. Ahn, H.S. Han, Y.S. Yoon, H.H. Kim, T.S. Lee, S.B. Kang, J.Y. Cho, Laparoscopic resection of nonadrenal retroperitoneal tumors, *Arch. Surg.* 146 (2011) 162–167.
- [5] R.A. Agha, M.R. Borrelli, R. Farwana, K. Koshy, A. Fowler, D.P. Orgill, For the SCARE Group, The SCARE 2018 statement: updating consensus Surgical CAse REport (SCARE) guidelines, *Int. J. Surg.* 60 (2018) 132–136.
- [6] M.C. Misra, H.K. Bhattacharjee, A.K. Hemal, V.K. Bansal, Laparoscopic management of rare retroperitoneal tumors, *Surg. Laparosc. Endosc. Percutan. Tech.* 20 (2010) e117–122.
- [7] O. Yuki, O. Naoyoshi, T. Yuki, et al., A case of adrenal ganglioneuroma diagnosed and removed by a laparoscopic surgery, *J. Jpn. Surg. Assoc.* 78 (2017) 2135–2139.
- [8] T. Abe, A. Sazawa, T. Harabayashi, Y. Oishi, N. Miyajima, K. Tsuchiya, S. Maruyama, H. Okada, N. Shinohara, Laparoscopic resection of paraaortic/paracaval neurogenic tumors: surgical outcomes and technical tips, *Surg. Endosc.* 30 (2016) 4640–4645.
- [9] N. Yoritaka, T. Hideo, T. Shuntaro, et al., Laparoscopic extirpation of a retroperitoneal ganglioneuroma—report of a case, *J. Jpn. Surg. Assoc.* 74 (2013) 2924–2928.
- [10] M. Barczynski, A. Konturek, W. Nowak, Randomized clinical trial of posterior retroperitoneoscopic adrenalectomy versus lateral transperitoneal laparoscopic adrenalectomy with a 5-year follow-up, *Ann. Surg.* 260 (2014) 740–748.
- [11] V.A. Constantinides, I. Christakis, P. Touska, K. Meeran, F. Palazzo, Retroperitoneoscopic or laparoscopic adrenalectomy? A single-centre UK experience, *Surg. Endosc.* 27 (2013) 4147–4152.

Open Access

This article is published Open Access at [sciencedirect.com](https://www.sciencedirect.com). It is distributed under the [IJSCR Supplemental terms and conditions](#), which permits unrestricted non commercial use, distribution, and reproduction in any medium, provided the original authors and source are credited.