



Contents lists available at ScienceDirect

Gynecology and Minimally Invasive Therapy

journal homepage: www.e-gmit.com

Short communication

Subtotal hysterectomy by natural orifice transluminal endoscopic surgery

Chyi-Long Lee^{a, c, *, 1}, Kai-Yun Wu^{b, c, 1}, Chen-Ying Huang^{b, c}, Chuan Cheng^b, Chien-Min Han^{b, c}, Chih-Feng Yen^{b, c}^a Department of Obstetrics and Gynecology, Keelung Chang Gung Memorial Hospital, Keelung, Taiwan^b Department of Obstetrics and Gynecology, Linkou Chang Gung Memorial Hospital, Kwei-Shan, Taoyuan, Taiwan^c Chang Gung University College of Medicine, Kwei-Shan, Taoyuan, Taiwan

ARTICLE INFO

Article history:

Received 19 September 2016

Received in revised form

26 January 2017

Accepted 3 February 2017

Available online 4 May 2017

Keywords:

laparoscopic hysterectomy

laparoscopy

myoma uteri

natural orifice transvaginal endoscopic surgery (NOTES)

subtotal hysterectomy

ABSTRACT

Study objective: To introduce the innovative surgical procedure of treating benign uterine pathology with subtotal hysterectomy by natural orifice transluminal endoscopic surgery (NOTES).**Design:** Prospective observational study.**Setting:** Tertiary referral medical center.**Methods:** From June 2014 to May 2016, three patients with benign uterine diseases who were eligible for laparoscopic subtotal hysterectomy were recruited to undergo transvaginal NOTES at a tertiary referral medical center. Intraoperative and postoperative surgical outcomes were measured.**Results:** Subtotal hysterectomy by transvaginal NOTES was successfully completed in all patients without any conversion to conventional laparoscopy. The operative time was 144 ± 4.5 (138–149) minutes with an average estimated blood loss of 133 ± 62 (50–200) mL. None of the patients required an intraoperative blood transfusion. The mean specimen weight was 140 ± 59 (56–188) g. The final histology reports were uterine leiomyoma and adenomyosis in these three cases. There were no intraoperative or postoperative complications. No case required intraoperative or postoperative blood transfusion. No cases were converted to traditional laparoscopy or laparotomy.**Conclusion:** Our preliminary results showed the safety and feasibility of subtotal hysterectomy by transvaginal NOTES in selected patients. It is one of the most minimally invasive surgeries and results in invisible scars.Copyright © 2017, The Asia-Pacific Association for Gynecologic Endoscopy and Minimally Invasive Therapy. Published by Elsevier Taiwan LLC. This is an open access article under the CC BY-NC-ND license (<http://creativecommons.org/licenses/by-nc-nd/4.0/>).

Introduction

Natural orifice transluminal endoscopic surgery (NOTES) is a novel concept of using the natural orifices of the human body as surgical channels.¹ For gynecologic surgeons, transvaginal access is the most familiar and useful approach. We developed the technique of transvaginal NOTES using the Lagiport kit (Lagis Enterprise Co., Ltd., Taichung, Taiwan; [Figure 1](#)) in 2012 and demonstrated that

transvaginal NOTES can be performed in surgeries such as adnexal procedures,^{2,3} total hysterectomies,^{4,5} myomectomy,⁶ and endometrial cancers.⁷

However, subtotal hysterectomy is rarely discussed in the literature of NOTES. The purpose of this study was to demonstrate the surgical procedure step by step, to prove the feasibility in selected patients, and to explore the possible limitations of subtotal hysterectomy performed using transvaginal NOTES in the daily practice for benign gynecologic disease in our initial experience.

Materials and methods

All patients who underwent surgical management provided written informed consent. Experienced gynecologic endoscopists performed all surgeries.

Conflicts of interest: All contributing authors declare no conflicts of interest.

* Corresponding author. Department of Obstetrics and Gynecology, Chang Gung Memorial Hospital at Linkou, 5, Fu-Hsin Street, Kwei-Shan, Tao-Yuan 33305, Taiwan.

E-mail address: leechyilong@gmail.com (C.-L. Lee).

¹ Both authors contributed equally to this study.

<http://dx.doi.org/10.1016/j.gmit.2017.02.005>

2213-3070/Copyright © 2017, The Asia-Pacific Association for Gynecologic Endoscopy and Minimally Invasive Therapy. Published by Elsevier Taiwan LLC. This is an open access article under the CC BY-NC-ND license (<http://creativecommons.org/licenses/by-nc-nd/4.0/>).

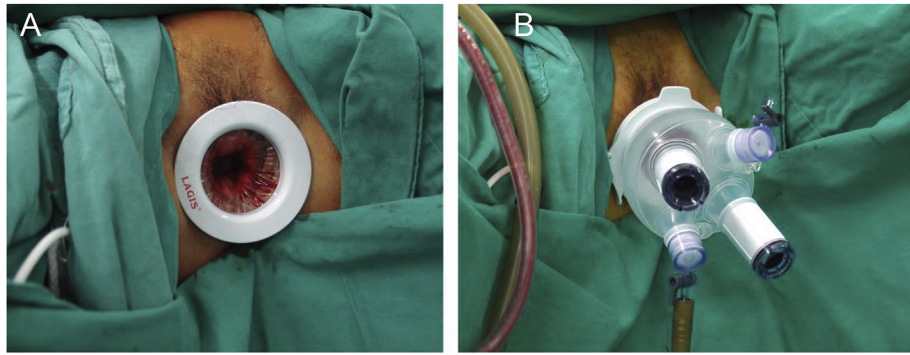


Figure 1. (A) A Lagiport kit multiple instrument access port (Lagis Enterprise Co., Ltd., Taichung, Taiwan) was inserted into vagina with its inner rim fixed against the posterior wall of the uteri and posterior *cul-de-sac*. (B) The insufflating tube was connected to one of the cannulas to establish pneumoperitoneum.

Patients

From June 2014 to June 2016, patients indicated for laparoscopic hysterectomy were offered laparoscopic subtotal hysterectomy as an alternative option if there was no contraindication to preserve the cervix. After the possible consequences of subtotal hysterectomy were explained, only three patients requested to undergo laparoscopic subtotal hysterectomy. Patients scheduled for laparoscopic subtotal hysterectomy in Chang Gung Memorial Hospital, Tao-Yuan, Taiwan were prospectively included to undergo transvaginal NOTES. Conditions such as obesity (body mass index $>30 \text{ kg/m}^2$), those who never had vaginal deliveries, those who needed concomitant adnexal surgeries, and those with a history of previous cesarean deliveries or abdominal surgeries were not considered contraindications. However, virgin patients, and those suspected to have severe pelvic adhesions from prior abdominal surgeries, tubo-ovarian abscesses, or endometriosis were excluded.

Surgical techniques

Under general anesthesia with endotracheal intubation, patients were placed in Trendelenburg position with legs bandaged and supported in the stirrups. A Foley catheter was indwelled. The surgical procedures were as follows,

1. Posterior colpotomy. With tractions on uterine cervix by two teneculums, the operation began with a 2- to 3-cm incision of the posterior fornix.
2. Establishment of the vaginal channel for endoscopic surgery. A Lagiport kit multiple instrument access port was inserted into the vagina with its inner rim fixed against the posterior wall of uteri and posterior *cul-de-sac* (Figure 1). We used a 10-mm, 0° endoscope (Karl Storz GmbH & Co. KG, Tuttlingen, Germany), and a 5-mm bipolar LigaSure system (Covidien Company, Boulder, CO, USA) designed for laparoscopy as the energy source to complete the procedure.
3. Endoscopic management of the uterus. After we established adequate pneumoperitoneum and inserted the endoscope to explore the pelvis, the uterine isthmus was identified. Then, posterior and anterior broad ligaments at the level of isthmus were opened by a monopolar scissor. The remaining structures going upward from the isthmic level, including broad ligaments, round ligaments, ovarian ligaments and Fallopian tubes, were then sealed and cut using LigaSure (Figure 2). If any adnexal lesions were found, concomitant surgery such as enucleation, salpingectomy, or salpingo-oophorectomy was performed whenever appropriate. Then the uterus was inverted vaginally, and the uterus was amputated at the level of isthmus. Repair of the cervical stump and hemostasis were performed vaginally

using conventional instruments. Then, the Lagiport was draped again, and the endoscope was reintroduced for hemostasis and to look over the whole pelvis and abdomen.

4. Procedure completion. Finally, the Lagiport was removed again, and the vaginal wound was closed using a 2–0 Vicryl suture.

Postoperative care

Prophylactic antibiotics with preoperative cefazolin, and postoperative cefazolin and gentamicin for were administered for 1 day. Nonsteroidal anti-inflammatory drugs were also routinely prescribed after the operation. Patients were discharged, per our national regulations, with an afebrile status for at least 24 hours, without evidence of surgical complications.

Results

The three patients were 43 years old, 45 years old, and 49 years old. They underwent subtotal hysterectomy via NOTES approach for the treatment of benign uterine pathologies, including myoma and adenomyosis. All of them were multiparous. One patient had a cesarean section twice only, and the others had vaginal deliveries. All of them denied having a history of hypertension, diabetes mellitus, or heart diseases. Except for cesarean section, one of them had previous laparoscopic myomectomy, and the others denied having an abdominal surgical history. Two patients had a history of pelvic inflammatory disease that required inpatient antibiotic treatment, but pelvic examination showed nonsignificant findings for suspicious pelvic adhesion. The demographic data, as well as intraoperative and postoperative surgical outcomes are established in Tables 1 and 2. Subtotal hysterectomy by transvaginal NOTES was successfully completed in all patients without any conversion to conventional laparoscopy. The operative time was 144 ± 4.5 (138–149) minutes with an average blood loss of 133 ± 62 (50–200) mL. No patients required an intraoperative blood transfusion. The mean specimen weight was 140 ± 59 (56–188) g. In the laboratory data survey on the 1st postoperative day, the hemoglobin level change was $-1.1 \pm 0.94 \text{ g/dL}$ on average. The postoperative hospital stay was 2.33 ± 0.47 (2–3) days. The final histology reports were uterine leiomyoma in two cases and adenomyosis in one case. There were no intraoperative or postoperative complications.

After a follow-up of up to 3 months after the operation, all patients showed good healing of the vaginal wound with normal voiding and sexual functions.

Discussion

In recent years, new techniques of minimally invasive surgery have been developed not only for better surgical outcomes but also

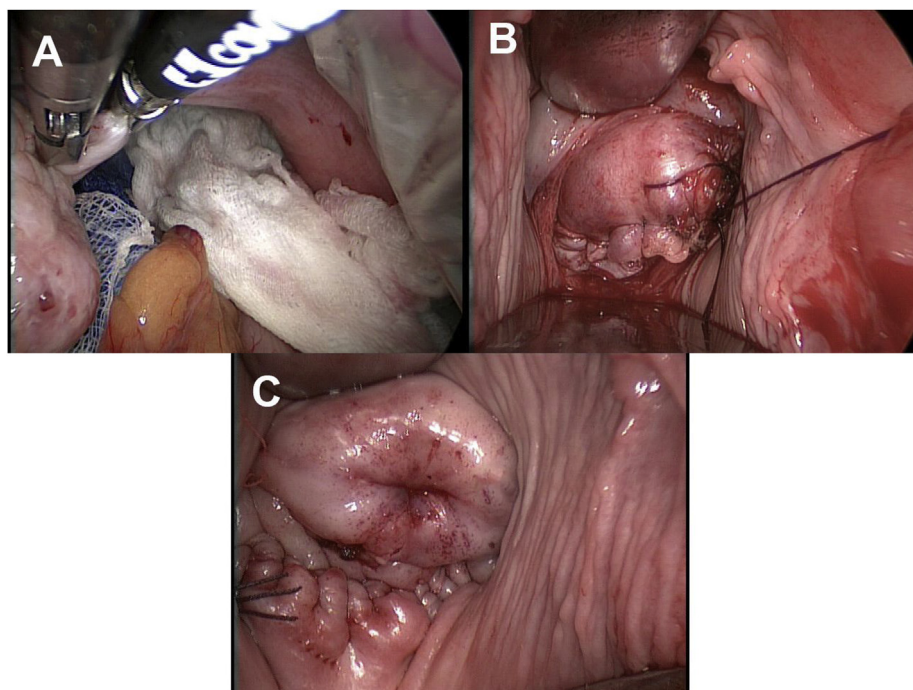


Figure 2. Intraoperative photographs from a representative patient showing portions of the endoscopic procedures. (A) The right ovarian ligament was exposed then dissected by the LigaSure. (B) Cervix stump was closed with 1–0 Vicryl. (C) Posterior colpotomy was approximated.

Table 1
Patient characteristics.

Patient No.	Age (y)	Parity	BMI	Abdominal operation history	Associated history
1	45	P2, vaginal delivery ×2	20.1	Laparoscopic myomectomy	Nil
2	43	P2, cesarean delivery ×2	21.6	Cesarean section ×2	PID
3	49	P2, vaginal delivery ×2	30.2	Nil	PID

BMI = body mass index; PID = Pelvic inflammatory disease.

Table 2
Surgical outcomes.

Patient No.	Operation time (min)	Uterine weight (g)	Blood loss (mL)	Hemoglobin change (g/dL)	Discharge on postoperative day	Pathology	Complication
1	144	188	200	+0.1	2	Leiomyoma	Nil
2	138	56	50	–1.2	2	Adenomyosis	Nil
3	149	175	150	–2.2	3	Adenomyosis	Nil

for better cosmesis. NOTES involves using the natural orifices of the human body as surgical channels to achieve the ultimate aim of leaving an invisible scar. There are lines of evidence showing the feasibility of performing a NOTES hysterectomy and adnexal surgery by using the transvaginal natural orifice technique. The advantages of NOTES surgery included the following: (1) no superficial wound; (2) decreased the pain and discomfort; (3) no possibility of herniation and infection of wound; (4) no risk of bowel injury in trocar insertion; and (5) an esthetic outcome after the surgery.^{1,2,4–7}

The options of surgical treatment of uterine fibroid include myomectomy, subtotal and/or total hysterectomy,⁸ and those that could be performed via different approaches.^{9–14} Among these options, subtotal hysterectomy is the choice considered to have better sexual outcomes compared with total hysterectomy.^{15–17} Unlike total hysterectomy, it only removes the uterine corpus with the preservation of the cervix. There is evidence showing that

subtotal hysterectomy could maintain the patients' sexual life and achievement of orgasm, as well as maintain the integrity of the pelvic floor. From the surgeon's point of view, subtotal hysterectomy does not have to involve bladder manipulation—i.e., pushing down the bladder and exposure of pubocervical fascia—or going through coagulation or dissection of the uterine vessels descending branch. Therefore, these could reduce the risk of ureter injury during manipulation. These are the inherent advantages of subtotal hysterectomy.

Although there are advantages in conventional laparoscopic subtotal hysterectomy, it did not have the same benefit as performing NOTES subtotal hysterectomy. The reason indicated is that NOTES surgery is performed from the cervix up to the fundus; thus, it is difficult to browse the whole pelvis, which may cause higher risk in surgery performance. Furthermore, the wound retractor usage in NOTES procedure could block the lower corpus of the

uterus. Therefore, it could affect the performance and completion of the surgery. Hence, NOTES subtotal hysterectomy might not seem to be an ideal approach compared to conventional laparoscopic subtotal hysterectomy; however, NOTES surgery is still considered beneficial for women who prefer esthetic outcomes with no superficial wound on their body.

Despite the rarity of subtotal hysterectomy performed by NOTES, our method has several advantages. First, there is no need to open the anterior colpotomy. The risk of bladder or ureter injury is markedly decreased because we do not manipulate the bladder at all. Therefore, in patients with previous cesarean sections, the adhesion over the bladder does not affect our procedure. Second, the blood loss in our surgery is acceptable because we perform cervical amputation after ligation of the uterine vessels. Third, the integrity of the pelvic floor remains almost intact. We do not interfere with the anterior compartment, and the posterior colpotomy wound was opened without disruption of the uterosacral ligaments.

The limitations of this innovative procedure may come from the disproportion of the vagina and uterine pathology. The vagina has a naturally wide elasticity, but it decreases because of the aging process. Therefore, in our experience, there is no definite limitation for the size of the uterine corpus. The size could be overcome with the length of the endoscopic instruments, as we had shown in our NOTES hysterectomy series. However, during specimen retrieval through the posterior colpotomy wound, it could be a problem if the wound lacks elasticity.

In conclusion, NOTES subtotal hysterectomy is a new method for subtotal hysterectomy. Vaginal subtotal hysterectomy is rare and is only found in a few reports on severe prolapse patients. Our method offers a feasible way to remove the uterine corpus in the nonprolapse uterus and leaves the cervix *in situ* with minimal manipulation. It maintains the advantage of the transabdominal approach that keeps the pelvic support. It broadens the indications of NOTES surgery. It leaves invisible scars and provides better cosmesis. Our report presents preliminary data showing the feasibility and safety of subtotal hysterectomy. However, more experience is needed to evaluate the full clinical application of performing this type of surgery.

Acknowledgments

We thank Miss Suan Huang for assistance in editing the manuscript. This study was supported partially by Chang Gung Memorial Hospital (NMRPD1C0761) research grants.

Authors' contributions

C.-L. L., K.-Y. W., C.-Y. H., and C.-F. Y. conceived and designed the study; K.-Y. W., and C.-Y. H. acquired the data; C.-L. L. analyzed and interpreted the data; K.-Y.W. and C.C. drafted the manuscript; C.-L.L. and K.-Y.W. reviewed the data and revised the manuscript critically for scientific and intellectual content. All authors approved the final version of the manuscript for submission.

References

1. Lee CL, Wu KY, Su H, Wu PJ, Han CM, Yen CF. Natural orifice transluminal endoscopic surgery (NOTES) in gynecology. *Gynecol Minim Invasive Ther.* 2012;1:23–26.
2. Lee CL, Wu KY, Su H, Ueng SH, Yen CF. Transvaginal natural-orifice transluminal endoscopic surgery (NOTES) in adnexal procedures. *J Minim Invasive Gynecol.* 2012;19:509–513.
3. Lee CL, Wu KY, Su H, Yen CF, Ueng SH. Regarding “transvaginal single-port natural orifice transluminal endoscopic surgery”. *J Minim Invasive Gynecol.* 2013;20:131–132.
4. Su H, Yen CF, Wu KY, Han CM, Lee CL. Hysterectomy via transvaginal natural orifice transluminal endoscopic surgery (NOTES): feasibility of an innovative approach. *Taiwan J Obstet Gynecol.* 2012;51:217–221.
5. Lee CL, Wu KY, Su H, Wu PJ, Han CM, Yen CF. Hysterectomy by transvaginal natural orifice transluminal endoscopic surgery (NOTES): a series of 137 patients. *J Minim Invasive Gynecol.* 2014;21:818–824.
6. Lee CL, Huang CY, Wu KY, Hu YF, Yen CF, Han CM. Natural orifice transvaginal endoscopic surgery myomectomy: an innovative approach to myomectomy. *Gynecol Minim Invasive Ther.* 2014;3:127–130.
7. Lee CL, Wu KY, Tsao FY, et al. Natural orifice transvaginal endoscopic surgery for endometrial cancer. *Gynecol Minim Invasive Ther.* 2014;3:89–92.
8. Doherty L, Mutlu L, Sinclair D, Taylor H. Uterine fibroids: clinical manifestations and contemporary management. *Reprod Sci.* 2014;21:1067–1092.
9. Khan AT, Shehmar M, Gupta JK. Uterine fibroids: current perspectives. *Int J Womens Health.* 2014;6:95–114.
10. Wu KY, Lertvikool S, Huang KG, Su H, Yen CF, Lee CL. Laparoscopic hysterectomies for large uteri. *Taiwan J Obstet Gynecol.* 2011;50:411–414.
11. Wu PJ, Tseng LH, Chang SD, Lee CL. Clinical outcome after laparoscopic assisted vaginal hysterectomy with transvaginal uterosacral ligament fixation. *Taiwan J Obstet Gynecol.* 2012;51:363–367.
12. Lee CL, Wang CJ. Laparoscopic myomectomy. *Taiwan J Obstet Gynecol.* 2009;48:335–341.
13. Han CM, Wu KY, Su H, et al. Feasibility of transumbilical single-port laparoscopic hysterectomy using conventional instruments. *Gynecol Minim Invasive Ther.* 2014;3:47–49.
14. Thain S, Tan HH. Approaches to adenomyomectomy. *Gynecol Minim Invasive Ther.* 2015;4:49–54.
15. Gimbel H. Total or subtotal hysterectomy for benign uterine diseases? A meta-analysis. *Acta Obstet Gynecol Scand.* 2007;86:133–144.
16. Ellstrom Engh MA, Jerhamre K, Junskog K. A randomized trial comparing changes in sexual health and psychological well-being after subtotal and total hysterectomies. *Acta Obstet Gynecol Scand.* 2010;89:65–70.
17. American Association of Gynecologic Laparoscopists. AAGL practice report: practice guidelines for laparoscopic subtotal/supracervical hysterectomy (LSH). *J Minim Invasive Gynecol.* 2014;21:9–16.