



Contents lists available at ScienceDirect

## International Journal of Surgery Case Reports

journal homepage: [www.casereports.com](http://www.casereports.com)

# Perforation of intramural gastric metastasis during preoperative chemotherapy in a patient with thoracic esophageal squamous cell carcinoma

Tomoyuki Okumura<sup>a,\*</sup>, Yutaka Shimada<sup>b</sup>, Shozo Hojo<sup>a</sup>, Shinich Sekine<sup>a</sup>, Katsuhisa Hirano<sup>a</sup>, Makoto Moriyama<sup>a</sup>, Shigeharu Miwa<sup>c</sup>, Takuya Nagata<sup>a</sup>, Kazuhiro Tsukada<sup>a</sup>

<sup>a</sup> Department of Surgery and Science, Graduate School of Medicine and Pharmaceutical Sciences, University of Toyama 2630 Sugitani, Toyama City, Toyama 930-0194, Japan

<sup>b</sup> Department of Nanobio Drug Discovery, Graduate School of Pharmaceutical Sciences, Kyoto University 46-29 Yoshida-Shimo-Adachi-cho, Sakyo-ku, Kyoto 606-8501, Japan

<sup>c</sup> Department of Diagnostic Pathology, Graduate School of Medicine and Pharmaceutical Sciences, University of Toyama 2630 Sugitani, Toyama City, Toyama 930-0194, Japan

## ARTICLE INFO

## Article history:

Received 19 September 2015

Accepted 12 October 2015

Available online 21 October 2015

## Keywords:

Esophageal cancer

Intramural gastric metastasis

Neoadjuvant chemotherapy

## ABSTRACT

**INTRODUCTION:** Perforation of intramural metastasis to the stomach (IMS) from esophageal cancer during chemotherapy has not been reported.

**PRESENTATION OF CASE:** A 68-year-old male consulted our hospital due to appetite loss. He was diagnosed with advanced esophageal squamous cell carcinoma in the lower thoracic esophagus along with a large IMS in the upper stomach. The patient received preoperative chemotherapy of docetaxel, cisplatin, and 5-fluorouracil (DCF). During the second cycle of DCF, he had upper abdominal pain and was diagnosed with gastric perforation. Omental implantation repair for the perforation, peritoneal drainage, tube-gastrostomy, and tube-jejunostomy were performed.

At 24 days after emergency surgery, he underwent thoracoscopic radical esophagectomy with total gastrectomy and reconstruction with colonic interposition. Pathological findings in the esophagus demonstrated complete replacement of the tumor by fibrosis. The gastric tumor was replaced by scar tissue with multinucleated giant cells along with a small amount of viable cancer cells. The patient was alive and healthy at 14 months after the radical operation, without tumor recurrence.

**DISCUSSION:** The gastric perforation occurred due to rapid regression of the IMS which had involved the whole gastric wall before chemotherapy. Close monitoring to detect rapid tumor shrinkage during chemotherapy in patients with IMS may be warranted. A two-step operation was proposed to achieve safe curative treatment in patients with perforation of IMS during preoperative chemotherapy.

**CONCLUSION:** We describe the first reported case of a patient with esophageal squamous cell carcinoma who showed perforation of IMS during preoperative chemotherapy.

© 2015 The Authors. Published by Elsevier Ltd. on behalf of IJS Publishing Group Ltd. This is an open access article under the CC BY-NC-ND license (<http://creativecommons.org/licenses/by-nc-nd/4.0/>).

## 1. Introduction

Intramural metastasis to the stomach (IMS) from esophageal cancer is rare [1,2], but is considered to be one of the most important poor-prognosis factors associated with a higher risk of distant metastasis [3].

Gastro-intestinal perforations during chemotherapy can be caused by rapid tumor shrinkage and necrosis due to chemotherapy [4]. The incidence and high mortality rate associated with surgery for patients with perforation of gastric cancer or gastric lymphoma during chemotherapy have been reported [4,5]; however, no article could be found that described perforation of IMS from esophageal cancer.

Here, we report a case of esophageal squamous cell carcinoma (ESCC) which showed perforation of IMS during preoperative chemotherapy.

\* Corresponding author. Department of Surgery and Science, Graduate School of Medicine and Pharmaceutical Sciences for Research, University of Toyama 2630 Sugitani, Toyama City, Toyama 930-0194, Japan. Fax: +81 76 434 5043.

E-mail address: [okumura@med.u-toyama.ac.jp](mailto:okumura@med.u-toyama.ac.jp) (T. Okumura).

## 2. Case report

A 68-year-old male consulted one of our hospitals due to appetite loss in May 2014. An upper gastrointestinal (GI) endoscopy revealed an advanced tumor in the lower thoracic esophagus (Fig. 1A) along with a submucosal tumor-like lesion in the upper stomach (Fig. 1B). Endoscopic biopsy from both tumors revealed moderately differentiated squamous cell carcinoma (Fig. 1C). Computed tomography (CT) showed high-density tumors in the lower thoracic esophagus (Fig. 1D) and upper stomach (Fig. 1E), but no evidence of lymph node involvement. The disease was diagnosed as ESCC with IMS, T3N0M1b Stage IVB, according to the classification of the Union for International Cancer Control (UICC, version 7).

The patient received preoperative chemotherapy of docetaxel, cisplatin, and 5-fluorouracil (DCF), which consisted of i.v. docetaxel (70 mg/m<sup>2</sup>) and cisplatin (70 mg/m<sup>2</sup>) on day 1, and the continuous infusion of fluorouracil (750 mg/m<sup>2</sup>/day) on days 1–5 [6]. The regimen was planned to be repeated every 3 weeks with a maximum of three cycles. The patient showed the nadir of immunosuppression on day 10 with febrile neutropenia (neutrophils:450/mm<sup>3</sup>) and recovered by treatment with granulocyte-colony stimulating factor and antibiotics.

On day 5 of the second cycle of DCF, the patient had sudden upper abdominal pain. CT demonstrated tumor regression in the lower esophagus (Fig. 2A). Free air and limited ascites were seen around the regressed tumor in the upper part of the stomach (Fig. 2B).

He was diagnosed with acute panperitonitis due to gastric perforation and received emergency surgery. Surgical findings revealed a 7-mm perforation at the centre of the induration in the upper part of the anterior wall of the stomach (Fig. 2C). There was no tumor mass in the gastric wall. Peritoneal lavage, peritoneal drainage, omental implantation repair for the perforation, tube gastrostomy for gastric drainage and tube jejunostomy for feeding were performed. The patient recovered from surgery without any complications.

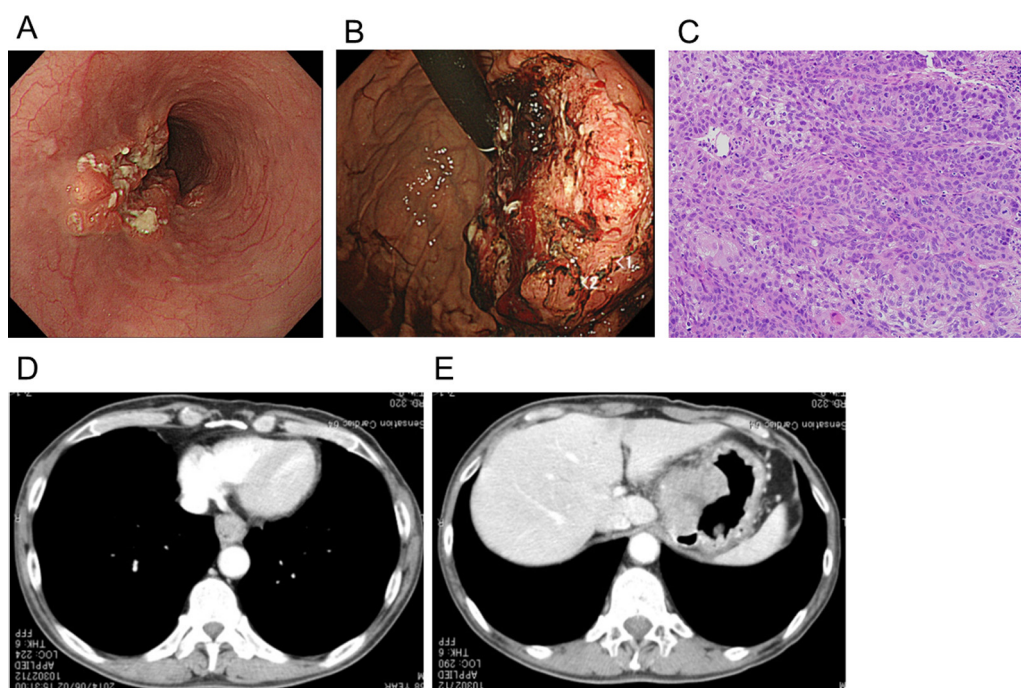
At 24 days after the emergency surgery, he underwent thoracoscopic radical esophagectomy with total gastrectomy, followed by reconstruction with colonic interposition. The patient again recovered from surgery without complications.

The gross appearance of the resected specimen revealed tumor regression both in the lower esophagus and stomach (Fig. 3). Pathological findings in the lesion of the lower esophagus demonstrated complete re-epithelialization and the replacement of submucosa and muscularis propria by fibrosis (Fig. 4A). Multinucleated giant cells that had phagocytosed cornified substances were observed scattered throughout the muscularis propria, indicating that squamous cell carcinoma which had involved the deep part of the muscularis propria had completely regressed with chemotherapy (Fig. 4A). Pathological findings in the perforated ulcer scar in the stomach demonstrated that the gastric wall had been replaced by scar tissue containing multinucleated giant cells, indicating the involvement of squamous carcinoma in all layers of the gastric wall before chemotherapy (Fig. 4B). Although a small number of viable cancer cells were seen at the horizontal margin of the scar, there was no evidence of the residual tumor.

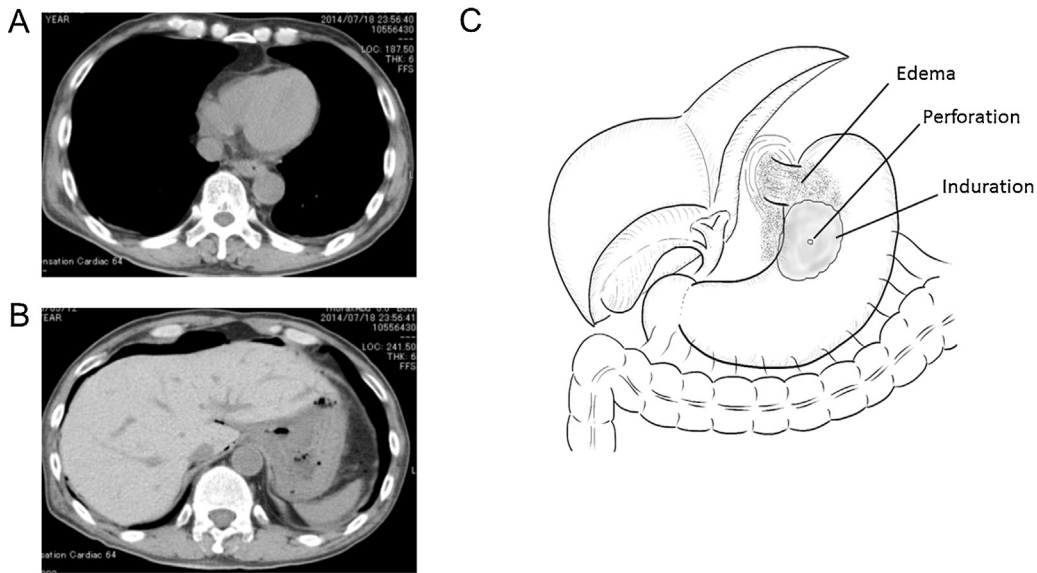
No metastasis was observed in any of the dissected mediastinal or abdominal lymph nodes. Peritoneal lavage cytology showed no malignant cells. The patient has been closely observed as an outpatient and was alive and healthy at 14 months after the radical operation, without any evidence of tumor recurrence.

## 3. Discussion

IMS from esophageal cancer is rare with an incidence of 1–1.7% in surgically resected cases [1,2], but the incidence increases up to 15% in autopsy cases [7]. The predominant location of the primary esophageal carcinomas and IMS have been reported to be the middle/lower thoracic esophagus and gastric body close to the esophagocardial junction, respectively [1]. Histologically, the incidence of moderately differentiated squamous cell carcinoma has



**Fig. 1.** (a) Upper gastrointestinal endoscopy showed an advanced tumor in the lower thoracic esophagus. (b) Upper gastrointestinal endoscopy showed a submucosal tumor-like lesion in the upper stomach. (c) Endoscopic biopsy from both tumors revealed moderately differentiated squamous cell carcinoma. (d) CT showed high-density tumors in the lower thoracic esophagus. (e) CT showed high-density tumors in the upper stomach.



**Fig. 2.** (a) CT demonstrated tumor regression in the lower esophagus on day 5 of the second cycle of DCF. (b) CT demonstrated free air and limited ascites around the regressed tumor in the upper part of the stomach. (c) Surgical findings showed perforation in the upper part of the stomach.

been reported to be the highest [1], with all findings consistent with our present case.

Microlymphatics in the esophageal submucosa which are continuous with those of the gastric submucosa are considered to play a key role in IMS [8].

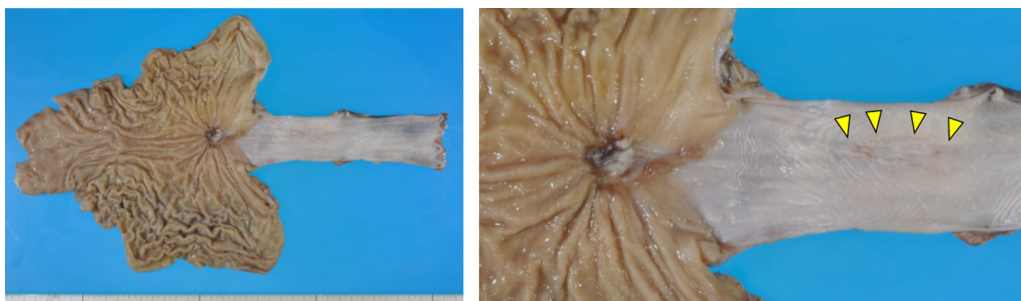
The prognosis for esophageal cancer patients with IMS has been reported to be poor, with an 11.9% postoperative 5-year survival rate due to a higher rate of distant metastasis [3]. Therefore, IMS from esophageal cancer is categorized as a distant metastasis described as M1b Stage IVB, according to the UICC Classification.

On the other hand, recent progress in preoperative chemotherapy has facilitated an improved postoperative prognosis even in advanced esophageal cancer patients. Based on the results of a Japan Clinical Oncology Study Group trial (JCOG 9907), preoperative chemotherapy with cisplatin and 5-fluorouracil (CF) is regarded as a standard treatment for Stage II/III ESCC in Japan [9]. To further improve survival, a phase II trial demonstrated the feasibility of preoperative DCF for Stage II/III ESCC with an overall response rate of 64.3% [6]. DCF also led to improvement in both rapid tumor shrinkage and the survival benefit [6]. Accordingly, a randomized controlled trial comparing CF versus DCF versus chemoradiation as neoadjuvant therapy for locally advanced esophageal cancer is in progress [10]. In addition, preoperative DCF was also reported to be effective in patients with Stage IV (M1-lymph) disease of esophageal cancer [11]. Based on this reported evidence, the present case with IMS received preoperative DCF.

Oncological gastrointestinal perforation has several causes, such as spontaneous tumor rupture with rapid tumor progression, mucosal epithelial cytotoxicity of the anticancer agents or corticosteroids, and rapid tumor shrinkage or necrosis due to chemotherapy [6,7,12]. In the present case, the pathological findings of the perforated stomach demonstrated total replacement of the gastric wall by fibrosis containing multinucleated giant cells which phagocytosed squamous cell carcinoma, indicating that the perforation occurred due to rapid regression of the IMS which had involved in the whole gastric wall before chemotherapy.

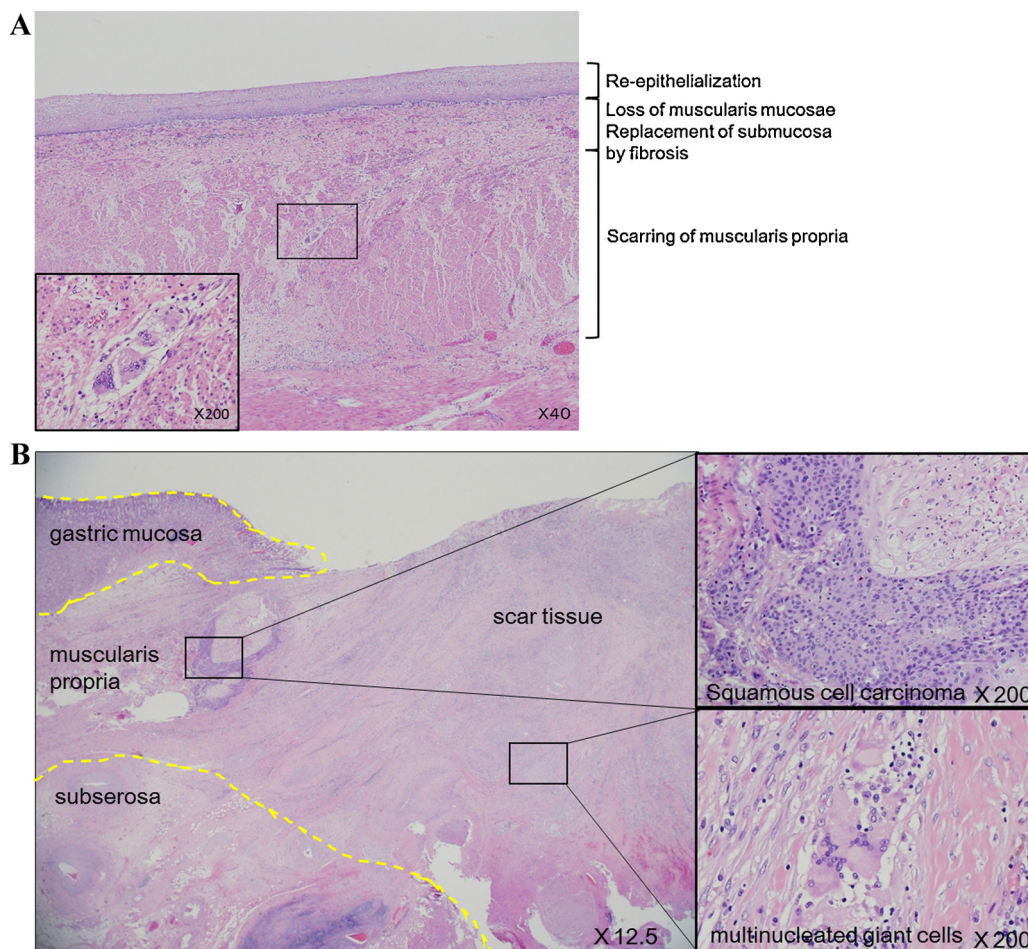
In the present case, we started the second cycle of DCF without imaging diagnosis to assess the response to the first cycle. A close observation using CT or upper GI endoscopy is proposed before starting the next cycle of chemotherapy, not only to rule out the progression of the tumor due to a poor therapeutic response, but also to rule out too rapid tumor regression of large IMS.

The mortality rate following surgery for perforated gastric cancer during chemotherapy was reported to be 40 to 80%, because of immunosuppression and/or undernutrition [6]. In the present case, considering that the nadir of neutropenia was predicted at 5 days after perforation, we performed a two-step operation. Firstly, we performed repair of the perforation, peritoneal drainage, gastric drainage, and tube jejunostomy for feeding to support recovery with minimal surgical invasion. Then, we could safely perform a radical resection after the recovery of the general status without any perioperative complications.



**Fig. 3.** The gross appearance of the resected specimen revealed tumor regression in both the lower esophagus and stomach.





**Fig. 4.** (a) Pathological findings in the lesion of the lower esophagus demonstrated complete re-epithelialization, and replacement of the submucosa and muscularis propria by fibrosis. Multinucleated giant cells that had phagocytosed cornified substances were observed scattered throughout the muscularis propria. (b) Pathological findings in the perforated ulcer scar in the stomach demonstrated that the gastric wall had been replaced by scar tissue containing multinucleated giant cells. A small number of viable cancer cells were seen at the horizontal margin of the scar.

**4. Conclusions**

Here, we describe, to our knowledge, the first reported case of a patient with esophageal squamous cell carcinoma who showed perforation of IMS during chemotherapy. Close monitoring to detect rapid tumor shrinkage during chemotherapy in patients with large IMS may be warranted. A two-step operation was proposed to achieve curative treatment with safety and minimal surgical invasion in a patient with perforation of IMS during pre-operative chemotherapy.

**Authors' contributions**

Tomoyuki Okumura: Played a role in the study conception and design, obtained informed consent, performed the surgical procedures and patient care, and wrote the manuscript.

Yutaka Shimada: Played a role in the study conception and design and wrote the manuscript.

Shozo Hojo: Played a role in the study conception and design and performed the surgical procedures and patient care.

Katsuhisa Hirano: Played a role in the study conception and design, performed the surgical procedures and patient care, and wrote the manuscript.

Shinich Sekine: Played a role in the study conception and design, performed the surgical procedures and patient care, and wrote the manuscript.

Makoto Moriyama: Played a role in the study conception and design, performed the surgical procedures and patient care, and wrote the manuscript.

Shigeharu Miwa: Performed pathological diagnosis.

Takuya Nagata: Played a role in the study conception and design, performed the surgical procedures and patient care, and wrote the manuscript.

Kazuhiro Tsukada: Played a role in the study conception and design, performed the surgical procedures and patient care, and wrote the manuscript.

**Consent**

Written informed consent was obtained from the patient for publication of this case report and accompanying images. A copy of the written consent is available for review by the Editor-in-Chief of this journal on request.

**Acknowledgment**

This work was partly supported by the Grant-in-Aid for Scientific Research (C)MEXT KAKENHI Grant number 15K10088.

## References

- [1] T. Saito, T. Iizuka, H. Kato, H. Watanabe, Esophageal carcinoma metastatic to the stomach: a clinicopathologic study of 35 cases, *Cancer* 56 (1985) 2235–2241.
- [2] Y. Ebihara, M. Hosokawa, S. Kondo, H. Katoh, Thirteen cases with intramural metastasis to the stomach in 1259 patients with oesophageal squamous cell carcinoma, *Eur. J. Cardiothorac. Surg.* 26 (2004) 1223–1225.
- [3] H. Kato, Y. Tachimori, H. Watanabe, Intramural metastasis of thoracic esophageal carcinoma, *Int. J. Cancer* 50 (1992) 49–52.
- [4] T. Chao, C. Wang, M. Chen, Gastroduodenal perforation in cancer patients, *Hepatogastroenterology* 46 (1999) 1878–1881.
- [5] G. Spectre, D. Libster, S. Grisariu, N. Da'as, D.B. Yehuda, Z. Gimmon, et al., Bleeding, obstruction, and perforation in a series of patients with aggressive gastric lymphoma treated with primary chemotherapy, *Ann. Surg. Oncol.* 13 (2006) 1372–1378.
- [6] H. Hara, M. Tahara, H. Daiko, K. Kato, H. Igaki, S. Kadowaki, et al., Phase II. feasibility study of preoperative chemotherapy with docetaxel, cisplatin, and fluorouracil for esophageal squamous cell carcinoma, *Cancer Sci.* 104 (2013) 1455–1460, <http://dx.doi.org/10.1111/cas.12274>.
- [7] L.L. Anderson, T.E. Lad, Autopsy findings in squamous-cell carcinoma of the esophagus, *Cancer* 50 (1982) 1587–1590.
- [8] M. Uehara, D. Manaka, Y. Matsutani, Y. Oji, K. Takemura, M. Shimizu, et al., Gastric wall metastasis from esophageal carcinoma: report of a case, *Jpn. J. Gastroenterol. Surg.* 41 (2008) 41–45.
- [9] N. Ando, H. Kato, H. Igaki, M. Shinoda, S. Ozawa, H. Shimizu, et al., A randomized trial comparing postoperative adjuvant chemotherapy with cisplatin and 5-fluorouracil versus preoperative chemotherapy for localized advanced squamous cell carcinoma of the thoracic esophagus (JCOG9907), *Ann. Surg. Oncol.* 19 (2012) 68–74.
- [10] K. Nakamura, K. Kato, H. Igaki, Y. Ito, J. Mizusawa, N. Ando, et al., Three-arm phase III. trial comparing cisplatin plus 5-FU (CF) versus docetaxel, cisplatin plus 5-FU (DCF) versus radiotherapy with CF (CF-RT) as preoperative therapy for locally advanced esophageal cancer (JCOG1109, NExT study), *Jpn. J. Clin. Oncol.* 43 (2013) 752–755.
- [11] T. Ui, H. Fujii, Y. Hosoya, M. Nagase, M.N. Mieno, M. Mori, et al., Comparison of preoperative chemotherapy using docetaxel, cisplatin and fluorouracil with cisplatin and fluorouracil in patients with advanced carcinoma of the thoracic esophagus, *Dis. Esophagus* 28 (2015) 180–187.
- [12] P.G. Rose, M.S. Piver, Intestinal perforation secondary paclitaxel, *Gynecol. Oncol.* 57 (1995) 270–272.

## Open Access

This article is published Open Access at [sciendoirect.com](http://sciendoirect.com). It is distributed under the [IJSCR Supplemental terms and conditions](#), which permits unrestricted non commercial use, distribution, and reproduction in any medium, provided the original authors and source are credited.