



Received: 2014.05.07
Accepted: 2014.05.08
Published: 2014.07.30

Authors' Contribution:

- A** Study Design
- B** Data Collection
- C** Statistical Analysis
- D** Data Interpretation
- E** Manuscript Preparation
- F** Literature Search
- G** Funds Collection

Interventional Treatment of Mesenteric Venous Occlusion

Heather J. Wichman¹**[B,C,D,E,F]**, Wojciech Cwikiel²**[A,B,C,D,E,F]**, Inger Keussen³**[B,D]**

¹ Department of Radiology, Covenant Medical Center, Waterloo, IA, U.S.A.

² Department of Interventional Radiology, Skane University Hospital, Lund, Sweden

³ Department of Interventional Radiology, Skane University Hospital and Lund University Hospital, Lund, Sweden

Author's address: Heather J. Wichman, Department of Radiology, Covenant Medical Center, 3421 W 9th Str., Waterloo, 50702, IA, U.S.A., e-mail: armah24@yahoo.com

Background:

Mesenteric venous thrombus may be an incidental finding during imaging studies and asymptomatic patients are treated conservatively or with anticoagulant therapy only. Patients with symptomatic acute thrombosis causing bowel ischemia require urgent treatment, which frequently includes extensive surgery. Interventional treatment may be an alternative. Purpose: To present results of interventional treatment in patients with symptomatic occlusion of the mesenteric veins.

Material/Methods:

Eight patients, four men and four women aged 24–74 years (mean 53 years) were treated due to symptomatic portomesenteric venous occlusion of thrombotic origin. Transhepatic (n=5), transsplenic (n=2), and transjugular (n=4) accesses were used. Patients were treated with mechanical thrombus fragmentation (n=4), pharmacological thrombolysis (n=3) and stent placement (n=8). Additional transjugular intrahepatic portosystemic shunt (TIPS) was created to facilitate the outflow from the treated veins (n=4).

Results:

The majority of the patients required combination of different treatment methods. Resolution of symptoms with initial clinical success was achieved in seven of the eight patients, and one patient died the day after the procedure due to sepsis. Two other patients had procedure-related complications; one of them required embolization. Two patients had documented long-term clinical success with patent stents and no symptoms at one year following intervention.

Conclusions:

Endovascular treatment of portomesenteric occlusion in patients with acute symptomatology showed good short-term clinical success rate.

MeSH Keywords:

Mesenteric Vascular Occlusion • Mesenteric Veins • Stents

PDF file:

<http://www.polradiol.com/abstract/index/idArt/890990>

Background

Mesenteric venous thrombosis is uncommon and responsible for 5–15% cases of mesenteric ischemia [1]. Acute mesenteric ischemia and subsequent bowel infarction have a mortality rate of 13–50% [2]. In the majority of patients mesenteric venous thrombus is an incidental finding on imaging studies and is related to portal hypertension, malignancy, or intra-abdominal inflammatory processes [3]. These asymptomatic patients require no treatment or only anticoagulant therapy and follow-up.

Patients with symptomatic, acute (< five days) thrombosis within the superior mesenteric vein (SMV) may be managed surgically [3], but also conservative medical treatment may

be applied in the absence of bowel necrosis. Endovascular treatment of portomesenteric venous thrombosis has been shown to be safe and effective in the majority of patients in the published cases [4–11]. Only a few publications address mesenteric stent placement [9,10,12]. We reported results of stent treatment combined with other methods in patients with symptomatic mesenteric venous occlusion.

Material and Methods

The medical records of treatment of eight patients were reviewed retrospectively following the internal review board approval. The patients, four men and four women aged 24–74 years (mean 53) admitted with symptomatic portomesenteric venous occlusions, were treated with

Table 1. Patients and treatment.

Patient	Sex	Age, years	Occlusion			Ascites	Symptoms at presentation				Access			Initial treatment			Stenting			
			Portal vein	SMV	Splenic		Bleeding	Cholangitis	Ischemia	Pain	Transjugular	Transhepatic	Trans-splenic	Paracentesis	Thrombolysis	Fragmentation/thrombectomy	Portal vein	SMV	Splenic vein	TIPS
1	M	47	X	X		X				X		X	X	X	X	X				X
2	F	24	X	X				X				X				X	X	X		
3	M	61		X				X	X		X				X		X			
4	F	53	X	X					X	X			X			X	X			X
5	M	74		X			X			X	X					X	X	X		
6	M	63	X	X	X			X	X		X					X	X			X
7	F	72		X		X			X		X		X				X			
8	F	33	X	X	X	X	X	X	X	X	X	X	X	X	X	X	X	X	X	X

SMV – superior mesenteric vein; TIPS – transjugular intrahepatic portosystemic shunt.

endovascular interventions. Six patients presented for treatment within four days from acute symptom onset. Two patients presented within one month of worsening symptoms, one of them had intractable ascites and the other had cholangitis. Symptoms included bowel ischemia secondary to compromised venous outflow (n=4), abdominal pain (n=5), ascites (n=3), gastrointestinal bleeding (n=2), and cholangitis secondary to portal biliopathy (n=1).

Occlusions, verified on non-invasive imaging computed tomography (CT) (n=6), magnetic resonance venography (MRV) (n=3), were secondary to acute thrombosis of SMV (n=8), thrombosis of SMV and portal vein (n=5), partial thrombosis of the splenic vein (n=2) and were of chronic nature (n=4). Thrombosis could be also observed in some of the more peripheral SMV branches in a few patients.

Patients' underlying conditions associated with portomesenteric thrombosis were secondary to intra-abdominal malignant tumor with vascular encasement (n=2), Klippel Trenaunay Weber disease (n=1), cryptogenic cirrhosis with portal hypertension (n=1), hypercoagulability disorder (n=3) and portal hypertension with acute SMV thrombosis with unclear etiology (n=1).

All patients underwent endovascular recanalization and stenting procedures of the portomesenteric veins. Procedure-related data included mechanical thrombus fragmentation, catheter-directed thrombolysis, stent placement and TIPS. Four of the patients underwent endovascular thrombectomy and thrombolysis procedures (Table 1).

Paracentesis was performed in patients with a significant amount of ascites prior to the endovascular procedure. Transjugular access to the portal circulation was attempted initially using Rosh-Uchida transjugular liver access set (William Cook Inc, Bloomington, IN). When the portal vein

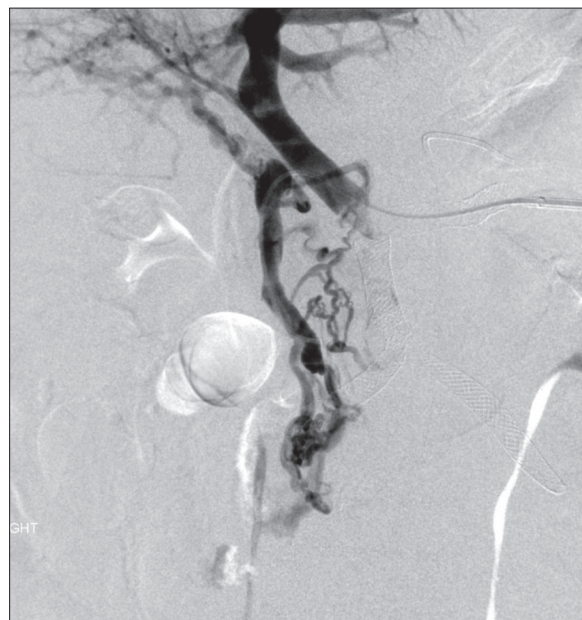

Figure 1. Trans-splenic access with stent placement in narrowed splenic vein and portal veins. Blood flows from mesenteric veins to periportal collaterals.

could not be accessed with several attempts, a trans-hepatic access was achieved using NEFF access set (William Cook). In the patients with extensive portal vein and mesenteric thrombosis beyond the portal confluence, direct trans-splenic access to the splenic vein branch was obtained [12] under ultrasonographic guidance using a NEFF access set (Figure 1). In one patient with coagulopathy and portal hypertension, a 5 F Cobra catheter (Cordis, Miami Lakes, FL) was positioned by transfemoral route, with the tip in the splenic artery, as a precaution for possible splenic hemorrhage, before a direct splenic access was attempted.

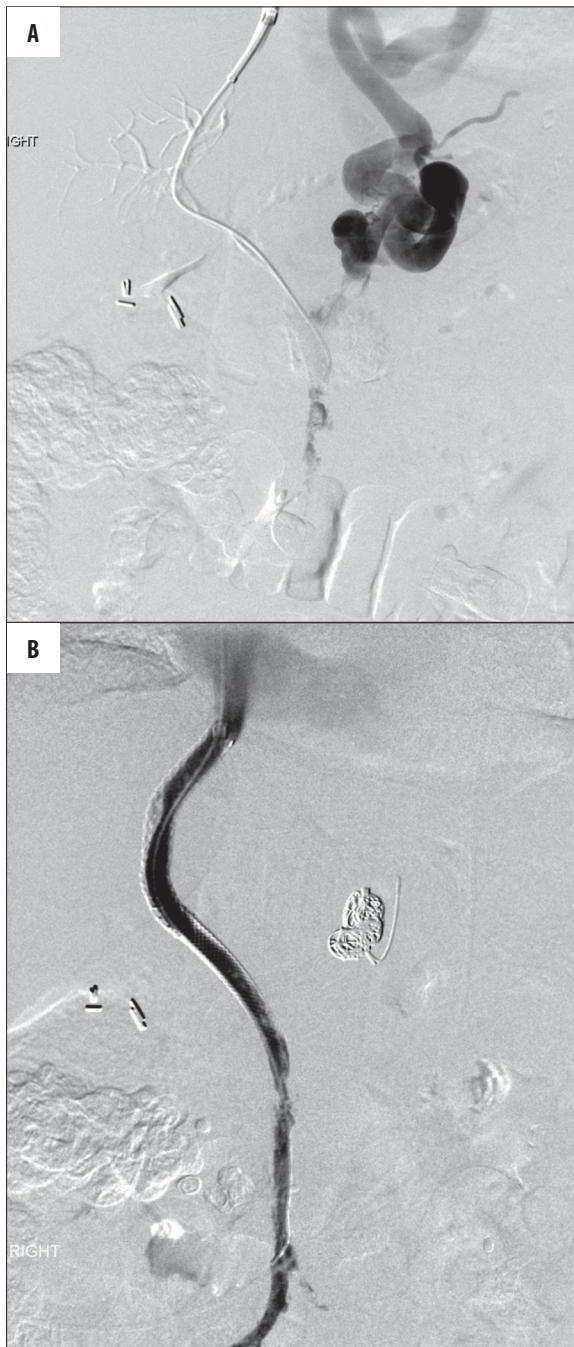

Figure 2. Access through the thrombosed portal vein. (A) Outflow through the enlarged left gastric vein. (B) Final venogram after endovascular thrombolysis and stenting of SMV, portal vein and TIPS placement. Some residual thrombus in SMV and TIPS, no flow through the embolized left gastric vein.

Mechanical thrombectomy procedures included suction of the thrombus using a 6–8 F guiding catheter (Cordis), power pulse thrombolysis (Angio-Jet, MedRad, Warrendale, PA) with heparinized saline and/or tissue plasminogen activator (TPA), and the over-the-wire Trerotola device (Arrow, Reading, PA) in patients with acute thrombus. Angio-Jet and Trerotola devices were chosen based on the availability of the product in the angiography suite. The patients with acute thrombus poorly responsive to initial treatment

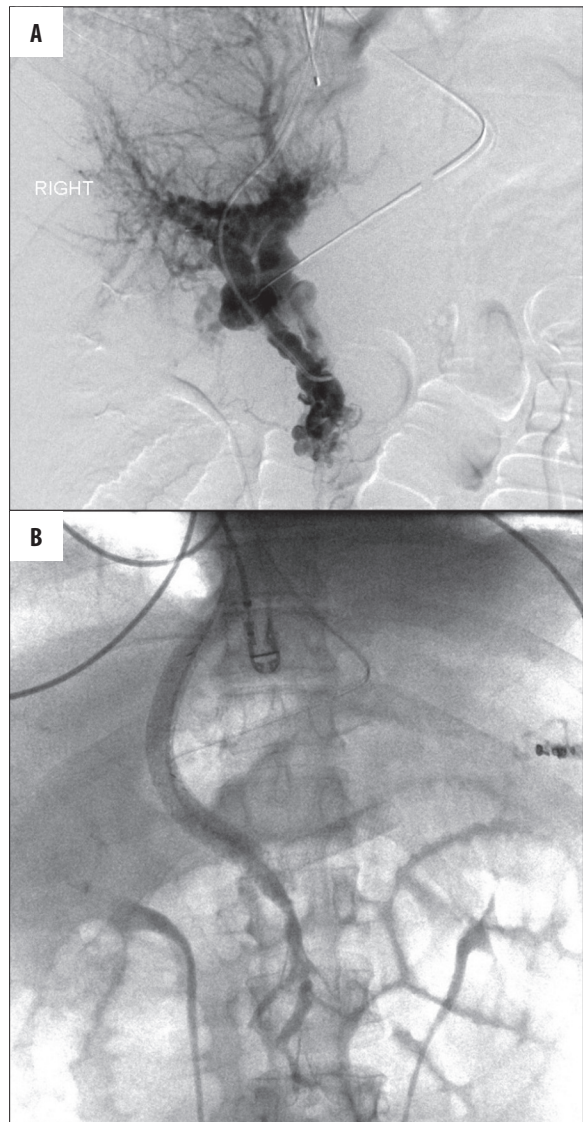


Figure 3. Portal vein occlusion. (A) Large periportal collaterals with no connection to the portal confluence. (B) Portogram following recanalization demonstrates good flow through stents and TIPS.

received continuous TPA infusion (0.02–0.04 mg/kg/hr) directly into the thrombosed mesenteric vessel through a 4–5 F infusion catheter (Unifuse, Angiodynamics, Latham, NY). The effect of the infusion was evaluated every 24 hours, up to 48 hours. In patients with chronic thrombosis, recanalization with angioplasty, and stenting were performed and significant competing collaterals were embolized to improve the flow (Figure 2).

TIPS with stent-graft (Viatorr, Gore, Newark, DE) 8–10 mm in diameter was created in patients with extensive thrombus burden to provide better outflow and also in patients with underlying portal hypertension and evidence of chronic portal vein occlusion (Figure 3). Mesenteric vessels with persistent stenosis or thrombosis were stented with either self-expanding (Wallstent, Boston Scientific, Natick, MA) 8–12 mm in diameter, or balloon expandable stents (Express LD Vascular Stent, Boston Scientific Corporation, Natick,

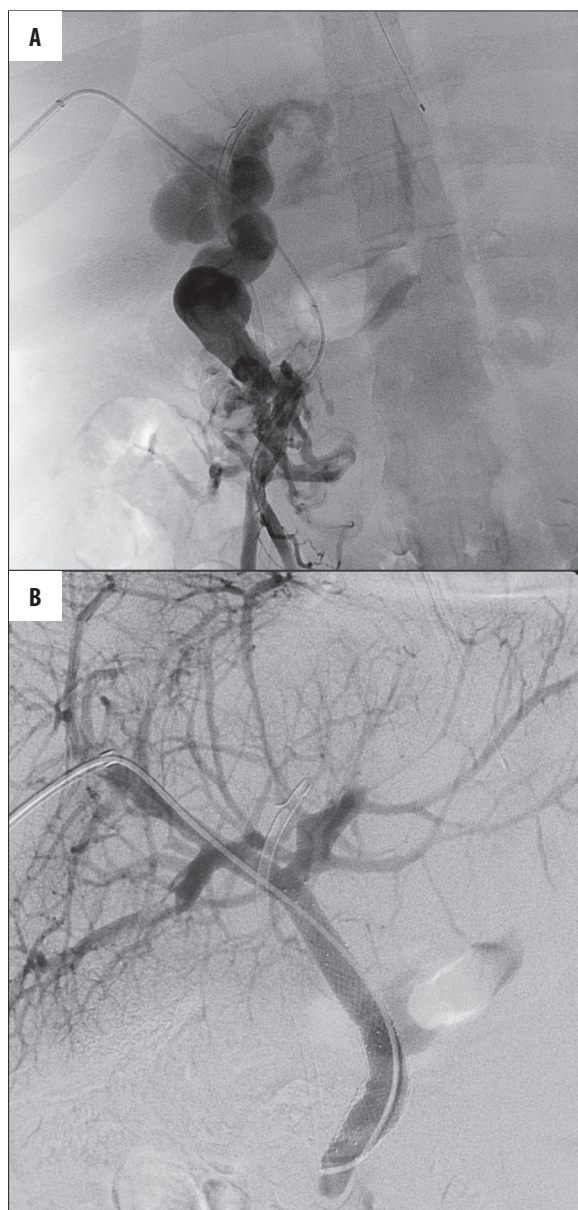


Figure 4. SMV and portal vein and thrombosis. (A) Large periportal collaterals causing biliary obstruction. (B) No flow through the collaterals after stenting of SMV and portal vein.

MA) (Palmaz Genesis stent, Cordis, Bridgewater NJ) sized 1–2 mm greater than the vessel diameter (Figures 4 and 5).

At the end of the procedures, direct trans-hepatic access tract was embolized with gelatin sponge pledgets and trans-splenic access tracts with a combination of platinum coils and gelatin sponge pledgets. Transjugular access was closed by manual compression.

Results

The majority of the patients showed documented short-term clinical success with complete resolution of initial symptoms in seven patients. Three of the patients had patent stents and three had occluded stents at the end of the observation period. One patient died the day after the

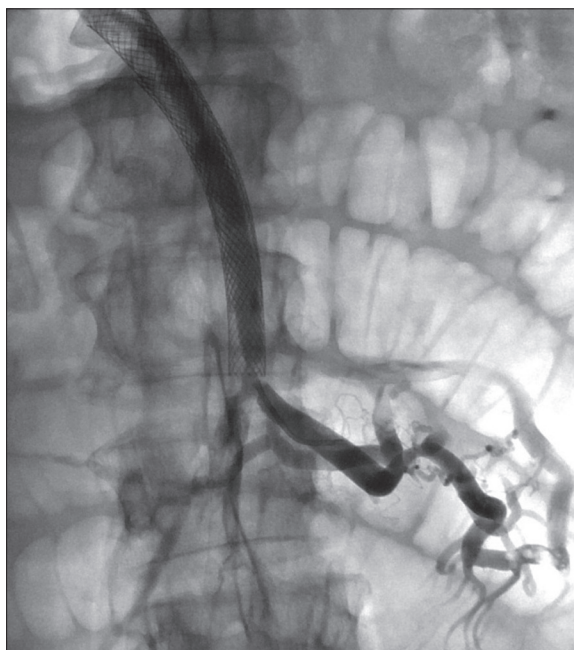


Figure 5. Improved flow through the SMV and the left jejunal branch after stenting and endovascular thrombectomy.

procedure secondary to septic shock; in that patient the short-term clinical success could not be evaluated. Two patients showed long-term clinical success with patent stents and no symptoms at one year after the intervention. Patient number two had cholangitis related to portal biliopathy, which disappeared after decompression of portal biliary collaterals following portal and SMV stent placement. Patient number five returned for another recanalization and stenting after 14 months following the initial procedure. Two patients developed stent thrombosis within six months, but remained symptom-free. Patient number seven did not have follow-up imaging but remained symptom-free six months after the procedure (Table 2).

Two of the patients had a procedure-related complication; both of them underwent thrombectomy procedures. Patient number one had splenic hemorrhage from the transsplenic access tract after 48 hours of ongoing thrombolysis, successfully treated with selective peripheral splenic arterial embolization. Patient number six had mesenteric vein perforation during the procedure, but without clinical consequences (Table 2).

Four of the patients were discharged on anticoagulant medications. Two of the patients with patent stents were on anticoagulation medications (Table 2).

Discussion

Bowel ischemia is secondary to mesenteric venous thrombosis in 5–15% cases [1], but in the majority of patients it is caused by compromised arterial circulation. Bowel ischemia progressing to infarction has been shown to have a significant mortality rate, of 13–50% [2].

A symptomatic porto-mesenteric thrombosis may be secondary to different medical conditions. Surgery is often

Table 2. Patient data and outcome summary.

Patient	Underlying condition	Complications	Medication at discharge	Outcome
1	Prothrombin 20210 mutation	Splenic tract hemorrhage	Clopidogrel × 3 M warfarin	2 yrs. patent stents, symptom-free
2	Klippel-Trenaunay-Weber	None	None	3 yrs. patent stents, symptom-free
3	Pancreatic mass	None	Clopidogrel × 3 M	7 M patent stents, symptom-free
4	Portal hypertension	None	Warfarin	5 M occluded stents, symptom-free
5	Abdominal carcinoid duodenal varices	None	None	14 M symptom-free then recurrent GIB, occluded stents, expired 8 days post re-intervention at hospice
6	Protein S deficiency, sepsis	Mesenteric vein perforation	None	Expired 1 day post procedure of septic shock.
7	Portal HTN, acute SMV thrombosis	None	None	9 M symptom-free, stent patency unknown.
8	Hypercoagulable disorder	None	Warfarin	6 M occluded stents, symptom-free

SMV – superior mesenteric vein; GIB – upper gastrointestinal bleeding; M – months.

difficult or impossible and endovascular treatment may be the only durable option for a symptomatic patient. Two of our patients with malignancy-induced mesenteric thrombosis responded promptly to the treatment and showed long-term clinical success without procedure-related complications. Short-term success with palliation of symptoms related to malignant mesenteric thrombosis has been reported previously [4,5,9].

Three of our patients with hypercoagulability disorder were admitted with severe acute symptoms and profound mesenteric thrombus burden. Those patients underwent initially extensive thrombectomy attempts. Two of them developed procedure-related complications. One of those complications, i.e. splenic access tract hemorrhage, occurred after 48 hours of TPA infusion and was successfully treated with distal splenic artery branch embolization. There is limited evidence of the safety of trans-splenic access for intervention, but we showed its usefulness in cases of extensive thrombosis limiting the possibility of the trans-jugular and trans-hepatic access.

The other complication, mesenteric vein perforation, was most likely due to the concurrent intra-abdominal sepsis in the patient with known pre-procedural septic shock. Despite initial technical success of the procedure, that patient died the day after the intervention. Similar experience has been reported with greater complication rates in patients with increased severity of symptoms and clinical deterioration, including death from sepsis, and thrombus burden necessitating repeated thrombolysis efforts in hypercoagulability [6,7,10]. Three of our patients had symptoms related to non-cirrhotic portal hypertension, secondary to acute thrombosis. The symptoms of the patient with Klippel Trenaunay Weber's disease can also be attributed to portal hypertension secondary to genetic vascular derangement, resulting in chronic portomesenteric thrombosis. The patients in that group showed long- and intermediate-term clinical success. The patient with cryptogenic cirrhosis

and portal hypertension with concurrent SMV thrombosis developed TIPS stent occlusion five months after placement, but continued to be symptom-free. It was shown that TIPS stent patency significantly decreases with splanchnic vein involvement in addition to portal vein thrombus [9].

Evaluation of stent patency in our study was limited due to a lack of a sufficient follow-up, since the majority of those patients returned to their home hospitals. Correlation of stent patency with underlying diseases, initial thrombus burden, and post-stent anticoagulation therapy was not found. Of the patients with post-procedure imaging, 50% had patent stents (n=3). However, the patients with occluded stents were also symptom-free, which may be explained by the later formation of mesenteric venous collaterals. Mesenteric vein recanalization and stenting in the acute thrombotic episode prevents mesenteric ischemia and provides time for collaterals to develop. There were no complications related to trans-hepatic access and one complication related to trans-splenic access. However, that patient had been on TPA infusion for 48 hours prior to his splenic tract hemorrhage, which was promptly resolved with distal splenic arterial embolization. Several other studies have shown relatively limited or no complications related to transhepatic access [4,5,7,9,10,13]. Limitations of this study are a small number of patients, inhomogeneity of material and used methods.

Conclusions

In conclusion, our study has shown that endovascular treatment (including stenting) of patients with acute symptoms secondary to porto-mesenteric venous occlusion has good short-term clinical success rate. The majority of the patients remain later asymptomatic regardless of stent patency.

Declaration of conflicting interests

The authors declare that there are no conflicts of interest.

References:

1. Kumar S, Sarr M, Kamath P: Mesenteric Venous thrombosis. *N Engl J Med*, 2001; 345(23): 1683-88
2. Rhee RY, Gloviczki P: Mesenteric Venous Thrombosis. *Surg Clin North Am*, 1997; 77: 327-38
3. Bradbury M, Kavanagh P, Bechtold R et al: Mesenteric Venous Thrombosis: Diagnosis and Non-Invasive Imaging. *Radiographics* 2002; 22: 527-41
4. Poplasky M, Kaufman J, Geller S et al: Mesenteric Venous Thrombosis Treated with Urokinase via the Superior Mesenteric Artery. *Gastroenterology*, 1996; 110: 1633-35
5. Hoffer E, Krohmer S, Gemery J et al: Endovascular Recanalization of Symptomatic Portomesenteric Venous Obstruction after Pancreaticoduodenectomy and Radiation. *J Vasc Interv Radiol*, 2009; 20(12): 1633-37
6. Haskal Z: Power - Pulse Thrombolysis, Thrombectomy, and TIPS Formation for the Accelerated Treatment of Portosplenomesenteric Thrombosis in Budd Chiari Syndrome. *J Vasc Interv Radiol*, 2007; 18(11): 1458-60
7. Kim H, Patra A, Khan J et al: Transhepatic Catheter Directed Thrombectomy and Thrombolysis of Acute Superior Mesenteric Venous Thrombosis. *J Vasc Interv Radiol*, 2005; 16(12): 1685-91
8. Luo J, Yan Z, Wang J et al: Endovascular Treatment for Non-Acute Symptomatic Portal Venous Thrombosis through Intrahepatic Portosystemic Shunt Approach. *J Vasc Interv Radiol*, 2011; 22(1): 61-69
9. Jia Z, Jiang G, Tian F et al: Early endovascular treatment of superior mesenteric occlusion secondary to thromboemboli. *Eur J Vasc Endovasc Surg*, 2014; 47(2): 196-203
10. Hollingshead M, Burke C, Mauro M et al: Transcatheter Thrombolytic Therapy for Acute Mesenteric and Portal Vein Thrombosis. *J Vasc Interv Radiol*, 2005; 16(5): 651-61
11. Liu FY, Wang MQ, Fan QS et al: Interventional treatment for symptomatic acute-subacute portal and superior mesenteric vein thrombosis. *World J Gastroenterol*, 2009; 15(40): 5028-34
12. Yamakado K, Nakatsuka A, Tanaka N et al: Portal Venous Stent Placement in Patients with Pancreatic and Biliary Neoplasms Invading Portal Veins and Causing Portal Hypertension: Initial Experience. *Radiology*, 2001; 220: 150-56
13. Cwikiel W: Interventional Procedures Involving Portal Vein Circulation: A Review. *Acta Radiologica*, 2006; 47: 145-56