

Case Report

Neurocytoma of the cerebellum

Hideki Ogiwara, Steve Dubner¹, Eileen Bigio¹, James ChandlerDivision of Neurosurgery, ¹Pathology, Northwestern University, Feinberg, School of Medicine, Chicago, IL, USAE-mail: Hideki Ogiwara - hideki_o@d5.dion.ne.jp; Steve Dubner - s-dubner@northwestern.edu, Eileen Bigio - e-bigio@northwestern.edu;*James P. Chandler - jchandler@nmff.orgp

*Corresponding author

Received: 28 December 10

Accepted: 3 February 11

Published: 23 March 11

Surg Neurol Int 2011, 2:36This article is available from: <http://www.surgicalneurologyint.com/content/1/2/36>

Copyright: © 2011 Ogiwara H. This is an open-access article distributed under the terms of the Creative Commons Attribution License, which permits unrestricted use, distribution, and reproduction in any medium, provided the original author and source are credited.

This article may be cited as:Ogiwara H, Dubner S, Bigio E, Chandler J. Neurocytoma of the cerebellum. *Surg Neurol Int* 2011;2:36.Available FREE in open access from: <http://www.surgicalneurologyint.com/text.asp?2011/1/2/78246>**Abstract**

Background: Neurocytomas are benign central nervous system tumor composed of small cells with characteristics of neuronal differentiation; they are usually located in the supratentorial periventricular region, in close relation to the septum pellucidum and the foramen of Monro.

Case Description: Herein we report a rare case of a neurocytoma located in the cerebellar hemisphere. To date there are only four such reported cases.

Conclusion: Neurocytomas should be considered in the differential diagnosis of mass lesions in the cerebellum.

Key Words: Cerebellar hemisphere, neurocytoma, posterior fossa

Access this article online**Website:**www.surgicalneurologyint.com**DOI:**

10.4103/2152-7806.78246

Quick Response Code:**INTRODUCTION**

Neurocytomas are small cell tumors first described by Hassoun, *et al.*^[10] The characteristic features of this rare tumor include 1) intraventricular location, 2) predominant occurrence in young adults around the third decade, 3) histopathological resemblance with oligodendrogliomas or ependymomas 4) expression of neuron-specific antigens and 5) ultrastructural features of neuronal differentiation.^[3,9,10,23,31,33] They comprise 0.1-0.5% of all brain neoplasms and present mostly as supratentorial intraventricular or periventricular tumors.^[33] There have been isolated reports of neurocytomas occurring at various sites within the cerebrum or spinal cord.^[4,7,18,20,22,26] We report an unusual case of a neurocytoma occurring in the cerebellar hemisphere.

CASE REPORT

A 45-year-old woman presented with intermittent episodes

of vertigo and dizziness of 5 years duration. A magnetic resonance (MR) image demonstrated an oblong 2×1.5 cm inferior right cerebellar hemispheric enhancing lesion which showed minimal mass effect [Figure 1]. Owing to our suspicion that the lesion may have represented a high-grade glioma or lymphoma we took the patient for elective needle biopsy with possibility of conversion to an open procedure for tumor resection. An intraoperative smear demonstrated discohesive cells within a delicate neuropil-like background. The nuclei showed some pleomorphism and the chromatin was clock-face to speckled [Figure 2a]. The preliminary diagnosis at the time of surgery was angiotrophic tumor, favoring lymphoma thus prompting the decision not to proceed with craniotomy. Permanent sections revealed a tumor composed of cells with small, round nuclei with speckled chromatin. Both perivascular and intratumoral acellular zones were noted. Mitoses were not identified [Figure 2b]. A Ki67 immunostain showed a very low proliferation index <1% [Figure 2c]. Lymphoma was ruled out with a negative

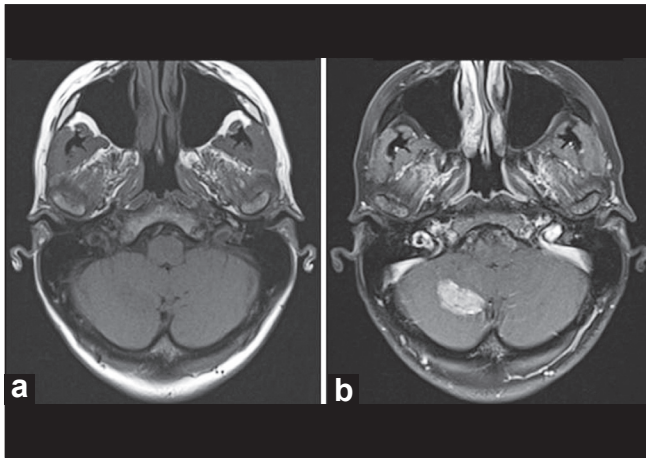


Figure 1: (a) Magnetic resonance imaging demonstrating the tumor in the right cerebellar hemisphere as a hypointense lesion in a T1-weighted image (b) and as an enhancing lesion in a gadolinium T1-weighted image

immunostain for CD45 (common leukocyte antigen). The architectural appearance of the tumor made ependymoma a possibility, but immunostains for glial fibrillary acid protein (GFAP) and epithelial membrane antigen (EMA) were negative. A synaptophysin immunostain demonstrated diffuse positivity [Figure 2d]. These histopathological findings were consistent with a low-grade neurocytic tumor. While surgical resection was a consideration, the risks of injury to cerebellospinal tracts and the dentate nucleus were felt to be high. Given the relative paucity of neurologic symptoms, we elected to follow the lesion with periodic MRIs and close neurologic checks. There was no evidence of progression at 14-month follow-up.

DISCUSSION

Neurocytomas typically consist of dense areas of small cells with a patchy fibrillary network and demonstrate features of neuronal differentiation. They characteristically demonstrate positive reactivity for neuron-specific enolase and synaptophysin.^[3,7,9,11,19,27,31] The differential diagnoses of neurocytoma includes ependymomas, oligodendrogliomas, dysembryoplastic neuroepithelial tumors (DNTs), and lymphoma.^[9,17]

Oligodendrogliomas and ependymomas typically do not demonstrate patchy fibrillary stroma. They show a positive reactivity for GFAP and S-100 protein and negative for markers of neuronal differentiation, which are not the characteristics of neurocytomas.^[9,29,31] DNTs demonstrate an abundance of ganglion cells and characteristically contain a mucoid matrix that is not observed in neurocytomas.^[10,17]

Two additional and rather newly described entities of the cerebellum include rosette-forming glioneuronal tumor

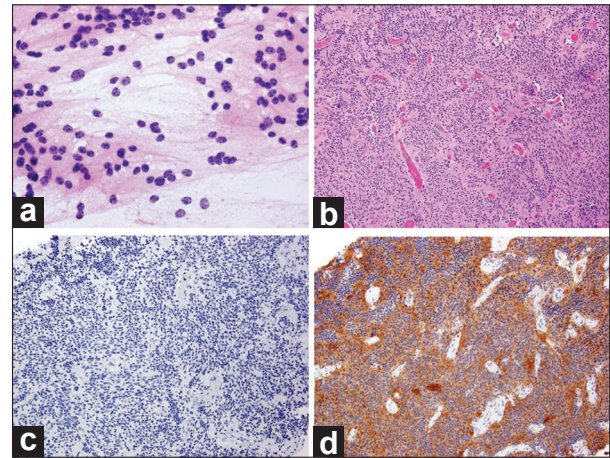


Figure 2: Histology slides. (a) Intraoperative smear (×400) showing discohesive cells with minimal cytoplasm and neurocytic nuclei with speckled chromatin. (b) (H and E, ×100) showing cells with small, round nuclei, minimal pleomorphism and no mitotic activity. Perivascular acellular zones and scattered intratumoral acellular zones, reminiscent of Homer-Wright rosettes were noted. (c) Ki67 immunostain (×100) showing a very low proliferation index <1%. (d) Synaptophysin immunostain (×100) showing diffuse positivity

(RGNT) of the 4th ventricle and liponeurocytoma. RGNT of the 4th ventricle was first described in a series of 11 patients by Komori *et al.*^[16] They appear to derive from pluripotential cells of the subependymal plate,^[25] which could explain the cerebellar midline location in almost all the reported patients. To date there are 30 reported cases of these tumors. There is only one reported case of lateral cerebellar origin of RGNT.^[21] Histopathologically, RGNT shows a biphasic neurocytic and glial architecture. RGNT can be differentiated from neurocytomas due to the presence of glial component. Liponeurocytomas are rare and slow-growing tumors located predominantly in the cerebellum.^[6] In 2000, the World Health Organization (WHO) classified cerebellar liponeurocytoma as a distinct entity from medulloblastoma in terms of prognostic, epidemiological and clinical aspects. This rare tumor is WHO grade I–II, generally with an accordingly indolent behavior.^[15] They occur generally in the cerebellum and are characterized by many lipidized cells found in clusters or scattered between small neoplastic cells. Immunohistochemical staining demonstrates both neuronal and glial differentiation. Mitotic activity is generally low in these lesions.^[24] Liponeurocytomas can be differentiated from neurocytomas due to the presence of glial differentiation and lipid component.

The origin of the neurocytomas is not fully understood. Based on the predominant intraventricular location and properties of neurocytoma cells which can differentiate into both glia and neuron, it has been proposed that they originate from bipotential progenitor cells in the periventricular matrix.^[3,12,13,30,32] On the other hand, it was recently reported that neural stem cells, which have the

potential to differentiate into astrocytes, oligodendrocytes or neurons, reside not only in the periventricular area of cerebellum but also in the cerebellar cortex.^[1,2] We postulate that cerebellar neurocytomas occurring remote from the ventricle, as in our case, may originate from those neural stem cells in cerebellar cortex.

Surgical biopsy and, when safe, gross total resection is usually recommended as the initial treatment modality for patients with cerebellar neurocytoma. In the presented case, the patient's symptoms did not correlate with her MRI finding. The decision to proceed with biopsy was based on the radiographic suspicion that the lesion might represent a glioma, metastasis, lymphoma, inflammatory condition, or a demyelinating process.

There is no consensus regarding the role of postoperative adjuvant therapy for neurocytomas. In our case given the relatively small size of the lesion and benign pathology, we elected to follow the patient without any adjuvant therapy. Surgical resection will be considered should the lesion grow or symptoms related to the lesion develop.

To date there are only four reported cases of a neurocytoma in the cerebellum, three in the vermis and one in the cerebellar hemisphere.^[5,8,14,25] While exceedingly rare, this entity should be considered in the differential diagnosis of enhancing lesions of the cerebellum.

REFERENCES

- Alcock J, Lowe J, England T, Bath P, Sottile V. Expression of Sox 1, Sox2 and Sox9 is maintained in adult human cerebellar cortex. *Neurosci Lett* 2009;450:114-6.
- Alcock J, Sottile V. Dynamic distribution and stem cell characteristics of Sox1-expressing cells in the cerebellar cortex. *Cell Res* 2009;19:1324-33.
- Barbosa MD, Balsitis M, Jaspan T, Lowe J. Intraventricular neurocytoma: A clinical and pathological study of three cases and review of the literature. *Neurosurgery* 1990;26:1045-54.
- Brat DJ, Scheithauer BW, Eberhart CG, Burger PC. Extraventricular neurocytomas: Pathologic features and clinical outcome. *Am J Surg Pathol* 2001;10:1252-60.
- Brandis A, Heyer R, Hori A, Walter GF. Cerebellar neurocytoma in an infant: An important differential diagnosis from cerebellar neuroblastoma and medulloblastoma? *Neuropediatrics* 1997;28:235-8.
- Buccoliero AM, Caldarella A, Bacci S, Gallina P, Taddei A, Di Lorenzo N, et al. Cerebellar liponeurocytoma: Morphological, immunohistochemical, and ultrastructural study of a relapsed case. *Neuropathology* 2005;25:77-83.
- Coca S, Moreno M, Martos JA, Rodriguez J, Barcena A, Vaquero J. Case report. Neurocytoma of spinal cord. *Acta Neuropathol* 1994;87:537-40.
- Enam SA, Rosenblum ML, Ho KL. Neurocytoma in the cerebellum. Case report. *J Neurosurg* 1997;87:100-2.
- Figarella-Branger D, Pellissier JF, Dumas-Duport C, Delisle MB, Pasquier B, Parent M, et al. Central neurocytomas. Critical evaluation of a small-cell neuronal tumor. *Am J Surg Pathol* 1992;16:97-109.
- Hassoun J, Gambarelli D, Grisoli F, Pellet W, Salamon G, Pellissier JF, et al. Central neurocytoma. An electron-microscopic study of two cases. *Acta Neuropathol* 1982;56:151-6.
- Hassoun J, Söylemezoglu F, Gambarelli D, Figarella-Branger D, von Ammon K, Kleihues P. Central neurocytoma: A synopsis of clinical and histological features. *Brain Pathol* 1993;3:297-306.
- Ishiiuchi S, Nakazato Y, Iino M, Ozawa S, Tamura M, Ohye C. *In vitro* neuronal and glial production and differentiation of human central neurocytoma cells. *J Neurosci Res* 1998;51:526-35.
- Ishiiuchi S, Tamura M. Central neurocytoma: an immunohistochemical, ultrastructural and cell culture study. *Acta Neuropathol (Berl)* 1997;94:425-35.
- Kapoor N, Gandhi A, Chaurasia AK. Central neurocytoma in the vermis of the cerebellum. *Indian J Pathol Microbiol* 2009;52:108-9.
- Kleihues P, Cavenee WK, editors. Pathology and genetics of tumours of the nervous system. World Health Organization Classification of Tumours. Vol 1. Lyon, France: International Agency for Research on Cancer; 2000.
- Komori T, Scheithauer BW, Hirose T. A rosette-forming glioneuronal tumor of the fourth ventricle. *Am J Surg Pathol* 2002;26:582-91.
- Leung SY, Gwi E, Ng HK, Fung CF, Yam KY. Dysembryoplastic neuroepithelial tumor: A tumor with small neuronal cells resembling oligodendroglioma. *Am J Surg Pathol* 1994;18:604-14.
- Louis DN, Swearingen B, Linggood RM, Dickersin GR, Kretschmar C, Bhan AK, et al. Clinical study. Central nervous system neurocytoma and neuroblastoma in adults-report of eight cases. *J Neurooncol* 1990;9:231-8.
- Maiuri F, Spaziante R, De Caro ML, Cappabianca P, Giamundo A, Iaconetta G. Central neurocytoma: Clinico-pathological study of 5 cases and review of the literature. *Clin Neurol Neurosurg* 1995;97:219-28.
- Miller DC, Kim R, Zagzag D. Neurocytomas: Non-classical sites and mixed elements. *J Neuropathol Exp Neurol* 1992;51:364.
- Marhold F, Preusser M, Dietrich W, Prayer D, Czech T. Clinicoradiological features of rosette-forming glioneuronal tumor (RGNT) of the fourth ventricle: Report of four cases and literature review. *J Neurooncol* 2008;90:301-8.
- Nishio S, Takeshita I, Kaneko Y, Fukui M. Cerebral neurocytoma. A new subset of benign neuronal tumors of the cerebrum. *Cancer* 1992;70:529-37.
- Nishio S, Tashima T, Takeshita I, Fukui M. Intraventricular neurocytoma: Clinicopathological features of six cases. *J Neurosurg* 1988;68:665-70.
- Owler BK, Makeham JM, Shingde M, Besser M. Cerebellar liponeurocytoma. *J Clin Neurosci* 2005;12:326-9.
- Pal L, Santosh V, Gayathri N, Das S, Das BS, Jayakumar PN, et al. Neurocytoma/rhabdomyoma (myoneurocytoma) of the cerebellum. *Acta Neuropathol* 1998;95:318-23.
- Polli FM, Salvati M, Miscusi M, Delfini R, Giangaspero F. Neurocytoma of the spinal cord: Report of three cases and review of the literature. *Acta Neurochir (Wien)* 2009;151:569-74.
- Robbins P, Segal A, Narula S, Stokes B, Lee M, Thomas W. Central neurocytoma. A clinicopathological, immunohistochemical and ultrastructural study of 7 cases. *Pathol Res Pract* 1995;191:100-11.
- Rosenblum MK. The 2007 WHO classification of nervous system tumors: Newly recognized members of the mixed glioneuronal group. *Brain Pathol* 2007;17:308-13.
- Tzaan WC, Ho YS, Chang CN, Lin TK, Wong CW. Intraventricular neurocytoma: Four cases report. *J Neurooncol* 1992;13:239-46.
- Vallat-Decouvelaere A, Gauchez P, Varlet P, Delisle M, Popovic M, Boissonnet H, et al. So-called malignant and extra-ventricular neurocytomas: Reality or wrong diagnosis. A critical review about two overdiagnosed cases. *J Neurooncol* 2000;48:161-72.
- von Deimling A, Janzer R, Kleihues P, Wiestler OD. Patterns of differentiation in central neurocytoma. An immunohistochemical study of eleven biopsies. *Acta Neuropathol* 1990;79:473-9.
- Westphal M, Stavrou D, Nausch H, Valdeuza JM, Herrmann HD. Human neurocytoma cells in culture show characteristics of astroglial differentiation. *J Neurosci Res* 1994;38:698-704.
- Yasargil MG, von Ammon K, von Deimling A, Valavanis A, Wichmann W, Wiestler OD. Central neurocytoma: Histopathological variants and therapeutic approaches. *J Neurosurg* 1992;76:32-7.